

Articaine Infiltration for Anesthesia of Mandibular First Molars

Ian P. Corbett, PhD, Mohammad D. Kanaa, MPhil, John M. Whitworth, PhD, and John G. Meechan, PhD

Abstract

A randomized, controlled trial of 31 healthy volunteers compared 4% articaine with 1:100,000 epinephrine buccal infiltration to buccal plus lingual infiltration of the same dose of drug in achieving pulpal anesthesia of mandibular first molar teeth. Data were compared with efficacy of an inferior alveolar nerve block using 2% lidocaine 1:80,000 epinephrine in a cohort of 27 of the volunteers. Anesthesia was determined using electronic pulp testing. Buccal and buccal plus lingual infiltrations of articaine with epinephrine did not differ in efficacy in obtaining pulpal anesthesia for mandibular permanent first molars ($p = 0.17$). Efficacy of 4% articaine with epinephrine infiltrations for first molar pulp anesthesia was similar to that of an IANB using lidocaine with epinephrine over a 30-minute study period (96 and 80 episodes of no response to maximal stimulation respectively, $p = 0.097$). Subjective tooth numbness was more common after IANB than buccal infiltration ($p = 0.005$). The discomfort of buccal infiltration with articaine was volume dependent ($p = 0.017$) and similar to that of an IANB. (*J Endod* 2008;34:514–518)

Key Words

Anesthesia, articaine, inferior alveolar, infiltration, lidocaine, mandibular

From the School of Dental Sciences, Newcastle University, Newcastle upon Tyne, United Kingdom.

Address requests for reprints to Dr I.P. Corbett, School of Dental Sciences, Newcastle University, Framlington Place, Newcastle upon Tyne, United Kingdom NE2 4BW. E-mail address: i.p.corbett@ncl.ac.uk.

0099-2399/\$0 - see front matter

Copyright © 2008 by the American Association of Endodontists.

doi:10.1016/j.joen.2008.02.042

Articaine has been used as a local anesthetic in dentistry for over 20 years and was introduced into the United Kingdom in 1999 and the United States in 2000. Articaine has been shown in clinical trials to be safe and effective (1–3), and our own recent work has shown that a buccal infiltration of 4% articaine with 1:100,000 epinephrine is more effective than a similar injection of 2% lidocaine with 1:100,000 epinephrine in obtaining pulp anesthesia in mandibular molars of healthy volunteers (4). This superiority of 4% articaine with epinephrine over 2% lidocaine with epinephrine after mandibular infiltration was confirmed by the work of Robertson and colleagues (5). The success of mandibular infiltration with articaine and epinephrine for first molar anesthesia is comparable to that of an inferior alveolar nerve block with 2% lidocaine and epinephrine when similar outcome measures are used (6–12). A recent blinded crossover study by Jung (13) directly compared the two techniques, with statistically comparable success of around 50% for articaine infiltration and lidocaine inferior alveolar nerve blocks for mandibular first molar anesthesia.

Anesthetic failure after an inferior alveolar nerve block may be caused by several factors, including collateral innervation (14–16) and supplementary injections can be useful in overcoming such failure (17). Supplemental intraosseous administration of lidocaine or articaine has been reported to be effective in approximately 90% of clinically inadequate anesthesia (18–20). Rosenberg and colleagues (21) showed articaine and lidocaine to have a similar efficacy for pain reduction when given as a supplemental buccal infiltration for inadequate pulpal anesthesia during endodontic procedures. Additionally, the combination of a buccal and lingual infiltration of lidocaine has been shown to be more effective than buccal alone in obtaining pulpal anesthesia of lower anterior teeth (22).

The purpose of the present investigation was to compare the efficacy of articaine buccal infiltration to buccal plus lingual infiltration of the same dose in the lower first molar region as a means of providing pulpal anesthesia of the mandibular first molar tooth in healthy volunteers. In addition, the results of the present study were compared to those obtained in a cohort of the present subjects who received 2% lidocaine with 1:80,000 epinephrine as an inferior dental block in a concurrent investigation (23).

Materials and Methods

A power calculation using data from a previous study (22) indicated that 31 subjects would provide a 90% chance of detecting an effect size of 0.83 (a change of 0.83 standard deviations [SDs]) in a continuous outcome measure, assuming a significance level of 5% and a correlation of 0.5 between responses from the same subject. The null hypothesis tested was that buccal and buccal plus lingual infiltrations of articaine did not differ in their efficacy for pulpal anesthesia of mandibular first permanent molar teeth.

Volunteers required the presence of at least one vital lower first molar tooth. Exclusion criteria included any reported allergy to local anesthetic agents, unstable cardiovascular disease, pregnancy, and neurologic disorders with sensory disturbance. Approval was obtained from the institutional review board, the Local Research Ethics Committee, and the UK Medicines and Healthcare Products Regulatory Authority. All participants provided informed written consent.

Although three parties were involved at each stage, the investigation was regarded as a double-blind, randomized controlled trial as both the subject and individual assessing outcome were blinded to the anesthetic administration method. The investigator

administering all anesthetics had no involvement in measuring outcomes. Randomization was performed by a researcher who was not involved in delivering the local anesthetic or assessing outcome (JGM) using a Web-based computer program (http://department.obg.cuhk.edu.hk/researchsupport/random_integer.asp). Blinding of allocation was maintained until completion of the trial. All interventions were performed in a dental hospital clinical setting.

The following treatments were given at separate visits:

1. Buccal infiltration of 1.8 mL 4% articaine with 1:100,000 epinephrine in the mucobuccal fold adjacent to a mandibular first molar with simulated injection (ie, needle penetration only) linguallly.
2. Buccal infiltration of 0.9 mL 4% articaine with 1:100,000 epinephrine plus lingual infiltration of 0.9 mL 4% articaine with 1:100,000 epinephrine.

Every volunteer received each treatment over 2 visits separated by at least 1 week. The same mandibular molar area was anesthetized at each visit; all injections were performed by a single operator (IPC). A dental aspirating syringe fitted with a 0.40×35 mm needle (Ultra Safety Plus XL; Deproco, Maidstone, UK) was used to deposit 4% articaine with 1:100,000 epinephrine (Septanest 1:100,000; Deproco, Maidstone, UK) at a rate of 0.9 mL per 15 seconds. Buccal injections were administered first at each visit, with a total needle penetration time of 30 seconds (1.8 mL over 30 seconds or 15 seconds penetration with no administration followed by 0.9 mL over 15 seconds). On the lingual side, the 0.9 mL of solution was injected over 15 seconds, and the simulated lingual injection was a 15-second needle penetration only to blind the subject to the method of infiltration. In the IANB investigation (reported previously, 23), 2 mL of 2% lidocaine with 1:80,000 epinephrine (Lignospan Special; Dentsply, Weybridge, UK) was administered over 1 minute using the direct or Halstead approach by the same operator who administered the infiltrations described earlier.

The investigator of anesthetic efficacy (MDK) was blinded to the infiltration method used at each visit. Pulpal anesthesia was determined by using an electronic pulp tester (Analytic Technology, Redmond, WA). The pulp tester was set to deliver a 0 to 80 digital reading on a rate setting of five, corresponding to a nonlinear increasing voltage, zero to maximum, over 30 seconds. Calibration of the pulp tester showed a maximum voltage of 270 V at an output impedance of 140 K ohms. The appropriate mandibular first molar was tested twice before injection, and the mean of these two readings was considered as baseline. Pulp testing was then repeated once every 2 minutes after injection for 30 minutes giving a total of 15 time points. In order to test the reliability of the pulp tester, a nonanesthetized canine tooth on the contralateral side of the mandible was tested at each time point. The canine tooth was chosen as a control because of the ease of access and moisture control in addition to the possibility of the contralateral molar being compromised by disease. The number of occasions (out of the 15 time points) on which there was no response to maximum stimulation was determined and the responses for the two treatments were compared across the 31 subjects.

For the concurrent IANB investigation, pulp testing was performed under identical conditions by the same investigator (MDK), with a variation only in the time interval used (23). Testing was carried out every 2 minutes for 10 minutes and then at 5-minute intervals to 45 minutes, giving seven corresponding time points between 0 and 30 minutes in the two studies.

The criterion for successful anesthesia after infiltration was no response to the maximum stimulation, a reading of 80, on two or more consecutive measurements (4). The onset of first molar pulp anesthesia was taken as the time from the beginning of at least two consecutive

maximum readings without sensation. The duration of anesthesia was similarly taken as the time from the beginning of at least two consecutive maximum readings without sensation until the onset of more than two responses at less than maximum stimulation or the end of the 30 minutes of the trial, whichever was sooner. In addition to objective assessment of pulpal anesthesia, volunteers were asked to report to the investigator when sensation in the molar teeth, lower lip, and floor of mouth/tongue felt different or "numb." Time of reported onset and presence of tooth, labial, and lingual soft-tissue anesthesia at each pulp testing time point were recorded.

Injection discomfort for each infiltration, dummy lingual infiltration, and the IANB was self-recorded by subjects on 100-mm visual analogue scales (VAS) with endpoints "no pain" (0 mm) and "unbearable pain" (100 mm).

Data were analyzed by Pearson Chi-square, Fisher's exact test, McNemar test and Student's *t* tests, performed using a statistical analysis package (SPSS 14.0, SPSS limited, Chicago, USA).

Results

Buccal versus Buccal Plus Lingual Infiltration

The study was performed over a 6-month period. Thirty-one healthy volunteers, recruited predominantly from the local university (including dental students) population, participated in the study, with no exclusions; 16 women (52%) and 15 men (48%), with a mean age of 23 years (range, 20-30 years) were included. Eighteen subjects received buccal and lingual infiltration with articaine at the first visit, 13 receiving buccal and simulated injections initially. The mean time between interventions was 41 days (range, 7-105). All recruited participants received the intended treatment and completed the trial; no protocol deviation was noted, and no adverse events were reported.

The number of episodes of no sensation on maximal stimulation (80) in first molars at each time point after injection was not significantly different ($p = 0.58$) after combined buccal and lingual infiltrations compared with buccal infiltration alone, with 242 episodes and 236 episodes, respectively (Fig. 1). Twenty (64.5%) volunteers experienced anesthetic success (two or more consecutive episodes of maximal stimulation without sensation) after articaine buccal infiltration compared with 21 (67.7%) after the combined buccal and lingual infiltration. This difference was not significant ($p = 1.0$).

The mean onset of first molar pulpal anesthesia was 6.5 minutes (SD, 5.5 minutes) after buccal and 7.5 minutes (SD, 6.0 minutes) after buccal plus lingual infiltrations. The difference was not significant ($t = 0.57$, $p = 0.57$).

The maximum duration of anesthesia possible in this trial was 28 minutes. Six subjects achieved 28 minutes of continuous anesthesia after buccal infiltration and four subjects after buccal plus lingual infiltration. The mean duration of successful pulpal anesthesia was 21.6 minutes (SD, 7.9 minutes) after buccal and 20.5 minutes (SD, 7.8 minutes) after buccal plus lingual infiltrations. The difference was not significant ($t = 0.46$, $p = 0.65$).

All volunteers reported lip numbness after buccal and buccal plus lingual infiltrations, with a mean onset of 51.2 seconds (SD, 26.6 seconds) and 61.0s (SD 51.1 seconds), respectively. The difference was not significant ($t = 1.1$, $p = 0.30$). Lingual mucosa numbness was reported by 7 (22.6%) subjects after buccal and 21 (67.7%) after combined buccal and lingual infiltration. This difference was significant ($p < 0.001$). Twenty-four (77.4%) volunteers reported subjective tooth numbness after buccal infiltration alone and 27 (87.1%) after buccal and lingual infiltration. The difference was not significant ($p = 0.38$).

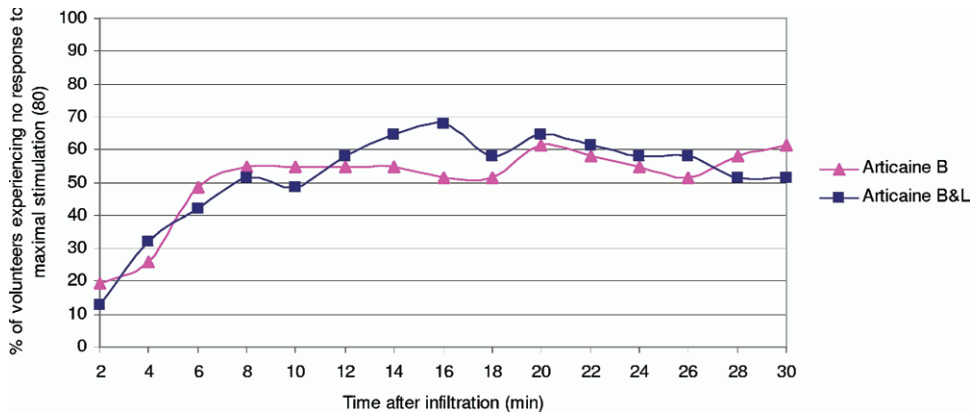


Figure 1. The percentage of volunteers reporting no sensation on maximal stimulation (80) in first mandibular molars after articaïne buccal (B) versus articaïne buccal and lingual (B&L) infiltration.

Lingual penetration and lingual injection showed similar discomfort over the two visits, with mean VAS scores of 19.7 mm (range, 0-51) and 21.5 mm (range, 1-78), respectively ($t = 0.68, p = 0.50$). Articaïne buccal infiltration with a volume of 1.8 mL (mean, 20.9 mm; range, 0-73) was significantly more uncomfortable than 0.9 mL of infiltration (mean, 15.2 mm; range, 0-54; $t = 2.5, p = 0.017$).

Articaïne Buccal Infiltration versus Lidocaine IANB

Twenty-seven of the volunteers enrolled in this current investigation were also participating in a concurrent study investigating the efficacy of inferior alveolar nerve blocks with 2% lidocaine 1:100,000 epinephrine (23). The study was performed under identical randomized, double-blinded, controlled conditions by the same investigators. Data used in this comparison related to delivery of an IANB at the rate of 2.0 mL over 1 minute. Seven of the time points up to 30 minutes postinjection corresponded between the present and the IANB investigations. The cohort involved in both trials consisted of 12 men (44.4%) and 15 women (55.6%), with a mean age of 22.8 years (range, 20-30 years). Of these 27 volunteers, 17 received the IANB before buccal infiltrations.

Comparing the present buccal infiltration data with the IANB data, of the 27 volunteers, 19 (70.4%) experienced anesthetic success after articaïne buccal infiltration compared with 15 (55.6%) after the IANB ($p = 0.39$), with a mean onset of pulpal anesthesia of 6.8 minutes (SD, 6.2 minutes) and 5.9 minutes (SD, 4.4 minutes) respectively (independent samples test: $t = 0.54, p = 0.60$). The number of episodes of no

sensation on maximal (80 μA) stimulation in first molars at each time point after injection (Fig. 2) was greater after the articaïne buccal infiltration (96 episodes) compared with IANB (80 episodes); this was not statistically significant ($p = 0.097$).

Subjective lip numbness was reported in all but one intervention (an IANB). The onset of lip numbness in the remaining volunteers ranged between 20 and 115 seconds (mean, 49.9 seconds; SD, 21.1 seconds) after articaïne buccal infiltration alone and between 6 and 730 seconds after IANB injection (mean, 97.2 seconds; SD, 165.9 seconds). This difference was not significant ($t = 1.5, p = 0.14$). All volunteers reported tongue numbness after IANB injection, but only six (22.2%) reported lingual mucosa numbness after articaïne buccal infiltration. This difference was significant ($p < 0.001$). Subjective tooth numbness was significantly more common after IANB compared to articaïne buccal infiltration (27 vs 20 cases, respectively; $p = 0.005$).

No significant difference was noted in injection discomfort between articaïne buccal infiltration (mean VAS 22.4 mm, SD 18.4 mm) and lidocaine IANB (20.7 mm, SD 17.4 mm) in the 27 subjects ($t = 0.41, p = 0.69$).

Discussion

The use of electrical stimulation is considered a safe and precise method to evaluate pulpal anesthesia in vital asymptomatic teeth (24, 25). The absence of perception to the maximum output of the pulp

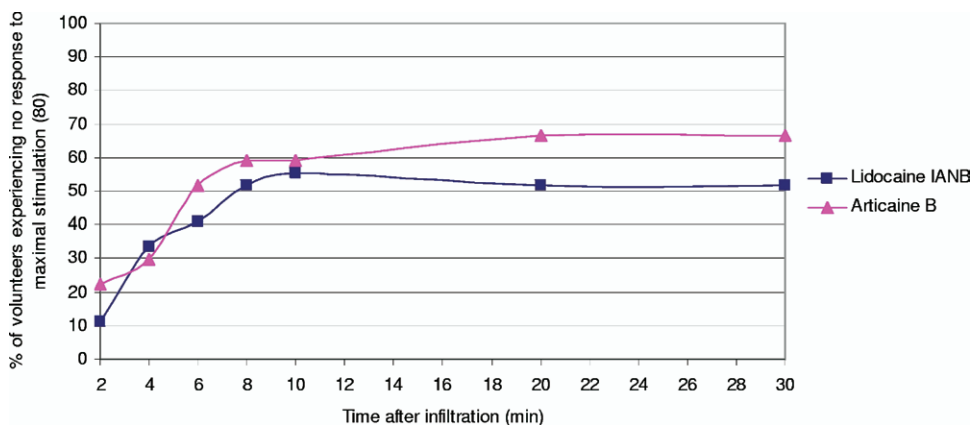


Figure 2. The percentage of volunteers reporting no sensation on maximal stimulation (80) in first mandibular molars after articaïne buccal infiltration (B) versus lidocaine IANB injection.

tester (80 reading) has been widely used as a criterion for pulpal anesthesia (4, 10, 26, 27).

The results of the present study show infiltration anesthesia efficacy in the mandibular molar region with 4% articaine and epinephrine (1:100,000) in adults of approximately 65%. This result is similar to that reported by Haas et al (28) but lower than that noted by Robertson et al (5). Buccal infiltration with articaine has been shown to achieve a higher success rate in mandibular molar anesthesia than that reported with a buccal infiltration of 2% lidocaine with epinephrine (1:100,000) (4, 5). This increase in efficacy may be the result of a concentration effect (1) or greater diffusion of articaine (29, 30).

The results of this investigation show that no advantage in anesthetic success was obtained from dividing the administration of a dose of articaine between buccal and lingual infiltrations in the molar region of the mandible compared with buccal infiltration alone. This is in contrast to the mandibular incisor region in which the combination of buccal plus lingual infiltration has been shown to be more effective than the same dose given buccally (22). This difference may be the result of the involvement of accessory nerves on the lingual side of the mandible (eg, in the innervation of the anterior but not the posterior teeth) (31). The effect is unlikely to relate to bone thickness/density and access to IAN; although the cortical plate may be around 0.5 mm thicker on the lingual than the buccal aspect (32), the inferior alveolar canal is predominantly toward the lingual cortex (33).

To eliminate a dose effect, the overall volume injected either on the buccal or in the combined buccal and lingual administration was kept constant. The minimum buccal articaine dose required to produce successful pulpal anesthesia has not been investigated in this trial. The role of lingual infiltration may become relevant if the buccal dose is reduced below a "critical" threshold.

Previous studies have reported the peak anesthetic effect of infiltration anesthesia in the anterior mandible in the region of 8 to 10 minutes (22, 34). In the current study, the anesthetic effect for the mandibular first molar peaked 16 to 20 minutes after infiltrations, the lag possibly resulting from a greater physical diffusion barrier. In comparison, the peak for the IANB occurred earlier (10 minutes) but was lower (Fig. 2), although neither of these differences was significant.

In the present study, approximately 70% of the volunteers who achieved successful first molar pulpal anesthesia after articaine buccal plus lingual infiltrations did so within 10 minutes. The corresponding figures for buccal infiltration alone and IANB were 85% and 93%, respectively. No significant difference was noted between the techniques with regard to overall mean onset; these were 7.5 minutes for articaine buccal plus lingual infiltration, 6.5 minutes for articaine buccal infiltration only, and 5.9 minutes for IANB with lidocaine. These results suggest that a period of 6 to 10 minutes should elapse before testing for pulpal anesthesia or indeed before commencing a potentially painful procedure such as accessing the dental pulp.

Reporting of subjective lip numbness was similar after both infiltration techniques and IANB. An earlier mean onset time for lip numbness was reported with the larger dose of articaine buccal infiltration (1.8 mL); however, this was not statistically significant. Not surprisingly, the reporting of subjective numbness of the lingual mucosa in the infiltration study was more common after a lingual injection (67%), with seven subjects reporting lingual mucosa numbness after buccal infiltration alone. All volunteers reported subjective lingual numbness after IANB. Approximately 77% of subjects reported first molar tooth numbness after articaine buccal infiltration compared with 87% after articaine buccal plus lingual infiltrations with no significant differences between the two techniques. Subjective tooth numbness was significantly more common after IANB than articaine buccal infiltration. Reporting of lingual anesthesia after lingual infiltration may have been expected to be

more common than recorded in the present study. This may reflect the subjectivity of self-reporting and may have been different if objective measurement was undertaken. It is possible that tooth numbness is more readily perceived (subjects being seen to tap their teeth together to assess this). In addition, anesthesia of the teeth may "confuse" assessment of lingual anesthesia, as seen by the higher incidence of reported subjective tooth numbness after buccal plus lingual infiltration. This may warrant further investigation.

In the present study, lingual injection and lingual needle penetration produced similar discomfort over the two visits. This is in contrast to the results of Meechan et al (31) who reported lingual injection was more uncomfortable than needle penetration with 2% lidocaine local anesthetic in the same region. This may be because buccal infiltration was always administered first and may diffuse deeply into the bone (29, 30), resulting in the lingual soft-tissue anesthesia as described earlier. Similarly, one study showed that extraction of teeth in the maxilla was possible with articaine buccal infiltration only (35), additional evidence of transalveolar diffusion. Other studies however have failed to show such diffusion (28).

The present results show that the discomfort of infiltrating 4% articaine with 1:100,000 epinephrine in the mandibular buccal sulcus increases with the volume of anesthetic solution. This is in contrast to data reported after lidocaine infiltration (31) and may suggest a concentration effect as opposed to a simple volume consequence. Because low-volume lingual infiltration discomfort is akin to large volume buccal infiltration, division of the dose between the two sites affords no benefit to the patient in terms of discomfort. Nevertheless, the mean scores reported by the volunteers for all routes of administration of local anesthetic in the first molar region represent mild discomfort only (36).

The results presented here provide evidence to support the view that a mandibular infiltration with 4% articaine with epinephrine can be as effective as an inferior alveolar nerve block over the 30-minute study period (13). The success rates reported in the present and other trials of inferior alveolar nerve block efficacy (6–13) may appear low compared with those that would be apparent in clinical practice; however, the criteria for success using an electronic pulp tester in such trials is more stringent than subjective ratings (10). Such profound anesthesia may not be necessary to perform many less invasive clinical procedures (11), and when profound pulpal anesthesia is required, clinical testing with an electronic pulp tester would be indicated.

Although buccal infiltration with articaine is not without disadvantages, avoidance of inferior alveolar nerve blocks for restorative dentistry has a number of advantages. Infiltration produces less unwanted soft-tissue anesthesia for minimally invasive procedures, a supplementary injection being required for lingual anesthesia. Similarly, a shorter duration of action (4, 5, 7, 8) may or may not be an advantage of articaine buccal infiltration over lidocaine inferior alveolar nerve block depending on the procedure undertaken and a repeat infiltration may be required. Trismus and nonsurgical paresthesia as a result of damage from the needle to the inferior alveolar or lingual nerves is avoided (37). In addition, infiltration techniques may be preferred in certain patient groups such as those suffering from hemophilia in order to reduce the chances of dangerous hemorrhage. Infiltration is a simpler technique than other alternatives to mandibular blocks such as intraosseous and intraligamentary injections. Infiltration anesthesia does not require the specialized equipment needed for intraosseous delivery, is less destructive to the periodontium, and avoids the large bacteremia that follows intraligamentary injections (38, 39). Articaine benefits from a shorter plasma half-life compared with other amide local anesthetics (29, 30) and when given as an infiltration should circumvent the

possible concentration-related neurotoxicity associated with regional block methods when 4% solutions are used (40, 41).

Conclusions

Buccal and buccal plus lingual infiltrations of articaine with epinephrine did not differ in their efficacy in obtaining pulpal anesthesia for mandibular permanent first molars. Anesthetic efficacy of 4% articaine with epinephrine infiltrations for first molar pulp anesthesia was similar to that of an IANB using 2% lidocaine with epinephrine over 30 minutes. The discomfort of buccal infiltration with articaine was dependent on the volume injected and similar to that of an IANB.

References

1. Malamed SF, Gagnon S, Leblanc D. Efficacy of articaine: a new amide local anesthetic. *J Am Dent Assoc* 2000;131:635–42.
2. Malamed SF, Gagnon S, Leblanc D. Articaine hydrochloride: a study of the safety of a new amide local anesthetic. *J Am Dent Assoc* 2001;132:177–85.
3. Hersh EV, Giannakopoulos H, Levin LM, et al. The pharmacokinetics and cardiovascular effects of high-dose articaine with 1:100,000 and 1:200,000 epinephrine. *J Am Dent Assoc* 2006;137:1562–71.
4. Kanaa MD, Whitworth JM, Corbett IP, Meechan JG. Articaine and lidocaine mandibular buccal infiltration anesthesia: a prospective randomized double-blind cross-over study. *J Endod* 2006;32:296–8.
5. Robertson D, Nusstein J, Reader A, Beck M, McCartney M. The anesthetic efficacy of articaine in buccal infiltration of mandibular posterior teeth. *J Am Dent Assoc* 2007;138:1104–12.
6. Childers M, Reader A, Nist R, Beck M, Meyers WJ. Anesthetic efficacy of the periodontal ligament injection after an inferior alveolar nerve block. *J Endod* 1996;22:317–20.
7. Dagher FB, Yared GM, Machtou P. An evaluation of 2% lidocaine with different concentrations of epinephrine for inferior alveolar nerve block. *J Endod* 1997;23:78–80.
8. Goodman A, Reader A, Nusstein J, Beck M, Weaver J. Anesthetic efficacy of lidocaine/meperidine for inferior alveolar nerve blocks. *Anesth Prog* 2006;53:131–39.
9. Mikesell P, Nusstein J, Reader A, Beck M, Weaver J. A comparison of articaine and lidocaine for inferior alveolar nerve blocks. *J Endod* 2005;31:265–70.
10. McLean C, Reader A, Beck M, Meyers WJ. An evaluation of 4% prilocaine and 3% mepivacaine compared with 2% lidocaine (1:100,000 epinephrine) for inferior alveolar nerve block. *J Endod* 1993;19:146–50.
11. Moore PA, Boynes SG, Hersh EV, et al. The anesthetic efficacy of 4 percent articaine 1:200,000 epinephrine: two controlled clinical trials. *J Am Dent Assoc* 2006;137:1572–81.
12. Nist RA, Reader A, Beck M, Meyers WJ. An evaluation of the incisive nerve block and combination inferior alveolar and incisive nerve blocks in mandibular anesthesia. *J Endod* 1992;18:455–9.
13. Jung IY, Kim JH, Kim ES, Lee CY, Lee SJ. An evaluation of buccal infiltrations and inferior alveolar blocks in pulpal anesthesia for mandibular first molars. *J Endod* 2008;34:11–13.
14. Pogrel MA, Smith R, Ahani R. Innervation of the mandibular incisors by the mental nerve. *J Oral Maxillofac Surg* 1997;55:961–3.
15. Meechan JG. Why does local anaesthesia not work every time? *Dent Update* 2005;32:66–8, 70–2.
16. Yonchak T, Reader A, Beck M, Meyers WJ. Anesthetic efficacy of unilateral and bilateral inferior alveolar nerve blocks to determine cross innervation in anterior teeth. *Oral Surg Oral Med Oral Pathol Endod* 2001;92:132–5.
17. Meechan JG. Supplementary routes to local anaesthesia. *Int Endod J* 2002;35:885–96.
18. Bigby J, Reader A, Nusstein J, Beck M, Weaver J. Articaine for supplemental intraosseous anesthesia in patients with irreversible pulpitis. *J Endod* 2006;32:1044–47.

19. Nusstein J, Reader A, Nist R, Beck M, Meyers WJ. Anesthetic efficacy of the supplemental intraosseous injection of 2% lidocaine with 1:100,000 epinephrine in irreversible pulpitis. *J Endod* 1998;24:487–91.
20. Parente SA, Anderson RW, Herman WW, Kimbrough WF, Weller RN. Anesthetic efficacy of the supplemental intraosseous injection for teeth with irreversible pulpitis. *J Endod* 1998;24:826–8.
21. Rosenberg PA, Amin KG, Zibari Y, Lin LM. Comparison of 4% articaine with 1:100,000 epinephrine and 2% lidocaine with 1:100,000 epinephrine when used as a supplemental anesthetic. *J Endod* 2007;33:403–5.
22. Meechan JG, Ledvinka JI. Pulpal anaesthesia for mandibular central incisor teeth: a comparison of infiltration and intraligamentary injections. *Int Endod J* 2002;35:629–34.
23. Kanaa MD, Meechan JG, Corbett IP, Whitworth JM. Speed of injection influences efficacy of inferior alveolar nerve blocks: a double-blind randomized controlled trial in volunteers. *J Endod* 2006;32:919–23.
24. Dreven IJ, Reader A, Beck M, Meyers WJ, Weaver J. An evaluation of an electric pulp tester as a measure of analgesia in human vital teeth. *J Endod* 1987;13:233–8.
25. Certosimo AJ, Archer RD. A clinical evaluation of the electric pulp tester as an indicator of local anesthesia. *Oper Dent* 1996;21:25–30.
26. Vreeland DL, Reader A, Beck M, Meyers W, Weaver J. An evaluation of volumes and concentrations of lidocaine in human inferior alveolar nerve block. *J Endod* 1989;15:6–12.
27. Hinkley SA, Reader A, Beck M, Meyers WJ. An evaluation of 4% prilocaine with 1:200,000 epinephrine and 2% mepivacaine with 1:20,000 levonordefrin compared with 2% lidocaine with 1:100,000 epinephrine for inferior alveolar nerve block. *Anesth Prog* 1991;38:84–9.
28. Haas DA, Harper DG, Saso MA, Young ER. Comparison of articaine and prilocaine anesthesia by infiltration in maxillary and mandibular arches. *Anesth Prog* 1990;37:230–7.
29. Oertel R, Rahn R, Kirch, W. Clinical pharmacokinetics of articaine. *Clin Pharmacokinetics* 1997;33:417–25.
30. Isen DA. Articaine: pharmacology and clinical use of a recently approved local anesthetic. *Dent Today* 2000;19:72–7.
31. Meechan JG, Kanaa MD, Corbett IP, Steen IN, Whitworth JM. Pulpal anaesthesia for mandibular permanent first molar teeth: a double-blind randomized cross-over trial comparing buccal and buccal plus lingual infiltration injections in volunteers. *Int Endod J* 2006;39:764–9.
32. Katranji A, Misch K, Wang HL. Cortical bone thickness in dentate and edentulous human cadavers. *J Periodont* 2007;78:874–8.
33. Ylikontiola L, Moberg K, Huuonen S, Oikarinen K. Comparison of three radiographic methods used to locate the mandibular canal in the buccolingual direction before sagittal split osteotomy. *Oral Surg Oral Med Oral Pathol Endod* 2002;93:736–42.
34. Yonchak T, Reader A, Beck M, Clark K, Meyers WJ. Anesthetic efficacy of infiltrations in mandibular anterior teeth. *Anesth Prog* 2001;48:55–60.
35. Uckan S, Dayangac E, Araz K. Is permanent maxillary tooth removal without palatal injection possible? *Oral Surg Oral Med Oral Pathol Endod* 2006;102:733–5.
36. Collins SL, Moore RA, McQuay HJ. The visual analogue pain intensity scale: what is moderate pain in millimetres? *Pain* 1997;72:95–7.
37. Harn SD, Durham TM. Incidence of lingual nerve trauma and post-injection complications in conventional mandibular block anesthesia. *J Am Dent Assoc* 1990;121:519–23.
38. Meechan JG. Intraligamentary anaesthesia. *J Dent* 1992;20:325–32.
39. Roberts GJ, Holzel HS, Sury MR, Simmons NA, Gardner P, Longhurst P. Dental bacteremia in children. *Pediatr Cardiol* 1997;18:24–7.
40. Haas DA, Lennon D. A 21 year retrospective study of reports of paresthesia following local anesthetic administration. *J Can Dent Assoc* 1995;61:319–20, 323–6, 329–30.
41. Hillerup S, Jensen R. Nerve injury caused by mandibular block analgesia. *Int J Oral Maxillofac Surg* 2006;35:437–43.