

# Laser-Assisted Oral Surgery with Three Wavelengths: Erbium:YAG, Carbon Dioxide and Diode

AVI REYHANIAN, D.D.S. *Natanya, Israel*



## Lasers and Implants - Thou Shalt and Shalt Not Do!

### INTRODUCTION

The spectrum of available clinical applications for laser-assisted dentistry is growing rapidly. The greater number of applications is for oral surgery.

My practice has been employing three laser wavelengths since 2001:

- 830 nm - Diode
- 2940 nm - Erbium:YAG
- 10600 nm - CO<sub>2</sub>

Thermal laser wavelengths used in dentistry and oral surgery are located in the infrared zone of the electromagnetic spectrum, considered to be extremely safe.

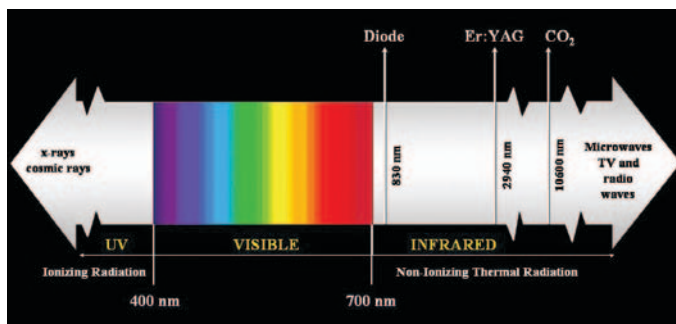


Figure 1. Electromagnetic Spectrum (in Nanometers)

Most of the procedures performed at my practice are in the realm of surgery and they are all performed with the lasers: periodontal surgery is performed with the Erbium laser, without the assistance of rotary equipment, scalpels or other hand tools. Apicectomy and bone manipulation - bone smoothing, bone harvesting, bone vaporization and guided bone regeneration (GBR).

How far can we advance with this technology? Where is the line between reality and fantasy - at times it is very clear, other times it can barely be seen and yet at other times the line disappears altogether. What is the stage where I lay down the laser's handpiece and retreat to the conventional system and rotary equipment?

Today we can observe an inordinate lack of knowledge and clarity concerning the clinical uses of the laser and with many doctors in the field reality does indeed mix with fantasy. There are four main reasons for this:

- Sharp, fast-talking sales representatives making promises no one can keep.

- Adequate training for new users is not readily available.
- The science of lasers is not being allowed outside of the academic world and is only being spread by us, the laser users in the field. This is a source of confusion, a lack of focus and uniformity in clinical applications (at times academicians will consult with me or visit my practice in order to get "up close and personal" with a laser).
- Prohibitive costs of the laser systems and their maintenance.

In this paper I intend to focus on the use of lasers in the field of implants. Principally, the only laser that may be used on hard oral tissue is the Erbium:YAG (2940 nm), though the same laser may also be used on soft tissue. For soft tissue vaporization I use the CO<sub>2</sub> laser, and for soft tissue with aesthetic value I use the diode laser.

### WHAT CAN THESE LASERS DO FOR IMPLANTS?

- Incision for flap lifting, if it is a crestal incision, intra-sulcular or vertical incision for release with the Erbium laser.
- Vaporization of granulated tissue (if any exists) with the Erbium laser.
- Marking the future location of the implant and its angle, where the use of the laser is only cortical bone in non-contact mode. **Be very clear: I do not drill the entire length of the implant with the laser.**
- Implant exposure may be performed with all three laser wavelengths.

### COMPLICATIONS INVOLVING IMPLANTS AND LASERS

The most common complications can be divided into 2 groups:

1. *Intra-operative complications:* bleeding, nerve injury, mandibular fracture, implants, displacement (sinus, mandibular canal nasal fosse), accidental bone perforation, incomplete flap closure.
2. *Post-operative complications:* peri-implant mucositis, peri-implantitis, surgical wound dehiscence, lesions to adjacent teeth, incomplete osteointegration.

The most prevalent reasons for complications and failures are: improper patient selection; an incorrectly performed surgical procedure; inadequate oral hygiene.

Infections are divided into two categories:

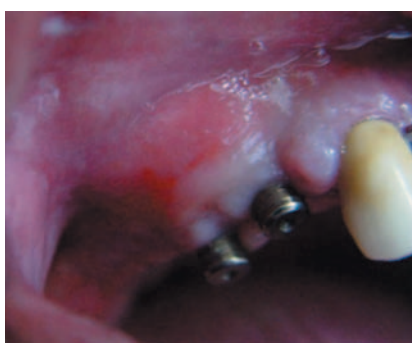**Mucositis** (like Gingivitis) - a reversible infection focused in the soft tissue around the implants. Treatment involves improved oral hygiene, mechanical sterilization of the pockets and use of antimicrobial agents, such as Chlorahexidin. At my practice we sterilize the pockets with the diode or CO<sub>2</sub> laser at very low power levels, and if there is any granulated tissue it gets vaporized with the CO<sub>2</sub> laser.

**Peri-implantitis** (like Periodontitis) - an inflammatory process that affects the soft and hard tissues around the implant and involves bone loss (*Albrektson, Isidore, 1994*). Treatment involves a combined application of local and systemic antibiotics, and mechanical & chemical cleaning of the damaged implant's surface with citric acid and tetracycline solution. I prefer not to use chemicals, but rather lift a flap with the Erbium laser, vaporize any existing granulated tissue until I have a clean bone surface, apply the laser to the surface of the damaged implant and, if necessary, perform GBR doing the decortication with the Erbium laser, and without any rotary tools.


An article published by Aoki *et al* in February 2001 states that "...the Erbium has the capability of removing plaque from the surfaces of implants without any morphological changes to the surfaces...". From an article by Kreisler *et al* (Nov. 2001) - "...even at low levels the Erbium has a bacteriocidal capability on the surfaces of implants...".

## THE ADVANTAGES OF LASERS IN THE FIELD OF IMPLANTS

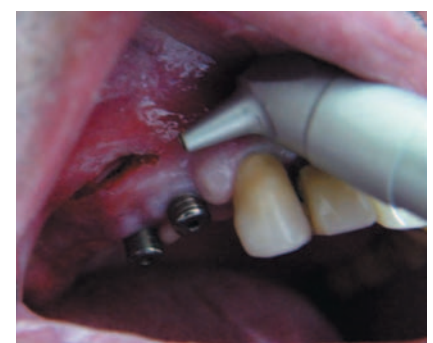- Safe for the surrounding tissue
- Surgical site sterilization - the laser is bacteriocidal
- Saves time
- Less bleeding during the procedure
- Post-operative - less swelling and less pain due to the laser's ability to cauterize small blood vessels,



**Figure 2.** Swelling appears three months after implants insertion



**Figure 3.** Area of radiolucency surrounding the two implants



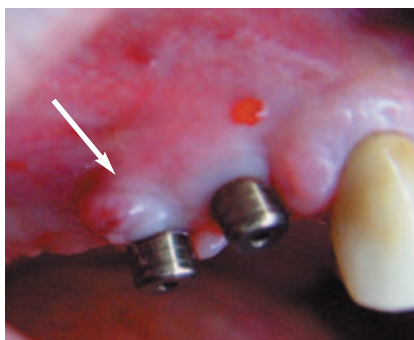
**Figure 4.** Drainage incision with the CO<sub>2</sub> laser

lymphatic vessels and exposed nerve endings

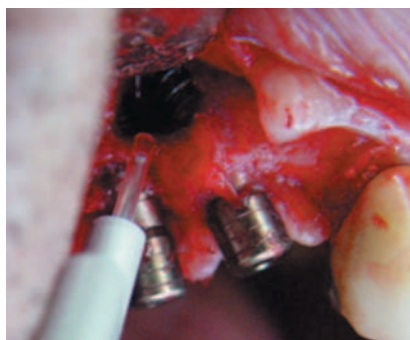
- No rotary tool vibrations
- No smear layer

I have been using Alpha-Bio implants for ten years now, and my success rate is between 94-97 percent. 3-6 percent involve complications and failures, one of which is described as follows:

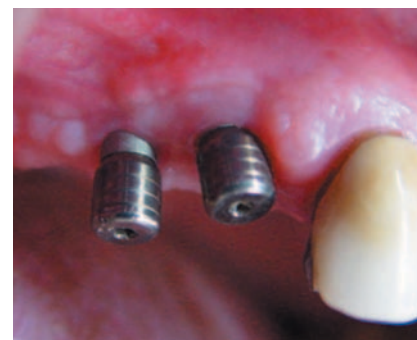A 53 year old patient with an unremarkable medical history presented for the purpose of a gradual restoration, during which three implants were inserted into the upper-right quadrant: a 2.9/16 implant at the location of tooth 12, a 3.75/16 implant at the location of tooth 14 and a 3.75/11.5 implant at the location of tooth 15. The patient returned three months later with buccal swelling around the implants at locations 14 & 15. An X-ray showed a process of radiolucency surrounding the two implants in the apical areas. A drainage incision was made, under anesthesia, with the CO<sub>2</sub> laser. The patient departed and returned two months later with fistula. An intrasulcular incision was made with the Erbium laser, using a 200 micron tip in contact mode, then a vertical incision for release was performed at the distal side of 15 and a buccal flap was lifted. The infection had engulfed both implants with massive loss of bone and a great deal of granulated tissue (a note must be made here that the implants were stable and with no evident migration). The granulated tissue was ablated with the Erbium laser and afterwards low-power levels of laser energy were aimed at the surfaces of the implants and exposed screws. The bone defect was filled with Bio-oss bone substitute, covered with an absorbent, bi-layer membrane called Bio-Gide (manufactured by Geistlich), made permanent with apical porous pins. Conversely the coronal was set into place using therapeutic screws. The fistula cleared, and a photographed follow-up after two years showed the affected area filling with no areas of radiolucency - remission of the symptoms. The photos presented in Figures 2 through 10 describe the various stages of this case study.



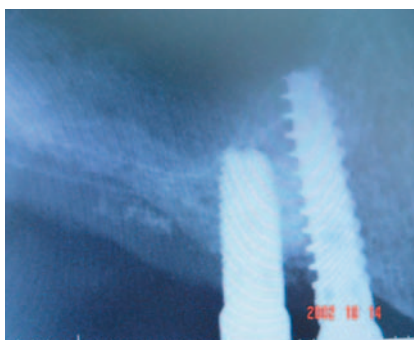**Figure 5.** Two months later the patient presents with fistula



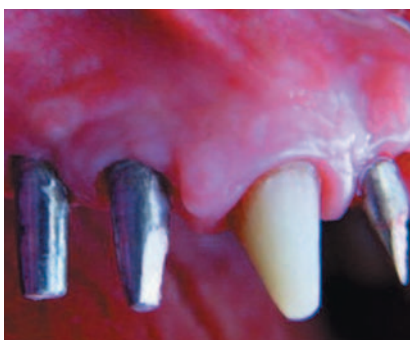**Figure 6.** Lifting a flap and cleaning the infection with the Erbium laser



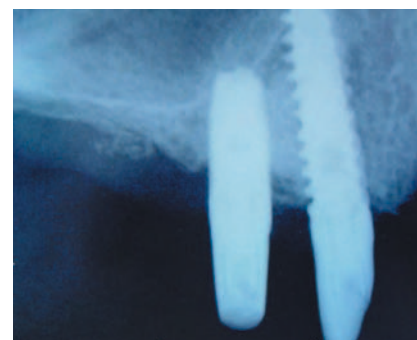**Figure 7.** Two months follow-up



**Figure 8.** X-Ray view at two months follow-up



**Figure 9.** Two years follow-up



**Figure 10.** X-Ray view at two years follow-up

## CONCLUSION

It is necessary to point out the important issues that require attention when applying the laser to bone tissue:

- Constant hand motion during laser emission - do not apply the laser beam to any one spot longer than necessary. The systems developed for dentistry are thermal lasers, and the interaction between the laser and target tissue raises the temperature of the tissue. Studies have proven that the temperature developed by a laser beam is no higher than that developed by rotary tools.
- As a cooling liquid I use saline solution as opposed to distilled water, because I want to provide the bone tissue with an isotonic environment.
- The laser energy applied to bone tissue should not exceed 500 milliJoules.
- The laser application to bone tissue should always be performed in non-contact mode, with a distance of 1-2 mm between the handpiece's tip and the tissue.

## Periodontal Surgery with an Erbium:YAG Laser (2940nm)

### PERIODONTAL DISEASE

Periodontal disease is one of the most widespread maladies of the human race, and in its chronic state it is an infectious disease as well. Treating the disease is done locally and the main premises of the treatment regimen are:

- Removal of known causes
- Prevention of reoccurrences
- Treating the defects that have developed
- Repairing the damage, when and where possible

Since the disease is both chronic and destructive, the sooner it is treated the better the prognosis is that we'll be faced with. The damage caused is reversible when limited to soft tissue areas (gingivitis), but as soon as supportive tissues are attacked the situation becomes non-reversible (Periodontitis) - treatment will stop the disease but will not regenerate damaged tissue. The guiding line is to preserve the natural teeth. There are many variables that should be considered before deciding on surgically reducing the depths of the pockets, and how this will benefit the patient's final hygienic situation.

### PERIODONTAL SURGERY WITH AN ERBIUM LASER

Using conventional methods, an incision is made with a scalpel to lift the flap; granulated tissue is removed with a curette; shaping and remodeling are performed with rotary equipment and assorted chisels. In my practice I utilize an Erbium laser system rather than a scalpel or curettes. The incision is made by laser with a 200 micron tip, in contact mode at intrasulcular depth. After the flap is lifted the granulated tissue is removed by ablation and vaporization, using the laser with a 1300 micron tip - non-contact mode - at a distance of 1-1.5 mm from the target tissue. In those narrow embrasures where the tip is too wide, it may be replaced with a narrower conical tip (400-800 microns). Be aware: the laser fires from the end of the tip and not from the sides. After ablating the soft tissue I move on to the hard tissue (bone) for shaping and remodeling.

Erbium is the only laser available today that can treat both soft and hard tissue, since it the only one that delivers a cooling water spray. Studies have proven that the laser does not raise the temperature of the surgical site by more than 2.5°C. In a study published by Yuichi Kimura *et al* (*J. Periodontol.*, March 2001) he states that there is no thermal necrosis, no melting and no change in the ratio between calcium and phosphor, the Erbium laser may be used as a treatment alternative when working with bone.

Many studies have shown us that Erbium laser energy

applied to bone releases growth factors that enhances regeneration of the bone. Implants inserted into holes drilled with the Erbium laser exhibit greater contact with the bone than those prepared by conventional methods.

### THE ADVANTAGES OF LASERS IN THE FIELD OF PERIODONTAL SURGERY

- Less bleeding during the procedure
- Surgical site sterilization (I do not dispense antibiotics after surgery)
- Less post-operative swelling and pain
- More effective bone cleaning
- Faster completion of the surgical procedure
- No rotary tool vibrations - patient comfort
- Working in non-contact mode enables constant rinsing of the bone

### SURGICAL CASE STUDY

A generally healthy, 55-year old male presented with the main complaints of halitosis and recurrent bleeding. A clinical examination showed bleeding periodontal pockets with depths between 5-7 mm, stable teeth with no mobility. An X-ray revealed horizontal absorption of the supporting bone with a 7mm pocket in the mesial of tooth # 15. A preliminary prep was performed which included plaque removal, planning and smoothing of the roots, as well as patient instruction for aggressive oral hygiene. Six week later the situation was re-evaluated: no significant reduction in the depths of the pockets was observed. A surgical procedure was decided upon which involved lifting a flap in order to treat the supporting bone, employing a technique of implanting filling agents that enhance tissue renewal in a guided manner.

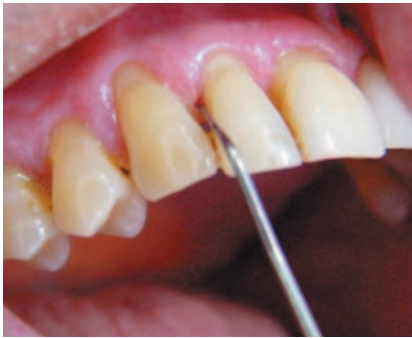The palatal and buccal incision made was intrasulcular, buccal and was performed with a 200 micron tip. Ablation was performed with a 1300 micron tip (non-contact), combined with reshaping of the bone tissue. The vertical pocket in the mesial of tooth # 15 was filled with Bio-oss bone substitute, covered with Bio-Gide absorbent, bi-layer membrane.

The patient was not prescribed antibiotics; he returned the following day stating that he was no longer suffering pain, and no swelling was observed. He is now 15 months post-surgery, coming in once every three months for plaque removal and a checkup. The depths of the pockets do not exceed 3mm.

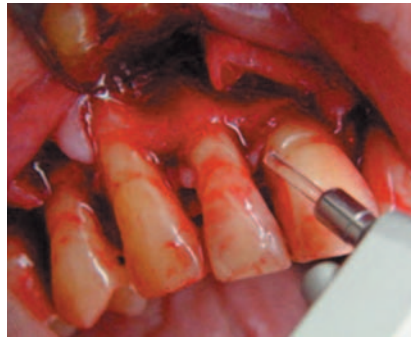To-date I have hundreds of completed cases of patients who have had Erbium laser-assisted periodontal surgery coming in for regular follow-ups.

The photos presented in Figures 11 through 17 describe the various stages of this case study. Figure 18 shows the angled delivery handpiece of an Erbium laser system,

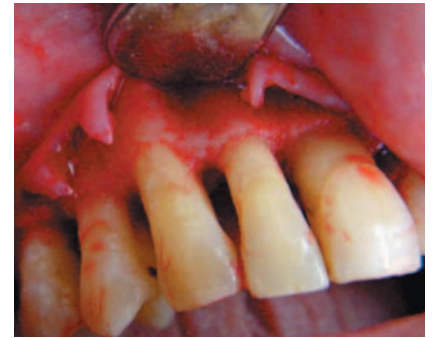with two tips: a 1300 micron, straight sapphire tip and a 200 micron, conical sapphire tip.



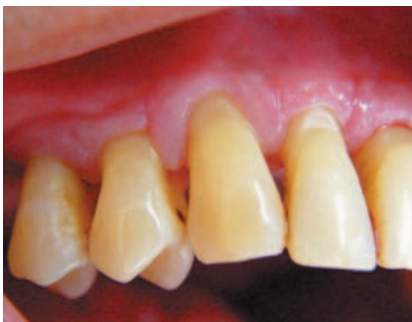**Figure 11.** Perio pockets at 5-7 mm depths



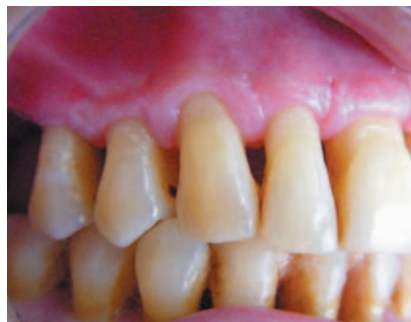**Figure 12.** Cutting and ablating granulated tissue with the Erbium laser



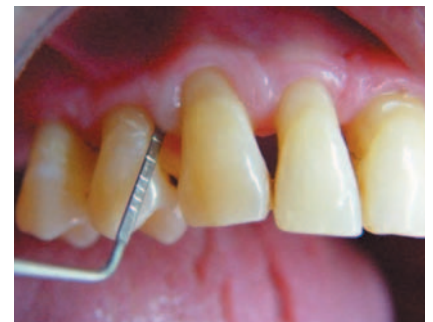**Figure 13.** Post-ablation of the granulated tissue and new bone exposure



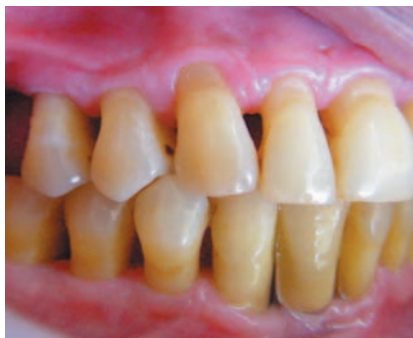**Figure 14.** Healing stage two weeks post-surgery



**Figure 15.** Healing stage 40 days post-surgery



**Figure 16.** Four months post-surgery - Perio pockets at 3 mm depths



**Figure 17.** Follow-up at fourteen months



**Figure 18.** Laser delivery handpiece and sapphire tips

**PERIODONTAL APPLICATION REFERENCES**

1. Aoki A, Miura M, Akiyama F, Nakagawa N, Tanaka J, Oda S, Watanabe H, Ishikawa I. "In vitro Evaluation of Erbium Laser Scaling of Sub-gingival Calculus in Comparison With Ultrasonic Scaling". *J Periodontal Res.* 2000 Oct;35(5):266-77.
2. Ando Y, Aoki A, Watanabe H, Ishikawa I. "Bactericidal Effect of Erbium:YAG Laser on Periodontopathic Bacteria". *Lasers Surg Med.* 1996;19(2):190-200.
3. Kesler G, Koren R, Kesler A, Kristt D, Gal R. "Differences in Histochemical Characteristics of Gingival Collagen After Erbium Laser Periodontal Plastic Surgery". *J Clin Laser Med Surg* 2000 Aug;18(4):203-7
4. Rossmann JA, Israel M. "Laser De-Epithelialization for Enhanced Guided Tissue Regeneration. A Paradigm Shift?" *Dent Clin North Am* 2000 Oct;44(4):793-809
5. Schwarz F, Sculean A, Georg T, Reich E. "Periodontal Treatment with an Erbium Laser Compared To Scaling and Root Planing. A Controlled Clinical Study." *J Periodontol* 2001 Mar;72(3):361-7

**HARD TISSUE APPLICATION REFERENCES**

1. Wigdor, H., "Patients' Perception of Lasers in Dentistry", *Lasers in Surgery and Medicine*, 20:47-50 (1997)
2. Cozean, C., Arcoria, C.J., Pelagalli, J., Powell, L. "Dentistry for the 21st Century? Erbium:YAG Laser for Teeth", *JADA*, Vol. 128, August 1997, p.p. 1-8
3. Pelagalli, J., Gimbel, C.B., Hansen, R.T. et al. "Investigational Study of the Use of Erbium laser Versus Dental Drill for Caries Removal and Cavity Preparation - Phase I", *Journal of Clinical Laser Medicine and Surgery*, Vol. 15, No. 3, 1997, p.p. 109-115
4. Visuri, S.R., Walsh Jr., J.T., Wigdor, H., "Erbium Laser Ablation of Dental Hard Tissue: Effect of Water Cooling", *Lasers in Surgery and Medicine*, 1996, 18:294-300
5. Wigdor, H., Walsh Jr., J.T., Featherstone, J.D.B. et al. "Lasers in Dentistry", *Lasers in Surgery and Medicine*, 16:103-133 (1995)
6. Wigdor, H., Abt, E., Ashrafi, S., Walsh Jr., J.T., "The Effects of Lasers on Dental Hard Tissues", *JADA*, Vol. 124, Feb. 1993, p.p. 65-70

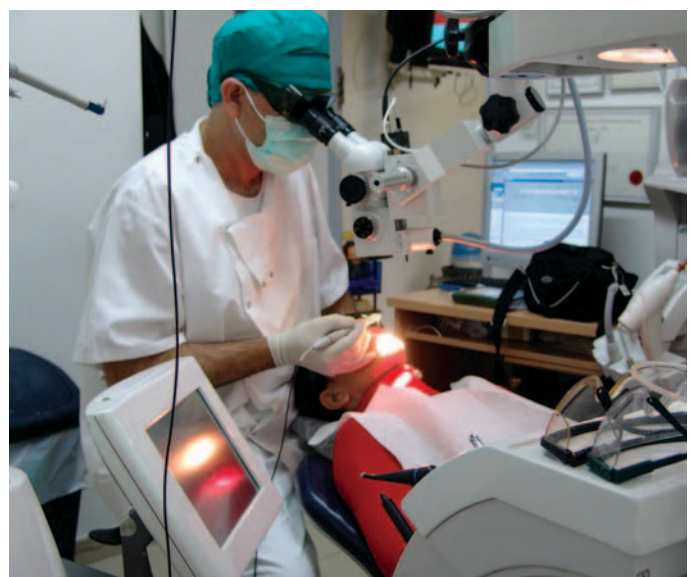**DR. AVI REYHANIAN**

Dr. Reyhanian graduated from the University of Bucharest, Romania in 1988. He then participated in a fellowship program at the Oral & Maxillofacial Department in the largest hospital in northern Israel. He currently practices general dentistry and oral surgery in Israel.

Dr. Reyhanian's practice has employed dental lasers since early 2002. He is a certified member of the ALD (American Society of Laser Dentistry) and the Israeli chapter of the same, and is a member of the Israel Society of Dental Implantology. Three wavelengths are used in his practice: Erbium:YAG (2940nm), CO<sub>2</sub> (10600nm) and Diode (830nm).

Dr. Reyhanian presents lectures in Israel and in Europe on the topics of dental lasers. He is an internationally recognized expert on the subject of laser dentistry.

The Topic of Dr. Reyhanian's lecture is: "Clinical Applications with Three Wavelengths in Oral Surgery, Periodontology and Implantology".



Laser-assisted, microscopic oral surgery at Dr. Reyhanian's clinic