

# Cellular, molecular, and tissue-level reactions to orthodontic force

Vinod Krishnan<sup>a</sup> and Ze'ev Davidovitch<sup>b</sup>

Tamilnadu, India, and Cleveland, Ohio

Remodeling changes in paradental tissues are considered essential in effecting orthodontic tooth movement. The force-induced tissue strain produces local alterations in vascularity, as well as cellular and extracellular matrix reorganization, leading to the synthesis and release of various neurotransmitters, cytokines, growth factors, colony-stimulating factors, and metabolites of arachidonic acid. Recent research in the biological basis of tooth movement has provided detailed insight into molecular, cellular, and tissue-level reactions to orthodontic forces. Although many studies have been reported in the orthodontic and related scientific literature, a concise convergence of all data is still lacking. Such an amalgamation of the rapidly accumulating scientific information should help orthodontic clinicians and educators understand the biological processes that underlie the phenomenon of tooth movement with mechanics (removable, fixed, or functional appliances). This review aims to achieve this goal and is organized to include all major findings from the beginning of research in the biology of tooth movement. It highlights recent developments in cellular, molecular, tissue, and genetic reactions in response to orthodontic force application. It reviews briefly the processes of bone, periodontal ligament, and gingival remodeling in response to orthodontic force. This review also provides insight into the biological background of various deleterious effects of orthodontic forces. (*Am J Orthod Dentofacial Orthop* 2006;129:469e.1-460e.32)

**T**ooth movement by orthodontic force application is characterized by remodeling changes in dental and paradental tissues, including dental pulp, periodontal ligament (PDL), alveolar bone, and gingiva. These tissues, when exposed to varying degrees of magnitude, frequency, and duration of mechanical loading, express extensive macroscopic and microscopic changes. Orthodontic tooth movement differs markedly from physiological dental drift or tooth eruption. The former is uniquely characterized by the abrupt creation of compression and tension regions in the PDL.<sup>1</sup> Physiological tooth movement is a slow process that occurs mainly in the buccal direction into cancellous bone or because of growth into cortical bone. In contrast, orthodontic tooth movement can occur rapidly or slowly, depending on the physical characteristics of the applied force, and the size and biological response of the PDL.<sup>2</sup> These force-induced strains alter the PDL's vascularity and blood flow, resulting in local synthesis and release of various key

molecules, such as neurotransmitters, cytokines, growth factors, colony-stimulating factors, and arachidonic acid metabolites. These molecules can evoke many cellular responses by various cell types in and around teeth, providing a favorable microenvironment for tissue deposition or resorption.<sup>3,4</sup>

Studies in the early 20th century attempted mainly to analyze the histological changes in paradental tissues after tooth movement. Those studies showed extensive cellular activities in the mechanically stressed PDL involving fibroblasts, endothelial cells, osteoblasts, osteocytes, and endosteal cells.<sup>5</sup> Apart from this finding, it was discovered that mechanical stresses alter the structural properties of tissues at the cellular, molecular, and genetic levels. Current literature has much data on molecular- and genetic-level cellular responses to orthodontic force. The rapid reactions at the initial stage of mechanotherapy and slower adaptive changes later are well explained in the literature. The following discussion on cellular, molecular, and tissue reactions is intended to provide basic information about histological and chemical changes of orthodontic tooth movement. It tries to update the readers with recent developments in cellular, molecular, tissue, and genetic reactions in response to orthodontic force application along with a brief description on the processes of bone, PDL, and gingival remodeling in response to orthodontic force. This review also provides insight into the

<sup>a</sup>Assistant professor, Department of Orthodontics, Rajas Dental College, Tirunelveli District, Tamilnadu, India.

<sup>b</sup>Clinical professor, Department of Orthodontics, Case Western Reserve University, Cleveland, Ohio.

Reprint requests to: Dr Vinod Krishnan, Gourivilasam, Kudappanakunnu PO, Trivandrum, Kerala State 695043, India; e-mail, vikrishnan@yahoo.com.

Submitted, May 2005; revised and accepted, October 2005.

0889-5406/\$32.00

Copyright © 2006 by the American Association of Orthodontists.

doi:10.1016/j.ajodo.2005.10.007

biological background of various deleterious effects of orthodontic forces.

### **ORTHODONTIC VERSUS ORTHOPEDIC FORCE**

Orthodontic force has been defined as “force applied to teeth for the purpose of effecting tooth movement, generally having a magnitude lower than an orthopedic force,” whereas orthopedic force is defined as “force of higher magnitude in relation to an orthodontic force, when delivered via teeth for 12 to 16 hours a day, is supposed to produce a skeletal effect on the maxillofacial complex.”<sup>6</sup> These definitions show that there is no clear distinction between orthodontic and orthopedic forces, even in terms of magnitude; furthermore, many widely variable arbitrary suggestions about the characteristics of orthodontic forces abound in the literature.

Orthodontic mechanotherapy is mainly aimed at tooth movement by remodeling and adaptive changes in paradental tissues. To effect this outcome, only small amounts of force—20 to 150 g per tooth—might be required. But craniofacial orthopedics is aimed at delivering higher magnitudes of mechanical forces—more than 300 g—in attempts to modify the form of craniofacial bones. The appliances, called craniofacial orthopedic devices, deliver macro-scale mechanical forces, which produce micro-structural sutural bone strain and induce cellular growth response in sutures.<sup>7</sup>

### **OPTIMAL ORTHODONTIC FORCE**

Orthodontic tooth movement is mediated by coupling bone resorption and deposition in compressed and stretched sides of the PDL, respectively. Orthodontic forces, by virtue of altering the blood flow and localized electrochemical environment, upset the homeostatic environment of the PDL space. This abrupt alteration initiates biochemical and cellular events that reshape the bony contour of the alveolus.<sup>8</sup> It is assumed that an optimal orthodontic force moves teeth efficiently into their desired position, without causing discomfort or tissue damage to the patient. Primarily, an optimal force is based on proper mechanical principles, which enable the orthodontist to move teeth without traumatizing dental or paradental tissues, and without moving dental roots redundantly (round-tripping), or into danger zones (compact plates of alveolar bone). Traditionally, orthodontic forces have been categorized as “light” or “heavy,” and it was assumed that light forces are gentler and therefore more physiologic than heavy forces. However, Burstone<sup>9</sup> reported that orthodontic forces are never distributed equally throughout the PDL, and Storey<sup>10</sup> observed that some trauma is always associated with applied orthodontic

forces, even light ones. Moreover, it is impossible, with the available instrumentation, to measure precisely the amount of force applied to roots or parts thereof under any mode of treatment. Consequently, at present, it can be stated that, to engender adequate biological response in the periodontium, light forces are preferable, because of their ability to evoke frontal resorption of bone. Unlike light forces, heavy forces often cause necrosis (hyalinization) of the PDL and undermining bone resorption,<sup>11</sup> and have been implicated in root resorption.

The concept of optimal orthodontic force is changing along with the specialty. The classic definition of optimal force by Schwarz<sup>12</sup> in 1932 was “the force leading to a change in tissue pressure that approximated the capillary vessels’ blood pressure, thus preventing their occlusion in the compressed periodontal ligament.” According to Schwarz, forces below optimum produce no reaction, whereas forces above that level lead to tissue necrosis, thus preventing frontal resorption of the alveolar bone. Oppenheim<sup>13</sup> and Reitan,<sup>11</sup> who recommended applying light forces for tooth movement, demonstrated cell-free compressed areas in the PDL. Storey and Smith<sup>14</sup> also reported the same finding in 1952. They studied distal movement of canines in orthodontic patients and suggested that there is an optimum range of pressure (150-200 g) on the tooth-bone interface that produces a maximum rate of tooth movement. Pressure below this range produced no tooth movement. When the force was increased above optimum, the rate of tooth movement was decreased and finally approached zero within a week.

The current concept of optimum force views it as an extrinsic mechanical stimulus that evokes a cellular response that aims to restore equilibrium by remodeling periodontal supporting tissues. So the mechanical input that leads to the maximum rate of tooth movement with minimal irreversible damage to root, PDL, and alveolar bone is considered to be optimal. This concept means that there is a force of certain magnitude and temporal characteristics (continuous v intermitted, constant v declining) capable of producing a maximal rate of tooth movement, without tissue damage, and with maximum patient comfort.<sup>15,16</sup> According to this concept, the optimal force might differ for each tooth and for each patient. Clinically, the relationship between orthodontic force magnitude and rate of tooth movement during active treatment is now considered to be a practical tool in identifying optimal forces on an individual basis.

### **THEORIES OF ORTHODONTIC MECHANISMS**

Orthodontic tooth movement has been defined as the result of a biologic response to interference in the

physiologic equilibrium of the dentofacial complex by an externally applied force.<sup>15</sup> The biologic foundation of force-induced tooth movement along with some concepts related to it was extensively investigated in the 19th century. This quest led to the proposal of 2 main mechanisms for tooth movement—the application of pressure and tension to the PDL, and bending of the alveolar bone.

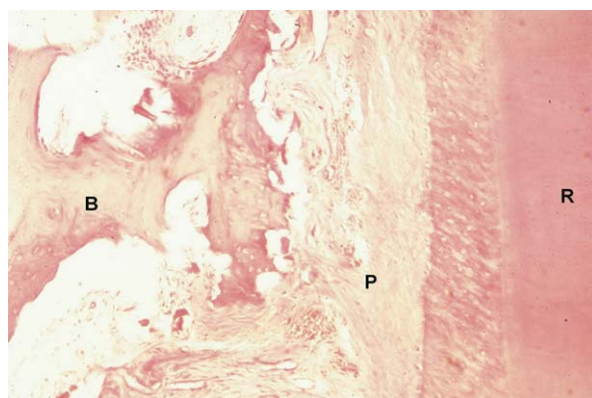
### The pressure-tension theory

Classic histologic research about tooth movement by Sandstedt (1904),<sup>17</sup> Oppenheim (1911),<sup>18</sup> and Schwarz (1932)<sup>12</sup> led them to hypothesize that a tooth moves in the periodontal space by generating a “pressure side” and a “tension side.” This hypothesis explained that, on the pressure side, the PDL displays disorganization and diminution of fiber production. Here, cell replication decreases seemingly due to vascular constriction. On the tension side, stimulation produced by stretching of PDL fiber bundles results in an increase in cell replication (Figs 1 and 2). This enhanced proliferative activity leads eventually to an increase in fiber production.<sup>19</sup>

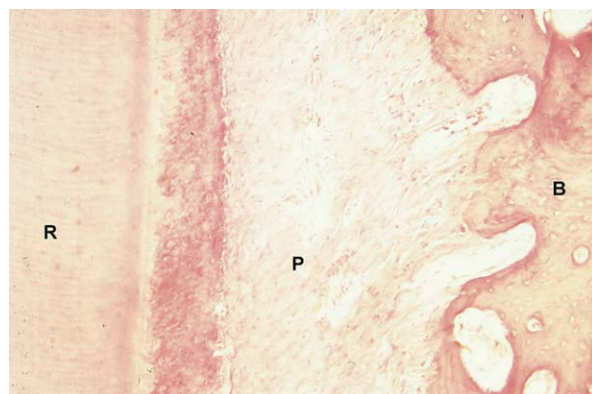Schwarz<sup>12</sup> detailed the concept further, by correlating the tissue response to the magnitude of the applied force with the capillary bed blood pressure. He concluded that the forces delivered as part of orthodontic treatment should not exceed the capillary bed blood pressure (20-25 g/cm<sup>2</sup> of root surface). If one exceeds this pressure, compression could cause tissue necrosis through “suffocation of the strangulated periodontium.” Application of even greater force levels will result in physical contact between teeth and bone, yielding resorption in areas of pressure and undermining resorption or hyalinization in adjacent marrow spaces.

The concept of pressure-tension in orthodontic tooth movement was evaluated mainly by histologic studies of the periodontium. It postulated that width changes in the PDL cause changes in cell population and increases in cellular activity. There is an apparent disruption of collagen fibers in the PDL, with evidence of cell and tissue damage. The first sign of hyalinization is the presence of pyknotic nuclei in cells, followed by areas of acellularity, or cell-free zones. The resolution of the problem starts when cellular elements such as macrophages, foreign body giant cells, and osteoclasts from adjacent undamaged areas invade the necrotic tissue. These cells also resorb the underside of bone immediately adjacent to the necrotic PDL area and remove it together with the necrotic tissue. This process is known as undermining resorption.<sup>20,21</sup>

Reitan,<sup>1,11</sup> in his classic articles on histologic changes after orthodontic force application, reported



**Fig 1.** Sagittal section, 6  $\mu$ m thick, of maxillary canine of 1-year-old female cat, after 14 days of distal tipping with 80 g force. R, canine root; P, canine PDL; B, alveolar bone. Shown is distal side of canine, where PDL had been compressed. Compressed PDL contains necrotic (hyalinized) zone, which is being removed by cells from surrounding viable PDL; adjacent alveolar bone is undergoing undermining and indirect resorption. Hematoxylin and eosin staining; X 320.



**Fig 2.** Sagittal section, 6  $\mu$ m thick, of maxillary canine of 1-year-old female cat, after 14 days of distal tipping with 80 g force. R, canine root, P, canine PDL; B, alveolar bone. Shown is mesial side of canine, where PDL had been stretched. New bony trabeculae are seen extending into widened PDL space in direction of applied force. Hematoxylin and eosin staining; X 320.

that hyalinization refers to cell-free areas in the PDL, in which the normal tissue architecture and staining characteristics of collagen in the processed histologic material have been lost. He could observe that (1) hyalinization occurred in the PDL after the application of even minimal force, meant to obtain a tipping movement; (2) more hyalinization occurred after application of force if a tooth had a short root; (3) during translation of a tooth, very little hyalinization was observed.

Reitan<sup>11</sup> concluded that the tissue changes observed were those of degeneration related to force per unit area, and that attempts should be made to minimize these changes.

The ongoing discussion suggests that inflammation might be at least partly responsible for cellular recruitment and tissue remodeling in areas of force application. This process might in turn lead to frontal resorption (where osteoclasts line up in the margin of the alveolar bone adjacent to the compressed PDL, producing direct bone resorption) and undermining resorption. The third phase of bone remodeling consists of loss of bone mass at PDL pressure areas and apposition at tension areas.<sup>22</sup> This succession of events formed the central theme of the pressure-tension hypothesis.

Baumrind,<sup>19</sup> reconsidering the propriety of the pressure-tension hypothesis, pointed out a conceptual flaw in it. He considered the PDL to be a continuous hydrostatic system and suggested that any force delivered to it would be transmitted equally to all regions. He drew support for this concept from Pascal's law, a basic law in physics. He further stated that the presence of fibers in the PDL does not modify the operation of this law, because of the concomitant existence of a continuous body of liquefied ground substance. He recognized that only part of the periodontium where differential pressures, as mentioned in the pressure-tension hypothesis, can be developed, is solid—bone, tooth, and discrete solid fractures of the PDL. Consequently, he proposed an alternative hypothesis in 1969, known as the bone-bending theory. It states that orthodontic forces routinely produce alveolar bone deflection, and that these strains are accompanied by changes in the PDL.<sup>19</sup>

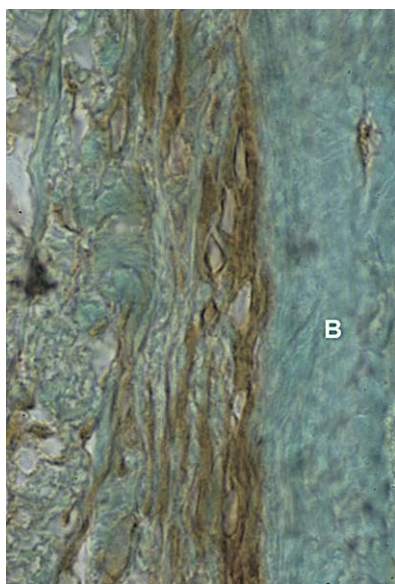
### **The bone-bending theory**

Farrar<sup>23</sup> was the first to suggest, in 1888, that alveolar bone bending plays a pivotal role in orthodontic tooth movement. This hypothesis was later confirmed with the experiments of Baumrind<sup>19</sup> in rats and Grimm<sup>24</sup> in humans. According to these authors, when an orthodontic appliance is activated, forces delivered to the tooth are transmitted to all tissues near force application. These forces bend bone, tooth, and the solid structures of the PDL. Bone was found to be more elastic than the other tissues and to bend far more readily in response to force application. The active biologic processes that follow bone bending involve bone turnover and renewal of cellular and inorganic fractions. These processes are accelerated while the bone is held in the deformed position. These authors further stated that "reorganization proceeds not only at the lamina dura of the alveolus, but also on the surface of every trabacu-

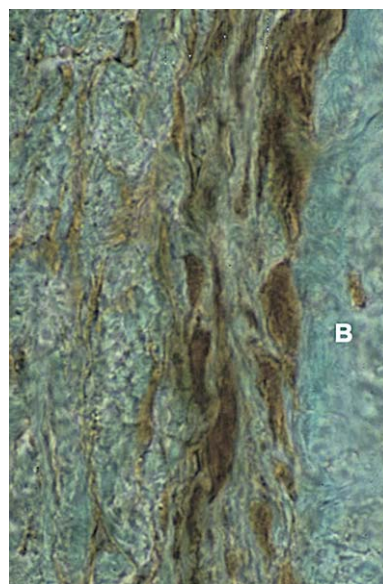
lum within the corpus of bone." The force delivered to the tooth is dissipated throughout the bone by development of stress lines, and further force application becomes a stimulus for altered biological responses of cells lying perpendicular to the stress lines. The altered activity of cells in turn modifies the shape and internal organization of bone, to accommodate the exogenous forces acting on it.

With the help of this theory, and gaining support from Wolff's law, these authors could explain facts such as (1) the relative slowness of en-masse tooth movement, when much bone flexion is needed for the rapidity of alignment of crowded teeth, and when thinness makes bone flexion easier; (2) the rapidity of tooth movement toward an extraction site; and (3) the relative rapidity of tooth movement in children, who have less heavily calcified and more flexible bones than adults.<sup>19,23</sup>

The deposition and resorption of bone in response to its bending by orthodontic forces is evidently an attractive hypothesis, but it seems to contradict the current orthopedic dogma, which states that "any mechanical compression stimulates bone formation and tension stimulates resorption."<sup>25</sup> Epker and Frost<sup>26</sup> described the change in shape of the alveolar bone circumference resulting from stretching the PDL fibers. This fiber stretching decreases the radius of the alveolar wall, ie, bending bone in the tension zone, where apposition of bone takes place. They attributed this response to a regional acceleratory phenomenon. Accordingly, any regional noxious stimulus of sufficient magnitude can evoke a regional acceleratory phenomenon. The extent of the affected region and intensity of the response vary directly with the magnitude and nature of the stimulus. Experimenting with dog mandibles in vitro and in vivo, Zengo et al,<sup>27</sup> Bassett and Becker,<sup>28</sup> and Pollack et al<sup>29</sup> demonstrated that orthodontic canine tipping bends the alveolar bone, creating on it concave and convex surfaces, identical to those generated in bent long bones. In areas of PDL tension, the interfacing bone surface assumes a concave configuration, in which the molecules are compressed, whereas, in zones of compressed PDL, the adjacent alveolar bone surface becomes convex. Hence, there is no contradiction between the response of alveolar bone and other parts of the skeleton to mechanical loading. The confusion in this regard has resulted from the usage of the same descriptions for different tissues. Although orthodontic tension refers to the PDL, an orthopedist might say that the area is under compression, because the bone near the stretched PDL has become concave.



**Fig 3.** Transversal section, 6  $\mu\text{m}$  thick, of 1-year-old female cat's mandible, after 7-day exposure to sham electrodes (control). Shown is buccal periosteum of second premolar opposite sham cathode, stained immunohistochemically for cAMP. *B*, alveolar bone. Bone surface lining cells are flat, and most stain lightly for cAMP; X 640.



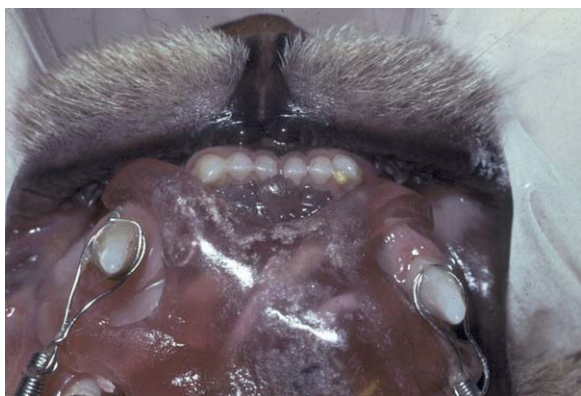**Fig 4.** Transversal section, 6  $\mu\text{m}$  thick, of 1-year-old female cat's mandible (same animal as in Fig 3), after exposure for 7 days to constant application of 20  $\mu\text{A}$  direct current to gingival mucosa noninvasively. Shown are tissues near stainless steel cathode, stained immunohistochemically for cAMP. *B*, alveolar bone. Compared with cells in Fig 3, bone surface lining cells near cathode are larger and more darkly stained for cAMP; X 640.

### Bioelectric signals in orthodontic tooth movement

In 1962, Bassett and Becker<sup>28</sup> proposed that, in response to applied mechanical forces, there is generation of electric potentials in the stressed tissues. These potentials might charge macromolecules that interact with specific sites in cell membranes or mobilize ions across cell membranes. Zengo et al<sup>27</sup> measured the electric potential in mechanically stressed dog alveolar bone during in-vivo and in-vitro experiments. They demonstrated that the concave side of orthodontically treated bone is electronegative and favors osteoblastic activity, whereas the areas of positivity or electrical neutrality—convex surfaces—showed elevated osteoclastic activity. It has been proposed by Davidovitch et al<sup>30,31</sup> that a physical relationship exists between mechanical and electrical perturbation of bone. Bending of bone causes 2 classes of stress-generated electrical effects. Their experiments with exogenous electrical currents in conjunction with orthodontic forces demonstrated enhanced cellular activities in the PDL and alveolar bone, as well as rapid tooth movement (Figs 3-5). Taken together, these findings suggest that bioelectric responses (piezoelectricity and streaming potentials) propagated by bone bending incident to orthodontic force application might function as pivotal cellular first messengers.

Piezoelectricity is a phenomenon observed in many crystalline materials, in which a deformation of a crystal structure produces a flow of electric current as electrons are displaced from 1 part of the lattice to another. Apart from inorganic crystals, it was found that organic crystals could also exhibit piezoelectricity. The 2 unusual properties of piezoelectricity, which seem to not correlate well with orthodontic tooth movement are (1) a quick decay rate, where the electron transfer from 1 area to another after force application reverts back when the force is removed, which does not or should not happen once orthodontic treatment is over; and (2) production of an equivalent signal in the opposite direction upon force removal.<sup>15</sup>

Borgens<sup>32</sup> investigated this phenomenon in bone fracture sites by inducing electric current for healing purposes. He found no correlation to what have been proposed as piezoelectric effects and showed that the dispersion of current as it enters the lesion is unpredictable. He attributed this finding to the complexity of distribution of mineralized and nonmineralized matrices. However, he observed generation of endogenous ionic currents evoked in intact and damaged mouse bones, and classified these currents as stress-generated potentials or streaming potentials, rather than piezo-



**Fig 5.** Occlusal view of maxilla of 1-year-old female cat wearing device that delivered constant direct current, 20  $\mu$ A noninvasively to gingival and oral mucosa labial to left canine. Right canine (control) received same electrodes, but without electrical current. Both canines were moved distally by 80 g tipping force. Right canine, which had been subjected only to mechanical force, moved distally smaller distance than left canine, that had received combined mechanical force and electrical current.

electric currents. In contrast to piezoelectric spikes, the streaming potentials had long decay periods. This finding led him to hypothesize that the mechanically stressed bone cells themselves, not the matrix, are the source of the electric current. His hypothesis received support from Pollack et al,<sup>29</sup> who proposed a mechanism by which force-evoked electric potentials can reach the surface of bone cells. According to this explanation, an electric double layer surrounds bone, where electric charges flow in coordination with stress-related fluid flow. These stress-generated potentials might affect the charge of cell membranes and of macromolecules in the neighborhood. Davidovitch et al<sup>30,31</sup> suggested recently that piezoelectric potentials result from distortion of fixed structures of the periodontium—collagen, hydroxyapatite, or bone cell surface. But in hydrated tissues, streaming potentials (the electrokinetic effects that arise when the electrical double layer overlying a charged surface is displaced) predominate as the interstitial fluid moves. They further reported that mechanical perturbations of about 1 minute per day are apparently sufficient to cause an osteogenic response, perhaps due to matrix proteoglycan related strain memory.

It is evident from the ongoing discussion that neither hypothesis provides conclusive evidence on the detailed nature of the biologic mechanism of tooth movement. Histologic, histochemical, and immunohistochemical studies in the 20th century and the early 21st century demonstrated that many phenomena, both

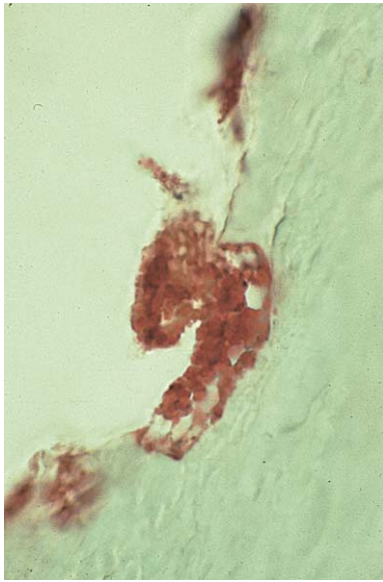
physical and biologic, are involved in tooth movement. When mechanical forces are applied, cells, as well as the extracellular matrix of the PDL and alveolar bone, respond concomitantly, resulting in tissue remodeling.<sup>3</sup> During early phases of tooth movement, PDL fluids are shifted, producing cell and matrix distortions, as well as interactions between these tissue elements. In response to these physicochemical events and interactions, cytokines, growth factors, colony-stimulating factors, and vasoactive neurotransmitters are released, initiating and sustaining the remodeling activity, which facilitates tooth movement.

### PHASES OF TOOTH MOVEMENT


In 1962, Burstone<sup>9</sup> suggested that, if the rates of tooth movement were plotted against time, there would be 3 phases of tooth movement—an initial phase, a lag phase, and a postlag phase. The initial phase is characterized by rapid movement immediately after the application of force to the tooth. This rate can be largely attributed to the displacement of the tooth in the PDL space. Immediately after the initial phase, there is a lag period, with relatively low rates of tooth displacement or no displacement. It has been suggested that the lag is produced by hyalinization of the PDL in areas of compression. No further tooth movement occurs until cells complete the removal of all necrotic tissues. The third phase of tooth movement follows the lag period, during which the rate of movement gradually or suddenly increases.

Two recent studies have proposed a new time/displacement model for tooth movement.<sup>33,34</sup> These studies, performed on beagles, divided the curve of tooth movement into 4 phases. The first phase lasts 24 hours to 2 days and represents the initial movement of the tooth inside its bony socket. It is followed by a second phase, when tooth movement stops for 20 to 30 days. After the removal of necrotic tissue formed during the second phase, tooth movement is accelerated in the third phase and continues into the fourth phase. The third and fourth phases comprise most of the total tooth movement during orthodontic treatment. Researchers<sup>33-36</sup> found these patterns well in agreement with those described in humans by Burstone as the initial phase, the lag phase, and the postlag phase.

Cellular and tissue reactions start in the initial phase of tooth movement, immediately after force application. Because of the compression and stretch of fibers and cells in PDL pressure and tension areas, respectively, the complex process of recruitment of osteoclast and osteoblast progenitors, as well as extravasation and chemoattraction of inflammatory cells, begins. The presence of hyalinized zones in the pressure area was



**Fig 6.** Sagittal section, 6  $\mu\text{m}$  thick, of maxillary canine of 1-year-old male cat, stained histochemically for localization of TRAP, after 56 days of distal translation with 80 g force. Canine was undergoing resorption in distal side of apical third of root. Odontoclasts that populated dentinal resorption lacunae were stained positively (red) for TRAP; X 960.



**Fig 7.** Sagittal section, 6  $\mu\text{m}$  thick, of maxillary canine of 1-year-old male cat (same animal as in Fig 6), stained histochemically for localization of alkaline phosphatase, after 56 days of distal translation with 80 g force. B, alveolar bone; P, PDL. Alveolar bone surface lining cells are stained positively (blue) for alkaline phosphatase; adjacent PDL cells are only faintly stained for this enzyme; X 960.

demonstrated in recent experiments even in this early stage.<sup>35,36</sup> The presence of osteoclastic and osteoblastic activity has been demonstrated by tartarate resistant acid phosphatase (TRAP) and alkaline phosphatase activity, respectively (Figs 6 and 7).

In the second phase, areas of compression are easily recognized by the distorted appearance of the normal PDL fiber arrangement. The disruption in blood flow due to this distortion leads to the development of hyalinized areas and the arrest of tooth movement, which can last from 4 to 20 days. Only removal of necrotic tissue and bone resorption from adjacent marrow spaces (indirect resorption) and from the direction of the viable PDL (undermining resorption) allow the resumption of tooth movement. This comprehensive process requires the recruitment of phagocytic cells such as macrophages, foreign body giant cells, and osteoclasts from adjacent undamaged areas of the PDL and alveolar bone marrow cavities. These cells act in tandem to remove necrotic tissues from compressed PDL sites and adjacent alveolar bone. In areas of PDL tension, quiescent osteoblasts (bone surface lining cells) are enlarged and start producing new bone matrix (osteoid). New osteoblast progenitors are recruited from the population of fibroblast-like cells (pericytes) around PDL capillaries. These preosteoblasts proliferate and migrate toward the alveolar bone surface, along the stretched Sharpey's fibers. Simultaneously, PDL fibroblasts in tension zones begin multiplying and remodeling their surrounding matrix.

The third and fourth phases of orthodontic tooth movement, also known as the acceleration and linear phases, respectively, start about 40 days after the initial force application. The pressure sides of teeth exhibit collagen fibers without proper orientation. Here, irregular bone surfaces are found, indicating direct or frontal resorption. However, a recent report presented data on hyalinization zones at the pressure areas even during this stage, especially in areas where high forces were applied.<sup>35</sup> This finding suggests that the development and removal of necrotic tissue is a continuous process during tooth displacement, rather than a single event. This conclusion is supported by Melsen's hypothesis<sup>25</sup> that "indirect bone resorption at the pressure side is not a reaction to force but an attempt to remove ischemic bone lying adjacent to the hyalinized tissue. The subsequent direct bone resorption could be considered part of the remodeling process." The tension sides in the third and fourth phases clearly show bone deposition, as evidenced by alkaline phosphatase positive osteoblastic cells.

Recent reports by von Böhl et al<sup>35,36</sup> demonstrated that teeth subjected to high forces show hyalinization more often than teeth experiencing light forces. Thus, development of hyalinization zones has a definite relationship to the force magnitude, but it was found to have no relationship to the rate of tooth movement. These investigators concluded that, once tooth move-

ment has started after the second (arrest) phase, bone remodeling takes place at a certain rate, independent of force magnitude. These findings agree with those of Owman-Moll et al<sup>37</sup> and Van Leeuwen et al,<sup>34</sup> who also reported the location of hyalinization to be mostly buccal or lingual to the mesiodistal plane.

### **SIGNALING MOLECULES AND METABOLITES IN ORTHODONTIC TOOTH MOVEMENT**

The early phase of orthodontic tooth movement always involves an acute inflammatory response, characterized by periodontal vasodilatation and migration of leucocytes out of the capillaries. These migratory cells produce various cytokines, the local biochemical signal molecules, that interact directly or indirectly with the entire population of native paradental cells. Cytokines, acting as paracrines or autocrines, always with other systemic and local signal molecules, evoke the synthesis and secretion of numerous substances by their target cells, including prostaglandins, growth factors, and cytokines. Ultimately, these cells comprise the functional units that remodel the paradental tissues and facilitate tooth movement.

The acute inflammatory process that typifies the initial phase of orthodontic tooth movement is predominantly exudative, in which plasma and leukocytes leave the capillaries in areas of paradental strain. A day or 2 later, the acute phase of inflammation subsides and is replaced by a chronic process that is mainly proliferative, involving fibroblasts, endothelial cells, osteoblasts, and alveolar bone marrow cells. During this period, leukocytes continue to migrate into the strained paradental tissues and modulate the remodeling process.

Chronic inflammation prevails until the next clinical appointment, when the orthodontist activates the tooth-moving appliance, thereby starting another period of acute inflammation, superimposing it on the ongoing chronic inflammation. For the patient, the periods of acute inflammation are associated with painful sensations and reduced function (chewing). A reflection of these phenomena can be found in the gingival crevicular fluid (GCF) of moving teeth, where significant elevations in the concentrations of inflammatory mediators, such as cytokines and prostaglandins, occur temporally.

#### **Arachidonic acid metabolites**

Arachidonic (eicosatetraenoic) acid, the main component of phospholipids of the cell membrane, is released due to the action of phospholipase enzymes. The released acid can be metabolized by 2 pathways—the cyclooxygenase pathway (with the help of cy-

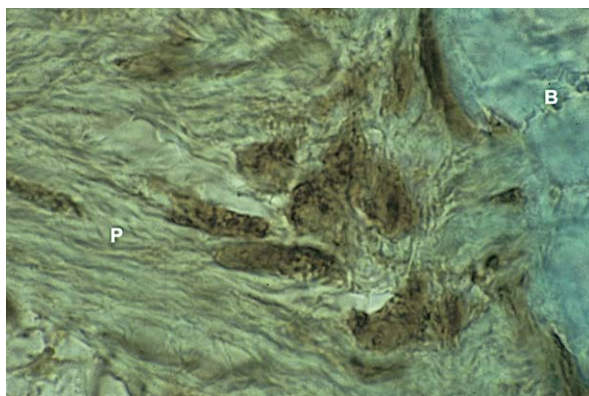
clooxygenase enzymes producing prostaglandins and thromboxanes) and the lipoxygenase pathway leading to release of leukotriens (originally demonstrated in leucocytes with 3 double bonds (triens) in the backbone of the molecule) and hydroxyeicosatetraenoic acids.<sup>38</sup> Evidence for the involvement of these eicosanoids in the bone remodeling process incident to orthodontic tooth movement has been extensively published.

#### **Prostaglandins in tooth movement**

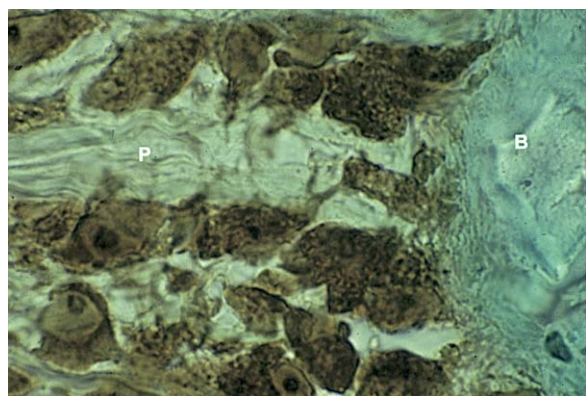
Von Euler,<sup>39</sup> who first discovered the compound in human semen and believed the prostate gland to be the main source of this chemical substance, introduced the term *prostaglandin*. However, it was later discovered that most cell types in the body produce prostaglandins. Harell et al<sup>40</sup> suggested that prostaglandins are important mediators of mechanical stress. This finding was followed by the work of Yamasaki et al,<sup>41</sup> who found an increase in osteoclast numbers after a local injection of prostaglandins into the paradental tissues of rodents. This association was demonstrated by the reduced rate of tooth movement after the administration of indomethocin, an anti-inflammatory agent and a specific inhibitor of prostaglandin synthesis.<sup>42</sup>

Clinical and animal studies by various authors have identified the role of prostaglandins (PGE<sub>1</sub> and PGE<sub>2</sub>) in stimulating bone resorption.<sup>43-45</sup> They have reported a direct action of prostaglandins on osteoclasts in increasing their numbers and their capacity to form a ruffled border and effect bone resorption. Like other bone-resorbing agents, PGE<sub>2</sub> also stimulates osteoblastic cell differentiation and new bone formation, coupling bone resorption in vitro. Studies have also identified other agents such as growth factors (platelet-derived growth factors), hormones (parathormone [PTH]), and interleukins or other cytokines that induce PGE<sub>2</sub> production, to effect bone remodeling and tooth movement.<sup>46</sup> A recent study evaluated the effects of prostacyclin and thromboxane A<sub>2</sub> in orthodontic tooth movement and osteoclastic activity on rats. It was found that these analogues increase the number of multinuclear osteoclasts, osteoclastic bone resorption, and the rate of orthodontic tooth movement.<sup>47</sup>

Within minutes, as paradental tissues become progressively strained by applied forces, the cells are subjected to other first messengers, the products of cells of the immune and the nervous systems. The binding of these signal molecules to cell membrane receptors leads to enzymatic conversion of cytoplasmic ATP and GTP into adenosine 3', 5'-monophosphate (cyclic AMP [cAMP]), and guanosine 3', 5'-monophosphate (cyclic GMP [cGMP]), respectively. These latter molecules are known as intracellular second messengers. Immunohis-



**Fig 8.** Horizontal section, 6  $\mu\text{m}$  thick, of maxillary canine of 1-year-old female cat. Tooth was not subjected to mechanical force and served as control. Section was stained immunohistochemically for cAMP. B, alveolar bone; P, PDL. Alveolar bone surface lining cells are flat; many adjacent PDL cells have round shape; X 960.



**Fig 9.** Horizontal section, 6  $\mu\text{m}$  thick, of maxillary canine of 1-year-old female cat, treated for 24 hours with distalizing tipping force (same animal as in Fig 8). Zone of force-induced tension in PDL is shown. Section was stained immunohistochemically for cAMP. Compared with parodontal cells of control canine (Fig 8), both alveolar bone surface cells and neighboring PDL cells were larger, and more intensely stained for cAMP; X 960.

tochemical staining during orthodontic tooth movement in cats showed high concentrations of these molecules in the strained parodontal tissues<sup>48</sup> (Figs 8 and 9).

#### The intracellular second-messenger systems

Sutherland and Rall<sup>49</sup> established the second-messenger basis for hormone actions in 1958. They discovered that free glucose appeared in the bathing media of liver slices exposed to adrenaline. They proposed that

the first messenger (a hormone or another stimulating agent) binds to a specific receptor on the cell membrane and produces an intracellular chemical second messenger. This second messenger then interacts with cellular enzymes, evoking a response, such as protein synthesis or glycogen breakdown. Two main second-messenger systems are now recognized—the cyclic nucleotide pathway and the phosphatidyl inositol (PI) dual signaling system.<sup>48</sup> These systems mobilize internal calcium stores and activate protein kinase C, respectively. The activation of specific protein kinases, together with an increase in intracellular calcium concentrations, might trigger a number of protein phosphorylation events, eventually leading to a cellular response. This response might comprise motility, contraction, proliferation, synthesis, and secretion.<sup>48</sup>

#### The cAMP pathway

Internal signaling systems are those that translate many external stimuli to a narrow range of internal signals or second messengers.<sup>38</sup> cAMP and cGMP are 2 second messengers associated with bone remodeling.<sup>50</sup> Bone cells, in response to hormonal and mechanical stimuli, produce cAMP *in vivo* and *in vitro*. Alterations in cAMP levels have been associated with synthesis of polyamines, nucleic acids, and proteins, and secretion of cellular products. The action of cAMP is mediated through phosphorylation of specific substrate proteins by its dependent protein kinases. In contrast to this role, cGMP is considered an intracellular regulator of both endocrine and nonendocrine mechanisms.<sup>5</sup> The action of cGMP is mediated through specific substrate proteins by cGMP-dependent protein kinases. This signaling molecule plays a key role in synthesis of nucleic acids and proteins as well as secretion of cellular products.

#### The PI dual signaling systems

Another second-messenger system reviewed extensively in relation to orthodontic tooth movement is the phosphoinositide pathway.<sup>51</sup> Interest in this system started with the demonstration of an increase in phosphate incorporation into cell membrane phospholipids by Hokin and Hokin in 1953.<sup>52</sup> The pathway outlines it as hydrolysis of PI 4,5 biphosphate in response to activation of cell surface receptors, leading to inositol triphosphate formation. This reaction in turn leads to a release of calcium ions from intracellular stores. Further phosphorylation of inositol triphosphate yields Ins (1,3,4,5) P<sub>4</sub>, which controls calcium entry at the plasma membrane through calcium channels. Inositol triphosphate is a mediator of mitogenesis in mechani-

cally deformed tissues through an increase in DNA synthesis.<sup>38</sup>

### **The importance of the second-messenger concept to orthodontics**

The second-messenger hypothesis postulates that target cells respond to external stimuli, chemical or physical, by enzymatic transformation of certain membrane-bound and cytoplasmic molecules to derivatives capable of promoting the phosphorylation of cascades of intracellular enzymes. Therefore, temporal increases in the tissue or cellular concentrations of second messengers are generally viewed as evidence that an applied extracellular first messenger, such as an orthodontic force, has stimulated target cells. The literature includes many reports on significant elevations in the concentrations of intracellular second messengers in paradental cells after exposure to applied mechanical forces.

### **Vitamin D and diacylglycerol**

Another agent that has been identified as an important factor in orthodontic tooth movement is 1, 25, dehydroxycholecalciferol (1, 25, DHCC).<sup>53,54</sup> This agent is a biologically active form of vitamin D and has a potent role in calcium homeostasis. A decrease in the serum calcium level stimulates secretion of parathyroid hormone, which in turn increases excretion of  $\text{PO}_4^{-3}$ , reabsorption of  $\text{Ca}^{++}$  from the kidneys, and hydroxylation of 25, hydroxycholecalciferol to 1, 25, DHCC. The latter molecule has been shown to be a potent stimulator of bone resorption by inducing differentiation of osteoclasts from their precursors. It is also implicated in increasing the activity of existing osteoclasts. In addition to bone-resorbing activity, 1, 25 DHCC is known to stimulate bone mineralization and osteoblastic cell differentiation in a dose-dependent manner.<sup>46</sup>

Kale et al<sup>46</sup> compared the effects of local administration of 1, 25, DHCC and  $\text{PGE}_2$  on orthodontic tooth movement in rats, and reported that both molecules enhance tooth movement significantly, when compared with the control group. In that study, 1, 25, DHCC was found to be more effective than  $\text{PGE}_2$  in modulating bone turnover during tooth movement, because of its well-balanced effects on bone formation and resorption. Another study tried to determine the effect of 1, 25, DHCC on alveolar bone formation during tooth movement in rats.<sup>55</sup> The researchers observed significant increases in mineral appositional rate associated with an elevated osteoblast surface in PDL tension sites of teeth subjected to repeated injections of 1, 25, DHCC. They concluded that local

applications of 1,25(OH)2D3 could enhance the reestablishment of dental supporting tissues, especially alveolar bone, after orthodontic treatment.<sup>55</sup>

Orthodontic forces are applied in patients who can differ substantially in their biological profiles. Vitamin D3 exemplifies this. It is an active participant, with PTH and calcitonin, in the regulation of calcium homeostasis. However, its level in the blood of patients might be scattered over a wide range, due to variations in age, sex, and its rates of synthesis and hydroxylation. Moreover, active forms of vitamin D3 are often consumed as dietary supplements. Evidently, increasing its concentration around paradental cells while they are subjected to orthodontic forces can evoke synergistic reactions by the cells, leading to rapid tooth movement. Similar responses might occur when other signals are introduced during orthodontic treatment. These factors might originate inside the patient, either locally or systemically, such as cytokines and hormones or from external sources, such as drugs and electric currents.

### **Cytoskeleton-extracellular matrix interactions**

Cells are motors for tissue modeling and remodeling, and most cell types are sensitive to mechanical loads. This fact provides the scientific foundation of orthodontics.<sup>25</sup> The dental and paradental cellular responses to applied mechanical loads involve interplay between intra- and extracellular structural elements, and among biochemical messengers. Applied mechanical forces are transduced from the strained extracellular matrix (ECM) to the cytoskeleton through cell surface proteins. The ECM molecules involved in this process include collagen, proteoglycans, laminin, and fibronectin. The transduction occurs by ECM binding to cell adhesion molecules (integrins) and other cell surface receptors. Adhesion of the ECM to these receptors can induce reorganization of the cytoskeleton, secretion of stored cytokines, ribosomal activation, and gene transcription.<sup>56,57</sup>

The role of mechanotransducers in transforming mechanical forces into biochemical signals has been studied extensively in recent years.<sup>38,56-58</sup> Of the 3 components of the cytoskeleton—microfilaments, microtubules, and intermediate filaments—microfilaments are best suited to detect these changes. The major subunit protein of microfilaments is actin. Apart from this molecule, there are several other associated proteins, such as myosin, tropomyosin, vinculin, and talin. Microfilament bundles terminate at special sites of the cell membrane, forming a junctional complex with the ECM, known as focal contacts, focal adhesions, or adhesion plaques.<sup>38</sup>

The role of cell adhesion molecules in signal transduction has received close attention. Explorations of this issue showed that the cell binding properties of ECM proteins depend on the presence of the peptide sequence Arg-Gly-Asp (RGD). A family of integral proteins known as integrins, which are present on the cell membrane, connecting the cytoplasm and nucleus to the ECM, recognizes these RGD sites. The integrins bind to fibronectin extracellularly and talin intracellularly, to provide a signal transduction pathway.<sup>58</sup> A recent study identified expressions of integrins (specifically  $\alpha$ V $\beta$ 3 subunit) in osteoclasts associated with bone resorption and in odontoclasts associated with root resorption.<sup>59</sup> Furthermore, these investigators also demonstrated the presence of integrin in epithelial cell rests of Malassez in the PDL. Intracellularly, actin and vinculin microfilaments bind to the talin-integrin complex. These details provide an important insight into the mechanisms underlying alterations in shape of cells and ECM in response to either mechanical forces, cytokines, growth factors, or neurotransmitters, that lead to changes in the attachment apparatus and cellular phenotype expression.

#### Role of the extracellular matrix

The ECM is primarily a collection of fibrous proteins embedded in a hydrated polysaccharide gel.<sup>57</sup> This important tissue component mainly contains macromolecules such as collagen and glycosaminoglycans (GAGs), secreted at a local level by cells such as fibroblasts, osteoblasts, and chondroblasts. In the ECM, GAGs link to a protein with a covalent bond to form proteoglycans. The GAG and proteoglycan molecules make a gel-like ground substance, in which other fibers such as collagen are embedded. This gel allows diffusion of nutrients and hormones, whereas collagen strengthens the matrix. The roles of the ECM are to provide a physical framework for the cells that are responsible for its production and to function as a medium regulating cellular identity, position, proliferation, and fate. It has been reported that all connective tissues in the body undergo a constant remodeling by synthesizing and degrading the macromolecular components of their extracellular matrix.<sup>57</sup> The PDL is considered to be one of the most highly metabolically active tissues in the body. Sodek<sup>60</sup> reported, with the help of radio-labeling studies, that the half-life for turnover of mature collagen in the PDL was 2 days, compared with 5 days for the gingiva, 6 days for alveolar bone, and 15 days for skin.

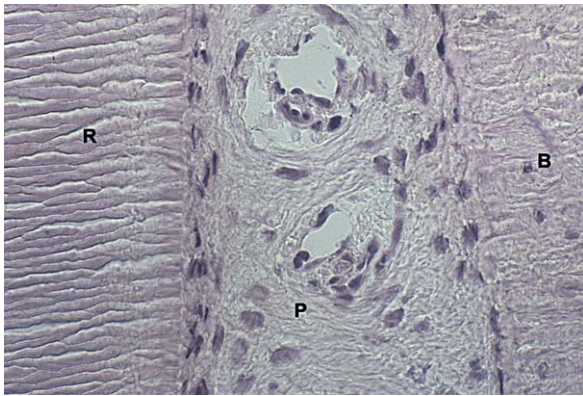
Remodeling of the ECM plays an integral part in orthodontic tooth movement with forces exerted on the tooth and transmitted to surrounding tissues of

the periodontium. It is well accepted that cells of the osteoblast lineage, which progress through maturational stages, accomplish bone formation. Proteins synthesized at the mineralization front, such as bone sialoprotein, have proposed roles in osteoblast attachment and in coordinating mineral deposition. The later expressed proteins, such as osteocalcin, have a possible role in preventing hypomineralization via interaction with osteopontin and osteoclast recruitment.<sup>61</sup> Immunolocalization studies recently suggested a profile change in PDL proteoglycans with an increase in immunodetection of chondroitin sulphate-6 epitopes near the compressive-side bone surface of tooth movement.<sup>62,63</sup> Many enzymes have been implicated in remodeling the ECM, including serine proteases, aspartate proteases, and cysteine proteases.<sup>58</sup> Recent reports have published data on matrix metalloproteinases (MMPs)—collagenases, gelatinases, stromelysin, and membrane-type matrix MMPs along with its inhibitor TIMP (tissue inhibitor of MMPs), suggesting that these enzymes play a major role in ECM remodeling.<sup>57,64-68</sup> Holliday et al<sup>66</sup> reported inhibition of tooth movement with TIMP, thereby providing proof for the mechanistic link between MMP activity and the production of RGD peptides.

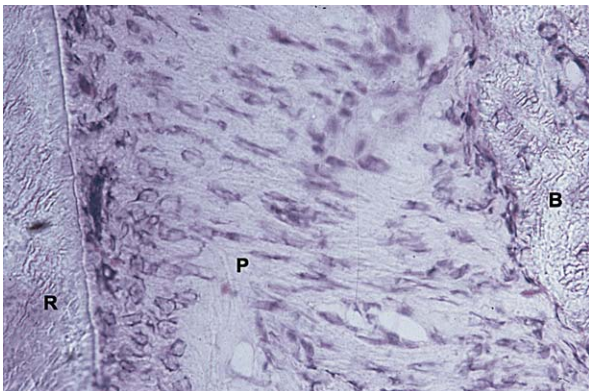
#### Molecules associated with mechanotransduction

The mechanism behind cellular reactions to mechanical forces is a matter of profound interest in the area of orthodontic tooth movement. Signal transduction can occur through receptors that constitute channels that traverse the plasma membrane. When interacting with a stimulus, these receptors are activated, and signals in the form of ion movement in or out of the cell produce changes in electric potential. These changes, in turn, enable the signal to be propagated intracellularly. The complexity of cell signaling is further modified by the physical linkage between cytoskeletal structures and the ECM, through cell adhesion molecules such as integrins. The strain produced by mechanical forces in the ECM causes a change in the cellular shape (Figs 10 and 11) and elicits release of signaling molecules from the affected cells. These molecules bind with cell adhesion complexes and start many cellular responses.<sup>56</sup>

Histochemical and immunohistochemical studies have demonstrated that, during the early phases of orthodontic tooth movement, PDL fluids are shifted, and cells and ECM are strained. In areas where tension or compression evolves under the influence of the orthodontic appliance, vasoactive neurotransmitters are released from distorted nerve terminals. In the PDL, most terminals are near blood-vessel walls. Therefore, the



**Fig 10.** Sagittal section, 6  $\mu\text{m}$  thick, of untreated maxillary canine of 1-year-old female cat (control). Section was stained with toluidine blue. *B*, alveolar bone; *R*, canine root; *P*, PDL. Cells populating bone and root surfaces appear rather flat; PDL cells are predominantly round; X 320.



**Fig 11.** Sagittal section, 6  $\mu\text{m}$  thick, of maxillary canine of 1-year-old female cat, that had been tipped distally for 12 hours with 80 g force (same animal as in Fig 10). Section was stained with toluidine blue. Tension area in PDL is shown. *B*, alveolar bone; *R*, canine root; *P*, PDL. Major change from Fig 10 (control) is elongated shape assumed by many PDL cells. Shape alteration is probably due to cells' attachment to stretched ECM fibers; X 320.

released neurotransmitters interact first with capillary endothelial cells. In response, the endothelial cells express receptors that bind circulating leukocytes, promoting their migration by diapedesis out of the capillaries. These migratory cells secrete many signal molecules, including cytokines and growth factors, some of which might be categorized as inflammatory mediators, that stimulate PDL and alveolar bone lining cells to remodel their ECM. This force-induced remodeling

facilitates movement of teeth to areas in which bone had been resorbed.<sup>3</sup>

Perhaps the most direct effect of orthodontic forces on paradental cells occurs at sites of focal adhesion. All paradental cells, with the exception of migratory leukocytes, must be attached to the ECM that surrounds them. This attachment is essential for cell survival. Orthodontic forces, which stretch or compress the PDL, have profound effects on cells in mechanically strained zones, as can be observed histologically. In such situations, cells in PDL tension sites become elongated as soon as the ECM to which they are attached is stretched. During this phase, their cytoskeleton transmits mechanical forces directly to the nucleus. However, the stretched cells continue to react by attempting to regain their normal, shorter shape. This goal is achieved by detachment and reattachment of the cells to their ECM. A similar reaction can be seen in PDL compression sites, where the cells assume a round shape in the first hours of treatment but regain a normal shape 2 or 3 days later. It can, therefore, be concluded that the ECM-attachment foci-cytoskeleton-nucleus combination, which acts in unison in handling mechanical loads, is the most powerful biological counterpart of the orthodontist. However, in the orthodontic patient, this force-sensitive mechanism can often be affected by factors such as neurotransmitters, cytokines, nutrients, and drugs. The extent of these interactions might vary among patients, and this biological variability is often reflected in the quality and pace of the treatment and its outcome.

#### SIGNALING MOLECULES INVOLVED IN LOAD-INDUCED TISSUE REMODELING Neurotransmitters

The relationship of nerves to tooth movement has been a matter of considerable research. The PDL is abundantly supplied with 2 kinds of nerve terminals: Ruffini-like endings and nociceptive endings.<sup>9</sup> Both endings can change their structures in response to external stimuli, such as orthodontic force.<sup>70,71</sup> It has been reported that the mechanoreceptors in the apical half of the dental root have a low threshold and respond to even minor stretching of the PDL.<sup>72</sup> In contrast, nociceptors have a high threshold and are activated by heavy forces, tissue injury, and inflammatory mediators. The force-sensing PDL nerve fibers are either unmyelinated C fibers or small myelinated A $\delta$  fibers.<sup>73</sup> The mechanoreceptors are silent in physiological conditions but contain various neuropeptides such as substance P, vasoactive intestinal polypeptide, and calcitonin gene-related peptide (CGRP).<sup>74</sup> These neuropeptides are routinely stored in peripheral and central nerve

terminals, and are released when these terminals are strained.

Orthodontic tooth movement affects the number, functional properties, and distribution of both mechanoinsensitive and nociceptive periodontal nerve fibers. Increased immunoreactivity of substance P has been demonstrated in the PDL in the early phases of tooth movement. This neuropeptide has been shown to cause vasodilatation and increased vascular permeability, contributing to increased local blood flow that accompanies inflammation.<sup>5</sup> It has been demonstrated by Davidovitch et al<sup>4</sup> that incubation of substance P with human PDL fibroblasts in vitro significantly increased the concentration of cAMP in the cells and of PGE<sub>2</sub> in the medium within 1 minute. Another neurotransmitter involved in orthodontic tooth movement is CGRP. Kvinnsland and Kvinnsland<sup>75</sup> localized CGRP in the PDL and the dental pulp during tooth movement in rats. They could detect an intensification of CGRP immunoreactivity after 3 days of molar movement in fibroblasts at PDL tension sites. Norevall et al<sup>76</sup> observed intense immunoreactivity for CGRP at PDL tension sites in cats 1 hour after the onset of treatment. Saito et al<sup>77</sup> reported finding intense reactivity to another neuropeptide, vasoactive intestinal polypeptide, in the compressed PDL and in the pulp of moving teeth in cats.

It has been proposed that vasoactive neurotransmitters released from PDL nerve terminals cause leukocytes to migrate out of the capillaries. The experiments conducted by Rygh and Selvig<sup>78</sup> and Storey<sup>10</sup> confirmed these findings in the early days of tooth movement. These cells, in addition to their participation in immune reactions (phagocytosis of necrotic tissues), also produce numerous signal molecules that perform various functions, from chemoattraction to stimulation of mitogenesis and cytodifferentiation. In addition to leukocytes, other PDL cell types, including osteoblasts, fibroblasts, epithelial cells, endothelial cells, and platelets, can also synthesize and secrete these molecules. The products of these cells can be classified into different categories, such as cytokines, growth factors, and colony-stimulating factors. Each of these ligands might act in an autocrine or a paracrine fashion, causing activation of target cells.<sup>5</sup>

### Pain and tooth movement

Tooth movement-associated tissue remodeling, an inflammatory process, might induce painful sensations, particularly after activation of the orthodontic appliance. After 24 hours of force application, C-fos (immunoreactive neurons known to be involved in transmission of nociceptive information) expression is noted

ipsilaterally in the trigeminal subnucleus caudalis and bilaterally in the lateral parabrachial nucleus. In a follow-up study, fos-like immunoreactive neurons were distributed in other brain regions such as the neocortex, dorsal raphe, and thalamic nucleus.<sup>79</sup> This finding indicates that nociceptive information by tooth movement is transmitted and modulated in several regions of the brain. These stimuli activate endogenous pain-control systems, including descending monoaminergic pathways.<sup>80</sup> Preliminary studies suggested that the nociception is modulated through serotonergic and dopaminergic systems.<sup>79</sup> But a subsequent experiment showed an increase in serotonin turnover in the medulla, indicating activation of the bulbospinal serotonergic pathway by nociceptive neurological response.<sup>80</sup> Thus, there appears to be an indirect nociceptive mechanism operating during tooth movement that evokes a delayed and continuous nociceptive response, which is expected to limit masticatory function during active tooth movement.

A recent report published data on administration of MK-801 (a noncompetitive antagonist of N-methyl-D-aspartate receptors), intraperitoneally before tooth movement in rats. The results suggest a blockade of N-methyl-D-aspartate receptors along with neuronal suppression of trigeminal sensory nuclear complex. These effects were found to increase the neuronal activity in the descending antinociceptive system, including nuclear raphe magnus, ventrolateral PAG, dorsal raphe nucleus, and Edinger-Westphal nucleus. These results indicate a pharmacological way to decrease pain perception during orthodontic tooth movement.<sup>81</sup>

### Cytokines in orthodontic tooth movement

Cytokines are extracellular signaling proteins that act on nearby target cells in low concentrations in an autocrine or paracrine fashion in cell-to-cell communications. Cytokines that were found to affect bone metabolism, and thereby orthodontic tooth movement, include interleukin 1 (IL-1), interleukin 2 (IL-2), interleukin 3 (IL-3), interleukin 6 (IL-6), interleukin 8 (IL-8), tumor necrosis factor alpha (TNF $\alpha$ ), gamma interferon (IFN $\gamma$ ), and osteoclast differentiation factor (ODF). The most potent among these is IL-1, which directly stimulates osteoclast function through IL-1 type 1 receptor, expressed by osteoclasts. Secretion of IL-1 is triggered by various stimuli, including neurotransmitters, bacterial products, other cytokines, and mechanical forces.<sup>5</sup> IL-1 has 2 forms— $\alpha$  and  $\beta$ —that code different genes. These interleukins have been reported to have similar biologic actions, systemically and locally. These actions include attracting leukocytes and stimulating fibroblasts, endothelial cells, os-

teoclasts, and osteoblasts to promote bone resorption and inhibit bone formation.<sup>82</sup> Osteoblasts are target cells for IL-1, which in turn conveys messages to osteoclasts to resorb bone.<sup>5</sup> Tuncer et al<sup>83</sup> reported increased levels of IL-8 at PDL tension sites and proposed it to be a triggering factor for bone remodeling.

TNF $\alpha$ , another pro-inflammatory cytokine, was shown to elicit acute or chronic inflammation and stimulate bone resorption. Recent studies<sup>4,84-86</sup> have shown that TNF $\alpha$  directly stimulates the differentiation of osteoclast progenitors to osteoclasts in the presence of macrophage colony-stimulating factor (M-CSF). Davidovitch et al<sup>4</sup> and Saito et al<sup>84</sup> demonstrated marked increases in the staining intensity for IL-1 and TNF $\alpha$  in cells of the PDL and alveolar bone during orthodontic tooth movement in cats.

Recent research by Alhashimi et al<sup>85,86</sup> focused on the role of IFN $\gamma$  during bone remodeling as part of orthodontic tooth movement. IFN $\gamma$  is better known as a potent inducer of major histocompatibility complex antigens in macrophages, which is an early marker of immune activation during inflammation. It also evokes the synthesis of other cytokines, such as IL-1 and TNF $\alpha$ . These cytokines were shown to induce production of nitric oxide, a potentially important osteoblast-osteoclast coupling factor. Alhashimi et al<sup>86</sup> reported that, during orthodontic treatment, IFN $\gamma$  can cause bone resorption by apoptosis of effector T-cells.

The role of cytokines of the RANKL/RANK/OPG system in inducing bone remodeling was demonstrated recently.<sup>87</sup> The TNF-related ligand RANKL (receptor activator of nuclear factor-Kappa ligand) and its 2 receptors, RANK and osteoprotegrin (OPG), have been shown to be involved in this remodeling process. RANKL is a downstream regulator of osteoclast formation and activation, through which many hormones and cytokines produce their osteoresorptive effect. In the bone system, RANKL is expressed on osteoblast cell lineage and exerts its effect by binding the RANK receptor on osteoclast lineage cells. This binding leads to rapid differentiation of hematopoietic osteoclast precursors to mature osteoclasts. OPG is a decoy receptor produced by osteoblastic cells, which compete with RANK for RANKL binding. The biologic effects of OPG on bone cells include inhibition of terminal stages of osteoclast differentiation, suppression of activation of matrix osteoclasts, and induction of apoptosis. Thus, bone remodeling is controlled by a balance between RANK-RANKL binding and OPG production. It has been suggested that OPG exists in both membrane-bound and soluble forms, and that its expression is up-regulated by CD40 stimulation. CD40 is a cell surface receptor that belongs to the tumor necrosis

factor (TNF) receptor family.<sup>88</sup> It can be seen in a variety of cells, such as B-lymphocytes, monocytes, dendrite cells, IL-6- and IL-8-secreting cells, such as endothelial cells, basophils, epithelial cells, and fibroblasts. It was found recently that CD40-CD40L (cellular responses mediated by CD40 are triggered by its counter receptor CD40L, which also belongs to the TNF gene family) interaction appears to be an active process during orthodontic tooth movement and that orthodontic force induces T-cell activation.<sup>89</sup> Such activation might be involved in the induction of inflammatory mediators and subsequent bone remodeling. Kanzaki et al<sup>90</sup> reported recently that OPG gene transfer to periodontal tissues inhibited RANKL-mediated osteoclastogenesis and inhibited experimental tooth movement in rats. The number of reports cited above makes it clear that bone remodeling, particularly bone resorption, is regulated by cytokines released in response to the orthodontic force.

### **Growth factors**

Bone contains abundant amounts of transforming growth factor  $\beta$  (TGF $\beta$ ), which includes TGF $\beta$ 1, activins, inhibins, and bone morphogenetic protein.<sup>91</sup> This small polypeptide is produced by several cell types, such as fibroblasts and osteoblasts, and is deposited in the ECM in a latent form. The richest sources of TGF $\beta$  are platelets and bone, and it attracts monocytes and fibroblasts, and stimulates angiogenesis *in vitro*.<sup>92</sup> These factors are involved in many biologic activities, including cell growth, differentiation, and apoptosis, as well as in developmental processes and bone remodeling.<sup>5</sup> TGF $\beta$  has been shown to enhance osteoclast differentiation in haemopoietic cells stimulated with RANKL and M-CSF.<sup>93</sup> More recently, a family of signal transducer proteins has been identified, presenting a mechanism through which TGF $\beta$  (specifically bone morphogenetic proteins) can signal from the cell membrane to the nucleus.<sup>94</sup> The signal transducer protein families are phosphorylated by cell surface receptors with serine/threonine kinase activity and in this state translocate to the nucleus. Then, inside the nucleus, the transcription factors produce cellular responses to TGF $\beta$ .<sup>95</sup> Isoforms of TGF $\beta$  (TGF $\beta$ <sub>1</sub>,  $\beta$ <sub>2</sub>, and  $\beta$ <sub>3</sub>), which are in latent form, are abundant in bone matrix. ten Dijke et al<sup>96</sup> demonstrated increased DNA synthesis by these 3 isoforms in osteoblast-rich cultures in fetal rats. These isoforms are also shown to enhance synthesis of collagen and noncollagenous proteins. Davidovitch et al<sup>5</sup> demonstrated TGF $\beta$ <sub>1</sub> immunoreactivity in cat PDL cells and alveolar bone osteoblasts during orthodontic tooth movement. They reported that enhancement can occur as early as 1 hour after force

application. The unstressed PDL and alveolar bone show negative or no staining for TGF $\beta$ .

The functions of 2 other growth factors—fibroblast growth factor (FGF) and insulin-like growth factor (IGF)—are similar.<sup>5</sup> The target cells of FGFs include fibroblasts, endothelial cells, myoblasts, chondrocytes, and osteoblasts. Two forms of FGF were demonstrated:  $\alpha$ FGF (acidic PI) and  $\beta$ FGF (basic PI). Since  $\alpha$ FGF and  $\beta$ FGF lack a signal sequence, they are sequestered in the cells responsible for their synthesis and are released only when there is a disruption of the plasma membrane. A recent report discussed plasma membrane disruption in PDL tension sites after orthodontic force application. This effect, demonstrated with the help of albumin uptake by PDL cells, suggests that plasma membrane disruption could promote uptake and release of large signaling molecules.<sup>97</sup> Globus et al<sup>98</sup> reported that bone cells can synthesize  $\beta$ FGF and secrete it into the surrounding ECM, where it might act as an autocrine or a paracrine signal. Noff et al<sup>99</sup> demonstrated increased DNA synthesis, alkaline phosphatase activity, and formation of bone-like nodules, when rat bone marrow cells were treated with  $\beta$ FGF in vitro.

IGF I and II might also be of relevance during tooth movement. This family of polypeptides promotes cell proliferation and differentiation, and has insulin-like metabolic effects. The liver is the main organ producing IGF I in humans and rodents, and its production is modulated by several factors, such as growth hormones, estrogen, and insulin, and also by fasting.<sup>5</sup> The IGF type I receptor is structurally similar to the insulin receptor, a trans-membrane glycoprotein with an extracellular ligand binding domain and a cytoplasmic portion with tyrosine kinase activity. However, IGF type II receptors are identical to the cation independent mannose 6-phosphate receptor, which functions as a lysosomal enzyme targeting protein.<sup>100</sup> In bone cells, the action of IGF I is regulated by various systemic and local factors, including growth hormone, PTH, vitamin D3, corticosteroids, TGF $\beta$ , IL 1, and platelet-derived growth factor (PDGF). It has been shown that IGF I, when added to PDL cells in culture, causes a dose-related increase in DNA synthesis.<sup>101</sup> The evidence is also increasing regarding the role of IGF II in fibroblasts, where it influences both calcium influx and DNA synthesis. Coxam et al,<sup>102</sup> in experiments in newborn lambs, demonstrated a direct stimulation of osteoblastic function, by injection of IGF II intravenously. The action was mediated through rapid and sustained release of osteocalcin. It has been proven that PTH and its related peptide enhance IGF I action.<sup>100</sup>

Each time mechanical damage to the periodontal vasculature is created by orthodontic force, platelets migrate from the blood vessels to the extravascular space. These platelets are a major source of growth factors for mesenchymal cells, in the form of PDGF.<sup>103</sup> Originally, PDGF was isolated from platelets, but it was later found to be synthesized by various cell types. Two distinct types of PDGF receptors have been identified, the  $\alpha$  receptor (which binds all 3 isoforms, PDGF AA, PDGF AB, and PDGF BB), and the  $\beta$  receptor (which binds to only PDGF BB). The 2 receptors are similar in structure, with an extracellular ligand-binding portion, a single transmembrane anchoring domain, and a highly conserved intracellular protein, tyrosine kinase. When PDGF binds to the extracellular portion, the receptor undergoes dimerization and autophosphorylation with activation of tyrosine kinases.<sup>56</sup> The ligand-receptor complex is then internalized and degraded, leading to (1) activation of phospholipase A<sub>2</sub>-release of arachidonic acid, which, via cyclooxygenase and lipooxygenase activity, leads to formation of prostaglandins and leucotriens; (2) activation of phospholipase-C $\gamma$  through a G-protein, with degradation of PIP2 and formation of IP3 and DAG; and (3) recruitment of substrate proteins to an oligomerized growth factor receptor, with increased tyrosine kinase activity.<sup>104</sup> The proteins include PI3 kinase, Ras-GAP, and PLC- $\gamma$ . Davidai et al<sup>105</sup> and Sandy et al,<sup>106</sup> with different experiments, proposed this pathway to be important in mitogenesis in bone cells. They reached this conclusion by observing that inhibitors of tyrosine kinases can block PDGF-stimulated cell proliferation and receptor phosphorylation.

Connective tissue growth factor (CTGF) is another secreted protein that is associated with the ECM during anabolic bone remodeling.<sup>107</sup> This signal molecule enhances vascular invasion, stimulates proliferation of osteoblast precursors, and promotes mineralization of new bone by osteoblasts. In alveolar bone, CTGF is localized in osteoblasts and osteocytes near the PDL. After 12 hours of experimental tooth movement, CTGF is expressed in osteoblasts and extends to osteocytes deep in the bone on both sides of the moving root.<sup>108</sup>

### Colony-stimulating factors

Colony-stimulating factors (CSF) include those related to granulocytes (G-CSF), macrophages (M-CSF), or to both cell types (GM-CSF), and might have particular implication in bone remodeling through osteoclast formation and thereby during tooth movement.<sup>5</sup> These molecules are specific glycoproteins, which interact to regulate the production, maturation, and function of granulocytes and monocyte-macrophages. Fibroblasts and endothelial

cells synthesize M-CSF. It was demonstrated by Kahn and Simmons<sup>109</sup> that osteoclasts can form as a result of culturing bone-marrow cells with M-CSF for 10 days. It has also been demonstrated that stimulation of fibroblasts with epidermal growth factor, PDGF, FGF, and IL-1 induce M-CSF expression by these cells.<sup>110</sup> Takahashi et al<sup>111</sup> reported that, in terms of potency, M-CSF is the most potent in stimulating bone-marrow cells to produce osteoclasts, followed by GM-CSF, IL-3, and G-CSF.

The above review of signal molecules that modulate various steps of tissue remodeling introduces the orthodontist to the complexity and minute details of events that appear to have major roles in this process. Prominent participants are products of the nervous, immune, and endocrine systems, but many locally produced growth factors and CSF appear also to participate actively in remodeling mineralized and nonmineralized connective tissues. Clinically, orthodontic patients might sense pain shortly after appliance activation. However, this feeling is just one of many reactions on the cellular and molecular levels that typifies orthodontic tissue remodeling.

### Genetic mechanisms

Mechanical activation of bone cells is linked to many genes, which produce various enzymes, such as glutamate/aspartate transporter, inducible nitric oxide synthase, and prostaglandin G/H synthetase.<sup>112</sup> In-situ hybridization under conditions of physiologic tooth movement in rats showed site-specific expression of mRNA for osteonectin, osteocalcin, and osteopontin. Osteoclast and osteoblast progenitor cells had positive signals for osteonectin and osteocalcin. Osteopontin was expressed in osteoblasts and adjacent osteocytes along bone-resorbing surfaces. In response to orthodontic force, osteopontin mRNA was elevated in the tissue by 12 hours, and this response was found to persist after 48 hours.<sup>79,113</sup> It was proposed recently that at least 26 genes are involved in osteoclast differentiation and regulation, including tyrosine kinase gene, M-CSF, C-fos, Pu.1, and NF- $\kappa$ B (osteoclast formation), and C-tyrosine kinase and microphthalmia transcription factor in osteoclast activity.<sup>114</sup> The role of the RANK-RANKL-OPG axis in bone remodeling was discussed in the previous section.<sup>87</sup> Kanzaki et al<sup>115</sup> observed an increase in RANKL mRNA expression in the PDL after exogenous PGE2 treatment and concluded that, in mechanically stressed PDL cells, RANKL up-regulation depended on PGE2. In addition, another gene, TREM-2 of TNF, has been implicated in the control of bone modeling and brain function.<sup>116</sup> Wilde et al<sup>117</sup> demonstrated periostin (a 90 kDa protein), showing a divergent expression pattern in PDL fibroblasts and

osteoblastic cells in alveolar bone surfaces, even after 168 hours of tooth movement.

Pavlin and Gluhak-Heinrich<sup>118</sup> used a mouse model to study the mechanically induced regulation of osteoblast- and cementoblast-associated genes. They demonstrated a defined temporal pattern of cell-specific gene regulation in periodontal osteoblasts, mechanically stimulated to differentiate and deposit bone matrix. According to these investigators, the primary responses to osteogenic loading are induction of differentiation and increased cell function, rather than an increase in cell numbers. They detected alkaline phosphatase and bone sialoprotein genes after 24 hours of treatment, followed by a concomitant stimulation of osteocalcin and collagen I between 24 and 48 hours, and deposition of osteoid after 72 hours. They reported that differential genetic responses to mechanical loading provide functional markers for a distinction between the cementoblast and osteoblast phenotypes.

Recent research has thus begun to unveil the identity of genes that control the synthesis of specific cellular and ECM components during tissue remodeling in response to mechanical loads. Continuous research in molecular genetics might identify additional genes that are activated by applied loads, leading ultimately to the development of new diagnostic, predictive, and therapeutic means in clinical orthodontics.

### PATHWAYS OF TOOTH MOVEMENT

On the basis of research in basic biology and clinical observations, Mostafa et al<sup>22</sup> proposed an integrated hypothetical model for tooth movement. This model consists of 2 pathways—I and II—that work concurrently to induce tooth movement. According to these authors, pathway I represents the more physiologic response, because it is usually associated with normal bone growth and remodeling, whereas pathway II represents the generation of a local inflammatory response by orthodontic forces.

#### Pathway I

In pathway I, orthodontic force creates vectors of pressure and tension, leading to bone bending, generation of tissue bioelectric polarization, and subsequent bone remodeling. With the circumstantial evidence of prostaglandin synthesis, and with the evoked electric signals, Mostafa et al<sup>22</sup> stated that these phenomena, along with membrane electrical polarization by piezoelectric processes, act on the cell surface cyclic nucleotide pathway, generating changes in the levels of intracellular second messengers. This effect, in turn, leads to alterations in cell proliferation, differentiation, and activation.

This pathway also describes the direction or the control of tooth movement with the help of charge differences between the concave and convex sides of the strained alveolar bone. This matrix charge polarizations—electrically neutral or positive areas—promote osteoclast activity, whereas electronegativity supporting osteoblastic activity might change cell membrane polarization, leading to alterations in cAMP levels.

### Pathway II

The alternative pathway proposed by Mostafa et al<sup>22</sup> attributes orthodontic tooth movement to a classic inflammatory response after force application. Orthodontic forces, along with increased vascular permeability and cellular infiltration, trigger inflammatory processes in the involved dental and paradental tissues. Lymphocytes, monocytes, and macrophages invade these tissues, enhancing prostaglandin release and hydrolytic enzyme secretion. The local elevation in prostaglandins and a subsequent increase in cellular cAMP concentrations increase osteoclast activity. Secreted hydrolytic enzymes, such as collagenase, dissolve the mechanically strained ECM.

### Recent model

Recent reports by Jones et al<sup>119,120</sup> detailed events in bone cells immediately after the application of mechanical stress. That report is based on the assumption that stress in any form—compressive, tensile, or shear—will evoke many reactions in the cell, leading to the development of strain. In osteoblasts, the first measured responses to physiologic levels of stress are increases in intracellular free calcium and membrane potential through activation of K<sup>+</sup> channels. This increase in calcium concentration is related to the activation of phospholipase C, which releases inositol triphosphate within 10 seconds. Elevated levels of phospholipase C maintain the high calcium concentration throughout stress application by keeping the mechanosensitive ion channels open and by further activation of protein kinase C through diacylglycerol after 3 to 4 minutes of force application. Phospholipase A is activated; it acts on stores of arachidonic acid, leading to detection of prostaglandins in the culture medium after about 10 minutes. This event is followed by the release of products of the lipoxygenase pathway (leucotriens and hydroxyeicosatetraenoic acids), followed by an elevation in the concentration of cAMP. The phosphorylation reactions mediated by this cyclic nucleotide in the nucleus and the cytoplasm lead to cellular synthetic and secretory activities.

A synthesis of the above discussions leads to the definitive conclusion that inflammation of paradental

tissues occurs every time they are exposed to an orthodontic force, whether the magnitude is light or heavy. The sequence of events after the application of mechanical forces with the help of orthodontic appliances can thus be outlined as:

- Movement of PDL fluids from areas of compression into areas of tension.
- A gradual development of strain in cells and ECM in involved paradental tissues.
- Direct transduction of mechanical forces to the nucleus of strained cells through the cytoskeleton, leading to activation of specific genes.
- Release of neuropeptides (nociceptive and vasoactive) from paradental afferent nerve endings.
- Interaction of vasoactive neuropeptides with endothelial cells in strained paradental tissues.
- Adhesion of circulating leukocyte to activated endothelial cells.
- Plasma extravasation from dilated blood vessels.
- Migration by diapedesis of leukocytes into the extravascular space.
- Synthesis and release of signal molecules (cytokines, growth factors, and CSFs) by the leukocytes that have migrated into the strained paradental tissues.
- Interaction of various types of paradental cells with the signal molecules released by the migratory leukocytes.
- Activation of the cells to participate in the modeling and remodeling of the paradental tissues.

### BEHAVIOR OF ORAL SOFT AND HARD TISSUES IN RESPONSE TO ORTHODONTIC FORCE

#### Bone remodeling and tooth movement

Bone resorption is crucial to orthodontic treatment, by removing alveolar bone from the path of the moving dental root. In this cell-mediated process, the appearance of osteoclasts is considered to be the requisite first step. However, it is unclear whether these cells arise from activation of mature osteoclasts already in the PDL or from the proliferation of stem cells in remote or local hemopoietic tissues.<sup>121</sup> Research on rat PDL has shown it to be virtually devoid of mature osteoclasts in physiologic conditions. However, when orthodontic force is applied, osteoclasts appear within days.<sup>122</sup> According to the widely accepted hypothesis by Mundy and Roodman,<sup>123</sup> osteoclasts are derived from stem cells in haemopoietic organs, and granulocyte-macrophage colony-forming units are the earliest identifiable precursors of osteoclasts. The proposed pathway can be outlined as follows: granulocyte-macrophage colony-forming units—promonocyte—early preosteoclast—late preosteoclast—osteoclast.

Several lines of evidence exist for the fact that the immediate precursors of osteoclasts—the late preosteoclasts—are present in the PDL and are activated or transformed to mature osteoclasts after orthodontic mechanotherapy. Roberts and Ferguson<sup>122</sup> found that osteoclast numbers per unit bone surface area show a peak level about 50 hours after orthodontic force application. Additionally, new osteoclasts reach the PDL from haemopoietic organs via the blood circulation, and from alveolar bone marrow cavities, during the orthodontic treatment period, which can last 2 to 3 years.

The bone-resorption cascade involves a series of steps directed toward removing both the mineral and the organic constituents of bone matrix by osteoclasts.<sup>124</sup> After the differentiation of osteoclasts, the unmineralized osteoid layer in the bone surface is removed by the lining osteoblasts. These cells produce various enzymes such as MMPs, collagenases, and gelatinases that help osteoclasts in accessing the underlying, mineralized bone.<sup>125</sup> The next step is osteoclast polarization by attaching itself to specific extracellular bone matrix proteins, such as osteopontin, through RGD sites provided by cell adhesion molecules. The polarization process involves formation of ruffled borders and clear zones, the 2 most characteristic features of osteoclasts.<sup>126</sup> The clear zone is an organelle-free region in the cytoplasm, which is rich in F-actin filaments. These structures, along with integrin receptors and RGD-containing extracellular proteins from focal adhesions or podosomes, are responsible for tight cell-to-cell substratum interactions. These clear zones provide a seal at the external space beneath the cell, where the ruffled border spreads and bone matrix dissolution occurs. This extracellular space is called the resorbing component or resorption lacunae.

The next step is osteoclast activation by local and systemic factors, and production of hydrogen ions (that dissolve the mineral) and proteolytic enzymes (that degrade the organic matrix) in the hemivacuole (localized environment) under the ruffled border of the cell.<sup>127</sup> In addition to this classic concept, recent findings have proposed a new concept, in which osteoblasts can activate osteoclasts through cell-to-cell contacts.<sup>128</sup> The osteoclasts thus activated produce hydrogen ions and proteolytic enzymes in the ruffled border of the cell. It has been proposed that these hydrogen ions are generated in the cell by the enzyme carbonic anhydrase, present in the cytoplasm close to the ruffled border.<sup>129</sup>

Degradation of the collagenous organic matrix follows the dissolution of the mineralized matrix and mainly involves 2 major classes of enzymes—lysosomal cysteine proteinases (cathepsin B, L, and K) and

MMPs, including collagenase and gelatinase B.<sup>124</sup> Osteoclasts ultimately undergo apoptosis, characterized by nuclear and cytoplasmic condensation, and fragmentation of nuclear DNA into nucleosomal sized units.<sup>130</sup> Roodman<sup>126</sup> suggested that TGF $\beta$ , which blocks bone resorption, can induce apoptosis of osteoclasts, whereas osteoclast-stimulating factors, such as PTH and vitamin D<sub>3</sub>, inhibit osteoclast apoptosis. The progression of bone remodeling requires continual addition of osteoclasts, because they have only a limited life span—less than 12.5 days.<sup>126</sup> Kobayashi et al<sup>131</sup> investigated the mechanism controlling the disappearance of osteoclasts from bone surfaces after bone resorption and observed a marked increase in TGF beta 1 and OPG mRNA simultaneously with the disappearance of osteoclasts, suggesting a sequential link in tensional force applied to bone lining cells, up-regulation of TGF-beta1/OPG, and the disappearance of osteoclasts.

Once the osteoclasts finish their work of bone removal, there is a “reversal phase,” when mononuclear cells, which might be of macrophage lineage, are seen on the bone surface. The events during this stage are not clearly understood but might involve further degradation of collagen, deposition of proteoglycans to form the so-called “cement line,” and release of growth factors to initiate the formation phase.<sup>132</sup> The end of bone resorption and the start of bone formation occurs through a coupling mechanism, which ensures that an equivalent amount of bone is laid down after the previous resorption phase. Whether activation of osteoblasts begins simultaneously with osteoclast recruitment or at a later stage during lacunar development is still controversial. It has been proposed that some growth factors and proteinases—TGF $\beta$ , IGF I and II, and plasminogen activators—play a major role in this coupling mechanism.<sup>124</sup>

Bone formation results from complex events that involve differentiation of osteoblast precursor cells from primitive mesenchymal cells, maturation of osteoblasts, and matrix formation, followed by its mineralization.<sup>123</sup> The initial event in this appositional phase consists of chemoattraction of osteoblasts or their precursors to the site of bone formation. The osteoblasts that converge at the bottom of a resorptive cavity form osteoid matrix, which mineralizes after 13 days at an initial rate of less than 1  $\mu$ m per day. The osteoblasts continue to lay down and mineralize osteoid until the defect is filled.<sup>133</sup> At the bottom of the cavity, osteoblasts are plump and vigorous, have tall nuclei, and make a thick layer of osteoid. The cells gradually flatten and become quiescent lining cells, and some become embedded in the newly formed matrix.<sup>124</sup> Osteoblasts that become surrounded by calcified matrix

and remain in the lacunae of bone are known as osteocytes. Osteocytes connect with each other by narrow processes, located in canaliculi throughout the bone matrix. They lose their alkaline phosphatase activity but maintain high levels of calcium. These cells are thought to be critical for maintaining fluid flow through bone, and any change in fluid flow might provide signals that are transmitted to osteoblasts, which then carry out modeling and remodeling activities.<sup>134</sup> Bozal et al<sup>135</sup> evaluated the response of osteocytes when subjected to inflammatory and mechanical stimuli and observed an enlargement in osteocytic lacunae without changes in cell volume. It was reported recently that there is a transient increase in immunoreactivity of dentin matrix protein 1, which is mainly observed in osteoblasts and osteocytes) after 7 days of mechanical loading in mouse alveolar bone.<sup>136</sup> These observations imply that this protein is involved in the responses of osteoblasts and osteocytes to mechanical loading. This finding supports the hypothesis that osteocytes alter their matrix microenvironment in response to mechanical loading.<sup>136</sup> The factors, systemic and local, affecting the remodeling process are listed in the [Table](#).

Tissue reaction to orthodontic tooth movement occurs either through bone or with bone.<sup>25</sup> Indirect and undermining bone resorption characterizes tooth movement through bone. During these types of alveolar bone resorption, little formative activity takes place at PDL tension sites, because only minor displacement of the tooth occurs initially. Simultaneously, necrosis occurs at PDL compression zones, triggering indirect and undermining resorption. When this resorptive activity reaches the PDL and hyalinized tissues are removed, the tooth begins its displacement and becomes mobile because of the widened PDL. At this point, apposition rates are markedly increased at PDL tension sites, followed by either renewed hyalinization or continuation of tooth movement through direct bone resorption. When teeth are moved with bone, resorption takes place directly on the wall of the alveolus. In this case, the activity of osteoclasts and osteoblasts is synchronized. The width of the PDL is maintained throughout the consecutive phases of tooth movement, and the tooth moves along with its alveolus.<sup>5</sup> It has been suggested that, in addition to cell-mediated activities that affect alveolar bone under mechanical stress, this bone can develop microcracks. A recent study evaluated microcracks as a trigger for alveolar bone remodeling after orthodontic force application in pigs. An increased presence of microcracks was found toward the direction in which the tooth had been moved; this suggested that it represents the first damage induced by

**Table.** Factors affecting bone-remodeling process

Hormones	Polypeptides Parathyroid hormones Calcitonin Insulin Growth hormone Steroid 1,25, dihydroxy vitamin D <sub>3</sub> Glucocorticoids Sex steroids Thyroid hormones
Growth factors	Insulin-like growth factors I & II Transforming growth factor $\beta$ Fibroblast growth factor Platelet derived growth factor Connective tissue growth factors
Cytokines	Bone loss Interleukin-1 Interleukin-6 Interleukin-11 Tumor necrosis factor Osteoclast differentiating factor Bone formation Interleukin-4 Interleukin-13 Interleukin-18 Interferon- $\gamma$ Osteoprotegrin
Colony-stimulating factors	M-CSF G-CSF GM-CSF
Others	Prostaglandins Leukotriens Nitric oxide

orthodontic force to the bone that must be remodeled.<sup>137</sup>

### PDL remodeling during tooth movement

PDL and alveolar bone cells are exposed to physical forces in vivo in response to mastication, para function, and orthodontic tooth movement.<sup>138</sup> Orthodontic forces induce remodeling of PDL and gingival connective tissue matrices. Rygh and Brudvik<sup>2</sup> described histologic and histochemical reactions in the rat PDL after the application of orthodontic force. Widening of the PDL was observed in tension sites; the tooth had been drawn away from the alveolar bone. In the stretched PDL, several cellular processes are apparently activated, along with an increase in the number of connective tissue cells. This initial phase is followed by deposition of osteoid tissue at the edge of the socket wall. The blood vessels in the PDL tension site become distended, and fibroblasts are rearranged in the direction of strain. The stretched fibroblasts appear spindle-shaped in the middle of the PDL and spherical near the alveolar bone. Findings by Garant and Cho<sup>139</sup> suggest

that these fibroblasts secrete new Sharpey's fibers in the PDL simultaneously with the deposition of a new matrix on the adjacent alveolar bone socket wall. Part of these newly synthesized collagen fibers are incorporated in the newly formed osteoid, whereas the other part is embedded in the PDL. Lengthening of fibers seems to occur by incorporation of new fibrils to existing ones.

Rygh and Brudvik<sup>2</sup> observed a great increase in vascularity in areas of PDL tension, as indicated by an increase in the space occupied by blood vessels in histologic sections of rodent jaws. Transmission electron microscopic (TEM) studies permitted identification of many cells paravascularly, concomitant with the vascular infiltration. Macrophages and leukocytes, along with proteins and fluids, seemed to have migrated from PDL capillaries. These cells are known to be able to produce various signaling molecules that participate in force-induced tissue remodeling. The pain that is expressed when the PDL is overstressed is considered to be the body's effort to counteract noxious stimuli by limiting function. This reduced function helps to repair and replace damaged tissue. Beyond a certain level of stress, the vascular supply to the PDL decreases, with cell death occurring between stretched fibers.

On the pressure side, toward which the tooth is being moved, there is narrowing of the PDL space and deformation of the alveolar crest bone. Depending on the magnitude of applied force, the reaction at this site differs; light pressure produces direct bone resorption and heavy forces produce hyalinization. In rats, a few hours after orthodontic force application, osteoclasts appear in the PDL along the alveolar bone surface, evidenced by positive TRAP staining.<sup>130,140,141</sup> With electron microscope studies, ruffled borders of osteoclasts were seen to be in close contact with the resorbing bone surface.<sup>2,130,142,143</sup> Garant<sup>144</sup> observed fibroblasts with increased amounts of intracellular collagen profiles near osteoclasts. It is evident that there is extensive remodeling of collagen throughout the PDL, along with new collagen formation and attachment to alveolar bone through localized bone apposition. Increased pressure in a localized region of the PDL can inhibit differentiation of osteoclasts.<sup>145</sup> Instead, a series of degenerative tissue reactions takes place, known as hyalinization.<sup>2,145</sup>

Tissue changes in the compressed PDL are characterized by edema, gradual obliteration of blood vessels, and breakdown of the walls of veins, followed by leakage of blood constituents into the extravascular space. Changes seen in fibroblasts at these sites are moderate swelling of the endoplasmic reticulum, formation of vacuoles, and rupture and loss of cytoplasm.

This disintegration leaves isolated nuclei, which undergo lysis over a period of several weeks. As long as the ground substance remains in the PDL, the tissue has a glossy appearance. The degenerative process is maintained as long as the pressure persists. With time, accumulated erythrocyte breakdown products in pressure regions might undergo crystallization.<sup>78</sup> No tooth movement occurs until the necrotic tissue is removed by the invasion of phagocytosing cells from peripheral undamaged ligament and bone marrow spaces. This removal is completed after 3 to 5 weeks, and the posthyalinized PDL is markedly wider than before treatment, perhaps to withstand greater mechanical influences.<sup>2,145</sup> A recent article by Attal et al<sup>146</sup> reported that the periodontal vasculature showed similar changes in pressure and tension areas, but large-diameter vessels are unaffected by mechanical loading. They found a significant decrease in the mean number of terminal arterioles, whereas there was an increase in capillary and postcapillary venules in the apical part of the tooth. These vascular changes persisted even 12 weeks after the removal of orthodontic force, suggesting a rebounding effect.

It is clear from this discussion that, as long as ankylosis does not occur, the general trend after force application is preservation of the width of the PDL, a remarkable process involving precisely controlled osteogenic resorption and deposition at specific sites in the paradental tissues. Conclusions from recent studies showed that the PDL might be both the medium of force transfer and the means by which alveolar bone remodels in response to applied forces.<sup>137</sup> Howard et al<sup>147</sup> found that mechanical force could induce fibronectin and collagen synthesis by PDL cells in a strain magnitude-dependent fashion. Current evidence suggests the presence of mechanosensory signaling systems, including adenylyl cyclase stretch-activated ion channels and changes in cytoskeletal organization in response to mechanical forces.<sup>48,56-59</sup>

The PDL is abundantly supplied with 2 kinds of receptors: Ruffini-like endings and free nerve endings.<sup>69</sup> These receptors play key roles in changing the PDL's structure and cellular functions in response to mechanical loads, such as those applied in orthodontics.<sup>70</sup> The most rapid response of PDL fibroblasts to mechanical forces involves elevation of the concentration of intracellular calcium ions, and changes in actin filament polymerization. The influx of calcium ions can then strongly induce other effectors, including the proteins that regulate the cytoskeleton.<sup>148,149</sup> Redlich et al<sup>150</sup> reported on a significant time-dependent up-regulation of tropoelastin gene after external pressure

simulating orthodontic force in cultured human PDL fibroblasts.

Long-term responses to in-vitro mechanical loading can include stimulation of cell division, which will lead to increased collagen synthesis, and stimulation of alkaline phosphatase activity as force-induced downstream changes.<sup>151</sup> Recent studies demonstrated enhancement of nitric oxide synthase production after mechanical force application in animals<sup>152-155</sup> and humans.<sup>156</sup> This immunohistochemical finding suggests that nitric oxide might be a key regulator of orthodontic tooth movement by regulating the functions of osteoblasts and osteoclasts, and thereby modulating bone metabolism.<sup>156</sup> Takahashi et al<sup>67</sup> demonstrated differential regulation of the expression of MMP-8 and MMP-13 genes, and concluded that this dichotomy could play an important role in defining the specific characteristics of PDL remodeling. Current research in this area is directed toward studying signaling mechanisms evoked through mechanotransduction and determining the nature of mechanosensors in PDL and bone cells.

#### **Gingival effects of orthodontic force**

The cellular and extracellular changes in the PDL, alveolar bone, and cementum after orthodontic force application have been extensively investigated. Although gingival changes have also been found to be important in the overall response, they have attracted only minimal attention. A recent review outlined various changes in the gingiva in response to orthodontic force application.<sup>157</sup> Accordingly, 2 disparate processes occur in the gingiva after transduction of orthodontic force. First, there is an injury of the gingival connective tissue, manifested by torn and ripped collagen fibers; second, the genes for both collagen and elastin are activated, whereas those for tissue collagenases are inhibited. The effect of mechanical strain on human gingival fibroblasts was evaluated recently. The study used as yardsticks the phosphorylation status and localization of Forkhead box family members (mediators of fibroblast apoptosis) and the level of proliferating cell nuclear antigens (for strain induced proliferation). The results indicated that mechanical strain can deliver anti-apoptotic and proliferative stimuli to human gingival fibroblasts.<sup>158</sup>

Gross clinical observation of the gingiva during orthodontic treatment showed tissue accumulation and enlargement of gingival papillae when extraction spaces are being closed. This tissue accumulation is attributed to both retraction and compression. Adjacent to this tissue accumulation, vertical clefts of both epithelium and connective tissue, which persisted for years after treatment, have been reported.<sup>159</sup> Histologic

studies showed discontinuation of transseptal fibers at extraction sites and their reestablishment during the healing phase.<sup>160</sup> These newly formed collagen fibers are coiled and compressed, and have a football-shaped appearance after orthodontic approximation of teeth at extraction sites. There are increases in the amount of oxytalan fibers and GAGs in the transseptal fiber area. It is reported that proline uptake by newly formed collagen is increased significantly, suggesting an increase in the synthesis rate by gingival fibroblasts.<sup>161</sup> Ultrastructural analysis with transmission electron microscopy showed increased diameters of newly formed gingival collagen fibers in both compressed and tension sites. Moreover, there is apparently a slight increase in the number and size of elastic fibers in gingival pressure sites, when compared to tension sites.<sup>157</sup>

Studies on gingival fibroblasts in vitro, with reverse transcriptase polymerase chain reaction showed gene transcription levels of collagen type I to be significantly increased, whereas that of tissue collagenase (MMP1) is decreased after mechanical loading.<sup>162</sup> In a recent report, Bolcato-Bellemin et al<sup>68</sup> subjected human fibroblasts from the PDL and the gingiva to mechanical force to quantify the mRNAs encoding the various MMPs, TIMPs, and alpha and beta integrin subunits. The results indicated that stretched fibroblasts of both types had the same pattern of mRNAs encoding MMPs and TIMPs, but differed for those encoding various integrin subunits, known to act as protein receptors in mechanotransduction. This finding suggests a disturbed equilibrium between collagen synthesis and degradation, required to maintain adequate tissue stability. These data suggest that orthodontic force effects on the gingiva are similar in cases of extraction space closure and rotation corrections. Furthermore, these findings indicate that the cause of relapse after treatment is most likely the increased elasticity of the compressed gingiva, brought about by biosynthesis of new elastic fibers and GAGs. In this fashion, the gingiva undergoes elastic deformation during orthodontic treatment, capable of causing relapse during the posttreatment retention period.

#### **Biomarkers of bone remodeling in gingival crevicular fluid**

GCF arises at the gingival margin and can variously be described as a transudate or an exudate. Its rate of flow is related to the degree of gingival inflammation, and a rate of 0.05 to 0.20  $\mu$ l per minute was reported in cases of apparent minimal inflammation. The total fluid flow is between 0.5 and 2.4 mL per day.<sup>163</sup> Recent studies in orthodontic tooth movement have used GCF because of its noninvasive nature and ease of repetitive sam-

pling from the same site with the help of platinum loops, filter paper strips, gingival washings, and micro pipettes. The fluid is used to analyze various biochemical markers such as prostaglandin production and the action of various extracellular and intracellular factors, such as IL-1, IL-6, TNF- $\alpha$ , epidermal growth factors,  $\beta_2$  microglobulin, cathepsin, aspartate aminotransferase, alkaline phosphatase, and lactate dehydrogenase.

Remodeling changes in the alveolar bone and the PDL induce production of various cell mediators or enzymes that can be used as biomarkers of orthodontic treatment.<sup>58,164</sup> The early works by Last et al,<sup>165</sup> and Embery and Waddington<sup>58</sup> described many GAGs, and proteoglycan and tissue proteins in GCF, providing evidence for the presence of underlying state of biochemical reflections in paradental tissues. Last et al<sup>165</sup> were the first to report a finding in this regard by demonstrating chondroitin-4-sulphate in GCF from the pressure side of tooth movement. Because the orthodontic model is a nonplaque, nondisease-related process, it is suggested that the increase in chondroitin-4-sulphate is a biological alteration in deep-seated tissues. Uematsu et al<sup>166,167</sup> found several cell mediators, such as IL-1 $\beta$ , IL-6, TNF $\alpha$ , epidermal growth factors,  $\beta_2$  microglobulin, and TGF $\beta$ , to be elevated in the GCF during orthodontic treatment. Grieve et al<sup>168</sup> and Lee et al<sup>169</sup> reported similar finding for PGE<sub>2</sub> and IL-1 $\beta$ , and Lowney et al<sup>170</sup> for TNF $\alpha$ .

Griffiths et al<sup>171</sup> demonstrated the presence of osteocalcin in GCF from teeth associated with orthodontic forces. A study by Insoft et al<sup>172</sup> found increased alkaline phosphatase levels during the first 3 weeks of orthodontic treatment, whereas acid phosphatase increased in subsequent weeks. Perinetti et al<sup>173</sup> also demonstrated alkaline phosphatase along with aspartate aminotransferase activity in GCF. Recently, Serra et al<sup>174</sup> observed an increase in lactate dehydrogenase activity in GCF after orthodontic force application and proposed it to be a sensitive marker for periodontal metabolism. Sugiyama et al<sup>164</sup> reported an increase in the amount of cathepsin B in GCF and suggested it to be involved in ECM degradation. Apajalahti et al<sup>65</sup> found a significantly higher amount of MMP-8 in GCF after orthodontic force application for 4 to 8 hours. They suggested that the increased expression and activation of GCF MMP-8 reflects the enhanced periodontal remodeling changes of orthodontic force application. They concluded that the presence of such markers in GCF might be useful in identifying the bone-remodeling activities during orthodontic treatment. This fluid can, therefore, be considered a promising and potent area of future research, because these investigations have already begun to provide insight

into the temporal aspects of resorptive and formative processes in the paradental tissues during orthodontic treatment.

## TISSUE REACTIONS WITH VARIED FORCE APPLICATIONS

Force can be defined as the action of 1 body on another that tends to change the state of rest or motion of the latter. It is a vectoral quantity, which means that, to adequately describe it, we have to define its magnitude, direction, and duration, as well as its point of application.<sup>6</sup> Orthodontics is based on application of force on the teeth, under the influence of which tooth movement occurs. The duration and character of force have great influence in orthodontic mechanotherapy, alterations in which can produce varied tissue reactions.

### Continuous, interrupted, and intermittent forces

Most contemporary fixed orthodontic appliances use light continuous forces as part of orthodontic mechanotherapy to effect tooth movement. However, a continuous force can subside rapidly and thus be interrupted after a limited period of time, such as in torquing movements by an edgewise archwire or labial movement of blocked-out maxillary lateral incisor with the help of ligation. It is not always possible to distinguish between continuous and interrupted movements, and the latter act for only comparatively short durations.<sup>175</sup> Nevertheless, it appears that this kind of a force, that starts in a continuous mode and then becomes interrupted, is biologically favorable, particularly when its initial magnitude is low. In such a case, hyalinized zones might develop in sites of compressed PDL, but, as soon as this necrotic tissue is eliminated and the tooth moves, the force decreases quickly. Finally, the archwire retains its passivity for a while, during which time (rest period) there will be an opportunity for calcification of the newly formed osteoid layer. This rest period between appliance activations is the time used by the tissues for reorganization. This rest can promote favorable cell proliferation for further tissue changes when the appliance is activated again.<sup>176</sup> The characteristic feature of continuous/interrupted tooth movement is formation of new bone layers in the richly cellular tissue at the entrance of open marrow spaces as soon as the tooth movement stops.<sup>50</sup> A recent study evaluated the areas of compressed PDL near rat molars subjected to continuous orthodontic force with the help of TEM and TRAP histochemistry.<sup>177</sup> The results prove that continuous orthodontic forces can resorb the alveolar bone concomitantly with the formation of new bony tissue at PDL tension sites.

Typical intermittent forces act as either an impulse or a shock of short duration, or for short periods with a

series of interruptions. These forces are mainly produced by removable appliances, which deliver force periodically. Examples of such a system are springs resting on tooth surfaces.<sup>175</sup> Intermittent force results in small compression zones in the PDL, short hyalinization periods, and lengthy rest periods when the appliance is removed intermittently. During this time, the tooth moves back to the tension side and remains in normal function. This mode of treatment can improve the paradental circulation and promote an increase in the number of PDL cells, because its fibers usually retain a functional arrangement.<sup>176</sup> Reitan defined this condition as “semi-hyalinization,” meaning that in the compressed PDL not all fibers become compressed, and only some cells undergo necrosis. Consequently, osteoclasts might be formed directly along the bone surface subjacent to hyalinized tissue, and bone resorption is less disturbed by hyalinization. This situation might affect smooth and uniform movement of teeth.<sup>175</sup>

#### Light v heavy forces and the rate of tooth movement

The magnitude of force applied for orthodontic mechanotherapy has received significant attention. It is generally accepted that light forces produce favorable tooth displacement, resulting in minimal discomfort and pain to the patient, but heavy forces (which exceed capillary blood pressure of 20-25 gm/cm<sup>2</sup> of root surface) produce the classic 3-phase reaction—initial strain, lag phase, and progressive tooth movement.<sup>9</sup> A recent article by Kohno et al<sup>178</sup> reported that light forces can tip teeth without friction, with a constant rate of tooth movement, and without the 3 phases. However, in most cases, this kind of tipping is uncontrolled and can cause root resorption, despite the small magnitude of the applied force.

In orthodontic tooth movement, as in all other biological responses to mechanical loading, one would expect a dose-response relationship between the magnitude of the applied force and the extent of the tissue reaction. Quinn and Yoshikawa<sup>179</sup> described 4 alternative models for this relationship. The first proposes an on-off switch that is turned on at a certain force level. All forces above this threshold will lead to the same rate of tooth movement. Several studies have supported this hypothesis.<sup>37,180</sup> A linear dose response relationship with a threshold level force is indicated in the second model. This concept was also supported by several authors,<sup>37,181</sup> who believe that higher forces are efficient in tooth movement. In the third model, it was suggested that a dose-response relationship exists in the lower force range, up to a certain level. Then a plateau is reached, and further increase in force level activity

decreases the rate of tooth movement. This hypothesis agrees with Begg's differential force concept.<sup>182</sup> In the fourth model, the decline in the rate of tooth movement in response to an increase in force magnitude is ignored, suggesting that merely applying greater orthodontic forces does not necessarily guarantee a faster rate of tooth movement.<sup>179</sup>

These findings suggest that, with increasing magnitudes of orthodontic forces, a constant rate of tooth movement would be reached, within a broad range of forces. This observation has led to the conclusion that force magnitude plays only a subordinate role in orthodontic tooth movement. In support of this hypothesis is a study by Pilon et al<sup>33</sup> in dogs, in which application of 2 forces (50 and 100 CN) to second premolars resulted in the same rate of tooth movement. A clinical experiment by Owman-Moll et al<sup>37</sup> in humans produced similar results.

Recent reports by von Böhl et al<sup>35,36</sup> also state that the models that describe the relationship between the magnitude of the orthodontic force and the rate of tooth movement probably are not valid. Apparently, the determining factor is the degree of PDL hyalinization in response to the application of heavy forces. The rate of removal of this necrotic tissue might depend on the pattern of strain distribution in the paradental tissues, the peculiarities of the PDL, and bone morphology. It was concluded that, with present knowledge, an appropriate model for tooth movement is difficult to propose; additional information is required about the biochemical background of the process, as well as insights into individual variations in bone density and the metabolism of PDL and bone.

#### Duration of force application

Clinical experience suggests that successful tooth movement requires a threshold of force duration of about 6 hours per day. It was determined in an experiment on cats that it takes about 3 hours for significant elevations in cAMP in extracts of alveolar bone and PDL, after sustained applications of tipping forces to the maxillary canines.<sup>183</sup> Recent reports proposed a role for nitric oxide as a marker of vascular signal transduction during the initial state of orthodontic tooth movement.<sup>152-156</sup> Nitric oxide is produced by various cells and is present in blood vessels, nerves, and PDL fibroblasts. This molecule has been reported to take part in bone remodeling<sup>184</sup> and in the regulation of blood vessels and nerves.<sup>185</sup> During the initial stages of tooth movement under the influence of light continuous forces, the activity of nitric oxide synthase in paradental tissues was found to increase as early as 1 to 3

hours<sup>152</sup> or within 6 hours<sup>15</sup> from the onset of treatment.

### **DELETERIOUS EFFECTS OF ORTHODONTIC FORCE**

Tissue reactions incident to orthodontic tooth movement depend mainly on the pattern of stress-strain distribution in the paradental tissues. Different types of tooth movement generate different force distribution patterns, and thereby different types of tissue reactions. Various studies, evaluating tissue reactions by radiologic and histologic means, have detected iatrogenic sequelae to orthodontic force. These effects include caries, gingivitis, marginal bone loss, pulpal reactions, root resorption, and allergic reactions to appliance materials. The discussion below is limited to deleterious effects affecting 3 main tissues—gingiva, cementum, and dental pulp.

#### **Gingival problems**

Fixed-appliance orthodontics has been shown to produce deleterious effects on the periodontium, ranging from gingivitis to bone loss.<sup>186-188</sup> The cementation of orthodontic bands or resin-bonded attachments can evoke local soft tissue response.<sup>189</sup> This response is mainly due to plaque accumulation and the proximity of these attachments to the gingival sulcus.<sup>186</sup> Another long-term complication of orthodontic treatment is gingival recession. Various authors have reported the range of its occurrence from 1.3% to 10%. It is widely accepted that at least 2 mm of keratinized gingiva should be present to withstand orthodontic force and prevent recession.<sup>187</sup> Dorfman<sup>188</sup> suggested that mandibular incisors are most likely to express gingival recession in response to orthodontic mechanotherapy. This outcome has been attributed to the thin or nonexistent labial plate of bone and inadequate or absent keratinized gingiva that covers labially prominent teeth. This potentially risky and harmful condition received much attention, because it can lead to poor esthetics, root sensitivity, loss of periodontal support, difficulty in maintaining oral hygiene, difficulty in successful periodontal repair, and increased susceptibility to caries.

Orthodontic treatment often leads to alteration in oral hygiene habits, which might result in plaque accumulation and gingival inflammation. The development of gingival inflammation during orthodontic mechanotherapy is associated with specific bacterial types, as listed in many reports.<sup>189-191</sup> Huser et al<sup>189</sup> studied longitudinally the microbial flora in plaque of patients undergoing orthodontic treatment. There were definite increases in plaque scores and probing depths in these patients when compared with controls. The

bacterial plaque was composed mainly of spirochetes and motile rods. Other authors reported increases in the levels of bacteroids and streptococcus species after orthodontic banding.<sup>190,191</sup> It can, therefore, be concluded that orthodontic mechanotherapy produces a local change in the oral ecosystem, altering the composition of bacterial plaque, tipping the scale toward the development of an inflammatory process.

#### **Root resorption**

Normally, cementum does not undergo appreciable resorption; it seems to be excluded from remodeling activities associated with maintenance of calcium homeostasis. However, orthodontic force application can sometimes evoke excessive resorption of root cementum, proceeding into the dentin, eventually shortening the root length—a process called root resorption.<sup>163</sup> Ottolengui (1914)<sup>192</sup> and Ketcham (1927)<sup>193</sup> were the first to report severe root resorption associated with orthodontic tooth movement. It is an undesirable and the least predictable sequelae of orthodontic treatment. It can occur during the middle or the posttreatment phase, raising questions about the longevity of the treated dentition and the stability of the treatment results. Along with other factors, orthodontic forces can initiate and sustain the resorptive process.<sup>194</sup> Jarabak and Fizzell,<sup>195</sup> after analyzing the effect of force systems during mechanotherapy, concluded that the magnitude of an orthodontic force and rigid fixation of the archwire to the brackets could be considered the most important factors predisposing a tooth to the root resorption. Jiggling forces and round tripping of teeth during mechanotherapy were also suggested as major causes of orthodontic root resorption.<sup>196,197</sup>

Comparing treatment mechanics with and without tooth extraction, there were definite correlation between extraction treatment and root resorption.<sup>198-200</sup> Of the various possible orthodontic tooth movements, intrusion and torquing make a tooth root more prone to resorption.<sup>198,201</sup> A literature search regarding tooth vulnerability to resorption found agreement among many authors. They state that maxillary incisors, particularly the central incisors, are the most prone to the process, followed by the maxillary molars and the canines. In the mandibular arch, the most prone teeth are the lateral and central incisors. It was also pointed out that tapered roots, compared with the blunted type, exhibit more resorption.<sup>202-205</sup>

Alignment of impacted canines as a risk factor for resorption has been identified recently.<sup>205</sup> Drugs, such as corticosteroids and alcohol, and systemic diseases, such as asthma and allergies, have been proposed to predispose tooth roots to resorption after orthodontic

force application.<sup>194</sup> Moreover, a previous history of dentofacial trauma and the detection of root resorption in pretreatment radiographs have also been proposed as predisposing factors.<sup>205</sup> A recent report suggested that a hypofunctional PDL, associated with nonoccluding teeth, increases the risk for orthodontic root resorption.<sup>206</sup>

Brezniak and Wasserstein<sup>207</sup> classified root resorption according to its severity. Accordingly, it is possible to identify (1) cemental, or surface resorption, where only the outer layers are resorbed, to be fully regenerated or remodeled later; (2) dentinal resorption with repair, where the cementum and the outer layers of dentin are resorbed, and are repaired along with morphological alterations; and (3) circumferential root resorption, where full resorption of the hard tissue components of the root apex occurs, resulting in root shortening.

Current research in orthodontic root resorption is directed toward identifying genes involved in the process, their chromosome loci, and their possible clinical significance. Al Qawasmi et al<sup>208</sup> reported on finding evidence of a linkage disequilibrium of IL1 $\beta$  polymorphism in allele 1 and external apical root resorption. Another study by the same authors<sup>209</sup> and one by Low et al,<sup>210</sup> linked RANKL and OPG with the regulation of root resorption.

Progress periapical and panoramic radiographs are useful aids in detecting midtreatment resorptive processes.<sup>203-205,211,212</sup> Whenever such a finding is encountered, a temporary halt in orthodontic treatment for 4 to 6 months is advised.<sup>198,203,213,214</sup>

Whatever the predisposing or influencing factors, most authors believe that there will be no apparent increase in resorption after termination of active orthodontic treatment.<sup>203,205,214-217</sup> Some repair occurs, including smoothing and remodeling of cemental surfaces and the return of the PDL width to normal. Original root contours and lengths are never reestablished, but the function of the tooth apparatus is usually not severely affected by the loss of root length.<sup>214</sup>

Several ways to slow down the rate of orthodontic root resorption during mechanotherapy have been proposed, including drugs, hormones, and growth factors.<sup>218-223</sup> In a recent experiment, Bialy et al<sup>224</sup> studied the effect of low-intensity pulsed ultrasound on healing of orthodontically induced root resorption. The results were promising, demonstrating a reduction of root resorption and acceleration in healing of already resorbed sites with reparative cementum over 4 weeks of low-intensity pulsed ultrasound application.

## Pulpal reactions

Various dental procedures, including orthodontic tooth movement, have been reported to adversely affect the dental pulp. The literature shows conflicting results for correlation of pulpal changes incident to orthodontic force. Some reports suggested permanent damage to pulpal tissue from orthodontic force, but others claimed no significant long-lasting effects on the dental pulp.<sup>225</sup> In 1980, Labart et al<sup>226</sup> demonstrated increased pulpal respiration rate in rat incisor pulp (1-2 times more than controls), when subjected to orthodontic stress for 72 hours. Harmersky et al<sup>227</sup> showed a depression in pulpal respiratory rate after orthodontic force application in humans. Unsterseher et al<sup>225</sup> also had the same results.

In recent years, the alterations in pulpal vasculature and blood flow in response to orthodontic force have gained much attention. Various experiments have demonstrated an initial decrease in blood flow, lasting approximately 32 minutes, followed by an increase in blood flow (lasting 48 hours). Mostafa et al<sup>228</sup> reported congested and dilated blood vessels, and edema of pulpal tissue in their histologic observations. A histomorphometric study on rats by Nixon et al<sup>229</sup> contradicted some studies and reported an increase in the number of functional pulpal vessels after orthodontic force application. Derringer and Linden,<sup>230</sup> who showed an increase in angiogenic growth factors in dental pulp, supported this result. A recent study by Derringer et al<sup>231</sup> identified the specific angiogenic growth factors released in response to orthodontic force application to be vascular endothelial growth factor, FGF-2, PDGF, and TGF-beta.

The clinical impact of all these studies was to determine whether any alterations in pulpal tissue could jeopardize the long-term vitality of the teeth. The progression of the inflammatory process in human pulp fibroblasts apparently depends on stimulation by neuropeptides and production of inflammatory cytokines, such as IL-1, IL-3, IL-6, and TNF $\alpha$ . A recent report described apoptosis in dental pulp tissues of rats undergoing orthodontic treatment.<sup>232</sup> Perinetti et al<sup>233</sup> demonstrated that an enzyme, aspartate aminotransferase (which is released extracellularly upon cell death), is significantly elevated after orthodontic force application.

## POSTTREATMENT CHANGES

Orthodontic forces are known to produce pressure and tension regions in the PDL and alveolar bone. This strain alters the affected tissues' vascularity and blood flow, providing a favorable microenvironment for ei-

ther tissue deposition or resorption. Murrell et al<sup>234</sup> reported that removal of orthodontic forces produces significant changes in the number and density of PDL blood vessels. Normalization of the periodontal vasculature was observed during an interval, equivalent to the duration of orthodontic force application, and it has been suggested to be a main reason for relapse of the end result of orthodontic treatment.

Nakanishi et al<sup>70</sup> reported that the response properties of periodontal mechanoreceptors are adapted to the newly acquired tooth position. After 7 days of force removal, the collagen fiber arrangement became very similar to that of the control group. Yoshida et al<sup>235</sup> evaluated the cellular responses in the relapse of experimentally moved rat molars and suggested that there will be rapid remodeling of the PDL and alveolar bone after treatment, which can be identified as the main cause of relapse. A recent report pointed out that, after tooth movement, occlusal forces were major factors in fostering and expediting periodontal recovery.<sup>236</sup> It is stated that various types of damage to teeth and PDL produced by orthodontic mechanotherapy healed more rapidly and extensively in functional teeth. During the recovery period, the return of periodontal dimensions to normal values is regulated by the rate and direction of alveolar bone turnover.<sup>141</sup>

## CONCLUSIONS

Rapid advances in all biological fields have enabled us to better understand the mechanisms involved in orthodontic tooth movement. It is evident that, at different stages of tooth movement, different combinations of cell-cell and cell-matrix interactions occur; these determine the nature of the remodeling changes. The research trend is now directed toward elucidating molecular level interactions during these events. A better understanding of the relationship between genes and transcription factors in controlling bone and PDL remodeling will expand our knowledge, and might strengthen our clinical capabilities. Above all, this growing body of knowledge on the response of our cells to mechanical loads should illuminate useful paths in clinical orthodontics and assist us in identifying and discarding harmful methods of mechanotherapy. Future orthodontics will, therefore, increasingly become biologically correct and, consequently, patient-friendly.

At the dawn of the 20th century, Edward H. Angle, the father of modern orthodontics, advocated including courses in biological sciences in orthodontic training programs. At that time, these courses were mainly inside the domain of anatomy and physiology. However, at the onset of the 21st century, the scientific frontiers in biology have witnessed remarkable ad-

vances in molecular biology and molecular genetics. Angle's recommendation for biological sciences in the orthodontic curriculum most likely stemmed from his realization that orthodontic treatment is rendered to human patients. This fact has remained unaltered throughout the passing years, as most orthodontic departments adopted the conviction that orthodontic excellence is derived from a comprehensive knowledge of mechanics and biology. In reality, though, commanding knowledge of mechanics, material science, and metallurgy have prevailed, while biological sciences continue to play a minor role in clinical orthodontics. However, future orthodontists will witness an improvement in this imbalance, as has been happening in all medical fields. Because the face and oral cavity are integral parts of the human body, growing understanding of the body's functions on the cellular and molecular levels will lead to the development of orthodontic appliances capable of correcting malocclusions successfully in patients with similar morphological features but varying biochemical profiles. This ongoing development will move orthodontics closer to the goal of being optimal, where teeth are moved efficiently, without causing discomfort to the patient or damage to the teeth and their supporting tissues.

## REFERENCES

1. Reitan K. Tissue behavior during orthodontic tooth movement. *Am J Orthod* 1960;46:881-90.
2. Rygh P, Brudvik P. The histological responses of the periodontal ligament to horizontal orthodontic loads. In: Berkovitz BB, Moxham BJ, Newman HN, editors. *The periodontal ligament in health and disease*. St Louis: Mosby; 1995.
3. Davidovitch Z. Tooth movement. *Crit Rev Oral Biol Med* 1991;2:411-50.
4. Davidovitch Z, Nicolay OF, Ngan PW, Shanfeld JL. Neurotransmitters, cytokines and the control of alveolar bone remodeling in orthodontics. *Dent Clin North Am* 1988;32:411-35.
5. Davidovitch Z. Cell biology associated with orthodontic tooth movement. In: Berkovitz BB, Moxham BJ, Newman HN, editors. *The periodontal ligament in health and disease*. St Louis: Mosby; 1995.
6. Daskalogiannakis J. *Glossary of orthodontic terms*. Berlin: Quintessence; 2000.
7. Mao JJ, Wang X, Kopher RA. Biomechanics of craniofacial sutures—orthopedic implications. *Angle Orthod* 2003;73:128-35.
8. Toms SR, Lemons JE, Bartolucci AA, Eberhardt AW. Nonlinear stress-strain behavior of periodontal ligament under orthodontic loading. *Am J Orthod Dentofacial Orthop* 2002;122:174-9.
9. Burstone CJ. The biomechanics of tooth movement. In: Kraus BS, Riedel RA, editors. *Vistas in orthodontics*. Philadelphia: Lea & Febiger; 1962.
10. Storey E. The nature of tooth movement: *Am J Orthod* 1973;63:292-314.
11. Reitan K. Some factors determining the evaluation of force in orthodontics. *Am J Orthod* 1957;43:32-45.

12. Schwarz AM. Tissue changes incident to orthodontic tooth movement. *Int J Orthod* 1932;18:331-52.
13. Oppenheim A. Human tissue response to orthodontic intervention of short and long duration. *Am J Orthod Oral Surg* 1942;28:263-301.
14. Storey E, Smith R. Force in orthodontics and its relation to tooth movement. *Aust Dent J* 1952;56:11-8.
15. Proffit WR. Biologic basis of orthodontic therapy. In: Proffit WR, Fields HW, editors. *Contemporary orthodontics*. 3rd ed. St Louis: Mosby; 2000.
16. Ren Y, Maltha JC, Kuijpers-Jagtman AM. Optimum force magnitude to orthodontic tooth movement—a systematic review. *Angle Orthod* 2003;73:86-92.
17. Sandstedt C. Einige beiträge zur theorie der zahnregulierung. *Nord Tandlaeg Tidsskr* 1904;5:236-56.
18. Oppenheim A. Tissue changes, particularly of the bone, incident to tooth movement. *Am Orthod* 1911;3:57-67.
19. Baumrind S. A reconsideration of the property of the pressure tension hypothesis. *Am J Orthod* 1969;55:12-22.
20. Kardos BT, Simpson LO. A new periodontal membrane biology based on thixotropic concepts. *Am J Orthod* 1980;77:508-15.
21. Yee JA, Kimmel DB, Jee WSS. Periodontal ligament cell kinetics following orthodontic tooth movement. *Cell Tissue Kinet* 1976;9:293-302.
22. Mostafa YA, Weaks-Dybrig M, Osdoby P. Orchestration of tooth movement. *Am J Orthod* 1983;83:245-50.
23. Farrar JN. Irregularities of the teeth and their correction. Vol 1. New York: DeVinne Press; 1888. p. 658.
24. Grimm FM. Bone bending, a feature of orthodontic tooth movement. *Am J Orthod* 1972;62:384-93.
25. Melsen B. Biological reaction of alveolar bone to orthodontic tooth movement. *Angle Orthod* 1999;69:151-8.
26. Epker BN, Frost HM. Correlation of bone resorption and formation with the physical behavior of loaded bone. *J Dent Res* 1965;44:33-41.
27. Zengo AN, Bassett CA, Pawluk RJ, Prountzos G. In vivo bioelectric potentials in the dentoalveolar complex. *Am J Orthod* 1974;66:130-9.
28. Basset CAL, Becker RO. Generation of electric potentials by bone in response to mechanical stress. *Science* 1962;137:1063-5.
29. Pollack SR, Salzstein R, Pienkowski D. The electric double layer in bone and its influence on stress generated potentials. *Calcif Tissue Int* 1984;36(Suppl):S77-81.
30. Davidovitch Z, Finkelson MD, Steigman S, Shanfeld JL, Montgomery PC, Korostaff E. Electric currents, bone remodeling and orthodontic tooth movement. I—the effect of electric currents on periodontal nucleotides. *Am J Orthod* 1980;77:14-32.
31. Davidovitch Z, Finkelson MD, Steigman S, Shanfeld JL, Montgomery PC, Korostaff E. Electric currents, bone remodeling and orthodontic tooth movement. II—increase in rate of tooth movement and periodontal cyclic nucleotide levels by combined force and electric current. *Am J Orthod* 1980;77:33-47.
32. Borgens RB. Endogenous ionic currents traverse intact and damaged bone. *Science* 1984;225:478-82.
33. Pilon JJAM, Kuijpers-Jagtman AM, Maltha JC. Magnitude of orthodontic forces and rate of bodily tooth movement: an experimental study in beagle dogs. *Am J Orthod Dentofacial Orthop* 1996;110:16-23.
34. Vas Leeuwen EJ, Maltha JC, Kuijpers-Jagtsman AM. Tooth movement with light continuous and discontinuous forces in beagle dogs. *Eur J Oral Sci* 1999;107:468-74.
35. von Böhl M, Maltha JC, Von Den Hoff JW, Kuijpers-Jagtman AM. Focal hyalinization during experimental tooth movement in beagle dogs. *Am J Orthod Dentofacial Orthop* 2004;125:615-23.
36. von Böhl M, Maltha JC, Von den Hoff H, Kuijpers-Jagtman AM. Changes in the periodontal ligament after experimental tooth movement using high and low continuous forces in beagle dogs. *Angle Orthod* 2004;74:16-25.
37. Owman-Moll P, Kurol J, Lundgren P. Effects of doubled orthodontic force magnitude on tooth movement and root resorption. *Eur J Orthod* 1996;18:141-50.
38. Sandy JR, Meikle MC. Recent advances in understanding mechanically induced bone remodeling and their relevance to orthodontic therapy and practice. *Am J Orthod Dentofacial Orthop* 1993;103:212-22.
39. Von Euler US. Contributions to the understanding of the pharmacologic effect of secretions and extracts from secondary male sex glands. *Naunym-Schmeideberg's Archiv fur Experimental Pathologie und Pharmakologie* 1934;175:78-84.
40. Harell A, Dekel S, Binderem I. Biochemical effect of mechanical stress on cultured bone cells. *Calcif Tissue Res* 1977;22(Suppl):202-7.
41. Yamasaki K, Shibata Y, Imai S, Tani Y, Shibasaki Y, Fukuhara T. Clinical application of prostaglandin E<sub>1</sub> (PGE<sub>1</sub>) upon orthodontic tooth movement. *Am J Orthod* 1984;85:508-10.
42. Chumbley AB, Tuncay OC. The effect of indomethacin (as aspirin-like drug) on the rate of orthodontic tooth movement. *Am J Orthod* 1986;89:312-4.
43. Lee W. Experimental study of the effect of prostaglandin administration on tooth movement with particular emphasis on the relationship to the method of PGE<sub>1</sub> administration. *Am J Orthod Dentofacial Orthop* 1990;98:238-41.
44. Leiker BJ, Nanda RS, Currier GF, Howes RI, Sinha PK. The effects of exogenous prostaglandins on orthodontic tooth movement in rats. *Am J Orthod Dentofacial Orthop* 1995;108:380-8.
45. Klein DC, Raisz LG. Prostaglandins: stimulation of bone resorption in tissue culture. *Endocrinology* 1970;86:1436-40.
46. Kale S, Kocadereli I, Atilla P, Aşan E. Comparison of the effects of 1,25 dihydroxycholecalciferol and prostaglandin E<sub>2</sub> on orthodontic tooth movement. *Am J Orthod Dentofacial Orthop* 2004;125:607-14.
47. Gurton AU, Akin E, Sagdic D, Olmez H. Effects of PGI<sub>2</sub> and TxA<sub>2</sub> analogs and inhibitors in orthodontic tooth movement. *Angle Orthod* 2004;74:526-32.
48. Sandy JR, Farndale RW. Second messengers: regulators of mechanically induced tissue remodeling. *Eur J Orthod* 1991;13:271-8.
49. Sutherland EW, Rall TW. Fractionation and characterization of a cyclic adenine ribonucleotide formed by tissue particles. *J Biol Chem* 1958;232:1077-91.
50. Reitan K, Rygh P. Biomechanical principles and reactions. In: Graber RM, Vanarsdall RL, editors. *Orthodontics—current principles and techniques*. 2nd ed. St Louis: Mosby; 1994.
51. Berridge MJ. Inositol triphosphate and diacylglycerol: two interacting second messengers. *Ann Rev Biochem* 1987;56:159-93.
52. Hokin MR, Hokin LE. Enzyme secretion and the incorporation of 32p into phospholipids of pancreas slices. *J Biol Chem* 1953;203:967-77.

53. Collins M, Sinclair PM. The local use of vitamin D to increase rate of orthodontic tooth movement. *Am J Orthod Dentofacial Orthop* 1988;94:278-84.
54. Takano-Yamamoto T, Kawakami M, Kobayashi Y, Yamashiro T, Sakuda M. The effect of local application of 1,25 dihydroxycholecalciferol on osteoclast numbers in orthodontically treated rats. *J Dent Res* 1992;71:53-9.
55. Kawakami M, Takano-Yamamoto TT. Local injection of 1,25-dihydroxyvitamin D3 enhanced bone formation for tooth stabilization after experimental tooth movement in rats. *J Bone Miner Metab* 2004;22:541-6.
56. Sandy JR. Signal transduction. *Br J Orthod* 1998;25:269-74.
57. Kerrigan JJ, Mansell JP, Sandy JR. Matrix turnover. *J Orthod* 2000;27:227-33.
58. Waddington RJ, Embery G. Proteoglycans and orthodontic tooth movement. *J Orthod* 2001;28:281-90.
59. Talic N, Evans CA, Daniel JC, George A, Zaki AM. Immunohistochemical localization of  $\alpha\beta_3$  integrin receptor during experimental tooth movement. *Am J Orthod Dentofacial Orthop* 2004;125:178-84.
60. Sodek J. A comparison of the rates of synthesis and turnover of collagen and non-collagen proteins in adult rat periodontal tissues and skin using a microassay. *Arch Oral Biol* 1977;22:655-65.
61. Bartold PM, Narayanan AS (eds). *Biology of periodontal connective tissue*. Chicago: Quintessence; 1998.
62. Bartold PM. A biochemical and immunohistochemical study of proteoglycans of alveolar bone. *J Dent Res* 1990;69:7-19.
63. Smith AJ, Singhrao SK, Newman GR, Waddington RJ, Embery G. A biochemical and immunoelectron microscopical analysis of chondroitin sulphate rich proteoglycans in human alveolar bone. *Histochem J* 1997;29:1-9.
64. Reynolds JJ, Meikle MC. Mechanisms of connective tissue matrix destruction in periodontics. *Periodontology* 2000 1997; 14:144-57.
65. Apajalahti S, Sorsa T, Railavo S, Ingman T. The in vivo levels of matrix metalloproteinase-1 and -8 in gingival crevicular fluid during initial orthodontic tooth movement. *J Dent Res* 2003;82:1018-22.
66. Holliday LS, Vakani A, Archer L, Dolce C. Effects of matrix metalloproteinase inhibitors on bone resorption and orthodontic tooth movement. *J Dent Res* 2003;82:687-91.
67. Takahashi I, Nishimura M, Onodera K, Bae JW, Mitani H, Okazaki M, et al. Expression of MMP-8 and MMP-13 genes in the periodontal ligament during tooth movement in rats. *J Dent Res* 2003;82:646-51.
68. Bolcato-Bellemin AL, Elkaim R, Abehseia A, Fausser JL, Haikel Y, Tenenbaum H. Expression of mRNAs encoding for alpha and beta integrin subunits, MMPs, and TIMPs in stretched human periodontal ligament and gingival fibroblasts. *J Dent Res* 2000;79:1712-6.
69. Maeda T, Iwanaga T, Fujita T, Takahashi Y, Kobuyashi S. Distribution of nerve fibers immunoreactive to neurofilament protein in rat molars and periodontium. *Cell Tissue Res* 1987;249:13-23.
70. Nakanishi H, Seki Y, Kohno T, Muramoto T, Toda K, Soma K. Changes in response properties of periodontal mechanoreceptors after experimental orthodontic tooth movement in rats. *Angle Orthod* 2004;74:93-9.
71. Kobayashi H, Ochi K, Saito I, Hanada K, Maeda T. Alterations in ultra structural localization of growth associated protein 43 (GAP-43) in periodontal Ruffini endings of rat molars during experimental tooth movement. *J Dent Res* 1998;77:503-17.
72. Linden RWA. An update on the innervation of the periodontal ligament. *Eur J Orthod* 1990;12:91-100.
73. Vandevska-Radunovic V. Neural modulation of inflammatory reactions in dental tissues incident to orthodontic tooth movement—a review of literature. *Eur J Orthod* 1999;21:231-47.
74. Jacobsen EB, Heyerans KJ. Pulpal interstitial tissue fluid pressure and blood flow after denervation and electrical tooth stimulation in the ferret. *Arch Oral Biol* 1997;42:407-15.
75. Kvinnsland I, Kvinnsland S. Changes in CGRP-immunoreactive nerve fibers during experimental tooth movement in rats. *Eur J Orthod* 1990;12:320-9.
76. Norevall LI, Forsgren S, Matsson L. Expression of neuropeptides (CGRP, substance P) during and after orthodontic tooth movement in the rat. *Eur J Orthod* 1995;17:311-25.
77. Saito S, Ngan PW, Saito M, Shanfield JL, Davidovitch Z. Interactive effects between cytokines on PGE production by human periodontal ligament fibroblasts in vitro. *J Dent Res* 1990;69:1456-62.
78. Rygh P, Selvig KA. Erythrocyte crystallization in rat molar periodontium incident to tooth movement. *Scand J Dent Res* 1973;81:62-73.
79. Roberts WE, Huja S, Roberts JA. Bone modeling—biomechanics, molecular mechanisms and clinical perspectives. *Semin Orthod* 2004;10:123-61.
80. Yamashiro T, Fukunaga T, Kabuto H, Ogawa N, Takano-Yamamoto T. Activities of the bulbospinal serotonergic system during experimental tooth movement in the rats. *J Dent Res* 2001;80:1854-7.
81. Hattori Y, Watanabe M, Iwabe T, Tanak E, Nishi M, Aoyama J, et al. Administration of MK-801 decreases c-FOS expression in the trigeminal sensory nuclear complex but increases it in midbrain during experimental tooth movement in rat molars. *Brain Res* 2004;1021:183-91.
82. Sabatini M, Boyce B, Aufdemorte T, Bonewald L, Mundy GR. Infusion of recombinant human interleukin 1 $\alpha$  and 1 $\beta$ —cause hypercalcemia in normal mice. *Proc Natl Acad Sci USA* 1988;85:5235-9.
83. Tuncer BB, Ozmeric N, Tuncer C, Teoman I, Cakilci B, Yucel A, et al. Levels of interleukin-8 during tooth movement: *Angle Orthod* 2005;75:539-44.
84. Saito S, Ngan P, Saito M, Kim K, Lanese R, Shanfield J, et al. Effect of cytokines of prostaglandin E and cAMP in human periodontal ligament fibroblasts in vivo. *Arch Oral Biol* 1990; 35:387-95.
85. Alhashimi N, Frithiof L, Brudvik P, Bakheit M. Orthodontic movement and de novo synthesis of proinflammatory cytokines. *Am J Orthod Dentofacial Orthop* 2001;119:307-12.
86. Alhashimi N, Frithiof L, Brudvik P, Bakheit M. Orthodontic movement induces high numbers of cells expressing interferon  $\gamma$  at mRNA and protein levels. *J Interferon Cytokine Res* 2000;20:7-12.
87. Drugarin D, Drugarin M, Negru S, Cioace R. RANK-RANKL/OPG molecular complex—control factors in bone remodeling. *TMJ* 2003;53:296-302.
88. Van Kooten C, Banchereau J. CD40-CD40 ligand: a multifunctional receptor ligand pair. *Adv Immunol* 1996;61:1-77.
89. Alhashimi N, Frithiof L, Brudvik P, Bakheit M. CD 40-CD 40L expression during orthodontic tooth movement in rats. *Angle Orthod* 2004;74:100-5.
90. Kanzaki H, Chiba M, Takahashi I, Haruyama N, Nishimura M, Mitani H. Local OPG gene transfer to periodontal tissue inhibits orthodontic tooth movement. *J Dent Res* 2004;83:920-5.

91. Katagiri T, Takahashi N. Regulatory mechanisms of osteoblast and osteoclast differentiation. *Oral Dis* 2002;8:147-59.
92. Merwin JR, Anderson JM, Kocher O, Van Italic CM, Madri JA. Transforming growth factor beta 1 modulates extracellular matrix organization and cell-cell junctional complex during in vitro angiogenesis. *J Cell Physiol* 1990;142:117-28.
93. Quinn JM, Itoh K, Udagawa N, Hausler K, Yasuda H, Shima N, et al. Transforming growth factor  $\beta$  effects on osteoclast differentiation via direct and indirect actions. *J Bone Min Res* 2001;16:1787-94.
94. Heldin CH, Miyazono K, ten Dijke. TGF $\beta$  signaling from cell membrane to nucleus through SMAD proteins. *Nature* 1997;319:511-4.
95. Shi Y. Structural insight on SMAD function in TGF $\beta$  signaling. *Bioessay* 2001;23:223-32.
96. ten Dijke P, Iwata KK, Goddard C, Pieler C, Canalis E, McCarthy TL, et al. Recombinant transforming growth factor type  $\beta_3$ : biological activities and receptor binding properties in isolated bone cells. *Mol Cell Biol* 1990;10:4473-9.
97. Orellana MF, Smith AK, Waller JL, DeLeon E Jr, Borke JL. Plasma membrane disruption in orthodontic tooth movement in rats. *J Dent Res* 2002;81:43-7.
98. Globus KB, Plouet J, Gospodarowicz D. Cultured bovine bone cells synthesize basic fibroblast growth factor and store it in extracellular matrix. *Endocrinology* 1989;12:1539-47.
99. Noff D, Pitaru S, Savion N. Basic fibroblast growth factor enhances the capacity of bone marrow cells to form bone-like nodules in vitro. *FEBS Lett* 1989;250:619-21.
100. Cohick WS, Clemmons DR. The insulin-like growth factors. *Ann Rev Physiol* 1993;55:131-53.
101. Blom S, Holmstrup P, Dabelsteen E. The effect of insulin like growth factor I and human growth hormone on periodontal ligament fibroblast morphology, growth pattern, DNA synthesis and receptor binding. *J Periodontol* 1992;63:960-8.
102. Coxam V, Davicco MJ, Pastoureau P, Delmas PD, Barlet JP. Insulin-like growth factor II increases plasma osteocalcin concentration in newborn lambs. *Bone Miner* 1992;17:177-86.
103. Deuel TF, Kawahara RS, Mustoe TA, Pierce AF. Growth factors and wound healing: platelet derived growth factor as a model cytokine. *Ann Rev Med* 1991;42:567-84.
104. Farndale RW, Sandy JR, Atkinson SJ, Pennington SR, Meghji S, Meikle MC. Parathyroid hormone and prostaglandin  $E_2$  stimulate both inositol phosphates and cyclic Amp accumulation on mouse osteoblast cultures. *Biochem J* 1988;252:263-8.
105. Davidai G, Lee A, Schvartz I, Hazum E. PDGF induce tyrosine phosphorylation in osteoblast like cells—relevance to mitogenesis. *Am J Physiol* 1992;263:205-9.
106. Sandy JR, Davies M, Prime S, Farndale R. Signal pathways that transduce growth factor stimulated mitogenesis in bone cells. *Bone* 1998;23:17-26.
107. Safadi FF, Xu J, Smock SL, Kanaan RA, Selim AH, Odgren PR, et al. Expression of connective tissue growth factor in bone—its role in osteoblast proliferation and differentiation in vitro and bone formation in vivo. *J Cell Physiol* 2003;196:51-62.
108. Yamashiro T, Funkunaga T, Kobashi N, Kamioka H, Nakanishi T, Takigawa M, et al. Mechanical stimulation induces CTGF expression in rat osteocytes. *J Dent Res* 2001;80:461-5.
109. Kahn AJ, Simmons DJ. Investigations of cell lineage in bone using a chimera of chick and quail embryonic tissue. *Nature* 1975;258:325-7.
110. Falkenberg JHF, Harrington MA, Walsh WK, Daub R, Broxmeyer HE. Gene expression and release of macrophage colony stimulating factor in quiescent and proliferating fibroblasts: effects of serum, fibroblast growth promoting factors and IL-1. *J Immunol* 1990;144:4657-62.
111. Takashi N, Udagawa N, Akatsu T, Tanaka H, Shionome M, Suda T. Role of colony stimulating factors in osteoclast development. *J Bone Min Res* 1991;6:977-85.
112. Nomura S, Takano-Yamamoto T. Molecular events caused by mechanical stress in bone. *Matrix Biol* 2000;19:91-6.
113. Takano-Yamamoto T, Takemura T, Kitamura Y, Nomura S. Site-specific expression of RNA for osteonectin, osteocalcin and osteopontin revealed by in situ hybridization in rat periodontal ligament during physiological tooth movement. *J Histochem Cytochem* 1994;42:885-96.
114. Shakespeare W, Yang M, Bohacek R, Cerasoli F, Stebbins K, Sundaramoorthi R, et al. Structure based design of an osteoclast-selective non-peptide Src homology 2 inhibitor with in vivo antiresorptive activity. *Proc Nat Acad Sci USA* 2000;97:9373-8.
115. Kanzaki H, Chiba M, Shimizu Y, Mitani H. Periodontal ligament cells under mechanical stress induce osteoclastogenesis by receptor activator of nuclear factor kappa B ligand up-regulation via prostaglandin  $E_2$  synthesis. *J Bone Miner Res* 2002;17:210-20.
116. Cella M, Buonsanti C, Strader C, Kondo T, Salmaggi A, Colonna M. Impaired differentiation osteoclasts in TREM-2 deficient individuals. *J Exp Med* 2003;198:645-51.
117. Wilde J, Yokozeki M, Terai K, Kudo A, Moriyama K. The divergent expression of periostin mRNA in the periodontal ligament during experimental tooth movement. *Cell Tissue Res* 2003;312:345-51.
118. Pavlin D, Gluhak-Heinrich J. Effect of mechanical loading on periodontal cells. *Crit Rev Oral Biol Med* 2001;12:414-24.
119. Jones DB, Bingmann D. How do osteoblasts respond to mechanical stimulation? *Cells Mater* 1991;1:329-40.
120. Jones DB, Nolte H, Scholubbers JG, Turner E, Veltel D. Biochemical signal transduction of mechanical strain in osteoblast-like cells. *Biomaterials* 1991;12:101-10.
121. Tsay PT, Chen MH, Oyen OJ. Osteoclast activation and recruitment after application of orthodontic force. *Am J Orthod Dentofacial Orthop* 1999;115:323-33.
122. Roberts WE, Ferguson DJ. Cell kinetics of periodontal ligament. In: Norton LA, Burstone CJ, editors. *Biology of tooth movement*. Boca Raton, Fla: CRC Press; 1995.
123. Mundy GR, Roodman GD. Osteoclast ontogeny and function. In: Peck WA, editor. *Bone and mineral research*. Amsterdam: Elsevier; 1987.
124. Hill PA. Bone remodeling. *Br J Orthod* 1998;25:101-7.
125. Meikle MC, Bord S, Hembry RM, Compston J, Croucher PI, Reynolds JJ. Human osteoblasts in culture synthesize collagenase and other matrix metalloproteins in response to osteotropic hormones and cytokines. *J Cell Sci* 1992;107:1093-9.
126. Roodman GD. Advances in bone biology: the osteoclast. *Endocrine Rev* 1996;17:308-32.
127. Martin TJ, Ng K. Mechanisms by which cells of the osteoblast lineage control osteoclast formation and function. *J Cell Biochem* 1994;56:357-66.
128. Fuller K, Gallagher AC, Chambers TJ. Osteoclast resorption—stimulating activity is associated with osteoblast surface and/or extracellular matrix. *Biochem Biophys Res Comm* 1991;181:67-73.
129. Laitala T, Vaananen HK. Inhibition of bone resorption in vitro by antisense RNA and DNA molecules targeted against car-

- bonic anhydrase II or two submits of vacolar H (+) ATPase. *J Clin Inv* 1994;93:2311-8.
130. Noxon SJ, King GJ, Gu G, Huang G. Osteoclast clearance from periodontal tissues during orthodontic tooth movement. *Am J Orthod Dentofacial Orthop* 2001;120:466-76.
131. Kobayashi Y, Hashimoto F, Miyamoto H, Kanaoka K, Miyazaki-Hawashita Y, Nakashima T. Force-induced osteoclast apoptosis in vivo is accompanied by elevation in transforming growth factor beta and osteoprotegerin expression. *J Bone Miner Res* 2000;15:1924-34.
132. Raisz LG. Physiology and pathophysiology of bone remodeling. *Clin Chem* 1999;45:1353-8.
133. Ericksen E, Moselkide L, Melsen F. Trabecular bone remodeling and balance in primary hyperparathyroidism. *Bone* 1986;7:213-21.
134. Whitson SW. Bone. Oral histology, development structure and function. St Louis: Mosby; 1998.
135. Bozal CB, Fiol JA, Ubios AM. Early osteocyte response to bone resorption stimuli. *Acta Odontol Latinoam* 2001;14:24-9.
136. Gluhak-Heinrich J, Ye L, Bonewald LF, Feng JQ, MacDougall M, Harris SE, et al. Mechanical loading stimulates dentin matrix protein 1 (DMP1) expression in osteocytes in vivo. *J Bone Miner Res* 2003;18:807-17.
137. Verna C, Dalstra M, Lee TC, Cattaneo PM, Melsen B. Microcracks in the alveolar bone following orthodontic tooth movement: a morphological and morphometric study. *Eur J Orthod* 2004;26:459-67.
138. Beersten W, McColloch CA, Sodek J. The periodontal ligament: a unique multi functional connective tissue. *Periodontology* 2000;1997:13:20-40.
139. Garant PR, Cho MI. Auto radiographic evidence of the coordination of the genesis of sharpeys fibres with new bone formation in the periodontium of the mouse. *J Periodont Res* 1979;14:107-14.
140. Keeling SD, King GJ, McCoy EA, Valdez M. Serum and alveolar bone phosphatase changes reflect bone turnover during orthodontic tooth movement. *Am J Orthod Dentofacial Orthop* 1993;103:320-6.
141. King GJ, Latta L, Ruttenberg AO, Keeling SD. Alveolar bone turnover and tooth movement in male rats after removal of orthodontic appliances. *Am J Orthod Dentofacial Orthop* 1997;111:266-75.
142. Rody WJ, King GJ, Gu G. Osteoclast recruitment to sites of compression in orthodontic tooth movement. *Am J Orthod Dentofacial Orthop* 2001;120:477-89.
143. Hughes B, King GJ. Effect of orthodontic appliance reactivation during the period of peak expansion in the osteoclast population. *Anat Rec* 1998;251:80-6.
144. Garant PR. Collagen resorption by fibroblasts. *J Periodontol* 1976;47:380-90.
145. Rygh P, Bowling K, Hovlandsdal L, Williams S. Activation of the vascular system. A main mediator of periodontal fiber remodeling in orthodontic movement. *Am J Orthod* 1986;89:453-68.
146. Attal U, Blaushild N, Brin I, Steigman S. Histomorphometric study of the periodontal vasculature during and after experimental tipping of the rat incisor. *Arch Oral Biol* 2001;46:891-900.
147. Howard PS, Kucich U, Taliwal R, Korostoff JM. Mechanical forces alter extracellular matrix synthesis by human periodontal ligament fibroblasts. *J Periodont Res* 1998;33:500-8.
148. McCulloch CAG, Lekic P, Mckee MD. Role of physical forces in regulating the form and function of periodontal ligament. *Periodontology* 2000;2000:24:56-72.
149. Bibby KJ, McCulloch CA. Regulation of cell volume and intracellular calcium in attached human fibroblasts responding to antiosmotic buffers. *Am J Physiol* 1994;266:C1639-49.
150. Redlich M, Roos AH, Reichenberg E, Zaks B, Mussig D, et al. Expression of tropoelastin in human periodontal ligament fibroblasts after simulation of orthodontic force. *Arch Oral Biol* 2001;49:119-24.
151. Bumann A, Carvalho RS, Schwarzer CL, Yen EH. Collagen synthesis from human PDL cells following orthodontic tooth movement. *Eur J Orthod* 1997;19:29-37.
152. Yoo SK, Wartia H, Soma K. Duration of orthodontic force affecting critical response of nitric oxide synthase in rat periodontal ligament. *J Med Dent Sci* 2004;51:83-8.
153. Akin E, Gurton AU, Olmez H. Effects of nitric oxide in orthodontic tooth movement in rats. *Am J Orthod Dentofacial Orthop* 2004;126:608-14.
154. Hayashi K, Igarashi K, Miyoshi K, Shinoda H, Mitani H. Involvement of nitric oxide in orthodontic tooth movement in rats. *Am J Orthod Dentofacial Orthop* 2002;122:306-9.
155. Shirazi M, Nilforoushan D, Alghari H, Dehpour AR. The role of nitric oxide in orthodontic tooth movement in rats. *Angle Orthod* 2002;72:211-5.
156. D'Attilio M, Maio FD, D'Arcangela C, Filippi MR, Felaco M, Lohinai Z, et al. Gingival endothelial and inducible nitric oxide synthase levels during orthodontic treatment: a cross sectional study. *Angle Orthod* 2004;74:851-8.
157. Redlich M, Shoshan S, Palmon A. Gingival response to orthodontic force. *Am J Orthod Dentofacial Orthop* 1999;116:152-8.
158. Danciu TE, Gagari E, Adam RM, Damoulis PD, Freeman MR. Mechanical strain delivers anti-apoptotic and proliferative signals to gingival fibroblasts. *J Dent Res* 2004;83:596-601.
159. Rivera Circuns AL, Tulloch JF. Gingival invagination in extraction sites of orthodontic patients: their incidence, effects in periodontal health and orthodontic treatment. *Am J Orthod* 1983;83:468-76.
160. Chase SW, Revesz J. Reestablishment of transseptal fibers following extraction. *J Dent Res* 1944;23:333-6.
161. Boisson M, Gianelly AA. Collagen synthesis in rat gingiva during tooth movement. *Am J Orthod* 1981;80:289-99.
162. Redlich M, Palmon A, Zaks B, Geremi E, Rayzman S, Shoshan S. The effect of mechanical force on the transcription levels of collagen type I and collagenase in cultured canine gingival fibroblasts. *Arch Oral Biol* 1998;43:313-6.
163. Ferguson DB. Oral bioscience. China: Churchill livingstone; 1999.
164. Sugiyama Y, Yamaguchi M, Kanekawa M, Yoshii M, Nozoe T, Nogimura A, et al. The level of cathepsin B in gingival crevicular fluid during human orthodontic tooth movement. *Eur J Orthod* 2002;25:71-6.
165. Last KS, Stanbury JB, Embery G. Glycosaminoglycans in human gingival crevicular fluid as indicators of active periodontal disease. *Arch Oral Biol* 1985;30:275-81.
166. Uematsu S, Mogi M, Deguchi T. Interleukin (IL)-1 $\beta$ , IL-6, tumor necrosis factor  $\alpha$ , epidermal growth factor and  $\beta_2$  microglobulin are elevated in gingival crevicular fluid during human orthodontic tooth movement. *J Dent Res* 1996;75:562-7.
167. Uematsu S, Mogi M, Deguchi T. Increase of transforming factor  $\beta_1$  in gingival crevicular fluid during human orthodontic tooth movement. *Arch Oral Biol* 1996;41:1091-5.

168. Grieve WG III, Johnson GK, Moore RN, Reinhardt RA, Dubois LM. Prostaglandin E (PGE) and interleukin-1 beta (IL-1beta) levels in gingival crevicular fluid during human orthodontic tooth movement. *Am J Orthod Dentofacial Orthop* 1994;105:369-74.
169. Lee KJ, Park YC, Yu HS, Choi SH, Yoo YJ. Effects of continuous and interrupted orthodontic force on interleukin-1 $\beta$  and prostaglandin E<sub>2</sub> production in gingival crevicular fluid. *Am J Orthod Dentofacial Orthop* 2004;125:168-77.
170. Lowney JJ, Norton LA, Shafer DM, Rossomando EF. Orthodontic forces increase tumor necrosis factor  $\alpha$  in human gingival sulcus. *Am J Orthod Dentofacial Orthop* 1995;108:19-24.
171. Griffiths GS, Moulson AM, Petrie A, James IT. Evaluation of osteocalcin and pyridinium cross links of bone collagen as markers of bone turnover in gingival crevicular fluid during different stages of orthodontic treatment. *J Clin Periodontol* 1998;25:492-8.
172. Insoft M, King GJ, Keeling SD. The measurement of acid and alkaline phosphatase in gingival crevicular fluid during orthodontic tooth movement. *Am J Orthod Dentofacial Orthop* 1996;109:287-96.
173. Perinetti G, Paolantonio M, D'Attilio M, D'Archivio D, Dolci M, Femminella B, et al. Asparate aminotransferase activity in gingival crevicular fluid during human orthodontic tooth movement. A controlled short-term longitudinal study. *J Periodontol* 2003;74:145-52.
174. Serra E, Perinetti G, D'Attilio M, Cordella C, Paolantonio M, Festa F, et al. Lactate dehydrogenase activity in gingival crevicular fluid during orthodontic treatment. *Am J Orthod Dentofacial Orthop* 2003;124:206-11.
175. Thilander B, Reitan K, et al: Tissue reactions in orthodontics. In: Graber TM, Vanarsdall RL, editors. *Orthodontics: current principles and techniques*. 3rd ed. St Louis: Mosby; 2000.
176. Gianelly AA. Force induced changes in the vascularity of the periodontal ligament. *Am J Orthod* 1969;55:5-11.
177. Bonafe-Oliveira L, Faltin RM, Arana-Chavez VE. Ultrastructural and histochemical examination of alveolar bone at the pressure areas of rat molars submitted to continuous orthodontic force. *Eur J Oral Sci* 2003;111:410-416.
178. Kohno T, Matsumoto Y, Kanno Z, Warita H, Soma K. Experimental tooth movement under light orthodontic forces—rates of tooth movement and changes of the periodontium. *J Orthod* 2002;29:129-35.
179. Quinn RS, Yoshikawa K. A reassessment of force magnitude in orthodontics. *Am J Orthod* 1985;88:252-60.
180. Iwasaki L, Haack JE, Nickel JC, Morton J, et al. Human tooth movement in response is continuous stress of low magnitude. *Am J Orthod Dentofacial Orthop* 2000;117:175-83.
181. Hixon EH, Aasen TO, Clark RA, Klosterman R, Miller SS, Odom WM. On force and tooth movement. *Am J Orthod* 1969;55:437-57.
182. Begg PR, Kesling PC. Differential force in orthodontic tooth movement. *Am J Orthod* 1956;42:481-510.
183. Davidovitch Z, Shanfeld JL. Cyclic AMP levels in alveolar bone of orthodontically treated cats. *Arch Oral Biol* 1975;20:567-74.
184. Collin-Osdoby P, Nickols GA, Osdoby P, et al. Bone cell function, regulation and communication: a role for nitric oxide. *J Cell Biochem* 1995;57:399-408.
185. Toda N, Okamura T. The pharmacology of nitric oxide in the peripheral nervous system of blood vessels. *Pharmacol Rev* 2003;55:271-324.
186. Alexander SA. Effects of orthodontic attachments on the gingival health of permanent second molars. *Am J Orthod Dentofacial Orthop* 1991;100:337-40.
187. Geiger AM. Mucogingival problems and the movement of mandibular incisors—a clinical review. *Am J Orthod* 1980;●●:511-27.
188. Dorfman HS. Mucogingival changes resulting from mandibular incisor tooth movement. *Am J Orthod* 1978;74:286.
189. Huser MC, Baehni PC, Lang R, et al. Effects on orthodontic bands on microbiologic and clinical parameters. *Am J Orthod Dentofacial Orthop* 1990;97:213-8.
190. Balenseifen JW, Madonia JV. Study of dental plaque in orthodontic patients. *J Dent Res* 1970;49:320-4.
191. Corbett JA, Brown LR, Keene HJ, Horton IM. Comparison of streptococcus mutans concentrations in non-banded and banded orthodontic patients. *J Dent Res* 1981;60:1936-42.
192. Ottolengui R. The physiological and pathological resorption of tooth roots. *Item of Interest* 1914;36:332-62.
193. Ketcham AH. A preliminary report of an investigation of apical root resorption of vital permanent teeth. *Int J Orthod* 1927;13:97-127.
194. Krishnan V. Critical issues concerning root resorption: a contemporary review. *World J Orthod* 2005;6:30-40.
195. Jarabak JR, Fizzell JA. *Technique and treatment with light wire edgewise appliance*. St Louis: C. V. Mosby; 1972.
196. Alexander SA. Levels of root resorption associated with continuous arch and sectional arch mechanics. *Am J Orthod Dentofacial Orthop* 1996;110:21-4.
197. Thompsun WJ. Current applications of Begg mechanics. *Am J Orthod* 1972;62:245-70.
198. Sameshima GT, Sinclair PM. Predicting and preventing root resorption—part II. Treatment factors. *Am J Orthod Dentofacial Orthop* 2001;119:11.
199. McNab S, Battistutta D, Taverne A, Symons AL. External apical root resorption following orthodontic treatment. *Angle Orthod* 2000;77:227-32.
200. Sharpe W, Reed B, Subtelny JD, Polson A. Orthodontic relapse, apical root resorption and crestal alveolar bone levels. *Am J Orthod Dentofacial Orthop* 1987;91:252-8.
201. L'Abée EM, Saderink GC. Apical root resorption during Begg treatment. *J Clin Orthod* 1985;19:60-1.
202. Beck BW, Harris EF. Apical root resorption in orthodontically treated subjects—analysis of edgewise and light wire mechanics. *Am J Orthod Dentofacial Orthop* 1994;105:350-61.
203. Remington DN, Joondeph D, Artun J, Reidel RA, Chapko MK. Long-term evaluation of root resorption occurring during orthodontic treatment. *Am J Orthod Dentofacial Orthop* 1989;96:43-6.
204. Sameshima GT, Asgarifer KO. Assessment of root resorption and root shape—periapicals vs panoramic films. *Angle Orthod* 2001;71:185-9.
205. Linge L, Linge BO. Patient characteristics and treatment variables associated with apical root resorption during orthodontic treatment. *Am J Orthod Dentofacial Orthop* 1991;99:35-43.
206. Sringkarnboriboon S, Matsumoto Y, Soma K. Root resorption related to hypo functional periodontium on experimental tooth movement. *J Dent Res* 2003;82:486-90.
207. Brezniak N, Wasserstein A. Orthodontically induced inflammatory root resorption—part II: clinical aspects. *Angle Orthod* 2002;72:180-4.
208. Al-Qawasmi RA, Hartsfield JK Jr, Everett ET, Flury L, Liu L, Foroud TM, et al. Genetic predisposition to external apical root resorption. *Am J Orthod Dentofacial Orthop* 2003;123:242-52.

209. Al-Qawasmī RA, Hartsfield JK Jr, Everett ET, Flury L, Liu L, Foroud TM, et al. Genetic predisposition to external apical root resorption: linkage of chromosome 18 marker. *J Dent Res* 2003;82:350-60.
210. Low E, Kharbanda O, Zoellner H, Darendeliler A. Genetic expression of RANK/RANKL and OPG during root resorption following orthodontic treatment. Available at: [www.chs.usyd.edu.au/conf2002/minipost/av-low.pdf](http://www.chs.usyd.edu.au/conf2002/minipost/av-low.pdf). Accessed Oct 1, 2005.
211. Janson GRP, Canto GDL, et al. A radiographic comparison of apical root resorption after orthodontic treatment with 3 different fixed appliance techniques. *Am J Orthod Dentofacial Orthop* 1999;118:262-73.
212. Sameshima GT, Sinclair PM. Predicting and preventing root resorption—Part I Diagnostic factors. *Am J Orthod Dentofacial Orthop* 2001;119:505-10.
213. Parker RJ, Harris EF. Directions of orthodontic tooth movements associated with apical root resorption of the maxillary central incisor. *Am J Orthod Dentofacial Orthop* 1998;114:677-83.
214. Copeland S, Green LJ. Root resorption in maxillary central incisors following active orthodontic treatment. *Am J Orthod Dentofacial Orthop* 1986;89:51-5.
215. Levander E, Malmgren O. Long-term follow-up of maxillary incisor with root end resorption. *Angle Orthod* 2000;22:25-92.
216. Linge BO, Linge L. Apical root resorption in upper anterior teeth. *Eur J Orthod* 1983;5:173-83.
217. Barkana I, Narayanan AS, et al. Cementum attachment protein enriches putative cementoblastic populations on root surfaces in vitro. *J Dent Res* 2000;79:1482-8.
218. Igarashi K, Adachi H, Mitani H, Shinoda H. Inhibitory effect of topical administration of a bisphosphonate (risedronate) on root resorption incident to orthodontic tooth movement in rats. *J Dent Res* 1996;75:1644-9.
219. Liu L, Igarashi K, Haruyama N, Saeki S, Shinoda H, Mitani H. Effects of local administration of clodronate on orthodontic tooth movement and root resorption in rats. *Eur J Orthod* 2004;26:469-73.
220. Villa PA, Oberti G, Moncada CA, Vasseur O, Jaramillo A, Tobon D, et al. Pulp-dentine complex changes and root resorption during intrusive orthodontic tooth movement in patients prescribed nabumetone. *J Endod* 2005;31:61-6.
221. Loberg EL, Engstrom C. Thyroid administration to reduce root resorption. *Angle Orthod* 1994;64:395-9.
222. Pouproms E, Loberg E, Engstrom C. Thyroid function and root resorption. *Angle Orthod* 1994;64:389-93.
223. Shirazi M, Dehpour AR, Jafari F. The effect of thyroid hormone on orthodontic tooth movement in rats. *J Clin Pediatr Dent* 1999;23:259-64.
224. Bialy TE, El-Shamy I, Graber TM. Repair of orthodontically induced root resorption by ultrasound in humans. *Am J Orthod Dentofacial Orthop* 2004;126:186-93.
225. Unsteseher RE, Nieberg LG, Weimer AD, Dyer JK. The response of human pulpal tissue after orthodontic force application. *Am J Orthod Dentofacial Orthop* 1987;92:220-4.
226. Labart WA, Taintor JF, Dyer JK, Weimer AD. The effect of orthodontic forces on pulp respiration in the rat incisor. *J Endod* 1980;6:724-7.
227. Hamersky PA, Weimer AD, Taintor JF. The effect of orthodontic force application on pulpal tissue respiration rate in the human premolar. *Am J Orthod* 1980;77:368-78.
228. Mostafa YA, El-Mangoury NH. Iatrogenic pulpal reactions to orthodontic extrusion. *Am J Orthod Dentofacial Orthop* 1991;99:30-4.
229. Nixon CE, Saviano JA, King GJ, Keeling SD. Histomorphometric study of dental pulp during orthodontic tooth movement. *J Endod* 1993;19:13-6.
230. Derringer KA, Jagers DC, Linden RWA. Angiogenesis in human dental pulp following orthodontic tooth movement. *Dent Res* 1996;75:1761-6.
231. Derringer KA, Linden RWA. Vascular endothelial growth factor and transforming growth factor beta released in human dental pulp during orthodontic force. *Arch Oral Biol* 2004;49:631-41.
232. Yamaguchi M, Kojima T, Kanekawa M, Aihara N, Nogimura A, Kasai K. Neuropeptides stimulate production of interleukin 1 $\beta$ , interleukin 6 and tumor necrosis factor in human dental pulp cells. *Inflamm Res* 2004;53:199-204.
233. Perinetti G, Varvara G, Festa F, Esposito P. Aspartate aminotransferase activity in pulp of orthodontically treated teeth. *Am J Orthod Dentofacial Orthop* 2004;125:88-92.
234. Murrell EF, Yen EH, Johnson RB. Vascular changes in the periodontal ligament after removal of orthodontic forces. *Am J Orthod Dentofacial Orthop* 1996;110:280-6.
235. Yoshida Y, Yoshida Y, Sasaki T, Yokoya K, Hiraide T, Shibasaki Y. Cellular roles in relapse processes of experimentally moved rat molars. *J Electron Microsc* 1999;48:147-57.
236. Terespolsky M, Brin I, Steigman S. The effect of functional occlusal forces on orthodontic tooth movement and tissue recovery in rats. *Am J Orthod Dentofacial Orthop* 2002;121:620-8.