



CASE REPORT

Pulp revascularization of necrotic bilateral bicuspid using a modified novel technique to eliminate potential coronal discolouration: a case report

K. Reynolds, J. D. Johnson & N. Cohenca

Department of Endodontics, School of Dentistry, University of Washington, Seattle, WA, USA

Abstract

Reynolds K, Johnson JD, Cohenca N. Pulp revascularization of necrotic bilateral bicuspid using a modified novel technique to eliminate potential coronal discolouration: a case report. *International Endodontic Journal*.

Aim To present a case report in which the pulp of two bilateral mandibular premolars with dens evaginatus were revascularized using a modified novel technique to avoid undesired crown discolouration.

Summary Recently, regeneration of necrotic pulps has become an alternative conservative treatment option for young permanent teeth with immature roots and is a subject of great interest in the field of endodontics. This novel procedure exploits the full potential of the pulp for dentine deposition and produces a stronger mature root that is better able to withstand the forces than can result in fracture. However, the current protocol has potential clinical and biological complications. Amongst them, crown discolouration, development of resistant bacterial strains and allergic reaction to the intracanal medication. In the case presented, a modified technique to avoid undesired crown discolouration was applied sealing the dentinal tubules of the chamber, thus avoiding any contact between the tri-antibiotic paste and the dentinal walls.

Key learning points

- Sealing the dentinal tubules of the chamber prevents the undesirable crown discolouration produced by tri-antibiotic medication whilst maintaining the revascularization potential of the pulp.
- Further research is warranted to seek an alternative infection control protocol capable of preventing possible allergic reactions and development of resistant strains of bacteria, as well as a biological material capable of inducing angiogenesis and allow a more predictable scaffold and tissue regeneration.

Correspondence: Dr Nestor Cohenca, Department of Endodontics, University of Washington, POB 357448, Seattle, WA 98195 7448, USA (Tel.: 1 206 543 5044; fax: 1 206 616 9085; e-mail: cohenca@u.washington.edu).

Keywords: crown discoloration, immature permanent tooth, open apex, pulp revascularization, vital pulp therapy.

Received 1 April 2008; accepted 19 July 2008

Introduction

In 1971, Nygaard-Östby & Hjortdal performed studies that can be considered the forerunner of pulpal regeneration (Nygaard-Ostby & Hjortdal 1971). The studies were aimed at determining how periodontal tissue would react, if the entire pulp was removed from the main canal and the apical part subsequently allowed to be filled with blood. Skoglund *et al.* (1978) further demonstrated that in a traumatic avulsion, blood vessels slowly grow from the apex toward the pulp horn by replacing the necrosed pulp left behind after the avulsion injury.

Since then, human avulsion case series (Kling *et al.* 1986) and controlled animal studies (Cvek *et al.* 1990a,b, Ritter *et al.* 2004) have shown radiographic and histological evidence of successful revascularization of immature permanent teeth after replantation. In this situation, the necrotic uninfected pulp acts as a scaffold for the in-growth of new tissue from the periapical area. The absence of bacteria is critical for successful revascularization because the new tissue will stop at the level it meets bacteria in the canal space (Myers & Fountain 1974, Yanpiset & Trope 2000). Studies to test the ability of topical antibiotics to improve revascularization outcomes in experimental avulsions (Yanpiset & Trope 2000, Ritter *et al.* 2004) have shown that topical doxycycline and minocycline can improve radiographic and histological evidence of revascularization in immature avulsed permanent teeth. Extrapolating from this information, it is hypothesized that once the canal infection is controlled, it resembles the avulsed tooth that has a necrotic but sterile pulp space. The blood clot is then introduced so as to mimic the scaffold that is in place with the ischemic necrotic pulp in the avulsed tooth and the access cavity is restored with a bacteria-tight seal. However, in necrotic cases with apical periodontitis it must be recognized that the vital tissue might not be normal pulp tissue, despite the fact that the root development continues and dentine maturation occurs. In teeth with open apices and necrotic pulps, it is possible that some vital pulp tissue and Hertwig's epithelial root sheath remain. When the canal is properly disinfected, the inflammatory process reverses and these tissues may proliferate.

Recently, the concept of revascularization of necrotic pulps regained interest and became an alternative conservative treatment option for young permanent teeth with immature roots (Sato *et al.* 1993, Hoshino *et al.* 1996, Sato *et al.* 1996, Iwaya *et al.* 2001, Banchs & Trope 2004, Windley *et al.* 2005, Thibodeau *et al.* 2007). As well stated by Windley *et al.* (2005), revascularization of immature teeth with apical periodontitis depends mainly on: (a) disinfection of the canal; (b) placement of a matrix in the canal for tissue in-growth; and (c) a bacterial tight seal of the access opening. Since the infection of the root canal system is considered to be polymicrobial, a combination of drugs would be needed to treat the diverse flora. Thus, the recommended protocol combines the use of metronidazole, ciprofloxacin and minocycline. Hoshino *et al.* (1996) performed a laboratory study testing the antibacterial efficacy of these drugs alone and in combination against the bacteria of infected dentine, infected pulps and periapical lesions. Alone, none of the drugs resulted in complete elimination of bacteria. However, in combination, these drugs were able to consistently sterilize all samples. In addition, a study by Sato *et al.* (1996) found that this drug combination was effective in killing bacteria in the deep layers of root canal dentine.

This novel procedure exploits the full potential of the pulp for dentine deposition and produces a stronger mature root that is better able to withstand fracture but has the potential for clinical and biological complications. Amongst them, crown discolouration (Windley *et al.* 2005), development of resistant bacterial strains (Greenstein & Polson 1998, Eickholz *et al.* 2002, Slots 2002) and allergic reaction to the intracanal medication (de Paz *et al.* 1999, Hausermann *et al.* 2005, Jappe *et al.* 2005, Isik *et al.* 2007, Madsen *et al.* 2007). Although coronal discolouration is not often reported in the literature in association with the use of this tri-antibiotic medication, it is believed that the marked discolouration may to be related to the use of minocycline. Kim *et al.* (2000) demonstrated that Ledermix (Lederle Pharmaceuticals, GMBH Wolfratshausen, Germany), an intracanal medication containing tetracycline, caused discolouration of immature teeth in a greater degree than in mature teeth.

A case report is presented in which the pulps of bilateral mandibular premolars became necrotic because of dens evaginatus and were revascularized using a modified novel technique to avoid undesired crown discolouration.

Case report

An 11-year-old Asian girl was referred to the graduate endodontic clinic by her dentist for evaluation and root canal treatment of her mandibular second premolars. The medical history was non-contributory. A review of the dental history revealed that the patient had sought dental care 3 months prior because of swelling and pain in the mandibular left premolar region. The patient was prescribed penicillin VK 1000 mg daily by her general dentist. The pain and swelling subsided within a week. Upon clinical examination, an occlusal tubercle consistent with dens evaginatus (Fig. 1a,b) was diagnosed. Intraoral sinus tracts, buccal to the mandibular left and right second premolars were present (Fig. 1c,d). No caries were clinically detected. Pulp sensibility tests using 1, 1, 1, 2-tetrafluoroethane (Endo-Ice; Hygenic Corp., Akron, OH, USA) produced no response from either mandibular second premolars whilst the adjacent mandibular first molars and premolars responded to cold without lingering. Neither mandibular second premolars were sensitive to percussion or palpation. Periodontal probing affirmed normal attachment with no probing depths >3 mm and normal physiological mobility. No crown discolouration was observed.

Radiographically both mandibular second premolars had a similar appearance, with widened periodontal ligament space, incomplete root formation and diffuse periapical radiolucencies 6 × 6 mm in size (Fig. 2a,b). No carious lesions were diagnosed (Fig. 2c) and the root development appeared arrested with wide open apices in both mandibular second premolars. A gutta-percha point was used to trace the sinus tract and a periapical radiograph taken, demonstrating the association between the drainage and the periradicular radiolucency (Fig. 2d).

Based on the results of clinical and radiographic examination, the pulpal and periradicular diagnosis of the mandibular left and right second premolars was determined as pulpal necrosis with chronic suppurative periradicular periodontitis. Taking into consideration the stage of root development, the maturation of the dentinal walls and the wide-open apices, the treatment plan included pulp revascularization of both mandibular second premolars. After a comprehensive discussion of the risks, complications and possible outcomes of this treatment, parental consent was obtained.

Following administration of local anaesthesia, the mandibular left second premolar was isolated with rubber dam. Under a dental-operating microscope, access preparation was performed and a single orifice with a wide canal was revealed. No purulent exudates or haemorrhage were observed in the chamber (Fig. 3a). Length was estimated

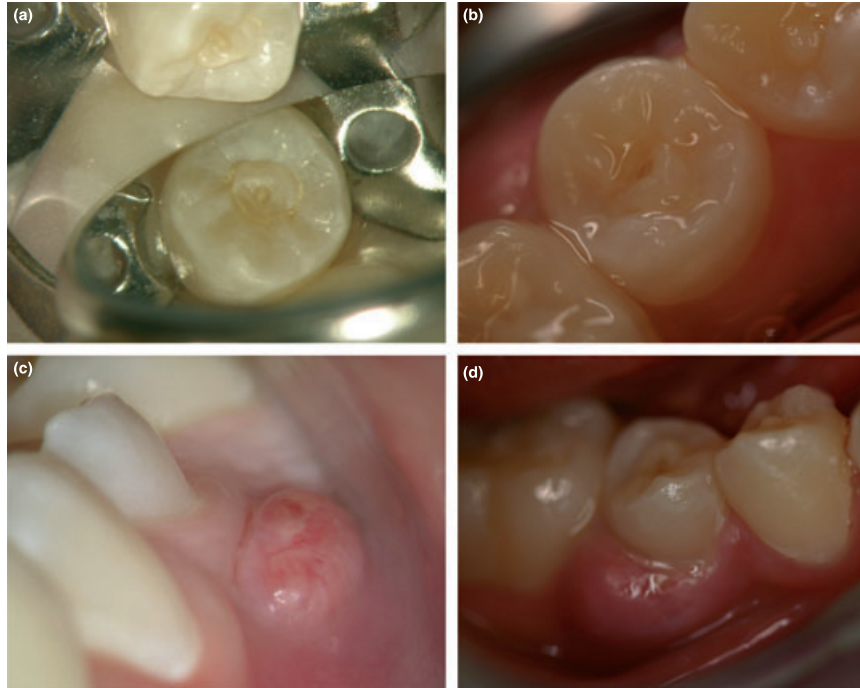


Figure 1 (a,b) Clinical photographs showing an occlusal tubercle consistent with dens evaginatus in both mandibular second premolars. (c,d) An intraoral localized swelling buccal to the mandibular left and right second premolars is noted. [20mlNaocl6%-->5mlSaline-->10mlCHX2](#)

radiographically using a size 15 K-file. The selection of the file size was made to avoid any damage to the canal walls. The irrigation protocol included a slow and careful irrigation of 20 mL of 6% sodium hypochlorite, 2 mm back from working length. This was followed by a 5 mL rinse of saline and then a final irrigation of 10 mL of 2.0% chlorhexidine gluconate (Vista Dental, Racine, WI, USA).

A modification of the current clinical protocol (Sato *et al.* 1996, Banchs & Trope 2004) was established to avoid crown discoloration. This novel approach seals the dentinal tubules of the chamber, thus avoiding any contact between the tri-antibiotic paste and the dentinal walls. The inner surfaces of the coronal access were etched for 20 s with 35% phosphoric acid (Ultra-Etch; Ultradent, South Jordan, UT, USA) and rinsed. Bonding agent was applied (Single Bond 3M, Minneapolis, MN, USA) to the etched surfaces and cured for 20 s. Then, a Root Canal Projector (CJM Engineering Inc., Santa Barbara, CA, USA) with a size 20 K-file inside the projector was placed into the prepared access to maintain patency. The space between the projector and the coronal dentine was sealed with flowable composite (PermaFlo DC; Ultradent, South Jordan, UT, USA) and light-cured for 30 s (Fig. 3b). The projector was then removed by engaging it with a Hedström file.

The tri-antibiotic paste was prepared immediately prior to treatment by mixing 250 mg of Ciprofloxacin, 250 mg of Metronidazole and 250 mg of Minocycline with sterile water (Fig. 3c). A 20G needle was set 2 mm short of working length and used to introduce the medication into the canal using a backfill approach up to the level of the cemento-enamel junction (CEJ) (Fig. 3d). The tooth was then temporarily sealed with a cotton pellet and Cavit (3M ESPE, Seefeld, Germany).

One month later, the patient presented with localized swelling and pain on her mandibular right quadrant associated with the mandibular right second premolar. The

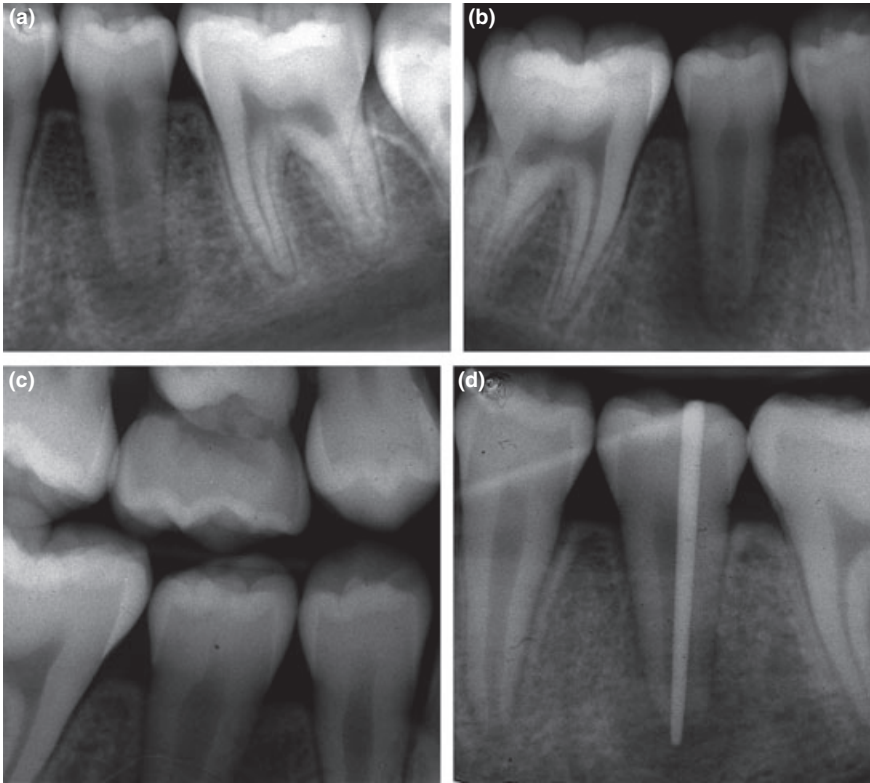


Figure 2 (a,b) Radiographic examination demonstrated incomplete root formation and diffuse periapical radiolucencies of 6 × 6 mm in size in both mandibular second premolars. (c) No carious lesion was diagnosed. (d) A gutta-percha point was used to trace the sinus tract and a periapical radiograph was taken, demonstrating the association between the drainage and the periradicular radiolucency.

swelling was visible extraorally along the lower border of the mandible in the submandibular space, tender to palpation and non-fluctuant. The patient's temperature was 36.6 °C. Under local anaesthetic and rubber dam isolation, the mandibular right second premolar was accessed for treatment. Upon access, no purulent exudate was noted and only some minor haemorrhage. After working length was determined, the canal was carefully irrigated with 10 mL of 6% sodium hypochlorite up to 2 mm from working length at which time the access was sealed with a cotton pellet and Cavit as a temporary restoration. In case of persistent pain, the patient was instructed to take ibuprofen 200 mg. Incision and drainage was not indicated, as the draining sinus tract was still present and the swelling was non-fluctuant.

At the same appointment, it was noted that the mandibular left second premolar was asymptomatic and was not sensitive to palpation and percussion. The sinus tract associated with the mandibular left second premolar had healed.

Four-days later the swelling was significantly reduced, as well as the patients' complain of pain in the mandibular right quadrant. The sinus tract stoma associated with the mandibular right second premolar was still present. At this appointment it was decided to continue treatment of the mandibular left second premolar as previously planned. Under local anaesthesia and rubber dam isolation, the tooth was re-accessed. No purulent drainage or haemorrhage was noted upon access and the tri-antibiotic paste was removed with 6% sodium hypochlorite with the irrigation needle tip 2 mm short of the working

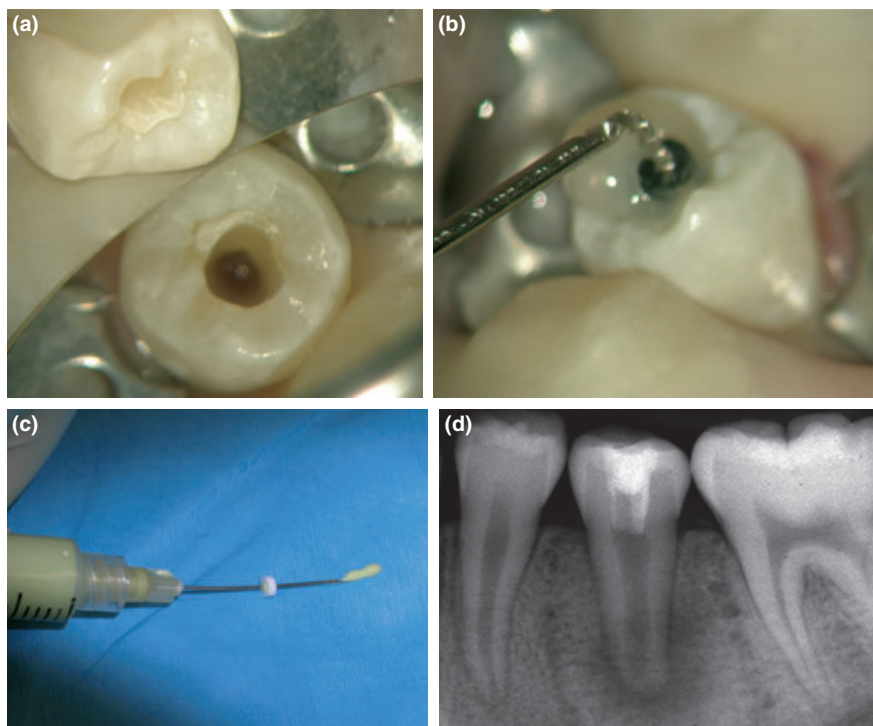


Figure 3 (a) Mandibular left second premolar was accessed under a dental-operating microscope, without evidence of purulent exudates or haemorrhage. (b) A Root Canal Projector with a size 20 K-file inside the projector was placed into the prepared access to maintain patency. The space between the projector and the coronal dentine was sealed with flowable composite and cured for 30 s. (c) The tri-antibiotic paste was prepared immediately prior to treatment and loaded in a syringe with a 20G needle and a rubber stopper. (d) The canal was dressed using a backfill approach up to the level of the cemento-enamel junction (CEJ) and the tooth was then temporarily sealed. Notice the flowable composite sealing the access walls up to the level of the CEJ.

length. With the root canal infection controlled, the regenerative process was initiated. A sterile size 20 K-File was introduced 2 mm past the working length to stimulate bleeding and create a biological scaffold for pulpal regeneration. The intracanal haemorrhage was controlled below the CEJ by applying pressure with a sterile saline-soaked cotton pellet until a clot was established. ProRoot grey MTA (Dentsply Tulsa Dental, Johnson City, TN, USA) was then mixed with sterile water and carefully placed above the blood clot up to the level of the CEJ. The access was sealed with a moist cotton pellet and Cavit. At the same appointment, the mandibular right second premolar was anaesthetized and isolated with rubber dam. No purulent drainage or haemorrhage was observed upon access of the mandibular right second premolar. At this time, the same clinical protocol used to treat the mandibular left second premolar was used on the mandibular right second premolar. Using the same novel technique mentioned previously to avoid discolouration, flowable composite was applied to the coronal dentine sealing the dentinal tubules preventing contact with the tri-antibiotic paste. The tri-antibiotic dressing was placed into the canal with a syringe set at 2 mm from the working length. The access was then sealed with a cotton pellet and Cavit.

Two weeks following the last appointment, the patient returned asymptomatic and without swelling or sinus tract stomas on either side of the mandible. Under local anaesthesia and rubber dam isolation in the mandibular left quadrant, the temporary restoration was removed from the mandibular left second premolar and the coronal

access refined, cleaned and restored with resin-bonded composite (Prisma TPH; Dentsply Culk, York, PA, USA).

Four weeks after the tri-antibiotic medication was placed on the mandibular right second premolar, the patient was asymptomatic and without swelling or sinus tract stomas on either side. Under local anaesthesia and rubber dam isolation, the tooth was treated using the same clinical protocol used for the mandibular left second premolar. Briefly, sodium hypochlorite irrigation was used for removal of the tri-antibiotic paste followed by stimulation of haemorrhage, clot formation and MTA placement. The tooth was then temporized and the patient was rescheduled for the final composite restoration which was place 2 weeks later without incident or change in symptoms.

During the 18-month follow-up period the patient remained asymptomatic. Clinically, both mandibular second premolars responded within normal limits to cold test using 1, 1, 1, 2-tetrafluoroethane. No tenderness to percussion or palpation was noted and the periodontal examination revealed no pocket depths over 3 mm and normal physiological mobility. The radiographs demonstrated evidence of periradicular bone healing and significant root development with maturation of the dentine as compared with the preoperative radiographs (Fig. 4a,b). Clinically, the mandibular right second premolar teeth showed no change in shade or colour (Fig. 4c), although mandibular left second premolar revealed a slight cervical discolouration possibly related to the use of grey MTA (Fig. 4d).

Discussion

An immature tooth with early irreversible pulp involvement presents with thin divergent or parallel dentinal walls. This situation creates clinical challenges in disinfection, and as a result, affects the long-term outcome of the treatment. Traditionally, calcium hydroxide has been used as the intra-canal medicament in apexification procedures. However, because of its high pH it will cause necrosis of tissues that can potentially differentiate into new pulp. Moreover, even if rendered successful, apexification procedures will leave a short root with thin dentinal walls with a high risk of root fracture.

Revascularization of a pulp-like tissue for dentine deposition will allow further development of the root and dentinal structure with a better long-term prognosis. As shown in the present case, clinical and radiographic evaluation at 6-month intervals is stressed after revascularization therapy, so as to assess pulp vitality and progression of root development. Current vitality tests still depend on neurological stimulation and its reliability on immature teeth is considered questionable (Fulling & Andreasen 1976, Fuss *et al.* 1986). The radiographic diagnosis of periapical pathosis may also become difficult in immature teeth because of the normal radiolucency of the developing root sheath which occurs apically as the root matures. Comparison of root formation with the contralateral teeth should always be performed to evaluate treatment outcome.

If crown discolouration occurs, treatment by intracoronal bleaching with sodium perborate should be attempted. In addition, the use of white MTA instead of grey MTA should also be considered. The modified protocol described in the present article is an attempt to avoid the undesired crown discolouration. It also describes a safer and more reliable technique for antibiotic dressing using a 20G needle with a backfill approach. This novel approach prevents the undesirable crown discolouration produced by the tri-antibiotic medication, whilst maintaining the revascularization potential of the pulp. Taking in consideration the importance of aesthetics, this technique could be consider for all anterior teeth in which the use of the tri-antibiotic paste is indicated for revascularization purposes. Further research is warranted to seek an alternative infection control protocol capable of preventing possible allergic reactions and development of resistant strains of

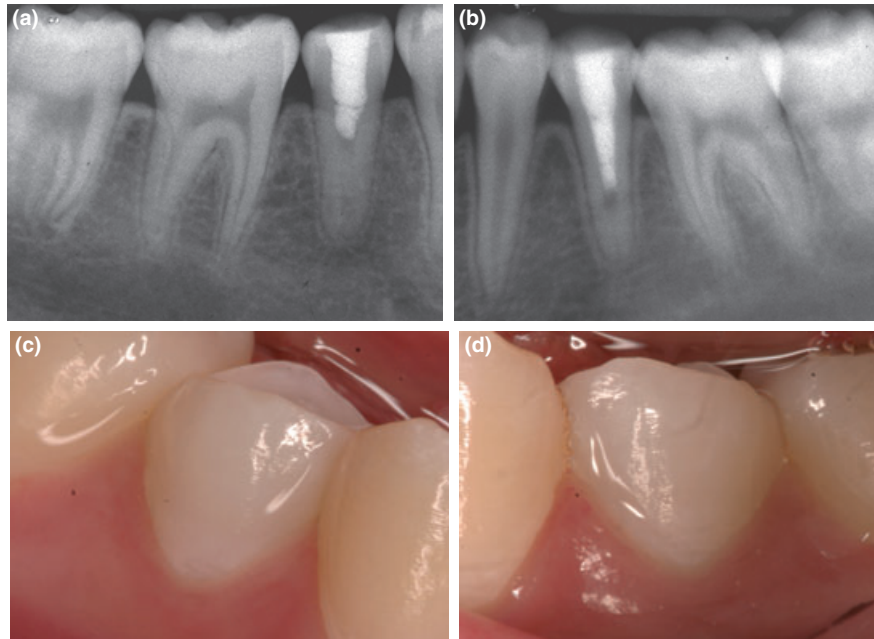


Figure 4 Eighteen-month follow-up. (a, b) Both mandibular second premolars demonstrated significant root development with maturation of the dentine. (c) Clinically, the mandibular right second premolar presented no crown discoloration whilst (d) the mandibular left second premolar showed a slight cervical discoloration related to the use of grey MTA.

bacteria, as well as a biological material capable of inducing angiogenesis and allow a more predictable scaffold and tissue regeneration.

Disclaimer

Whilst this article has been subjected to Editorial review, the opinions expressed, unless specifically indicated, are those of the author. The views expressed do not necessarily represent best practice, or the views of the IEJ Editorial Board, or of its affiliated Specialist Societies.

References

- Banchs F, Trope M (2004) Revascularization of immature permanent teeth with apical periodontitis: new treatment protocol? *Journal of Endodontics* **30**, 196–200.
- Cvek M, Cleaton-Jones P, Austin J, Lownie J, Kling M, Fatti P (1990a) Pulp revascularization in reimplanted immature monkey incisors—predictability and the effect of antibiotic systemic prophylaxis. *Endodontics and Dental Traumatology* **6**, 157–69.
- Cvek M, Cleaton-Jones P, Austin J, Lownie J, Kling M, Fatti P (1990b) Effect of topical application of doxycycline on pulp revascularization and periodontal healing in reimplanted monkey incisors. *Endodontics and Dental Traumatology* **6**, 170–6.
- Eickholz P, Kim TS, Burklin T *et al.* (2002) Non-surgical periodontal therapy with adjunctive topical doxycycline: a double-blind randomized controlled multicenter study. *Journal of Clinical Periodontology* **29**, 108–17.
- Fulling HJ, Andreasen JO (1976) Influence of maturation status and tooth type of permanent teeth upon electrometric and thermal pulp testing. *Scandinavian Journal of Dental Research* **84**, 286–90.
- Fuss Z, Trowbridge H, Bender IB, Rickoff B, Sorin S (1986) Assessment of reliability of electrical and thermal pulp testing agents. *Journal of Endodontics* **12**, 301–5.

- Greenstein G, Polson A (1998) The role of local drug delivery in the management of periodontal diseases: a comprehensive review. *Journal of Periodontology* **69**, 507–20.
- Hausemann P, Scherer K, Weber M, Bircher AJ (2005) Ciprofloxacin-induced acute generalized exanthematous pustulosis mimicking bullous drug eruption confirmed by a positive patch test. *Dermatology* **211**, 277–80.
- Hoshino E, Kurihara-Ando N, Sato I *et al.* (1996) In-vitro antibacterial susceptibility of bacteria taken from infected root dentine to a mixture of ciprofloxacin, metronidazole and minocycline. *International Endodontic Journal* **29**, 125–30.
- Isik SR, Karakaya G, Erkin G, Kalyoncu AF (2007) Multidrug-induced erythema multiforme. *Journal of Investigational Allergology & Clinical Immunology* **17**, 196–8.
- Iwaya SI, Ikawa M, Kubota M (2001) Revascularization of an immature permanent tooth with apical periodontitis and sinus tract. *Dental Traumatology* **17**, 185–7.
- Jappe U, Schnuch A, Uter W (2005) Rosacea and contact allergy to cosmetics and topical medicaments – retrospective analysis of multicentre surveillance data 1995–2002. *Contact Dermatitis* **52**, 96–101.
- Kim ST, Abbott PV, McGinley P (2000) The effects of Ledermix paste in discolouration of immature teeth. *International Endodontic Journal* **33**, 233–7.
- Kling M, Cvek M, Mejare I (1986) Rate and predictability of pulp revascularization in therapeutically reimplanted permanent incisors. *Endodontics and Dental Traumatology* **2**, 83–9.
- Madsen JT, Thormann J, Kerre S, Andersen KE, Goossens A (2007) Allergic contact dermatitis to topical metronidazole – 3 cases. *Contact Dermatitis* **56**, 364–6.
- Myers WC, Fountain SB (1974) Dental pulp regeneration aided by blood and blood substitutes after experimentally induced periapical infection. *Oral Surgery Oral Medicine Oral Pathology* **37**, 441–50.
- Nygaard-Ostby B, Hjortdal O (1971) Tissue formation in the root canal following pulp removal. *Scandinavia Journal of Dental Research* **79**, 333–49.
- de Paz S, Perez A, Gomez M, Trampal A, Dominguez Lazaro A (1999) Severe hypersensitivity reaction to minocycline. *Journal of Investigational Allergology Clinical Immunology* **9**, 403–4.
- Ritter AL, Ritter AV, Murrah V, Sigurdsson A, Trope M (2004) Pulp revascularization of replanted immature dog teeth after treatment with minocycline and doxycycline assessed by laser Doppler flowmetry, radiography, and histology. *Dental Traumatology* **20**, 75–84.
- Sato T, Hoshino E, Uematsu H, Noda T (1993) In vitro antimicrobial susceptibility to combinations of drugs on bacteria from carious and endodontic lesions of human deciduous teeth. *Oral Microbiology & Immunology* **8**, 172–6.
- Sato I, Ando-Kurihara N, Kota K, Iwaku M, Hoshino E (1996) Sterilization of infected root-canal dentine by topical application of a mixture of ciprofloxacin, metronidazole and minocycline in situ. *International Endodontic Journal* **29**, 118–24.
- Skoglund A, Tronstad L, Wallenius K (1978) A microangiographic study of vascular changes in replanted and autotransplanted teeth of young dogs. *Oral Surgery Oral Medicine Oral Pathology* **45**, 17–28.
- Slots J (2002) Selection of antimicrobial agents in periodontal therapy. *Journal of Periodontal Research* **37**, 389–98.
- Thibodeau B, Teixeira F, Yamauchi M, Caplan DJ, Trope M (2007) Pulp revascularization of immature dog teeth with apical periodontitis. *Journal of Endodontics* **33**, 680–9.
- Windley W, Teixeira F, Levin L, Sigurdsson A, Trope M (2005) Disinfection of immature teeth with a triple antibiotic paste. *Journal of Endodontics* **31**, 439–43.
- Yanpiset K, Trope M (2000) Pulp revascularization of replanted immature dog teeth after different treatment methods. *Endodontics and Dental Traumatology* **16**, 211–7.