



## CASE REPORT

# Complex endodontic treatment of an immature type III dens invaginatus. A case report

**E. R. Fregani<sup>1,2</sup>, L. F. B. Spinola<sup>2</sup>, J. R. O. Sônego<sup>2</sup>, C. E. S. Bueno<sup>2</sup> & A. S. De Martin<sup>2</sup>**

<sup>1</sup>Department of Stomatology, A. C. Camargo Cancer Hospital, São Paulo; and <sup>2</sup>São Leopoldo Mandic Dental Research Centre, Campinas, São Paulo, Brazil

### Abstract

**Fregani ER, Spinola LFB, Sônego JRO, Bueno CES, De Martin AS.** Complex endodontic treatment of an immature type III dens invaginatus. A case report. *International Endodontic Journal*, 41, 913–919, 2008.

**Aim** To report the endodontic treatment of an immature maxillary central incisor with dens invaginatus.

**Summary** Dens invaginatus is a rare malformation of teeth, probably resulting from an infolding of the dental papilla during tooth development. The present case describes the complex endodontic treatment of a type III dens invaginatus in an immature maxillary central incisor with a necrotic pulp and abscess formation. The initial treatment goal was to achieve apexification of the pseudocanal root and conservative root canal treatment in the main canal. Following 1-year of treatment with calcium hydroxide dressings, radiography revealed a healing response, but no sign of a hard tissue barrier at the apex. Periapical surgery with the placement of a zinc oxide cement (IRM) root-end filling was considered successful at the 4-year follow-up.

### Key learning points

- The complexity of the canal system and open apex in dens invaginatus present a challenge to endodontic treatment.
- Correct diagnosis and treatment planning are fundamental to treatment of dens invaginatus.
- Periapical surgery is indicated in cases of unsuccessful apexification in immature teeth with dens invaginatus and nonvital pulp.

**Keywords:** calcium hydroxide, dens invaginatus, endodontic treatment.

Received 8 July 2007; accepted 4 February 2008

Correspondence: Dr Eduardo Fregani, Rua Alves Guimarães, 150/1307, São Paulo, SP 05410-000, Brazil (Tel.: 55 11 2189-5129; fax: 55 11 2189-5100; e-mail: erfreg@terra.com.br).

## Introduction

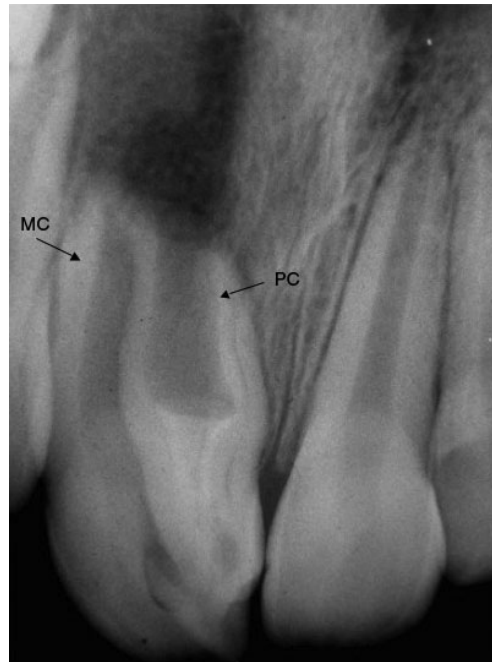
Dens invaginatus is a dental developmental abnormality in which the enamel organ is disorganized, leading to an invagination in the tooth crown before the calcification phase (Chen *et al.* 1998, de Sousa & Bramante 1998). The cavity formed retains external communication through the foramen coecum. The aetiology remains uncertain and its prevalence varies substantially, ranging from 0.25 to 10%, depending on the type of classification (Jung 2004). Most authors use Oehlers (1957) classification based on the extent of the invaginated dental tissue. Type I, characterized by the invagination confined within the crown, extending only to the cemento-enamel junction; type II, characterized by the invagination extending apically beyond the cemento-enamel junction, where connection between the invagination and the pulp is possible; and type III, characterized by the invagination extending beyond the cemento-enamel junction and exhibiting a second foramen into the lateral periodontal ligament or periradicular tissue. Various techniques and approaches to treating dens invaginatus have been reported in the literature, including preventive sealing or filling of the invagination, root canal treatment either associated or not with endodontic apical surgery, intentional replantation and extraction (Hata & Toda 1987, de Sousa & Bramante 1998, De Martin *et al.* 2005).

## Case report

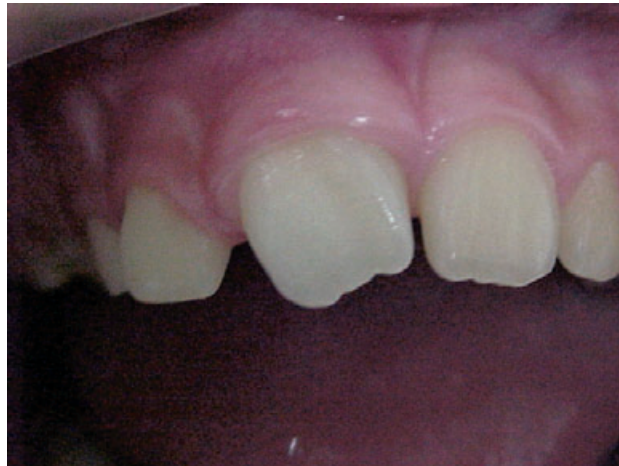A 9-year-old boy with severe pain and facial swelling was referred for endodontic treatment of his maxillary right central incisor. An extensive intra-oral swelling was observed in the buccal area above the affected incisor, which showed clinical signs of morphological alteration, with a pronounced 'dens invaginatus' on the palatal surface, but no visible foramen coecum. The tooth had no obvious decay; there was no history of oral-facial trauma and the colour of the tooth did not differ from that of the adjacent teeth. The total number of teeth in the anterior region was normal. Vitality tests were performed with refrigerant spray (dichlorotetrafluoroethane, Endo-Frost; Roeko, Langenau, Germany) and there was no response from the right maxillary central incisor.

Radiographic examination revealed the presence of an immature Oehlers type III dens invaginatus and an extended radiolucent area in the apical region. A foramen coecum was visible as a radiolucency on the crown (Fig. 1). A large invagination extended from the crown to the apex of the root (pseudocanal), with no evident communication with the main canal. Moreover, the main canal was associated with complete root formation, but as seen on Fig. 1, the pseudocanal apex was not completely shaped.

With the diagnosis of acute alveolar abscess and after local anaesthesia, surgical soft tissue drainage was performed and systemic analgesics were prescribed (Paracetamol 500 mg, 6/6 h.s. for 2 days, Janssen-Cilag Farmacêutica, São José dos Campos, Brazil). After 1 week, there were no signs of acute inflammation and conservative nonsurgical root canal treatment was the treatment of choice for the main canal (with full root formation). Figure 2 shows the clinical signs of morphological alteration in the maxillary right central incisor at that time. After isolating the tooth, access preparation was completed and two canal orifices were located. Preparation of the main canal was accomplished with the balanced-force technique of instrument manipulation and 5.25% sodium hypochlorite irrigant. Working length was determined with an apex locator (Root ZX; J. Morita Europe GmbH, Dietzenbach, Germany) and a radiograph. After canal preparation, the canal was irrigated with 17% EDTA for 3 min followed by irrigation with 5.25% sodium hypochlorite, then dried and filled with Gutta-percha and AH-plus root canal sealer (Dentsply-De Trey, Konstanz, Germany), using lateral compaction and Gutta-condensers (Dentsply-Maillefer, Ballaigues, Switzerland).



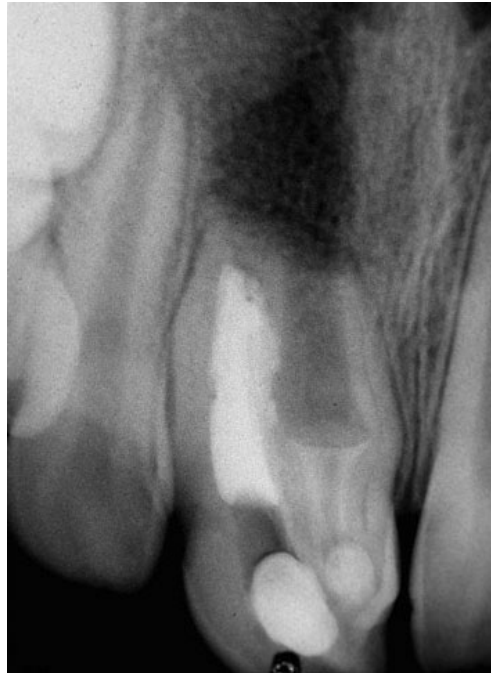**Figure 1** Periapical radiograph shows a type III dens invaginatus. Main canal (MC) and pseudo-canal (PC) are indicated. Apical radiolucence and open apex are also observed.



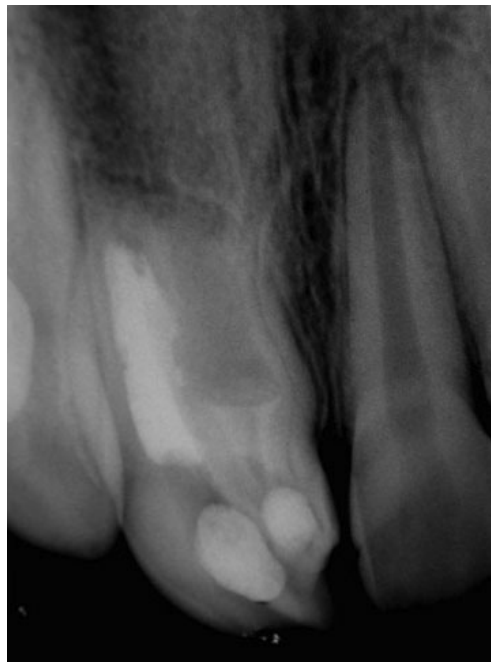**Figure 2** Clinical signs of morphological alteration in the maxillary right central incisor.

The pseudocanal was filled with calcium hydroxide and an apexification treatment was initiated (Fig. 3). The calcium hydroxide dressing was renewed every month for 1 year and although there was radiographic evidence of healing, no hard tissue barrier was formed. The patient failed to attend for 2 years, and when a follow-up periapical radiograph was taken, it revealed no hard tissue barrier formation (Fig. 4). A decision was made at this stage to complete treatment by a combined nonsurgical and surgical approach.

First, the coronal root filling material was condensed with warm hand instrument and the coronal cavity was sealed with a composite restoration. The radiographs showed

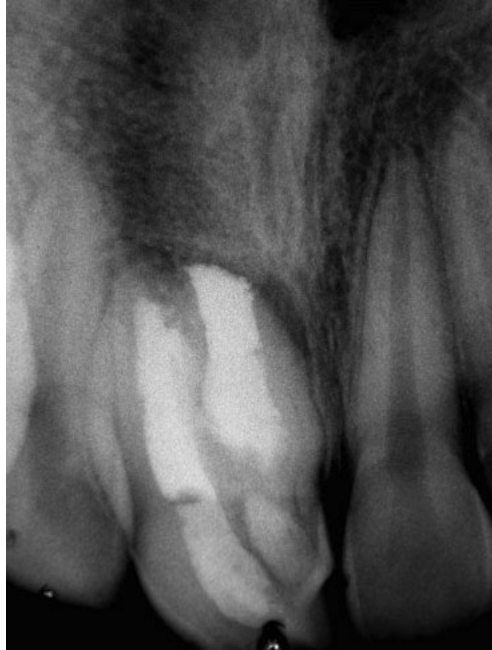

**Figure 3** Periapical radiograph immediately after main canal filling and calcium hydroxide treatment for pseudo canal apexification.



**Figure 4** Periapical radiograph shows healing of the periapical lesion, but no evidence of hard tissue barrier was found.

inadequate root filling with poor apical adaptation. Surgical access followed at the same appointment and a triangular flap was raised before removing the extruded root filling material. An immature root apex with defective dentine walls was revealed and its surface



**Figure 5** A 4-year follow-up periapical radiograph.

was corrected with appropriate ultrasonic tips, a zinc oxide cement (IRM) was placed into the root-end cavity. The flap was sutured for 7 days; an antibiotic (Amoxicillin 250 mg each 8 h for 7 days; Medley S/A Indústria Farmacêutica, Campinas, Brazil), analgesic (Paracetamol 500 mg, 6/6 h.s. for 2 days; Janssen-Cilag Farmacêutica, São José dos Campos, Brazil) and 2% chlorhexidine mouth rinse were prescribed.

After 4 years of clinical and radiographic follow-up, the tooth was asymptomatic, normal clinical conditions were observed and the periapical appearance on the radiograph was considered healthy (Fig. 5).

### Discussion

Endodontic treatment in teeth with dens invaginatus, which extends up to the apical region and associated with apical pathosis, generally involves complicated procedures that require accurate diagnosis and appropriate treatment planning (Chen *et al.* 1998, De Martin *et al.* 2005). There is a high incidence of pulp infection and degeneration associated with this anomaly, and because of this, Oehlers (1957) emphasized the importance of early diagnosis to prevent pulp necrosis and periapical inflammation. However, in many cases of conventional root canal treatment, surgical or combined treatments need to be carried out (Ferguson *et al.* 1980, Holtzman & Lezion 1996, Pai *et al.* 2004).

The complexity of the canal system and possible open apex present a challenge to root canal treatment (da Silva Neto *et al.* 2005, Sübay & Kayatas 2006, Soares *et al.* 2007). Furthermore, the morphology of the main canal may be irregular, circular or narrow and a possible explanation is that the invaginated tissue occupied and compressed the main canal at different levels (De Smit & Demaut 1982, Soares *et al.* 2007). As observed in the present case, pulp necrosis and acute periradicular abscess are frequently found in cases of dens invaginatus (Ferguson *et al.* 1980, Rotstein *et al.* 1987, Yeh *et al.* 1999, De Martin *et al.* 2005).

Nonsurgical root canal treatment should be attempted first. Irrespective of the size of the periradicular lesion, surgical treatment is the second option and is only indicated when nonsurgical root canal treatment has failed (Yeh *et al.* 1999, Steffen & Splieth 2000, Pai *et al.* 2004, Subay & Kayatas 2006). In this case, the option was to attempt apexification with the use of calcium hydroxide, as other reports have indicated this to be successful (Ferguson *et al.* 1980, Tarjan & Rozsa 1999, Yeh *et al.* 1999, Jung 2004). However, the technical result obtained was not satisfactory and further surgical treatment was indicated.

Although MTA has been widely evaluated and is the preferred root-end material, IRM has been extensively studied with favourable results (Chong *et al.* 2003). As evidenced with this case and others, it can be considered as an alternative material (Bernabé *et al.* 2005, Lindeboom *et al.* 2005).

The use of zinc oxide cement may lead to the formation of a fibrous barrier that has been shown to reduce the initial toxicity of the cement enhancing tissue repair (Olsen *et al.* 1994). Pitt Ford *et al.* (1994) reported that tissue response to IRM was one of toleration rather than biocompatibility. So, the radiolucency that can be observed in Fig. 5 suggests scar formation that tends to hinder complete periapical regeneration.

Periapical surgery is indicated in cases in which conventional root canal therapy has failed, and in teeth that present anatomic variations that do not allow access to and cleaning of all the parts of the canal system, such as many cases of dens invaginatus type III with periapical lesions (Hata & Toda 1987, da Silva Neto *et al.* 2005, Sübay & Kayatas 2006, Soares *et al.* 2007).

### Conclusion

With the complications presented in this case of dens invaginatus type III, including an open apex and acute periapical abscess, a combination of conservative and surgical treatments preserved a functional and aesthetic tooth during a 4-year follow-up.

### Disclaimer

Whilst this article has been subjected to Editorial review, the opinions expressed, unless specifically indicated, are those of the author. The views expressed do not necessarily represent best practice, or the views of the IEJ Editorial Board, or of its affiliated Specialist Societies.

### References

- Bernabé PF, Holland R, Morandi R *et al.* (2005) Comparative study of MTA and other materials in retrofilling of pulpless dogs' teeth. *Brazilian Dental Journal* **16**, 149–55.
- Chen YH, Tseng CC, Harn WM (1998) Dens invaginatus. Review of formation and morphology with 2 case reports. *Oral Surgery, Oral Medicine, Oral Pathology, Oral Radiology, and Endodontics* **86**, 347–52.
- Chong BS, Pitt Ford TR, Hudson MB (2003) A prospective clinical study of mineral trioxide aggregate and IRM when used as root-end filling materials in endodontic surgery. *International Endodontic Journal* **36**, 520–6.
- De Martin AS, da Silveira Bueno CE, Sandhes Cunha R, Aranha de Araujo R, Fernandes de Magalhaes Silveira C (2005) Endodontic treatment of dens invaginatus with a periradicular lesion: case report. *Australian Endodontic Journal* **31**, 123–5.
- De Smit A, Demaut L (1982) Nonsurgical endodontic treatment of invaginated teeth. *Journal of Endodontics* **8**, 506–11.

- Ferguson F, Friedman S, Frazetto V (1980) Successful apexification technique in an immature tooth with dens in dente. *Oral Surgery, Oral Medicine, and Oral Pathology* **49**, 356–9.
- Hata G, Toda T (1987) Treatment of dens invaginatus by endodontic therapy, apicocurettage, and retrofilling. *Journal of Endodontics* **13**, 469–72.
- Holtzman L, Lezion R (1996) Endodontic treatment of maxillary canine with dens invaginatus and immature root. *Oral Surgery, Oral Medicine, Oral Pathology, Oral Radiology, and Endodontics* **82**, 452–5.
- Jung M (2004) Endodontic treatment of dens invaginatus type III with three root canals and open apical foramen. *International Endodontic Journal* **37**, 205–13.
- Lindeboom JA, Frenken JW, Kroon FH, van den Akker HP (2005) A comparative prospective randomized clinical study of MTA and IRM as root-end filling materials in single-rooted teeth in endodontic surgery. *Oral Surgery, Oral Medicine, Oral Pathology, Oral Radiology, and Endodontics* **100**, 495–500.
- Oehlers FAC (1957) Dens invaginatus (dilated composite odontome). I. Variations of the invagination process and associated anterior crown forms. *Oral Surgery, Oral Medicine, and Oral Pathology* **10**, 1204–18.
- Olsen FK, Austin BP, Walia H (1994) Osseous reaction to implanted ZOE retrograde filling materials in the tibia of rats. *Journal of Endodontics* **20**, 389–94.
- Pai SF, Yang SF, Lin LM (2004) Nonsurgical endodontic treatment of dens invaginatus with large periradicular lesion: a case report. *Journal of Endodontics* **30**, 597–600.
- Pitt Ford TR, Andreasen JO, Dorn SO, Kariyawasam SP (1994) Effect of IRM root end fillings on healing after replantation. *Journal of Endodontics* **20**, 381–5.
- Rotstein I, Stabholz A, Heling I, Friedman S (1987) Clinical considerations in the treatment of dens invaginatus. *Endodontics & Dental Traumatology* **3**, 249–54.
- da Silva Neto UX, Hirai VH, Papalexiou V *et al.* (2005) Combined endodontic therapy and surgery in the treatment of dens invaginatus type 3: case report. *Journal of Canadian Dental Association* **71**, 855–8.
- Soares J, Santos S, Silveira F, Nunes E (2007) Calcium hydroxide barrier over the apical root-end of a type III dens invaginatus after endodontic and surgical treatment. *International Endodontic Journal* **40**, 146–55.
- de Sousa SM, Bramante CM (1998) Dens invaginatus: treatment choices. *Endodontics & Dental Traumatology* **14**, 152–8.
- Steffen H, Splieth C (2000) Conventional treatment of dens invaginatus in maxillary lateral incisor with sinus tract: one year follow-up. *Journal of Endodontics* **31**, 130–3.
- Sübay RK, Kayatas M (2006) Dens invaginatus in an immature maxillary lateral incisor: a case report of complex endodontic treatment. *Oral Surgery, Oral Medicine, Oral Pathology, Oral Radiology, and Endodontics* **102**, 37–41.
- Tarjan I, Rozsa N (1999) Endodontic treatment of immature tooth with dens invaginatus: a case report. *International Journal of Paediatric Dentistry* **9**, 53–6.
- Yeh SC, Lin YT, Lu SY (1999) Dens invaginatus in the maxillary lateral incisor: treatment of 3 cases. *Oral Surgery, Oral Medicine, Oral Pathology, Oral Radiology, and Endodontics* **87**, 628–31.