

# Dentine-bonded resin composite (Retroplast) for root-end filling: a prospective clinical and radiographic study with a mean follow-up period of 8 years

P. M. Yazdi<sup>1</sup>, S. Schou<sup>2</sup>, S. S. Jensen<sup>3</sup>, K. Stoltze<sup>4</sup>, B. Kenrad<sup>1</sup> & I. Sewerin<sup>5</sup>

<sup>1</sup>Department of Oral and Maxillofacial Surgery, School of Dentistry, Faculty of Health Sciences, University of Copenhagen, Copenhagen, Denmark; <sup>2</sup>Department of Oral and Maxillofacial Surgery, Aalborg Hospital, Aarhus University Hospital, Aalborg, Denmark; <sup>3</sup>Department of Oral and Maxillofacial Surgery, Copenhagen University Hospital Glostrup, Glostrup, Denmark; Departments of <sup>4</sup>Periodontology and <sup>5</sup>Oral Radiology, School of Dentistry, Faculty of Health Sciences, University of Copenhagen, Copenhagen, Denmark

## Abstract

**Yazdi PM, Schou S, Jensen SS, Stoltze K, Kenrad B, Sewerin I.** Dentine-bonded resin composite (Retroplast) for root-end filling: a prospective clinical and radiographic study with a mean follow-up period of 8 years. *International Endodontic Journal*, 40, 493–503, 2007.

**Aim** To evaluate treatment outcome after using a resin composite (Retroplast, RP) in combination with a dentine-bonding agent (GLUMA) as root-end filling material after 1 year as well as after more than 5 years (final examination). Also, the influence of various pre-, intra- and postoperative factors on the treatment outcome was studied.

**Methodology** All patients (87) undergoing root-end resection consecutively treated by root-end filling with RP on an incisor, canine, pre-molar, or first molar (87 teeth, 118 roots) were initially enrolled in the study. RP was applied on the entire resected surface that was prepared to a slightly concave shape and after conditioning with EDTA and GLUMA. The treatment outcome involving subjective, clinical and radiographic parameters was evaluated after 1 year and at the final examination. A total of 27 patients (36 roots) were excluded from the study because of unavailability of follow-up (19) and extraction of the operated tooth for reasons other than failed surgery (8). Consequently, 60

patients (82 roots) were included in the final material. The mean follow-up period at the final examination was 8 years (range: 6.5–9 years).

**Results** The radiographic evaluation at the final examination revealed that 77%, 5%, 7% and 11% of the treated roots were characterized by complete, incomplete, uncertain and unsatisfactory healing, respectively. A total of 95% of the roots classified as completely healed at the 1-year control were also completely healed at the final examination. Two roots (5%) showing complete healing at the 1-year control revealed unsatisfactory healing at the final examination because of displaced or lost RP-filling. Moreover, 60% of the roots with uncertain healing at the 1-year control demonstrated complete or incomplete healing at the final examination. The classification according to subjective, clinical and radiographic parameters revealed that 78% of the teeth were characterized by a successful treatment outcome at the final examination. Evaluation of the influence of various pre-, intra- and postoperative factors on the treatment outcome revealed that the radiographic classification at the final examination was exclusively influenced by the radiographic classification at the 1-year control ( $P < 0.001$ ).

**Conclusions** The present long-term study indicates that RP can be used for root-end filling with a successful treatment outcome.

**Keywords:** endodontic surgery, periapical diseases, prospective clinical study, resin composite, root-end obturation, Retroplast.

Received 29 August 2006; accepted 28 November 2006

Correspondence: Pouya Masroori Yazdi, Department of Oral and Maxillofacial Surgery, School of Dentistry, Faculty of Health Sciences, University of Copenhagen, 20 Nørre Allé, DK-2200 Copenhagen N, Denmark (Tel.: +45 35 32 66 10; fax: +45 35 32 66 25; e-mail: pmy@odont.ku.dk).

## Introduction

A BISGMA/TEGDMA-based resin composite (Retroplast, RP) in combination with a dentine-bonding agent (GLUMA) has been developed for root-end filling during endodontic surgery (Rud *et al.* 1991a). In contrast to previously used root-end filling materials, RP is not condensed into an apical cavity, but applied onto a slightly concave resection surface with the intention of sealing both root canals and exposed dentinal tubules. A successful radiographic healing frequency of 74–92% was reported by Rud *et al.* after a 6-month to 12-year follow-up period (Table 1) (Rud *et al.* 1991b, 1996, 1997, 2001).

Long-term studies by other research groups are needed to evaluate the general feasibility of RP for root-end filling. However, only one such study is available with a 1-year follow-up period demonstrating a 78% successful radiographic healing frequency (Table 1) (Jensen *et al.* 2002). Consequently, the aim of the present study was to evaluate the treatment outcome after using dentine-bonded RP as root-end filling material after 1 year as well as after more than 5 years. Finally, the influence of various pre-, intra- and postoperative factors on the treatment outcome was assessed. The study is in part based on data from the above-mentioned 1-year study (Jensen *et al.* 2002).

## Material and methods

A license to perform the study was obtained from the Scientific Ethical Board of Copenhagen, Denmark (No. 03 271663) and the patients signed a consent form according to the declaration of Helsinki.

### Characteristics of initially included patients

All patients (87) consecutively treated by root-end filling with RP on an incisor, canine, pre-molar, or first molar (87 teeth, 118 roots) at the Department of Oral

**Table 2** Characteristics of initially included patients

	<i>n</i> (%)
Age (years), mean (range)	50 (24–84)
Gender	
Women	56 (64)
Men	31 (36)
Treated teeth	87
Treated roots	118
Tooth type	
Maxilla	
Incisor	14 (16)
Canine	2 (2)
Pre-molar	23 (26)
Molar	10 (11)
Mandible	
Incisor	3 (3)
Canine	2 (2)
Pre-molar	7 (8)
Molar	26 (30)

and Maxillofacial Surgery, School of Dentistry, Faculty of Health Sciences, University of Copenhagen, Denmark, between September 1996 and May 1999 were initially enrolled in the study. If root-end filling of more than one tooth was indicated, only one was selected at random before surgery for inclusion. Finally, teeth with apicomarginal communication or previous surgical endodontic treatment were excluded from the study. The characteristics of the patients included initially are presented in Table 2. Briefly, the mean age at the time of surgery was 50 (24–84) years with 64% women and 36% men. The study involved maxillary and mandibular incisors, canines, pre-molars and first molars. The number of each tooth type was unequal.

### Recordings before surgery

Presence of subjective symptoms (pain, tenderness, swelling of oral mucosa) of the treated tooth was recorded. In addition, the clinical recordings of the affected tooth included assessment of:

**Table 1** Previous studies on dentine-bonded Retroplast for root-end filling

Study	No. of patients	No. of roots	Length of follow-up (years)	Radiographic classification (%)			
				Complete healing	Incomplete healing	Uncertain healing	Unsatisfactory healing
Rud <i>et al.</i> (1991b)	388	No information	$\frac{1}{2}$ –1	74	4	15	7
Rud <i>et al.</i> (1996)	No information	347	2–4	89	0	1	9
Rud <i>et al.</i> (1997)	No information	551	2–4	86	8 <sup>b</sup>		7
Rud <i>et al.</i> (2001)	No information	834	$\frac{1}{2}$ –12	92	0	1	7
Jensen <i>et al.</i> (2002)	60	77	1	78	4	18	0 <sup>a</sup>

<sup>a</sup>Six patients re-operated and excluded from the radiographic classification.

<sup>b</sup>Incomplete healing and uncertain healing.

- Gingival score (0, 1, 2, 3) (Löe & Silness 1963) mesio-buccally, mid-buccally, disto-buccally, mesio-lingually, mid-lingually and disto-lingually.
- Probing depth to the nearest millimetre mesio-buccally, mid-buccally, disto-buccally, mesio-lingually, mid-lingually and disto-lingually.
- Tooth mobility (0°, 1°, 2°, 3°) (Mühlemann & Herzog 1961).
- Restoration sealing coronal part of root canal (yes, no).
- Signs of inflammation (tenderness to tooth percussion, sinus tract with or without suppuration, swelling/redness/palpation tenderness of oral mucosa).

A radiograph using a paralleling technique was obtained and the following registrations were recorded:

- Root filling (yes, no).
- Length of root filling (root filling 0–1.5 mm short of apex, root filling more than 1.5 mm short of apex, root filling exceeding apex).
- Adaptation between root filling and root canal (no radiolucency along root filling material, radiolucency along root filling material).
- Largest diameter of apical radiolucency (<5 mm, 5–10 mm, >10 mm).
- Marginal bone level, i.e. distance from cemento-enamel-junction to alveolar crest mesially and distally (<2 mm, 2–5 mm, >5 mm).

The recordings before surgery are presented in Tables 3 and 4. Briefly, the teeth were in general nonmobile with healthy periodontal tissues. A total of 51% of the root fillings were more than 1.5 mm short of apex. In addition, 58% of the roots were characterized by a radiographic radiolucency along the root filling material. The largest diameter of the apical rarefaction was in 51% <5 mm and >10 mm in 6%.

### Surgery

The surgical procedure performed by five surgeons has previously been described in detail (Jensen *et al.* 2002). Briefly, the tooth apex was exposed and 2–3 mm of the apex was resected. The resected surface was made slightly concave using a round diamond burr. After haemostasis by Stryphnon gauze (Sanova, Vienna, Austria), cotton-pellets soaked in 1% adrenaline or electrocauterization in combination or alone, the prepared surface was conditioned with EDTA (DanDental, Ballerup, Denmark), rinsed with saline and dried with compressed air using a 20-mL syringe before application of GLUMA (Heraeus Kulzer, Wehrheim, Germany). If the resected surface was contaminated with blood or

**Table 3** Preoperative subjective and clinical registrations of initially included patients

	n (%)
Patients with subjective symptoms	50 (57)
Mean gingival score <sup>a</sup>	
0	18 (21)
0.1–1	40 (46)
1.1–2	26 (30)
>2	2 (2)
Not registered	1 (1)
Mean probing depth <sup>a</sup>	
≤4 mm	72 (83)
>4 mm	14 (16)
Not registered	1 (1)
Tooth mobility	
0°	58 (67)
1°	25 (29)
2°	2 (2)
3°	1 (1)
Not registered	1 (1)
Restoration sealing coronal part of root canal	
Yes	67 (77)
No	19 (22)
Not registered	1 (1)
Signs of inflammation	
Tenderness to tooth percussion	30 (34)
Sinus tract with or without suppuration	12 (13)
Other signs (swelling/redness/tenderness to palpation)	20 (23)

<sup>a</sup>Mean of six measurements per tooth.

saliva during conditioning, application of EDTA and GLUMA was repeated after further preparation of the surface with a round diamond burr. RP (Department of Dental Materials, School of Dentistry, Faculty of Health Sciences, University of Copenhagen, Denmark) was placed on the entire resection surface using a small excavator. The nonpolymerized surface layer was removed after 3 min by 70% ethanol before thorough irrigation with saline and suturing. Mouth-rinsing with 0.1% chlorhexidine was prescribed twice daily until removal of sutures 1 week postoperatively. In addition, postoperative pain control was achieved by Ibuprofen (Nycomed Danmark, Roskilde, Denmark, 600 mg × 3 daily for 1 week). Finally, postoperative antibiotic (Ampicillin; Lundbeck, Valby, Denmark, 800 mg × 2 daily for 1 week) was prescribed only when communication to the maxillary sinus was observed during the surgical procedure.

### Recordings during surgery

The intraoperative registrations included combined buccal and lingual bone penetration (yes, no) and post

**Table 4** Preoperative radiographic registrations of initially included patients

	<i>n</i>			Total <i>n</i> (%)
	First root	Second root	Third root	
<b>Length of root filling</b>				
0–1.5 mm short of apex	28	7	0	35 (30)
>1.5 mm short of apex	42	17	1	60 (51)
Exceeding apex	8	3	1	12 (10)
No root filling	5	2	0	7 (6)
Not registered <sup>a</sup>	4	0	0	4 (3)
<b>Adaptation between root filling and root canal</b>				
No radiolucency along root filling material	32	11	0	43 (36)
Radiolucency along root filling material	50	16	2	68 (58)
No root filling	5	2	0	7 (6)
<b>Largest diameter of apical radiolucency</b>				
<5 mm	44	16	0	60 (51)
5–10 mm	35	9	2	46 (39)
>10 mm	5	2	0	7 (6)
Not registered <sup>b</sup>	3	2	0	5 (4)
<b>Mean marginal bone level<sup>c</sup></b>				
<2 mm	56	23	2	81 (69)
2–5 mm	28	5	0	33 (28)
>5 mm	3	0	0	3 (3)
Not registered <sup>d</sup>	0	1	0	1 (1)

<sup>a</sup>Preoperative radiograph not available, but conventional root filling present on postoperative radiograph.

<sup>b</sup>Preoperative radiograph not available.

<sup>c</sup>Mean bone level mesially and distally.

<sup>d</sup>Measurement not possible.

**Table 5** Intra- and postoperative registrations

	<i>n</i> (roots)	%
<b>Intraoperative registrations</b>		
Combined buccal and lingual bone penetration		
Yes	4	3
No	111	94
Not registered	3	3
Post or root filling material visible after root-end resection		
Yes	79	67
No	38	32
Not registered	1	1
<b>Postoperative registrations</b>		
Largest diameter of apical radiolucency		
<5 mm	18	15
5–10 mm	87	74
>10 mm	13	11

or root filling material visible after root-end resection (yes, no) (Table 5).

### Recordings after surgery

A radiograph using paralleling technique was obtained just after surgery and the largest diameter of the apical radiolucency (<5 mm, 5–10 mm, >10 mm) was recorded (Table 5).

### Assessment of treatment outcome

Presence of subjective symptoms (pain, tenderness, swelling of the oral mucosa) of the treated tooth was recorded at the final examination. In addition, clinical signs of periapical inflammation (tenderness to tooth percussion, sinus tract with or without suppuration, swelling/redness/palpation tenderness of oral mucosa) were registered.

### Radiographic classification

A radiograph using paralleling technique was obtained at the 1-year control as well as at the final examination. The evaluation involved quality assessment of each RP-filling (present without displacement, displaced, lost). In addition, the healing of the periapical bone of each root was categorized as complete, incomplete, uncertain and unsatisfactory, respectively, according to the criteria described by Rud *et al.* (1972a). When, uncertain healing was observed at the final examination, the healing was regarded as unsatisfactory in accordance with Rud *et al.* (1972b). If the RP-filling was displaced or lost, the healing was also classified as unsatisfactory. When re-operation or extraction was performed due to persistent subjective symptoms and/or persistent periapical pathological

changes not caused by root fracture, the final radiographic evaluation was carried out at the time of re-operation or extraction. The assessment was carried out independently by three of the authors (PMY, SSJ, IS). In case of disagreement (23%), consensus was achieved by discussion.

#### *Classification according to subjective, clinical and radiographic parameters*

The treatment outcome of each tooth was classified at the final examination according to subjective, clinical and radiographic parameters into:

- **Successful.** Absence of subjective symptoms as well as clinical signs of periapical inflammation for all treated roots. In addition, a radiographic classification of all treated roots as complete or incomplete healing without displaced or lost RP-filling.
- **Failure.** Presence of subjective symptoms. In addition, clinical signs of periapical inflammation and/or a radiographic healing classification as uncertain or unsatisfactory and/or signs of displaced or lost RP-filling of one or all treated roots. When additional endodontic surgery was performed during the follow-up period due to persistent subjective symptoms and/or persistent periapical pathological changes not caused by root fracture, the treatment was regarded as a failure. Finally, the treatment outcome was classified as a failure if the tooth was extracted due to persistent subjective symptoms and/or persistent periapical pathological changes not caused by a root fracture.

#### **Characteristics of finally included patients**

A total of 27 of the 87 patients included initially were excluded from the study mainly because of unavailability of follow-up (Table 6). Consequently, 60

**Table 6** Excluded patients

Cause of exclusion	n (%)
Extraction for other reasons than failed surgery	
Fracture of root	2 (2.3)
Fracture of crown	3 (3.4)
Periodontitis	3 (3.4)
Patient could not be contacted for follow-up	6 (6.9)
Patient deceased	4 (4.6)
Patient uninterested in follow-up <sup>a</sup>	9 (10.3)
<b>Total</b>	<b>27 (31)</b>

<sup>a</sup>Operated tooth *in situ*, no re-operation and no subjective symptoms (reported in telephone).

patients with 82 treated roots were finally included in the study. Re-operation or extraction because of persistent periapical pathological changes not caused by a root fracture was performed on seven patients. The mean follow-up period at the final examination was 8 years (range: 6.5–9 years). There were no significant differences in the characteristics of the 87 patients included initially and the final 60 patients ( $P > 0.05$ ).

#### **Data analysis**

Data management and analysis were undertaken using the Statistical Analysis System for Personal Computers (SAS Institute Inc., Cary, NC, USA). The influence of the pre-, intra- and postoperative recordings on the treatment outcome at the final examination was evaluated by regression analysis using the GLM procedure. A chi-square test was used to compare the characteristics of the initially and finally included patients. The unit of analysis was the patient and the level of significance was 0.05.

#### *Radiographic classification*

The influence of the following recordings on the radiographic classification was assessed: tooth type (incisor/canine, pre-molar, molar), tooth mobility, presence of restoration sealing coronal part of root canal, presence of root filling, length of root filling, adaptation between root filling and root canal, largest diameter of apical radiolucency (pre- and postoperative), combined buccal and lingual bone penetration, post or root filling material visible after root-end resection and radiographic classification at the 1-year control. As previously described, uncertain healing at the final evaluation was regarded as unsatisfactory. Therefore, the analysis of the radiographic classification included two categories (complete/incomplete, uncertain/unsatisfactory), i.e. satisfactory and unsatisfactory healing.

#### *Classification according to subjective, clinical and radiographic parameters*

The influence of the following recordings on the classification according to subjective, clinical and radiographic parameters was assessed: tooth type (incisor/canine, pre-molar, molar), presence of root filling, tooth mobility and presence of restoration sealing coronal part of root canal. Inclusion of the other recordings was impossible because of differences in recordings of the individual roots of each tooth.

## Results

### *Radiographic classification*

Examples of the four healing types are illustrated in Figs 1–4. A total of 68%, 0%, 18% and 6% of the roots were at the 1-year examination characterized by complete, incomplete, uncertain and unsatisfactory healing, respectively (Table 7). The corresponding figures at the final examination were 77%, 5%, 7% and 11%. Seven roots (four teeth) out of nine with unsatisfactory healing were characterized by lost or displaced RP-filling at the final examination. Except for the radiographic classification at the 1-year control ( $P < 0.001$ ), the radiographic classification at the final examination was not significantly influenced by any of the pre-, intra- and postoperative recordings ( $P > 0.05$ ).

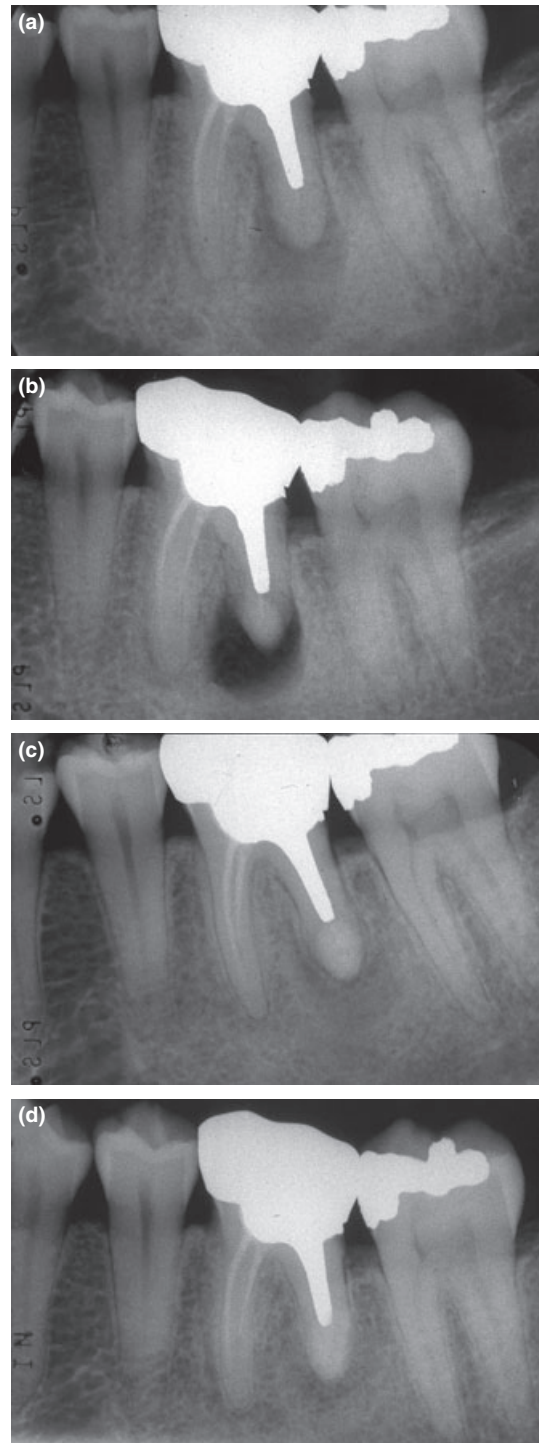
Changes in the radiographic healing classification from the 1-year control to the final examination are presented in Fig. 5. A total of 95% of the roots classified as completely healed at the 1-year control were also completely healed at the final examination. Two roots (5%) showing complete healing at the 1-year control revealed unsatisfactory healing at the final examination because of displaced or lost RP-filling (Fig. 6). Moreover, 60% of the roots with uncertain healing at the 1-year control demonstrated complete or incomplete healing at the final examination, whilst the remaining roots (40%) were unchanged or classified as unsatisfactory (Fig. 5).

### *Classification according to subjective, clinical and radiographic parameters*

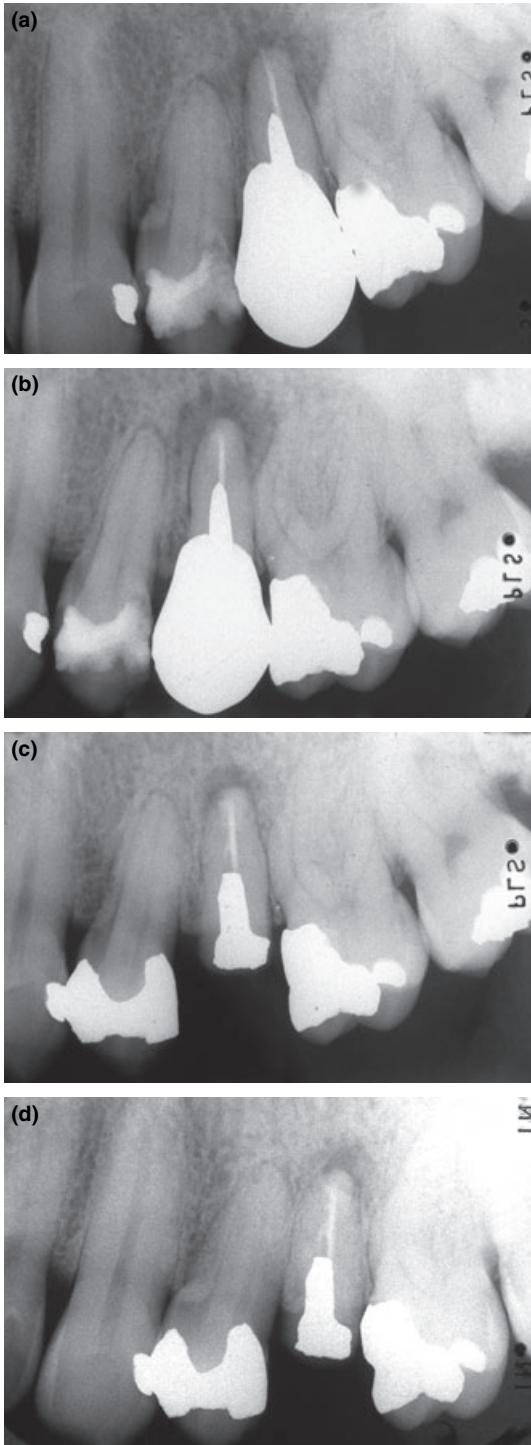
A total of 47 teeth had a treatment outcome classified as successful (78%) and 13 as failures (22%) at the final examination (Table 8). The classification was not significantly influenced by any of the pre-, intra- and postoperative recordings ( $P > 0.05$ ).

## Discussion

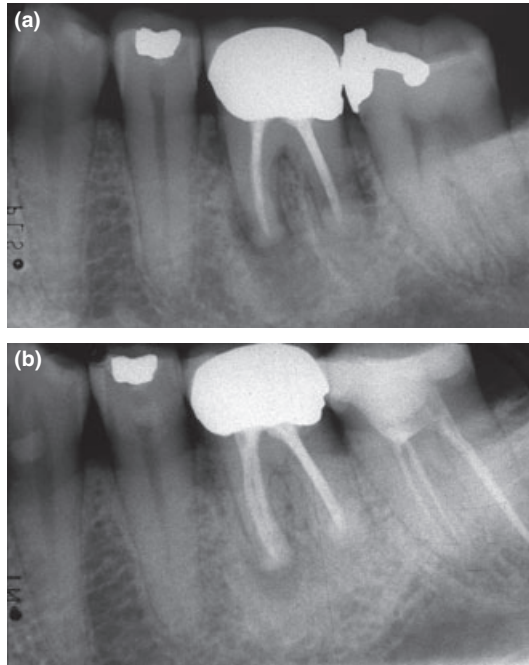
The dentine-bonded resin composite, RP, for root-end filling was assessed in the present study with a mean follow-up period of 8 years (range: 6.5–9 years). The radiographic classification included the assessment of the individually treated root without including subjective and clinical parameters. In contrast, the classification according to subjective, clinical and radiographic parameters determined the treatment outcome on the tooth level, i.e. was the operation a success or a failure.



**Figure 1** Example of complete healing. Radiographs taken preoperatively (a), postoperatively (b), at 1-year follow-up (c) and at final examination after 9 years (d).



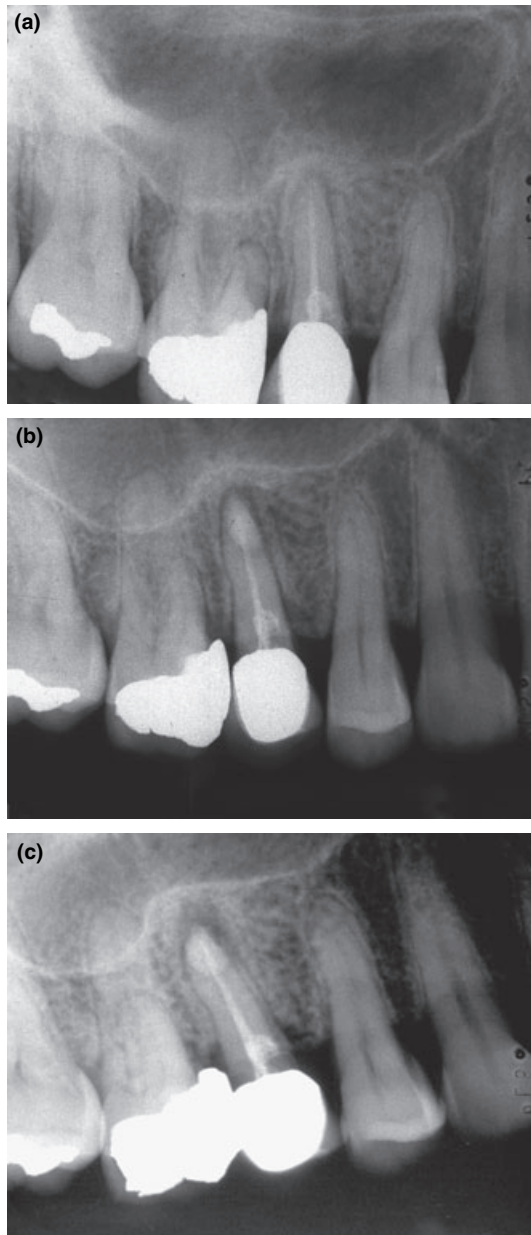
**Figure 2** Example of incomplete healing. Radiographs taken preoperatively (a), postoperatively (b), at 1-year follow-up (c) and at final examination after 8 years (d). Please notice decreased size and irregular outline of radiolucency located asymmetrically at tooth apex.



**Figure 3** Example of uncertain healing. Radiographs taken preoperatively (a) and at final examination after 8 years (b). Please notice decreased semilunar radiolucency located symmetrically at tooth apex. In addition, size of radiolucency is more than twice the width of the periodontal ligament.

A total of 77% of the roots were characterized by complete radiographic healing. The main reason for unsatisfactory healing was displaced or lost RP-filling. When the treatment outcome of endodontic surgery is assessed, subjective, clinical and radiographic parameters should be included (Zuolo *et al.* 2000). By using these guidelines, 78% of the teeth revealed a successful treatment outcome. Therefore, the present long-term study indicates that RP used as a root-end filling material is associated with a successful treatment outcome in the majority of cases.

High drop-out rates may introduce considerable bias in prospective long-term studies and requires all patients not available for follow-up to be thoroughly accounted for. A total of 27 out of the original 87 patients were excluded in the present study. The reason for exclusion was extraction because of other reasons than failed surgery (8), could not be contacted for follow-up (6), deceased (4) and uninterested in follow-up (9). Although the treatment outcome of the nine patients uninterested in follow-up could not be determined, contact by telephone revealed that all operated teeth were present without symptoms. In addition, no



**Figure 4** Example of unsatisfactory healing. Radiographs taken preoperatively (a), postoperatively (b) and after 1 year (c). Please notice increased size of radiolucency.

re-operations had been performed during the follow-up period. A 85–95% recall rate has previously been reported in prospective studies with at least 4-year follow-up (Kvist & Reit 1999, Wang *et al.* 2004, Gagliani *et al.* 2005). However, comparison of the recall rate is compromised by different calculation methods.

**Table 7** Radiographic classification at 1-year follow-up and at final examination

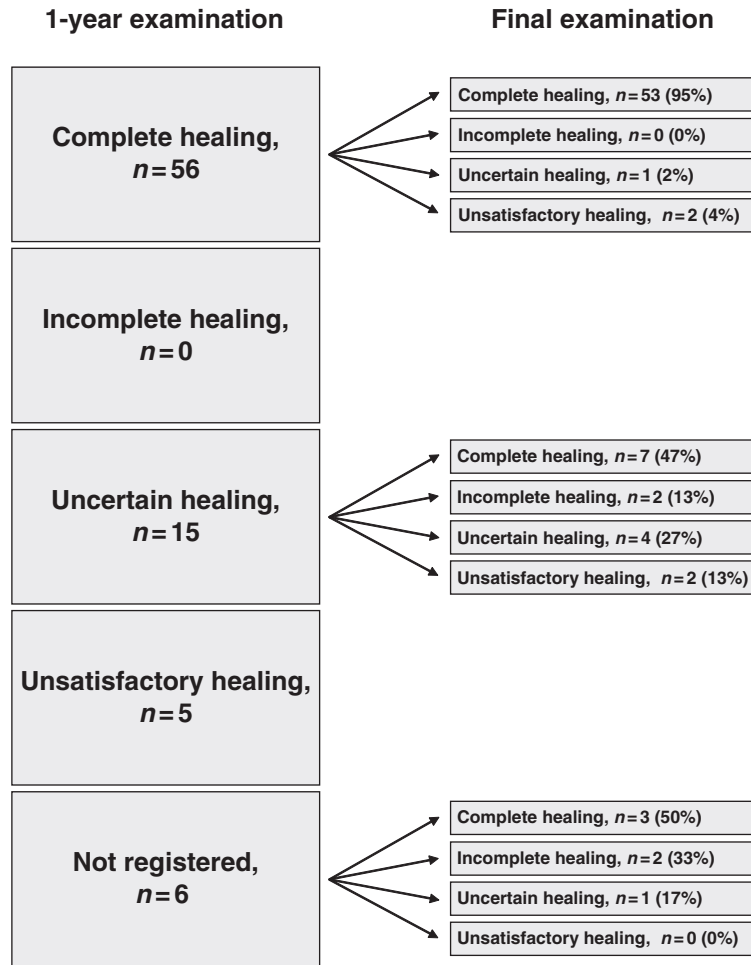
	1-year follow-up		Final examination	
	<i>n</i> (roots)	%	<i>n</i> (roots)	%
Complete healing	56	68	63	77
Incomplete healing	0	0	4	5
Uncertain healing	15	18	6	7
Unsatisfactory healing	5	6	9	11
Not registered <sup>a</sup>	6	7	0	0
<b>Total</b>	<b>82</b>	<b>100</b>	<b>82</b>	<b>100</b>

<sup>a</sup>Three patients not available for 1-year follow-up.

Different materials have been used for root-end filling, including amalgam, various reinforced zinc-oxide eugenol cements, glass-ionomer cements, gutta-percha, composite resins and mineral trioxide aggregate (for review, see Friedman 2005). Clinical studies on the treatment outcome after root-end filling are characterized by great diversity. Indeed, successful radiographic healing frequency between 31% and 97% has been reported (for review, see Friedman 2005). However, a successful radiographic healing frequency above 80% has been revealed in recently published studies involving microsurgical technique and improved tools for intraoperative diagnostics (for review, see von Arx 2005).

The use of RP in combination with GLUMA has been assessed in previous clinical and radiographic studies (Table 1) (Rud *et al.* 1991b, 1996, 1997, 2001, Jensen *et al.* 2002). Except for the 1-year study by Jensen *et al.* (2002), these studies have all been undertaken by the research group originally developing the method (Rud *et al.* 1991b, 1996, 1997, 2001). To some extent, these studies are based on the same patients (J. Rud, personal communication). A total of 74–92% of the included roots showed complete healing and in accordance with these reports, a complete healing frequency of 77% was found in the present study. The results are also similar to the results of previously published long-term studies evaluating other materials than RP for root-end filling demonstrating a radiographic complete healing frequency of 60–78% (Kvist & Reit 1999, Wang *et al.* 2004, Gagliani *et al.* 2005).

The use of RP for root-end filling involves preparation of a slightly concave resection surface followed by conditioning with EDTA and GLUMA and sealing of the entire surface by RP (Rud *et al.* 1991a). Therefore, the use of RP as root-end filling material does not involve preparation of an apical cavity as for other root

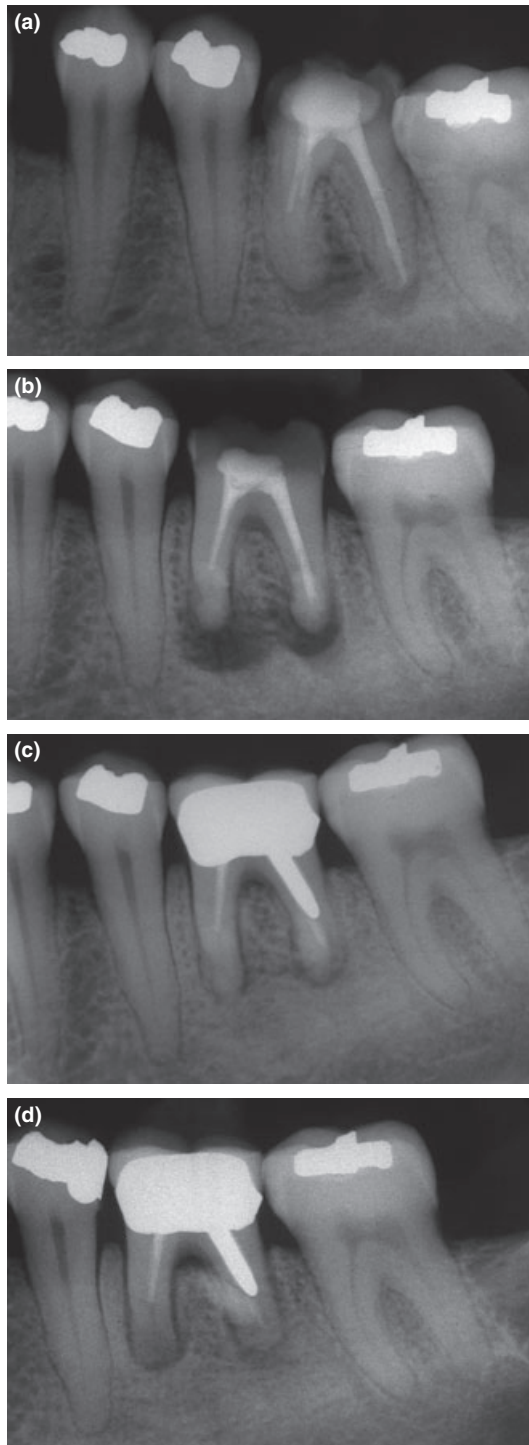


**Figure 5** Changes in radiographic healing classifications from the 1-year control to the final examination. All roots with unsatisfactory healing after 1-year follow-up were either re-operated or extracted.

filling materials. Consequently, preparation of the resection surface for RP is in general less complex. However, avoidance of contamination of the resection surface with blood and saliva during the conditioning procedure and application of RP is mandatory for a successful treatment outcome (Rud *et al.* 1991a). Therefore, endodontic surgery with RP is a technically demanding procedure. The present study involved surgeons and surgical assistants with no or limited experience with RP. Although it is still debated whether the outcome of surgical endodontic treatment is influenced by experience, skill and thoroughness of the surgeon (for review, see Friedman 2005), it is generally accepted that a meticulous surgical technique including trained surgical assistants is a prerequisite for high success rates after using RP as root-end filling material.

The present study involved assessment of the treatment outcome 1 year and more than 5 years postoperatively. It has previously been reported that roots

with complete healing 1 year postoperatively require no additional follow-up (Rud *et al.* 1972b, Halse *et al.* 1991, Rubinstein & Kim 2002). In accordance with these observations, 95% of the roots classified as completely healed at the 1-year control were also completely healed at the final examination in the present study. Actually, only two roots (5%) showing complete healing at the 1-year control revealed unsatisfactory healing at the final examination because of displaced or lost RP-filling. The radiograph taken just postoperatively showed two correctly placed RP fillings respectively on the mesial and distal root-end of a first lower molar (Fig. 6b). The radiograph taken at the final control revealed that the RP filling of the distal root was dislocated, whereas the RP filling of the mesial root was missing and apparently penetrating the oral mucosa (Fig. 6d). The background for the loss and displacement is not known, but is probably related to unobserved contamination with blood or saliva during conditioning



**Figure 6** Example of displaced (distal root) and lost (mesial root) RP-filling. Radiographs taken preoperatively (a), postoperatively (b), at 1-year follow-up (c) and at final examination after 8 years (d).

and sealing of the root-end. Regarding the roots with uncertain healing at the 1-year control, 60% demonstrated complete or incomplete healing at the final examination. Consequently, for the assessment of the final treatment outcome a longer observation period is required in case of uncertain healing at the 1-year control. This observation is in accordance with previously published studies (Rud *et al.* 1972b, Halse *et al.* 1991).

Within the limits of this study, the radiographic healing at the final examination was significantly influenced by the observed radiographic healing at the 1-year control. In contrast, the radiographic healing was not significantly influenced by any of the other assessed pre-, intra- and postoperative factors, i.e. tooth type, tooth mobility, presence of restoration sealing coronal part of root canal, presence of root filling, length of root filling, adaptation between root filling and root canal, largest diameter of apical radiolucency, combined buccal and lingual bone penetration and post or root filling material visible after root-end resection. However, the validity of the analysis may be compromised by the limited number of patients included. Therefore, knowledge about the influence of most of these factors on the treatment outcome is still limited (for review, see Friedman 2005).

## Conclusions

The dentine-bonded resin composite, RP, for root-end filling was evaluated in the present study involving 60 patient (82 roots) with a mean follow-up period of 8 years (range: 6.5–9 years). A total of 77% of the roots were characterized by complete radiographic healing. The main reason for unsatisfactory healing was displaced or lost RP-filling. When the treatment outcome was assessed by subjective, clinical and radiographic parameters, 78% of the teeth were classified as successful. The results are comparable to the results of previously published long-term studies evaluating materials other than RP for root-end filling. Therefore, the present long-term study indicates that RP used as a root-end filling material is associated with a successful treatment outcome in the majority of cases.

## Acknowledgements

This study was supported by a grant from the Danish Dental Association.

**Table 8** Classification according to subjective, clinical and radiographic parameters at final examination

	n (teeth)	%
Success	47	78
Failure		
Extraction during follow-up period because of persistent periapical pathological changes	1	2
Re-operation during follow-up period because of persistent periapical pathological changes	6	10
Subjective symptoms and/or clinical signs of persistent periapical pathological changes at final examination	3	5
No subjective symptoms and/or clinical signs of persistent periapical pathological changes at final examination but uncertain radiographic healing	3	5
Total	60	100

## References

- von Arx T (2005) Failed root canals: the case for apicoectomy (periradicular surgery). *Journal of Oral and Maxillofacial Surgery* **63**, 832–7.
- Friedman S (2005) The prognosis and expected outcome of apical surgery. *Endodontic Topics* **11**, 219–62.
- Gagliani MM, Gorni FGM, Strohmenger L (2005) Periapical resurgery versus surgery: a 5-year longitudinal comparison. *International Endodontic Journal* **38**, 320–7.
- Halse A, Molven O, Grung B (1991) Follow-up after periapical surgery: the value of the one-year control. *Endodontics and Dental Traumatology* **7**, 246–50.
- Jensen SS, Nattestad A, Egdo P, Sewerin I, Munksgaard EC, Schou S (2002) A prospective, randomized, comparative clinical study of resin composite and glass ionomer cement for retrograde root filling. *Clinical Oral Investigations* **6**, 236–43.
- Kvist T, Reit C (1999) Results of endodontic retreatment: a randomized clinical study comparing surgical and nonsurgical procedures. *Journal of Endodontics* **25**, 814–7.
- Löe H, Silness J (1963) Periodontal disease in pregnancy. 1. Prevalence and severity. *Acta Odontologica Scandinavica* **21**, 533–51.
- Mühlemann HR, Herzog H (1961) Tooth mobility and microscopic tissue changes reproduced by experimental occlusal trauma. *Helvetica Odontologica Acta* **5**, 33–9.
- Rubinstein RA, Kim S (2002) Long-term follow-up of cases considered healed one year after apical microsurgery. *Journal of Endodontics* **28**, 378–83.
- Rud J, Andreasen JO, Jensen JE (1972a) Radiographic criteria for the assessment of healing after endodontic surgery. *International Journal of Oral Surgery* **1**, 195–214.
- Rud J, Andreasen JO, Jensen JE (1972b) A follow-up study of 1,000 cases treated by endodontic surgery. *International Journal of Oral Surgery* **1**, 215–28.
- Rud J, Munksgaard EC, Andreasen JO, Rud V, Asmussen E (1991a) Retrograde root filling with composite and a dentin-bonding agent. 1. *Endodontics and Dental Traumatology* **7**, 118–25.
- Rud J, Munksgaard EC, Andreasen JO, Rud V (1991b) Retrograde root filling with composite and a dentin-bonding agent. 2. *Endodontics and Dental Traumatology* **7**, 126–31.
- Rud J, Rud V, Munksgaard EC (1996) Retrograde root filling with dentin-bonded modified resin composite. *Journal of Endodontics* **22**, 477–80.
- Rud J, Rud V, Munksgaard EC (1997) Effect of root canal contents on healing of teeth with dentin-bonded resin composite retrograde seal. *Journal of Endodontics* **23**, 535–41.
- Rud J, Rud V, Munksgaard EC (2001) Periapical healing of mandibular molars after root-end sealing with dentine-bonded composite. *International Endodontic Journal* **34**, 285–92.
- Wang N, Keith K, Dao T, Friedman S (2004) Treatment outcome in endodontics – The Toronto Study. Phases 1 and 2: apical surgery. *Journal of Endodontics* **30**, 751–61.
- Zuolo ML, Ferreira MO, Gutmann JL (2000) Prognosis in periradicular surgery: a clinical prospective study. *International Endodontic Journal* **33**, 91–8.