

Decoronation – a conservative method to treat ankylosed teeth for preservation of alveolar ridge prior to permanent prosthetic reconstruction: literature review and case presentation

Cohenca N, Stabholz A. Decoronation – a conservative method to treat ankylosed teeth for preservation of alveolar ridge prior to permanent prosthetic reconstruction: literature review and case presentation. © Blackwell Munksgaard, 2006.

Abstract – Avulsed teeth that are stored extraorally in a dry environment for >60 min generally develop replacement root resorption or ankylosis following their replantation due to the absence of a vital periodontal ligament on their root surface. One negative sequelae of such ankylosis is tooth infra-positioning and the local arrest of alveolar bone growth. Removal of an ankylosed tooth may be difficult and traumatic leading to esthetic bony ridge deformities and optimal prosthetic treatment interferences. Recently a treatment option for ankylosed teeth named ‘de-coronation’ gained interest, particularly in pediatric dentistry that concentrated in dental traumatology. This article reviews the up-to-date literature that has been published on decoronation with respect to its importance for future prosthetic rehabilitation followed by a case presentation that demonstrates its clinical benefits.

Nestor Cohenca^{1,2}, Ayala Stabholz³

¹Department of Endodontics, School of Dentistry, University of Washington, Seattle, WA, USA; Departments of ²Endodontics and ³Periodontology, Hebrew University – Hadassah, Faculty of Dental Medicine, Jerusalem, Israel

Key words: avulsion; ankylosis; decoronation; guided bone regeneration; prosthetic rehabilitation; implants

Nestor Cohenca, Department of Endodontics, School of Dentistry, University of Washington, POB 357448, Seattle, WA 98195-7448, USA
Tel.: +1 206 543 5044
Fax: +1 206 616 9085
e-mail: cohenca@u.washington.edu

Accepted 28 September, 2005

The incidence of dental trauma has increased significantly during the last decades, in particular for anterior teeth of children and adolescents (1). The mean prevalence of dental and oral injuries reported in the literature oscillated between 4% and 33%, dependant on the sex and age of the patients (2, 3). Most maxillofacial traumatic injuries occur to the dentition alone (50%) or involve both the dentition and adjacent soft tissue (36%) (4). The overall age distribution of dental trauma shows an incidence of 28.9% for the first decade of life, 44.2% for the second decade, followed by a sharp decrease in incidence thereafter (5–7). Factors that predispose the young population to dental trauma include protruded maxillary incisors and incompetent lips (8), whereas traumatic injuries among adults are

more likely to occur following car accidents, fights and sport activities.

Avulsion is defined as a complete separation of a tooth from its alveolus following a traumatic injury which results in extensive damage to the pulp and periodontal tissues (9). Avulsed teeth comprise 1–16% of all traumatic injuries of the permanent dentition (10). The avulsed tooth should be optimally replanted into its original alveolus as early as possible, although in most cases the replantation is carried out at the dental office or the emergency room hours after the injury. Immediately after replantation, an inflammatory process takes place in the periodontal tissues followed by re-organization of the new attachment apparatus. The type of healing is directly related to the duration of the

extraoral time as well as to the storage conditions of the avulsed tooth prior to replantation (11, 12).

The treatment of avulsed teeth is divided into two stages: initially, an emergency treatment is provided immediately after the accident followed by a definitive treatment, which includes endodontic therapy, crown restoration and clinical and radiographic follow ups. The International Association of Dental Trauma (IADT) and the American Association of Endodontists (AAE) have recently published therapeutic guidelines for the management of traumatic dental injuries (13, 14). These guidelines stressed the importance of preconditioning the root of the avulsed tooth prior to its replantation in order to enhance the healing process of the periodontium. However, teeth that are stored extraorally in a dry environment for more than 60 min generally develop replacement root resorption or ankylosis following their replantation because of the absence of a vital periodontal ligament on their root surface (15, 16).

After the initial inflammatory response following tooth replantation, mesenchymal cells surrounding the denuded root compete to repopulate its surface. Bone cells (osteoblasts and osteoclasts) come into direct contact with the root and initiate resorption of the dentin (osteoclasts) with a simultaneous formation of new bone (osteoblasts) in the affected area. The process leads to the replacement of the dental tissues by bone (17, 18). Tronstad stated in 1988 that progressive inflammatory root resorption can be treated with a high rate of success; yet non-inflammatory replacement root resorption still remains beyond our clinical competence (19) thus, no preventive or arresting measures of this pathosis can be taken.

Various storage media, antibiotics, growth factors, enamel proteins as well as different conditioning agents have been proposed to delay or prevent post-traumatic root resorption in order to increase the long-term success rate of avulsed teeth (20). In 2001, the International Association of Dental Traumatology suggested, for the first time, the use of Emdogain[®] (hydrophobic enamel matrix proteins extracted from porcine developing enamel; Biora, Malmo, Sweden) for the treatment of avulsed teeth that were kept in dry extraoral conditions and replanted after 60 min. Emdogain[®], which was originally introduced for regeneration of lost periodontal tissues is believed to have the ability to induce growth of cementum, periodontal ligament and bone using the socket-side cell population. Despite its wide-spread clinical use, it is still not conclusive whether Emdogain[®] can regenerate a complete periodontium. Although there are an almost equal number of publications reporting conflicting results using this treatment (21,22), recent *in vivo* studies reported that Emdogain[®] did

not prevent or delay the onset of replacement root resorption (23, 24).

Recent studies (25, 26) reported promising results in preventing root resorption using Ledermix[™] Paste (Lederle Pharmaceuticals, Wolfrantshausen, Germany) as an intracanal medication immediately after replantation of an avulsed tooth. This endodontic medication is based on steroids and antibiotics. It is suggested that Ledermix can diffuse through the dentinal tubules causing the steroid to decrease the local inflammatory response of the periodontium, thereby preventing further damage to the protective cemental layer against root resorption.

A root of a replanted tooth may continue to undergo replacement resorption until completely replaced by bone preserving the surrounding alveolar ridge volume. A resorptive process that results in ankylosis allows the clinician the freedom of choice as to the appropriate timing for tooth replacement and allows the postponement of the prosthetic rehabilitation to a convenient time (27). In addition, the rate of root resorption may be age dependant due to the rate of the patient's skeletal growth (28–30). Andersson et al. (29) demonstrated that the rate of root resorption was higher in younger (8–16 years) than in older patients (17–39 years). The average time for a replanted tooth to resorb ranges between 3 and 7 years in younger individuals, whereas in older patients replanted teeth may function for some decades or throughout life.

One of the negative sequela of tooth ankylosis is its infra-positioning, which occurs as the result of the local arrest of the surrounding alveolar bone growth concomitant to the continuous skeletal growth and development. Such infra-positioning results in an unaesthetic dento-gingival complex and might complicate future prosthetic rehabilitation.

The most accepted treatment option of ankylosed teeth has been their surgical removal which is frequently accompanied by traumatic alveolar bone tear, particularly in the presence of a thin maxillary buccal plate. As most cases of dental trauma and subsequent tooth replantation and ankylosis involve the anterior maxilla, such traumatic extractions of ankylosed teeth may lead to esthetic bony ridge deformities and might interfere with optimal prosthetic treatment delivered.

In 1984, Malmgren et al. (31) suggested an alternative treatment to the extraction of ankylosed teeth which attempts to preserve its surrounding alveolar bone and prevent tooth infra-positioning. This procedure is defined as decoronation and involves gingival mucoperiosteal flap elevation, subcrestal removal of the tooth crown leaving the root in its alveolus to be replaced by bone. Histological and radiographical findings showed few inflammatory changes around vital and endodontically trea-

ted roots that had been submerged for the purpose of alveolar bone preservation (32–39).

Following complete crown removal, the existing root canal filling (when present) is removed to prevent foreign body reaction. The empty root canal is thoroughly rinsed with saline and intentionally filled with blood to promote additional replacement resorption from its internal aspect, while the external replacement resorption continues without interruption (40). The mucoperiosteal flap is sutured over the decoronated root leaving it to be gradually fully resorbed (31, 40, 41).

This is an easy and predictable procedure that constitutes a conservative approach to the removal of ankylosed teeth compared with the surgical approach (42). The preservation of decoronated roots in the alveolar process not only helps maintain existing bone volume (43) but also enables vertical bone growth which can be observed coronally to the decoronated root; such vertical growth could minimize the need for future ridge augmentation before implant placement (42).

Malmgren et al. (40, 41) concluded that if ankylosis occurs before the age of 10 or before the growth spurt, a high risk of developing severe infra-positioning exists. Therefore, they suggested that in early mixed dentition (age 7–10 years) cases – decoronation should be performed within 2 years, whereas in late mixed dentition (age 10–12 years) cases – individual decision-making should be performed. If ankylosis occurs during the growth spurt resulting in infra-occlusion – decoronation should be performed as soon as the problem is diagnosed. In the early permanent dentition (≥ 12 years) – the tooth should be monitored regularly without any intervention unless tilting of neighboring teeth or moderate infra-occlusion occurs which necessitates decoronation. According to Malmgren et al. (41), decoronation is recommended when the severity of infra-positioning is moderate or corresponds to an index score of two ($\geq 1/8$ but $< 1/4$ of the crown height of the neighboring teeth) or more.

Augmentation of the resorbed or underdeveloped alveolar ridge has become a standard procedure where implant placement is planned. In a recent report, Oikarinen et al. (44) reviewed the latest literature on augmentation procedures and materials for rebuilding a narrow anterior alveolar ridge. When decoronation is performed on an ankylosed tooth that is well aligned in the bony arch, no ridge augmentation is usually indicated following crown removal. However, Schwartz-Arad et al. (45) noted that although vertical dimension is preserved following decoronation, horizontal bone augmentation could still be indicated before implant placement because of remnant root translocation to a more apical position. In cases of severe infra-positioned ankylosed teeth

scheduled for decoronation, ridge augmentation is usually unavoidable. The use of bone substitutes coupled with guided bone regeneration for horizontal and/or vertical ridge augmentation following crown removal is a predictable and least traumatic procedure to the young patient undergoing decoronation.

It is not until skeletal growth and development is completed that dental implants are being considered for placement in the previously treated edentulous ridge (44–47). Presented is a case of an avulsed and ankylosed tooth that was treated by decoronation and ridge augmentation following dental trauma and its follow up until final prosthetic reconstruction.

Case report

A 15-year-old boy presented to the pediatric dental clinic at the School of Dental Medicine, Hebrew University with a complaint of a non-esthetic maxillary right central incisor position. His medical history included the presence of an allergy to penicillin and a heart murmur with regurgitation that required antibiotic prophylaxis prior to dental intervention. Dental history revealed that at the age of nine, during gymnastic training at school, he fell and both maxillary central incisors were traumatized. Based on the patient's records, the injury caused the avulsion of his maxillary right central incisor combined with an uncomplicated crown fracture and sub-luxation of the maxillary left central incisor accompanied by a complicated crown fracture. The avulsed tooth was left in dry extraoral conditions for 90 min prior to being treated by a professional dental provider. The emergency treatment included rinsing the root and socket of the maxillary right central incisor with saline solution prior to replantation (Fig. 1). The

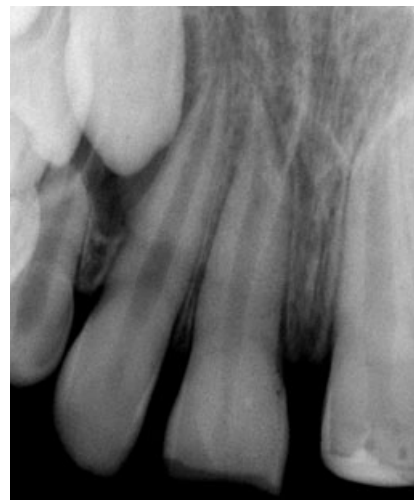

Fig. 1. Periapical radiograph of maxillary right central incisor immediately after replantation.

maxillary left central incisor was treated by partial pulpotomy with calcium hydroxide followed by a composite bandage application. The teeth were splinted with a flexible orthodontic wire and a composite resin for 2 weeks. The endodontic treatment of the maxillary right central incisor was initiated 2 days later and completed 6 months later. At the age of 13 years, 4 years after trauma, during a routine follow-up examination of the patient, pulp necrosis of the maxillary left central and lateral incisors were diagnosed and root canal treatments were performed accordingly.

The clinical examination of the patient at presentation to our clinic 6 years after trauma revealed an advanced infra-occlusion of the maxillary right central incisor (Fig. 2). The tooth was clinically asymptomatic and no sensitivity to percussion or tenderness to palpation was observed. A metallic sound was noted upon percussion.

Radiographical examination showed replacement root resorption of the maxillary right central incisor with evidence of an undeveloped alveolar ridge (Fig. 3). The periapical tissues surrounding the maxillary left central and lateral incisors were in a

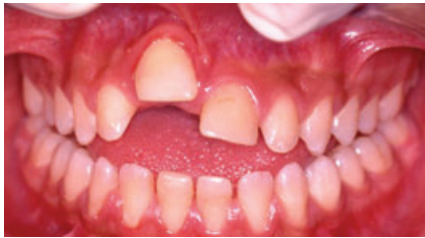

Fig. 2. Clinical photograph of infra-positioned maxillary right central incisor 6 years following trauma.

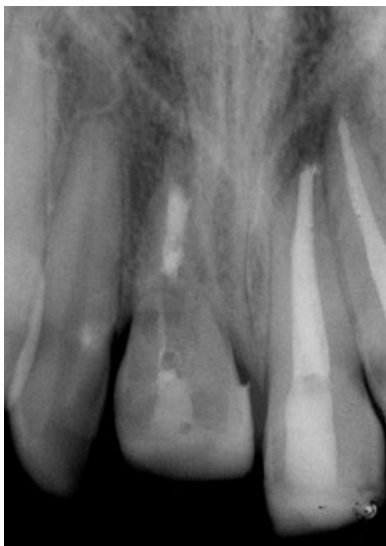

Fig. 3. Radiograph of ankylosed maxillary right central incisor.

process of healing without evidence of root resorption. The adjacent teeth were asymptomatic and responded normally to thermal and electric pulp stimuli. A diagnosis of replacement root resorption of the maxillary right central incisor was made and the patient was referred to a multidisciplinary team of specialists for evaluation and treatment planning.

The treatment plan included decoronation of the maxillary right central incisor followed by orthodontic treatment with a temporary prosthetic crown to restore the esthetics until completion of the patient's developmental growth in an attempt to place an implant supported porcelain crown.

The surgical procedure was performed after obtaining parental consent. The patient was given antibiotic prophylaxis (600 mg clindamycin, Dalacin C; Upjohn, Puurs, Belgium) 1 h prior to treatment. Following administration of local anesthesia, an intrasulcular incision around the treated tooth with mesial and distal sub-marginal releasing incisions was performed to avoid the interproximal papillae. A full-thickness buccal mucoperiosteal flap was elevated exposing the tooth and the labial cortical plate (Fig. 4). The palatal tissue was left intact. The crown was decoronated and the root canal filling removed. The root canal was then alternately instrumented and rinsed with saline until bleeding from the surrounding tissues filled the empty root canal (Fig. 5). This step is critical, as the blood clot will decrease the risk of infection and allow the ingress of osteoclasts and osteoblasts, thus

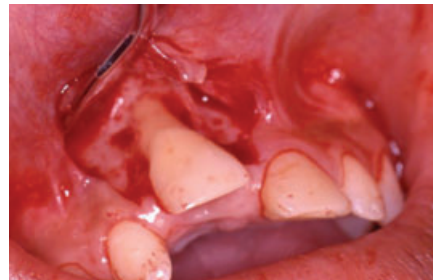

Fig. 4. Full thickness mucoperiosteal flap elevation exposing the ankylosed tooth.

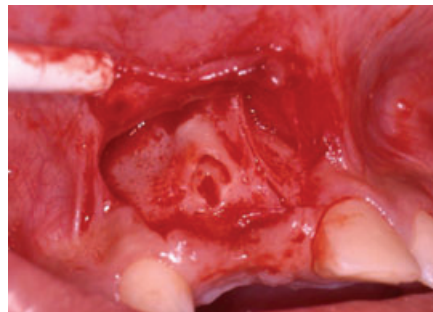

Fig. 5. Decoronated root canal filled with blood.

inducing bone formation at the inner surface of the root canal.

Following decoronation, an extensive horizontal (bucco-lingual) ridge concavity was left around the decoronated embedded root that required horizontal ridge augmentation. Porous deproteinized bovine bone mineral (Bio-Oss, Geistlich, Zurich, Switzerland) particles were applied into the osseous defect, covering the bony concavities around the decoronated embedded root, as well as the surrounding alveolar bone (Fig. 6). An occlusive absorbable collagen membrane (Bio-Gide, Geistlich, Zurich, Switzerland) was then placed to cover the particulated bone graft (Fig. 7). The flap was released to allow its closure without tension and sutured using resorbable 4-0 sutures (Vicryl, Ethicon, Somerville, NJ, USA).

The patient was seen every 2 weeks until soft tissue healing was clinically completed and radiographs were taken 4 months postoperatively to assess residual root resorption. The decoronated root was replaced by osseous tissue at this time, and orthodontic treatment was initiated. During orthodontic treatment, the boy was examined every 6 months by the periodontist and supportive periodontal maintenance therapy was performed by the dental hygienist. Healing of the treated site was uneventful, and there was a rapid vertical growth of the bony ridge at the decoronated site (Fig. 8).

At the age of 17.5 years, about two and a half years after decoronation and before his admission to

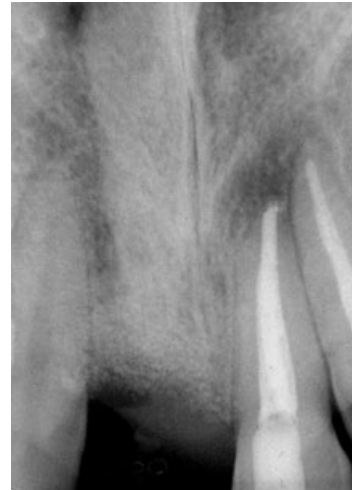

Fig. 8. Follow-up radiograph taken 18 months following decoronation.

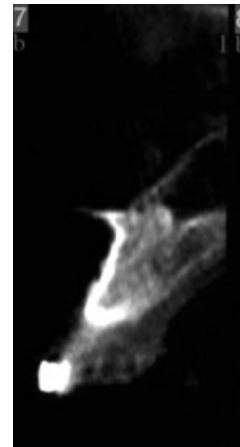


Fig. 9. CT radiograph of the alveolar ridge of the decoronated tooth site prior to implant placement.

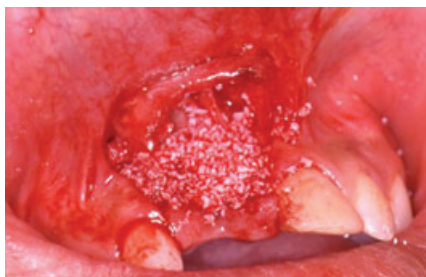

Fig. 6. Bone graft (Bio-Oss) applied on top of decoronated root to augment alveolar bone deficiency.

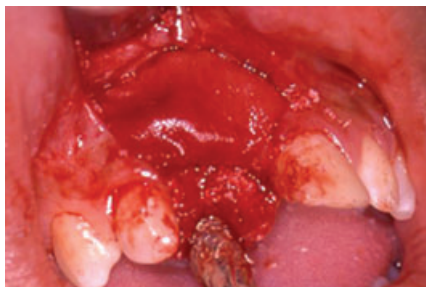

Fig. 7. Collagen membrane (Bio-Gide) covering Bio-Oss particles.

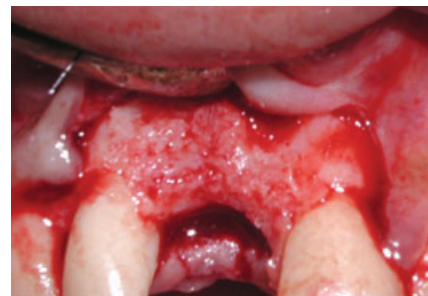

Fig. 10. Clinical view of alveolar ridge prior to implant insertion to replace the maxillary right central incisor.

A 15-mm long, 5-mm wide tapered screw type implant (3i, Osseotite NT; Implant Innovations Inc., Palm Beach Gardens, FL, USA) was placed using a two-stage surgical protocol (Figs 10 and 11). Six months later, the final crown was fabricated (Figs 12 and 13).

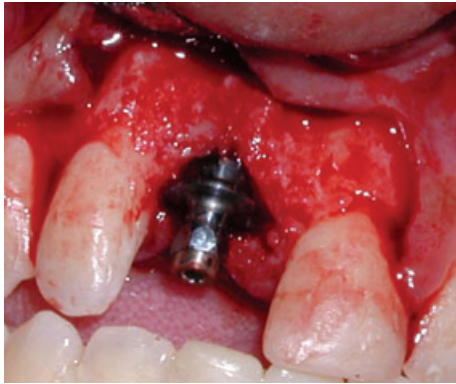


Fig. 11. Implant placement.

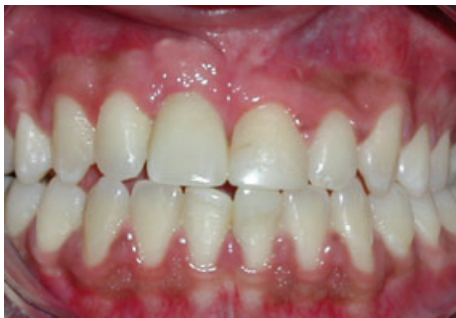

Fig. 12. Final implant supported restoration.

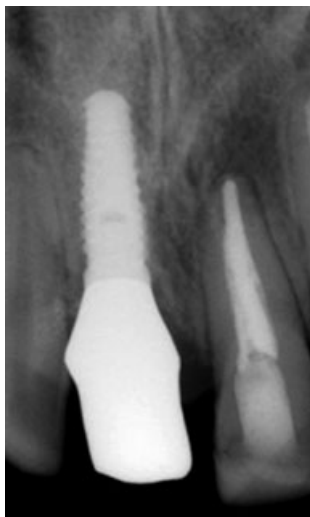

Fig. 13. Radiograph of the implant and final restoration.

Discussion

The surgical extraction of an ankylosed tooth often results in considerable loss of bone, due to the traumatic surgical procedure. Recently, an alternative treatment which includes the surgical luxation and orthodontic repositioning of the tooth with a distraction device was reported (48, 49). Although orthodontic movement will preserve more bone than surgical extraction, such treatment is not predictable and will not arrest the replacement resorption process. Moreover, the root canal filling material that remains entrapped in bone may jeopardize a future implant-based rehabilitation treatment.

In our case, the treatment plan included decoronation and ridge augmentation in order to preserve the remaining bone and to increase the horizontal and vertical dimensions of the alveolar ridge. Decoronation may be considered a type of guided bone regeneration due to the fact that the remaining, embedded in bone, blood clot filled residual root will conduct the formation of new bone from available osteoprogenitor cells to gradually replace it.

The timing of the decoronation procedure is critical, particularly when vertical growth of alveolar ridge is desired to a level commensurate with that of adjacent teeth. Maxillary skeletal and dental growth results in marked changes in all three dimensions during active development. Research models demonstrate that osseointegrated implants lack the compensatory growth mechanism of the natural dentition (50–52) and therefore the skeletal maturation and not the chronological age of the patient must be taken into consideration to avoid unacceptable esthetics of the implant-supported final prosthesis (53).

At present, therapeutic guidelines for avulsed teeth remain unpredictable. In cases of avulsed teeth with more than 60 min extraoral dry time, resorption and subsequent ankylosis is commonly expected. Our efforts should therefore be stressed towards prevention of dental trauma throughout the community, health care providers, and educational staff. It is also important to promote awareness and up-to-date treatment guidelines among health care providers. Correct application of these guidelines immediately after the traumatic injury should improve both short- and long-term outcomes. Further research is still necessary in order to arrest the resorption process and to develop a new biological inductive material that will eventually regenerate the severely injured periodontal ligament.

References

1. Andreasen JO, Andreasen FM. Textbook and color atlas of traumatic injuries to the teeth, 3rd edn. Copenhagen: Munksgaard; 1994. p. 383–425.

2. Andreasen JO. Aetiology and pathogenesis of traumatic dental injuries. A clinical study of 1298 cases. *Scand J Dent Res* 1970;78:329–42.
3. Hunter ML, Hunter B, Kingdon A, Addy M, Dummer PMH. Traumatic injuries to the maxillary incisor teeth in Swedish children. *Endodon Dent Traumatol* 1990;6:260–4.
4. Gassner R, Bosch R, Tuli T, Emshoff R. Prevalence of dental trauma in 6000 patients with facial injuries: implications for prevention. *Oral Surg Oral Med Oral Pathol Oral Radiol Endod* 1999;87:27–33.
5. Da Silva AC, Passeri LA, Mazzonetto R, de Moraes M, Moreira RWF. Incidence of dental trauma associated with facial trauma in Brazil: a 1-year evaluation. *Dent Traumatol* 2004;20:6–11.
6. Delattre JP, Resmond-Richard F, Allanche C, Perrin M, Michel JF, Le Berre A. Dental injuries among schoolchildren aged from 6 to 15, in Rennes. *Endod Dent Traumatol* 1995;11:186–8.
7. Levin L, Friedlander L, Geiger SB. Dental and oral trauma and mouthguard use during sport activities in Israel. *Dent Traumatol* 2003;19:237–40.
8. Brin I, Ben-Bassat Y, Heling I, Brezniak N. Profile of an orthodontic patient at risk of dental trauma. *Endod Dent Traumatol* 2000;16:111–5.
9. American Association of Endodontists. Glossary of endodontic terms, 7th edn. Chicago, IL: American Association of Endodontists; 2003.
10. Fountain SB, Camp JH. Traumatic injuries. In: Cohen S, Burns AC, editors. *Pathways of the pulp*, 6th edn. St Louis: Mosby; 1994.
11. Andreasen JO. Periodontal healing after replantation of traumatically avulsed human teeth: assessment by mobility testing and radiography. *Acta Odontol Scand* 1975;33:325–35.
12. Andreasen JO, Kristerson L. The effect of limited drying or removal of the periodontal ligament: periodontal healing after replantation of mature permanent incisors in monkeys. *Acta Odontol Scand* 1981;39:1–13.
13. American Association of Endodontists. Treatment of traumatic dental injuries. Recommended guidelines of the American Association of Endodontists. Chicago, IL: American Association of Endodontists; 2004.
14. Flores MT, Andreasen JO, Bakland LK, Feiglin B, Gutmann JL, Oikarinen K et al. Guidelines for the evaluation and management of traumatic dental injuries. *Dent Traumatol* 2001;17:193–8.
15. Andreasen JO. A time related study of periodontal healing and root resorption activity after replantation of mature permanent incisors in monkeys. *Swed Dent J* 1980;4:101–10.
16. Andreasen JO. Relationship between cell damage in the periodontal ligament after replantation and subsequent development of root resorption. *Acta Odont Scand* 1981;39:15–25.
17. Lindskog S, Pierce AM, Blomloff L, Hammarstrom L. The role of the necrotic periodontal membrane in cementum resorption and ankylosis. *Endod Dent Traumatol* 1985;1:96–101.
18. Hammarstrom L, Lindskog S. General morphology aspects of resorption of teeth and alveolar bone. *Int Endo J* 1985;18:93–108.
19. Tronstad L. Root resorption etiology, terminology and clinical manifestations. *Endod Dent Traumatol* 1988;4:241–52.
20. Kenny DJ, Barrett EJ, Johnston DH, Sigal MJ, Tenenbaum HC. Clinical management of avulsed permanent incisors using Emdogain: initial report of an investigation. *J Can Dent Assoc* 2000;66:21–4.
21. Lam K, Sae-Lim V. The effect of Emdogain gel on periodontal healing in replanted monkey's teeth. *Oral Surg Oral Med Oral Pathol Oral Radiol Endod* 2004;97:100–7.
22. Craig RG, Kallur SP, Inoue M, Rosenberg PA, LeGeros RZ. Effect of enamel matrix proteins on the periodontal connective tissue-material interface after wound healing. *J Biomed Mater Res* 2004;69A:180–7.
23. Schjott M, Andreasen JO. Emdogain does not prevent progressive root resorption after replantation of avulsed teeth: a clinical study. *Dent Traumatol* 2005;21:46–50.
24. Barrett EJ, Kenny DJ, Tenenbaum HC, Sigal MJ, Johnston DH. Replantation of permanent incisors in children using Emdogain. *Dent Traumatol* 2005;21:269–75.
25. Bryson EC, Levin L, Banchs F, Abbot PV, Trope M. Effect of immediate intracanal placement of Ledermix paste on healing of replanted dog teeth after extended dry times. *Dent Traumatol* 2002;18:316–21.
26. Wong KS, Sae-Lim V. The effect of intracanal Ledermix on root resorption of delayed replanted monkey teeth. *Dent Traumatol* 2002;18:309–15.
27. Oikarinen K. Dental tissues involved in exarticulation, root resorption and factors influencing prognosis in relation to replanted teeth. A review. *Proc Finn Dent Soc* 1993;89:29–44.
28. Andersson L. Dentoalveolar ankylosis and associated root resorption in replanted teeth. Experimental and clinical studies in monkeys and man. *Swed Dent J Suppl* 1988;56:1–75.
29. Andersson L, Bodin MK, Sorensen S. Progression of root resorption following replantation of human teeth after extended extra-oral storage. *Endod Dent Traumatol* 1989;5:38–47.
30. Ebeleseder KA, Friehs S, Ruda C, Perl C, Glockner K, Hulla H. A study of replanted permanent teeth in different age groups. *Endod Dent Traumatol* 1998;14:274–8.
31. Malmgren B, Cvek M, Lundberg M, Frykholm A. Surgical treatment of ankylosed and infrapositioned replanted incisors in adolescents. *Scand J Dent Res* 1984;92:391–9.
32. Simon JH, Kimura JT. Maintenance of alveolar bone by the intentional replantation of roots. *Oral Surg Oral Med Oral Pathol* 1974;37:936–45.
33. Simon JH, Jensen JL, Kimura JT. Histologic observations of endodontically treated replanted roots. *J Endod* 1975;1:178–80.
34. Johnson DL, Kelly JF, Flinton RJ, Cornell MT. Histologic evaluation of vital root retention. *J Oral Surg* 1974;32:829–33.
35. Levin M, Getter L, Cutright D, Bhaskar S. Intentional submergence of nonvital roots. *J Oral Surg* 1974;32:834–79.
36. Plata RL, Kelln EE. Intentional retention of vital submerged roots in dogs. *Oral Surg Oral Med Oral Pathol* 1976;42:100–8.
37. Whitaker DD, Shankle RJ. A study of the histologic reaction of submerged root segments. *Oral Surg Oral Med Oral Pathol* 1974;37:919–35.
38. O'Neal RB, Gound T, Levin MP, del Rio CE. Submergence of roots for alveolar bone preservation. I. Endodontically treated roots. *Oral Surg Oral Med Oral Pathol* 1978;45:803–10.
39. Gound T, O'Neal RB, del Rio CE, Levin MP. Submergence of roots for alveolar bone preservation. II. Reimplanted endodontically treated roots. *Oral Surg Oral Med Oral Pathol* 1978;46:114–22.
40. Malmgren B. Decoronation: how, why, and when? *J Calif Dent Assoc* 2000;28:846–54.
41. Malmgren B, Malmgren O. Rate of infraposition of reimplanted ankylosed incisors related to age and growth in children and adolescents. *Dent Traumatol* 2002;18:28–36.
42. Filippi A, Pohl Y, von Arx T. Decoronation of an ankylosed tooth for preservation of alveolar bone prior to implant placement. *Dent Traumatol* 2001;17:93–5.

43. Andersson L, Emami-Kristiansen Z, Hogstrom J. Single-tooth implant treatment in the anterior region of the maxilla for treatment of tooth loss after trauma: a retrospective clinical and interview study. *Dent Traumatol* 2003;19:126–31.
44. Oikarinen KS, Sandor GKB, Kainulainen VT, Salonen-Kemppi M. Augmentation of the narrow traumatized anterior alveolar ridge to facilitate dental implant placement. *Dent Traumatol* 2003;19:19–29.
45. Schwartz-Arad D, Levin L, Ashkenazi M. Treatment options of untreatable traumatized anterior maxillary teeth for future use of dental implantation. *Implant Dent* 2004;13:11–19.
46. Kohavi D, Dikapua L, Rosenfeld P, Tarazi E. Dental implants following trauma in young adults. *Refuat Hapeh Vehashinayim* 2003;20:70–8.
47. Schwartz-Arad D, Levin L. Post-traumatic use of dental implants to rehabilitate anterior maxillary teeth. *Dent Traumatol* 2004;20:344–7.
48. Takahashi T, Takagi T, Moriyama K. Orthodontic treatment of a traumatically intruded tooth with ankylosis by traction after surgical luxation. *Am J Orthod Dentofacial Orthop* 2005;127:233–41.
49. Razdolsky Y, El-Bialy TH, Dessner S, Buhler JE Jr. Movement of ankylosed permanent teeth with a distraction device. *J Clin Orthod* 2004;38:612–20.
50. Odman J, Grondahl K, Lekholm U, Thilander B. The effect of osseointegrated implants on the dento-alveolar development. *Eur J Orthod* 1991;13:279–86.
51. Thilander B, Odman J, Grondahl K, Lekholm U. Aspects on osseointegrated implants inserted in growing jaws. A biometric and radiographic study in young pigs. *Eur J Orthod* 1992;14:99–109.
52. Oesterle IJ, Cronin RJ Jr, Ranly DM. Maxillary implants and the growing patient. *Int J Oral Maxillofac Implants* 1993;8:377–87.
53. Thilander B, Odman J, Grondahl K, Friberg B. Osseointegrated implants in adolescents. An alternative in replacing missing teeth? *Eur J Orthod* 1994;16:84–95.