



Detection of periapical bone defects in human jaws using cone beam computed tomography and intraoral radiography

S. Patel^{1,2}, A. Dawood², F. Mannocci¹, R. Wilson³ & T. Pitt Ford¹

¹Endodontic Postgraduate Unit, King's College London Dental Institute, London, UK; ²Specialist Practice, London, UK; and ³Department of Periodontology, King's College London Dental Institute, London, UK

Abstract

Patel S, Dawood A, Mannocci F, Wilson R, Pitt Ford T. Detection of periapical bone defects in human jaws using cone beam computed tomography and intraoral radiography. *International Endodontic Journal*, 42, 507–515, 2009.

Aim To compare the diagnostic accuracy of intraoral digital periapical radiography with that of cone beam computed tomography (CBCT) for the detection of artificial periapical bone defects in dry human jaws.

Methodology Small and large artificial periapical lesions were prepared in the periapical region of the distal root of six molar teeth in human mandibles. Scans and radiographs were taken with a charged couple device (CCD) digital radiography system and a CBCT scanner before and after each periapical lesion had been created. Sensitivity, specificity, positive predictive values, negative predictive values and Receiver Operator Characteristic (ROC) curves as well as the reproducibility of each technique were determined.

Results The overall sensitivity was 0.248 and 1.0 for intraoral radiography and CBCT respectively, i.e. these techniques correctly identified periapical lesions in 24.8% and 100% of cases, respectively. Both imaging techniques had specificity values of 1.0. The ROC Az values were 0.791 and 1.000 for intraoral radiography and CBCT, respectively.

Conclusions With intraoral radiography, external factors (i.e. anatomical noise and poor irradiation geometry), which are not in the clinician's control, hinder the detection of periapical lesions. CBCT removes these external factors. In addition, it allows the clinician to select the most relevant views of the area of interest resulting in improved detection of the presence and absence of artificial periapical lesions.

Keywords: cone beam computed tomography, endodontic diagnosis, periapical lesions.

Received 21 September 2008; accepted 18 November 2008

Introduction

Chronic apical periodontitis is the localized inflammation of the periapical tissues caused by bacterial infection from within the root canal system and the surrounding dentine (Huomonen & Ørstavik 2002, Nair 2004). It can present radiographically as a periapical radiolucent lesion as a result of a localized inflammatory reaction to infection within the root canal system reducing the mineral density of the affected periapical bone (Bender 1982, Ørstavik & Larheim 2008). The ability of radio-

graphic systems to detect chronic apical periodontitis is essential in Endodontology for diagnosis, treatment planning, determination of outcome and epidemiological studies (Bender 1982, Patel *et al.* 2009, Ørstavik & Larheim 2008). At present, intraoral radiography is the technique of choice for diagnosing, managing and assessing endodontic disease (Lofthag-Hansen *et al.* 2007, Nair & Nair 2007, Patel *et al.* 2007), but it is well established that intraoral radiography is of limited use for detecting chronic apical periodontitis (Huomonen & Ørstavik 2002). Anatomical features (noise) immediately adjacent to the area of interest may result in poor contrast and therefore increased difficulty in assessing the periapical tissues. Several studies (Bender and Seltzer 1961, Pauls & Trott 1966, Schwartz & Foster

Correspondence: Shanon Patel, Specialist Endodontist, 45 Wimpole Street, London W1G 8SB, UK (Tel.: +020 7935 0080; e-mail: shanonpatel@hotmail.com).

1971) have concluded that artificially created periapical lesions in posterior region of dry jaws are not easily visualized on radiographs when confined to the cancellous bone (the area of interest), as it is masked by the more mineralized and therefore denser overlying cortical bone (i.e. the anatomical noise). Periapical radiolucent lesions are usually only diagnosed when there has been perforation or erosion of the overlying cortical plate. Regan & Mitchell (1963) came to similar conclusions after assessing the radiographs of 289 teeth in 27 human cadavers. Lee & Messer (1986) suggested that periapical lesions, which have been successfully detected when confined to the cancellous bone, may not be readily observed if the thickness of the cortical bone is increased, i.e. the anatomical noise increases resulting in less contrast between the area of interest (periapical lesion in cancellous bone) and overlying anatomical noise (cortical bone).

The cortical plate, which acts as anatomical noise, is also one of the reasons why the radiographic size of periapical lesions is under-estimated when compared with the actual size of the periapical lesion (Schwartz & Foster 1971, Shoha *et al.* 1974, Scarfe *et al.* 1999). Another factor which may influence the radiological size of the periapical lesion is the inability to take parallel radiographs in certain situations. This can cause geometric distortion that may result in an increase or decrease in the size of the periapical lesion, or even result in the inability to visualize periapical lesions (Bender & Seltzer 1961, Huuonen & Ørstavik 2002).

Tachibana & Matsumoto (1990) were one of the first groups to recognize the benefits of computed tomography in endodontics. Computed tomography (CT) has been used in the management of endodontic problems to overcome the limitations (anatomical noise and geometric distortion) of conventional radiography (Marmary *et al.* 1999, Velvart *et al.* 2001). However, CT imaging has several disadvantages. These include the high radiation doses and the cost of the scans, and access to CT scanners is limited to dedicated specialized radiography centres. Over the last two decades, cone beam computed tomography (CBCT) has been developed specifically to produce three-dimensional scans of the maxillo-facial skeleton (Arai *et al.* 1999, Mozzo *et al.* 1999). Essentially, there are two types of CBCT, large volume CBCT scanners have a large field of view allowing the entire maxilla and/or mandible to be scanned, whereas limited CBCT scanners have a smaller field of view (3–4 cm³). The smaller the field of view, the lower the radiation (with all other factors being equal). These limited CBCT scanners are better

for managing endodontic problems as only the relevant part of the jaw is scanned. CBCT's major advantage over CT scanners is the huge reduction in radiation exposure. This is due in part to rapid scan times, pulsed X-ray beams and sophisticated image receptor sensors (Cotton *et al.* 2007, Patel *et al.* 2007). Shortcomings of both CT and CBCT include poorer resolution, scattering and artefacts when compared with conventional radiography (Patel 2009, Patel *et al.* 2009).

Loftag-Hansen *et al.* (2007) has compared CBCT scans with two-angled (parallax) periapical radiographs to assess the periapical status of posterior mandibular and maxillary teeth. The prevalence of periapical lesions associated with teeth with endodontic problems was 31% higher when CBCT was used. Estrela *et al.* (2008) compared the ability of panoramic and periapical radiographs with CBCT for the detection of apical periodontitis. Their results confirmed the apparent increased sensitivity of CBCT for detecting apical periodontitis. Similar findings have also been reported by Low *et al.* (2008). These clinical studies appear to presume that the radiological findings from CBCT represent the true status of the periapical tissues, i.e. that CBCT can be used as a 'gold standard' to detect the presence or absence of periapical disease. The captured CBCT data also reveal additional relevant information about root canal morphology and neighbouring anatomical structures (e.g. the maxillary sinus and mandibular nerve), the true nature and relationship of a periapical lesion to a root and the thickness of the cortical and cancellous plates (Low *et al.* 2008), which cannot be readily obtained from conventional radiological views. To date, there have been no studies correlating the radiological findings of CBCT with the actual features found within the human jaws.

The aim of the present study was to compare the diagnostic accuracy of CBCT with intraoral periapical radiography for the detection of artificially prepared periapical bone defects in dry human jaws.

Materials and methods

Subject material

Ten first molar teeth on six partially dentate intact human dry mandibles were used this study (Department of Anatomy and Human Sciences, King's College London, University of London). Each mandible was soaked for 90 min in warm water into which hand dish washing liquid (Fairy Liquid Original, Procter & Gamble, Weybridge, Surrey, UK) had been added to reduce

the surface tension of the bone therefore increasing its water absorption. This also increased the moisture content and the resilience of the dry mandibles for the subsequent extraction of teeth. Screening radiographs and CBCT scans were taken of each first molar tooth to identify existing periapical lesions.

Prosthetic dental wax (Ribbon Wax; Metrodent, Huddersfield, UK) was used as a soft tissue substitute. The wax was applied in layers. Radiographs and CBCT scans were taken after each incremental layer of wax had been applied and compared with equivalent *in vivo* views. The process was continued until the radiological appearance of the dry mandible was similar to the radiological appearance of patient's mandibular molars. Once the optimal thickness of wax had been determined, it was applied to all mandibles.

The crown of the first molar tooth was sectioned through the furcation separating the mesial and distal roots. The distal root was then atraumatically extracted. The base of the socket was inspected with the aid of a dental operating microscope (3 step entrée Dental Microscope; Global, St Louis, MO, USA) to confirm that it was intact. The root was then firmly replaced into the socket. Baseline radiographs and CBCT scans were taken. Four first molar teeth were not used (one had an existing periapical lesion and three were fractured as they were being extracted).

The distal root was then removed again and a spherical periapical lesion of 2 mm (small) in diameter was prepared by drilling a hole into the cancellous bone at the base of the extraction socket using a premeasured dental laboratory bur (No. 406702 Diadur[®] Carbide Cutter; Bracon Limited, Etchingam, UK) in a laboratory handpiece. The mandible was then soaked in warm soapy water again for 15 min and the root was then firmly re-implanted into its socket. Radiographs and CBCT scans were then taken. The process was repeated using a second bur to enlarge the existing periapical lesion to 4 mm in diameter (No. 406602 Diadur[®] Carbide Cutter; Bracon Limited). A fresh fillet of beef tightly wrapped in cling film was used to mimic the tongue in the mandible for CBCT scans.

Radiographic technique

Two jigs were made for each mandible, one to allow standardized reproducible radiographs to be taken with a dental X-ray machine (Planmeca Prostyle Intra, Helsinki, Finland) using a digital CCD (Schick Technologies, New York, NY, USA). A second jig was made for standardized images to be taken with the small volume

CBCT scanner (Veraviewpocs; J Morita Manufacturing, Kyoto, Japan). The angle (i.e. the border between the ramus and body) of each mandible was embedded in polyvinyl-siloxane impression material (President, Coltène AG, Altstätten Switzerland) mounted onto medium-density fibreboard board using cyanoacrylate adhesive (SuperGlue; The Original Super Glue Corporation, Rancho Cucamonga, CA, USA). Once set, each mandible could be removed and reinserted in exactly the same position into its own jig. The X-ray tube head and digital sensor were also secured into position using a similar technique. The X-ray tube head, digital sensor and mandible were aligned to allow radiographs to be exposed using the paralleling technique. A similar jig was made for each mandible to be exactly repositioned in the CBCT scanner. Exposure parameters of 66 kV, 7.5 mA and a 0.10 s were used for the intraoral radiograph and 80 kV, 3.0 mA and a 17.5 s scan for the CBCT scanner. CBCT data was reformatted to align the root axis with the vertical plane in the sagittal and coronal views. The brightness and contrast of all the acquired images was enhanced to improve visualization of the periapical lesions. All CBCT data was resliced (0.125 slice intervals and 1.5-mm slice thicknesses).

Radiological assessment

Six examiners (endodontists $n = 2$, endodontic post-graduates $n = 4$) individually assessed the radiographs and CBCT scans in the following sequence: session 1 – radiographs (including duplication to assess intra-observer agreement), session 2 – CBCT scans and session 3 – CBCT scans repeated (to assess intra-observer agreement).

The images were then randomly ordered in each session and viewed as a powerpoint presentation (Microsoft Corp, Seattle, WA, USA) on a laptop computer (Toshiba Portege R500-11Z, Tokyo, Japan) which had a screen pixel resolution of 1280 × 1024. A CBCT image that best confirmed the presence or absence of a radiolucent periapical lesion in the sagittal and coronal planes was used as the starting point for each tooth observation. Examiners also had access to the raw CBCT data allowing them to scroll through any of the orthogonal scans. All images were assessed in a quiet dimly lit room. The examiners were trained using examples of clinical radiographs and CBCT images with and without the presence of periapical lesions before embarking on the assessment; a periapical lesion was defined as a radiolucency associated with the radiographic apex of the distal root of the mandibular first

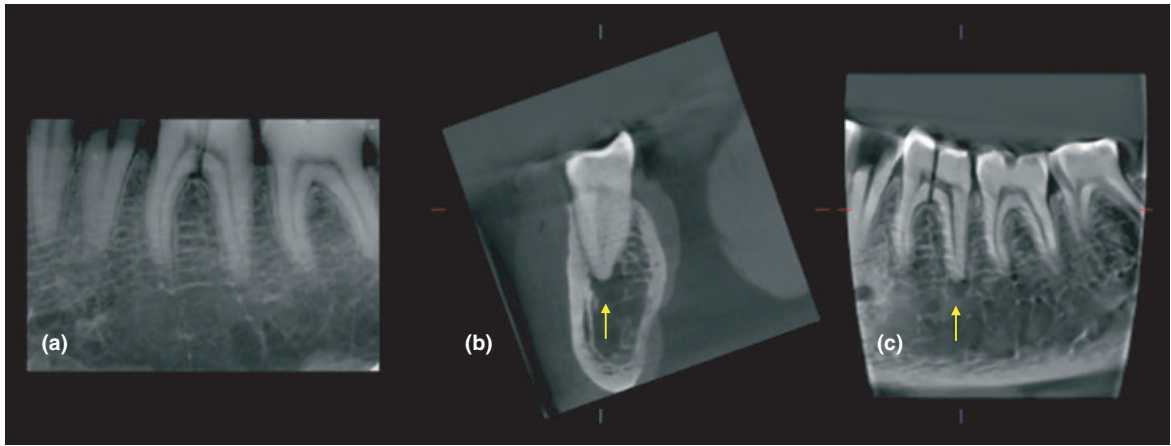


Figure 1 (a) Radiograph and (b) coronal and sagittal reconstructed cone beam computed tomography (CBCT) image of the same molar tooth. Note that an artificial lesion (yellow arrows) can be identified on the CBCT images but not on the periapical radiograph.

molar, which was at least twice the width of the periodontal ligament space (Fig. 1).

Examiners were asked to note down the presence or absence of a periapical lesion using a 5-point confidence scale as follows: 1 – periapical lesion definitely not present, 2 – periapical lesion probably not present, 3 – unsure, 4 – periapical lesion probably present and 5 – periapical lesion definitely present.

There was at least an interval of 1 week between each session. To assess intra-examiner validity for the radiographic assessment nine radiographs were repeated within session 1. Session 3 was used to assess intra-examiner validity for session 2.

Data analysis

Stata™ software (Stata 9, College Station, TX, USA) was used to analyse the raw data. Sensitivity, specificity and positive (PPV) and negative (NPV) predictive values were determined; Receiver Operating Characteristic (ROC) curve analysis was used to assess the diagnostic accuracy of each examiner and each imaging system for detecting the presence or absence of a periapical lesion. Inter-examiner and intra-examiner agreement was assessed by Kappa statistics for 50% of the intraoral radiographs and 100% of the CBCT scans.

Results

The overall sensitivity of intraoral radiography (0.248) was lower than CBCT (1.000) regardless of the size of the lesion ($P = 0.026$), i.e. these techniques correctly

Table 1 Mean (SD) values of sensitivity, specificity, PPV and NPV for radiograph and CBCT for detecting small periapical lesions

	Sensitivity	Specificity	PPV	NPV
Radiograph	0.2 (0.0)	1 (0.0)	1 (0.0)	0.545 (0.0)
CBCT	1*	1	1	1

SD, standard deviation; PPV, positive predictive value; NPV, negative predictive value; CBCT, cone beam computed tomography.

*Wilcoxon matched-pairs, signed-ranks test for differences in sensitivity: $P = 0.014$.

Table 2 Mean (SD) of sensitivity, specificity, PPV and NPV for radiograph and CBCT for detecting large periapical lesions

Examiner	Sensitivity	Specificity	PPV	NPV
Radiograph	0.35 (0.16)	1 (0.0)	1 (0.0)	0.573 (0.03)
CBCT	1*	1	1	1

SD, standard deviation; PPV, positive predictive value; NPV, negative predictive value; CBCT, cone beam computed tomography.

*Wilcoxon matched-pairs, signed-ranks test for differences in sensitivity: $P = 0.024$.

Table 3 Mean (SD) of sensitivity, specificity, PPV and NPV for radiograph and CBCT for detecting all periapical lesions

Examiner	Sensitivity	Specificity	PPV	NPV
Radiograph	0.248 (0.10)	1 (0.0)	1 (0.0)	0.384 (0.02)
CBCT	1*	1	1	1

SD, standard deviation; PPV, positive predictive value; NPV, negative predictive value; CBCT, cone beam computed tomography.

*Wilcoxon matched-pairs, signed-ranks test for differences in sensitivity: $P = 0.026$

Table 4 Area under the curve from ROC analysis of radiographs and CBCT for individual examiners: comparison of no defect with both small and large defects

Examiner	Radiograph	Cone beam	P-value
1	0.875	1.000	0.056
2	0.917	1.000	0.138
3	0.708	1.000	<0.001
4	0.764	1.000	0.025
5	0.708	1.000	<0.001
6	0.771	1.000	0.020
Mean (SD)	0.791 (0.087)	1.000 (0.000)	0.027*

SD, standard deviation; ROC, Receiver Operator Characteristic; CBCT, cone beam computed tomography.

*P-value from Wilcoxon matched-pairs, signed-ranks test.

Table 5 Area under the curve from ROC analysis of radiographs and CBCT for individual examiners: comparison of no defect with small defects

Examiner	Radiograph	Cone beam	P-value
1	0.833	1.000	0.114
2	0.917	1.000	0.317
3	0.667	1.000	0.002
4	0.722	1.000	0.055
5	0.750	1.000	0.025
6	0.764	1.000	0.071
Mean (SD)	0.766 (0.088)	1.000 (0.000)	0.028*

SD, standard deviation; ROC, Receiver Operator Characteristic; CBCT, cone beam computed tomography.

*P-value from Wilcoxon matched-pairs, signed-ranks test.

Table 6 Area under the curve from ROC analysis of radiograph and CBCT for individual examiners: comparison of no defect with large defects

Examiner	Radiograph	Cone beam	P-value
1	0.917	1.000	0.317
2	0.917	1.000	0.317
3	0.750	1.000	0.025
4	0.806	1.000	0.112
5	0.667	1.000	0.002
6	0.778	1.000	0.082
Mean (SD)	0.860 (0.098)	1.000 (0.000)	0.027*

SD, standard deviation; ROC, Receiver Operator Characteristic; CBCT, cone beam computed tomography.

*P-value from Wilcoxon matched-pairs, signed-ranks test.

identified all periapical lesions in 24.8% and 100% of cases, respectively. Both imaging techniques had high specificity values of 1.000, i.e. both techniques were equally accurate in diagnosing healthy periapical periodontium (Tables 1–3). The sensitivity of intraoral radiography was lower than CBCT for detecting the presence of both ‘small’ periapical lesions (0.200; $P = 0.014$) and ‘large’ periapical lesions (0.350; $P = 0.024$).

Table 7 Kappa values for intra- and inter-examiner agreement in reading radiographs and CBCT images

Examiner	Intra-examiner kappa	
	Radiograph	Cone beam
1	0.386	0.670
2	0.294	1.000
3	0.182	0.686
4	0.667	0.531
5	1.000	ND
6	0.526	ND
Mean (SD)	0.509 (0.295)	0.722 (0.198)
Inter-examiner kappa	0.351	0.641

SD, standard deviation; ND, not done.

The ROC analysis for intraoral radiography revealed a lower Az value (0.766) than CBCT (1.000) for the detection of smaller periapical lesions ($P = 0.028$). Similarly, the intraoral radiography Az value (0.860) for the detection of larger periapical lesions was also less than that for CBCT (1.000) ($P = 0.027$). The overall Az value regardless of size of lesion was 0.791 for intraoral radiography and 1.000 for CBCT ($P = 0.027$) (Tables 4–6).

The kappa value for overall inter-examiner agreement was 0.351 and 0.641 for intraoral radiography and CBCT, respectively. The mean intra-examiner agreement was 0.509 and 0.722 for intraoral radiography and CBCT, respectively (Table 7).

Discussion

A diagnostic test should exhibit validity and reliability if it is to be useful (Zakariassen *et al.* 1984). In this study, the diagnostic tests under investigation (intraoral radiographs and CBCT) should be able to detect periapical disease when it is present (validity) and should be repeatable, i.e. generate the same result (reliability).

Periapical lesions were created immediately below the distal root of first molar tooth as it was surrounded by more cancellous bone than its mesial counterpart, this also perhaps explains why periapical radiolucent lesions are usually first detected on the mesial root(s) of mandibular first molars (Bender 1982). The distal root was also easier to extract without damaging it as it tended to be straighter than the mesial root. This investigation compared the efficacy of intraoral radiography and CBCT in detecting artificial periapical lesions limited to the cancellous bone in human mandibles. The results of this study suggest that CBCT imaging of teeth with endodontic problems (e.g. pulpitis

and periapical periodontitis) lesions is of value. This study showed that intraoral radiography was not sensitive at detecting periapical lesions of either size; the overall sensitivity was 0.248 (24.8%). However, the intraoral radiography was more accurate at diagnosing 'large' periapical lesions than 'small' periapical lesions. This probably reflects the increased volume of bone destruction, and is in agreement with the findings of Paurazas *et al.* (2000). Intraoral radiography was accurate in confirming when periapical lesions were not present, in this situation there was 100% accuracy (specificity 1.0). CBCT was 100% accurate in diagnosing the presence (sensitivity 1.0) and absence (specificity 1.0) of periapical lesions. ROC analysis confirmed that CBCT was significantly more accurate than intraoral radiography in detecting the presence of periapical disease. The overall diagnostic accuracy of intraoral radiographs (ROC Az value 0.791) in this study was in the same order of magnitude as other studies assessing artificial periapical lesions within the cancellous bone using digital (CCD) intraoral radiography (Kullendorff *et al.* 1996, Paurazas *et al.* 2000). The results of the sensitivity, specificity, PPV, NPV and ROC analysis of intraoral radiographs in the present study are also similar to the findings of a recent clinical study (Estrela *et al.* 2008). In the clinical setting, the detection of periapical lesions may have been even poorer with intraoral radiography because of the additional problem of less than ideal irradiation geometry associated with the difficulty in placing image receptors in an ideal position in certain regions of the oral cavity. In addition, divergent roots may also be displayed with varying degrees of distortion on radiographs (Lofthag-Hansen *et al.* 2007).

It would have been desirable to use human cadavers to accurately reproduce soft tissue attenuation and scatter from the CBCT X-ray beam. However, as this study was being carried out in an unlicensed area (private practice) rather than a University Institution, this was not possible because of Government legislation (Human Tissue Act 2004). Therefore, dry mandibles rehydrated in soapy water were used. Prosthetic dental wax was used as a soft tissue substitute as it has the same optical density as human soft tissue (Ricketts *et al.* 1995, 1997). Pilot studies confirmed that the radiographic and CBCT appearance of this mandible model closely replicated clinical images on patients.

The results of this study appear to validate clinical studies that have used CBCT as the 'gold standard' for determining the presence or absence of periapical lesions (Lofthag-Hansen *et al.* 2007, Estrela *et al.*

2008, Low *et al.* 2008). CBCT has evolved from CT. Essentially, the collected raw data from both imaging techniques may be formatted and viewed in similar ways. Velvart *et al.* (2001) compared the diagnostic information of CT scans with periapical radiographs of 50 mandibular posterior teeth scheduled for periapical surgery to the clinical findings at the time of surgery. They found that CT was 100% accurate in detecting the presence of periapical lesions compared with 78% for intraoral radiographs. The higher detection rate of periapical lesions with radiographs in this study may have been due to long-standing chronic periapical periodontitis, which may have eroded the cortical bone. It would have been interesting to correlate the cortical plate involvement as seen on coronal CT slices to the corresponding radiographs. Similar results were also found by Huuemonen *et al.* (2006) when they assessed maxillary molar teeth. The reduced accuracy of intraoral radiography in detecting periapical lesions using intraoral radiography compared with CT or CBCT technology in these clinical studies and the present study may be due to the fact that the lesions were confined to the cancellous bone only. This results in the mineral bone loss of the periapical lesion being masked by the denser, more mineralized cortical plate, which means that these lesions are more difficult to detect with intraoral radiographs (Schwartz & Foster 1971, Bender 1982). Changes in bone density, trabeculae architecture, bone marrow spaces and morphological variations in the apical region would also be missed (Halse *et al.* 2002).

Cone beam computed tomography software allows the clinician to view reconstructed slices of data without the overlying cortical plate (anatomical noise), which may otherwise hide what is actually occurring within the cancellous bone. With CBCT, the examiner usually specifies the orientation of the reconstructed slice(s) resulting in orthogonal views that are parallel and perpendicular to the long axis of the root under investigation. In addition, the thickness of each slice (i.e. how much information) and the interval between each slice can be adjusted. These factors ultimately result in periapical lesions being significantly more perceptible to the examiner compared with intraoral radiographs as the CBCT software may be used to maximize the diagnostic yield of the captured data in each case. In addition, the reconstructed slices are geometrically accurate. Therefore, periapical lesions will not change size or disappear on reconstructed scans as can happen with intraoral radiography as a result of poor irradiation geometry (Gröndahl & Huuemonen

2004). Not only can the presence of a periapical lesion(s) be diagnosed with CBCT, but the specific root that it is associated with can also be confirmed. This may influence treatment planning (Lofthag-Hansen *et al.* 2007). It was interesting to note that the favourable results achieved with CBCT in this study were despite the fact that none of the examiners had previous experience in the interpretation of CBCT data.

A digital intraoral radiographic system rather than a conventional X-ray film was used in this study as the resulting image was dynamic and therefore could be easily enhanced (contrast/brightness) to improve the diagnostic yield of the radiographic image (Kullendorff & Nilsson 1996). Several studies have shown that there is no difference in the detectability of artificially created periapical lesions using conventional X-ray films and digital sensors (Kullendorff & Nilsson 1996, Barbat & Messer 1998, Stavropoulos & Wenzel 2007). Enhancing the radiographic images (e.g. colourizing and inverting) with software was not carried out as it has not been shown to enhance the detection of periapical lesions (Barbat & Messer 1998). The detection rate of periapical lesions with radiographs may have been higher if parallax radiographs were taken of each tooth (Brynolf 1970a,b) and if a consensus agreement between all the examiners was reached for each case (Molven *et al.* 2002).

There is a school of thought that believes that periapical lesions confined to the cancellous bone and not affecting the cortical plate cannot be detected using intraoral radiography (Bender & Seltzer 1961, Radaman & Mitchell 1962, Schwartz & Foster 1971, Bender 1982). However, in the present study a number of periapical lesions confined to cancellous bone were detected using intraoral radiography. Similar findings have been reported by other investigators (Barbat & Messer 1998, Marmary *et al.* 1999, Paurazas *et al.* 2000, Wallace *et al.* 2001).

The inter- and intra-examiner agreement between the examiners was higher with CBCT, suggesting that CBCT scans are perhaps easier to interpret compared with periapical radiographs. Goldman *et al.* (1972, 1974) found inter-examiner agreement between their six examiners was 47% and intra-examiner agreement was between 74% and 80% using intraoral radiographs. Similar results were presented by Zakariasen *et al.* (1984), who reported that inter-examiner agreement was only 38% and intra-observer agreement was between 64.5 and 81%. Although not directly comparable with the Kappa results in this study, they do seem to suggest a similar level of agreement.

The results of this study provides evidence of CBCT's validity and reliability for detecting the presence of periapical lesions. Further investigations are required to determine the diagnostic validity of different CBCT scanners and the effect of changing the exposure parameters on the detection of periapical lesions. Intraoral radiography, which is the imaging technique of choice for the management for periapical disease, appears to be quite crude on both accounts (validity and reliability) in the detection of the presence of periapical lesions. The superior accuracy of CBCT may result in a review of the radiographic techniques used in the management of endodontic problems, and to detect periapical lesions in outcome and epidemiological studies since the prevalence of apical disease may be significantly under-estimated with conventional radiography (Estrela *et al.* 2008, Patel *et al.* 2009).

Radiation exposure to patients should be kept as low as reasonably practicable (ALARP). The effective radiation dose from CBCT is higher than conventional radiography, therefore when considering taking a CBCT scan the benefits of this investigation must outweigh any potential risks to the patient (Farman & Farman 2005). Evidence-based selection criteria for the use of CBCT are required (Patel *et al.* 2007, Patel 2009).

Conclusion

External factors (i.e. anatomical noise and poor irradiation geometry), which are not in the operators control with intraoral radiography, dictate what might or might not be revealed on a conventional periapical image. CBCT eliminates these external factors. In addition, it allows the clinician to select the most relevant views. This study indicates that this results in improved detection of the presence and absence of periapical disease.

Acknowledgements

The authors would like to thank Professor K. Horner (University of Manchester, UK) for his help and advice in the preparation of this manuscript, and Cavendish Imaging, London, UK for their technical expertise.

References

- Arai Y, Tammissalo E, Iwai K, Hashimoto K, Shinoda K (1999) Development of a compact computed tomographic apparatus for dental use. *Dentomaxillofacial Radiology* **28**, 245–8.

- Barbat J, Messer HH (1998) Detectability of artificial periapical lesions using direct digital and conventional radiography. *Journal of Endodontics* **24**, 837–42.
- Bender IB (1982) Factors influencing the radiographic appearance of bony lesions. *Journal of Endodontics* **23**, 5–14.
- Bender IB, Seltzer S (1961) Roentgenographic and direct observation of experimental lesions in bone: I. *Journal of the American Dental Association* **62**, 152–60.
- Brynolf I (1970a) Roentgenologic periapical diagnosis IV. When is one roentgenogram not sufficient? *Swedish Dental Journal* **63**, 415–23.
- Brynolf I (1970b) Roentgenologic periapical diagnosis III. The more roentgenograms – the better information? *Swedish Dental Journal* **63**, 409–13.
- Cotton TP, Geisler TM, Holden DT, Schwartz SA, Schindler WG (2007) Endodontic applications of cone-beam volumetric tomography. *Journal of Endodontics* **9**, 1121–32.
- Estrela C, Bueno MR, Leles CR, Azevedo B, Azevedo JR (2008) Accuracy of cone beam computed tomography and panoramic radiography for the detection of apical periodontitis. *Journal of Endodontics* **34**, 273–279.
- Farman AG, Farman TT (2005) A comparison of 18 different X-ray detectors currently used in dentistry. *Oral Surgery, Oral Medicine, Oral Pathology, Oral Radiology and Endodontology* **99**, 485–9.
- Goldman M, Pearson AH, Darzenta N (1972) Endodontic success – who’s reading the radiograph? *Oral Surgery, Oral Pathology, Oral Medicine* **33**, 432–7.
- Goldman M, Pearson AH, Darzenta N (1974) Reliability of radiographic interpretations. *Oral Surgery, Oral Pathology, Oral Medicine* **38**, 287–93.
- Gröndahl H-G, Huuononen S (2004) Radiographic manifestations of periapical inflammatory lesions. *Endodontic Topics* **8**, 55–67.
- Halse A, Molven O, Fristad I (2002) Diagnosing periapical lesions—diagnosis and borderline cases. *International Endodontic Journal* **35**, 703–9.
- Human Tissue Act (2004) *Office of Public Sector Information*. <http://www.opsi.gov.uk/ACTS/acts2004/ukpga>.
- Huuononen S, Ørstavik D (2002) Radiological aspects of apical periodontitis. *Endodontic Topics* **1**, 3–25.
- Huuononen S, Kvist T, Gröndahl K, Molander A (2006) Diagnostic value of computed tomography in re-treatment of root fillings in maxillary teeth. *International Endodontic Journal* **39**, 827–33.
- Kullendorff B, Nilsson M (1996) Diagnostic accuracy of direct digital dental radiography for the detection of periapical bone lesions – II. Effects on diagnostic accuracy after application of image processing. *Oral Surgery, Oral Medicine, Oral Pathology, Oral Radiology and Endodontology* **82**, 585–9.
- Kullendorff B, Nilsson M, Rohlin M (1996) Diagnostic accuracy of direct digital dental radiography for the detection of periapical bone lesions – overall comparison between conventional and direct digital radiography. *Oral Surgery, Oral Medicine, Oral Pathology, Oral Radiology and Endodontology* **82**, 344–50.
- Lee S-J, Messer HH (1986) Radiographic appearance of artificially prepared periapical lesions confined to cancellous bone. *International Endodontic Journal* **19**, 64–72.
- Lofthag-Hansen S, Huuononen S, Gröndahl K, Gröndahl H-G (2007) Limited cone-beam CT and intraoral radiography for the diagnosis of periapical pathology. *Oral Surgery, Oral Medicine, Oral Pathology, Oral Radiology and Endodontology* **103**, 114–19.
- Low MTL, Dula KD, Bürgin W, von Arx T (2008) Comparison of periapical radiography and limited cone beam tomography in posterior maxillary teeth referred for apical surgery. *Journal of Endodontics* **34**, 557–562.
- Marmary Y, Koter T, Heling I (1999) The effect of periapical rarefying osteitis on cortical and cancellous bone. A study comparing conventional radiographs with computed tomography. *Dentomaxillofacial Surgery* **28**, 267–71.
- Molven O, Halse A, Fristad I (2002) Long-term reliability and observer comparisons in the radiographic diagnosis of periapical disease. *International Endodontic Journal* **35**, 142–7.
- Mozzo P, Procacci C, Tacconi A, Martini PT, Andreis IA (1999) A new volumetric CT machine for dental imaging based on the cone-beam technique: preliminary results. *European Radiology* **8**, 1558–64.
- Nair PNR (2004) Pathogenesis of apical periodontitis and the cause of endodontic failures. *Critical Review in Oral Biology and Medicine* **15**, 348–81.
- Nair MK, Nair UP (2007) Digital and advanced imaging in endodontics: a review. *Journal of Endodontics* **33**, 1–6.
- Nicopoulou-Karayianni K, Bragger U, Patrikiou A, Stassinakis A, Lang NP (2002) Image processing for enhanced observer agreement in the evaluation of periapical bone changes. *International Endodontic Journal* **35**, 615–22.
- Ørstavik D, Larheim TA (2008) Chapter 6, Radiology of apical periodontitis. In: (Ørstavik D, Pitt Ford T, eds) *Essential Endodontology*, 2nd Edn. Oxford: Blackwell Munksgaard.
- Patel S (2009) New dimensions in endodontic imaging: part 2. Cone beam computed tomography. *International Endodontic Journal*, in press.
- Patel S, Dawood A, Whaites E, Pitt Ford T (2007) The potential applications of cone beam computed tomography in the management of endodontic problems. *International Endodontic Journal* **40**, 818–30.
- Patel S, Dawood A, Whaites E, Pitt Ford T (2009) New dimensions in endodontic imaging: part 1. Conventional and alternative radiographic systems. *International Endodontic Journal*, in press.
- Pauls V, Trott JR (1966) A radiological study of experimentally produced lesions in bone. *Dental Practice* **16**, 254–8.
- Paurazas SB, Geist JR, Pink FE, Hoen MM, Steiman HR (2000) Comparison of diagnostic accuracy of digital imaging by using CCD and CMOS_APS sensors with E-speed film in the detection of periapical lesions. *Oral Surgery, Oral Medicine,*

- Oral Pathology, Oral Radiology and Endodontology* **89**, 356–62.
- Radaman AE, Mitchell DF (1962) A roentgenographic study of experimental bone destruction. *Oral Surgery, Oral Medicine, Oral Pathology* **15**, 934–43.
- Regan JE, Mitchell DF (1963) Evaluation of periapical radiolucencies found in cadavers. *Oral Surgery, Oral Medicine, Oral Pathology* **66**, 529–533.
- Ricketts DN, Kidd EAM, Smith BGN, Wilson RF (1995) Clinical and radiographic diagnosis of occlusal caries: a study *in vitro*. *Journal of Oral Rehabilitation* **22**, 15–20.
- Ricketts DN, Whaites EJ, Kidd EA, Brown JE, Wilson RF (1997) An evaluation of the diagnostic yield from bitewing radiographs of small approximal and occlusal carious lesions in a low prevalence sample *in vitro* using different film types and speeds. *British Dental Journal* **182**, 51–8.
- Scarfe WC, Czerniejewski VJ, Farman AG, Avant SL, Molteni R (1999) *In vivo* accuracy and reliability of color-coded image enhancements for the assessment of periradicular lesion dimensions. *Oral Surgery, Oral Medicine, Oral Pathology, Oral Radiology and Endodontology* **88**, 603–11.
- Schwartz SF, Foster JK (1971) Roentgenographic interpretation of experimentally produced bony lesions. Part 1. *Oral Surgery, Oral Medicine, Oral Pathology* **32**, 606–12.
- Shoha RR, Dowson J, Richards AG (1974) Radiographic interpretation of experimentally produced bony lesions. *Oral Surgery, Oral Medicine, Oral Pathology, Oral Radiology and Endodontics* **38**, 294–303.
- Stavropoulos A, Wenzel A (2007) Accuracy of cone beam dental CT, intraoral digital and conventional film radiography for the detection of periapical lesions: an *ex vivo* study in pig jaws. *Clinical Oral Investigations* **11**, 101–6.
- Tachibana H, Matsumoto K (1990) Applicability of X-ray computerized tomography in endodontics. *Endodontics and Dental Traumatology* **6**, 16–20.
- Velvart P, Hecker H, Tillinger G (2001) Detection of the apical lesion and the mandibular canal in conventional radiography and computed tomography. *Oral Surgery, Oral Medicine, Oral Pathology, Oral Radiology and Endodontology* **92**, 682–8.
- Wallace JA, Nair MK, Colaco MF, Kapa SF (2001) A comparative evaluation of the diagnostic efficacy of film and digital sensors for detection of simulated periapical lesions. *Oral Surgery, Oral Medicine, Oral Pathology, Oral Radiology and Endodontology* **92**, 93–7.
- Zakariassen KL, Scott DA, Jensen JR (1984) Endodontic recall radiographs: how reliable is our interpretation of endodontic success or failure and what factors affect our reliability? *Oral Surgery, Oral Pathology, Oral Medicine* **57**, 343–7.