

Clinical cases indicate that silver points can be adequately used with teeth that require preparations for posts. Other cases are presented as evidence that healing takes place without root canal fillings, but with the use of a medicament. On the basis of this finding and the belief that neither gutta-percha nor silver points produce "hermetic seals," the validity of the present concept of the role of the root canal filling in treatment is questioned.

Silver points and gutta-percha and the role of root canal fillings

Hyman Dubrow, DDS, Far Rockaway, NY

In recent literature and lectures some clinicians have questioned the use of silver points for root canal fillings. Their main objections have been that the silver points cannot produce a "hermetic" or "molecular" seal¹ and that they are not amenable to the preparation of posts² because the apical seal may be disturbed and because it is difficult to prepare the post holes. The atmosphere has become so supercharged that some dentists accept only gutta-percha fillings from endodontists for their referred patients. Some believe that canals filled with silver points should be refilled with gutta-percha before the construction of posts.

Luks¹ questioned whether silver points produce "hermetic" seals, even though Auslander³ inferred that this may be done by a "cork in bottle" effect. However, I have found in my practice that silver points can adequately help to preserve teeth. Clinical cases indicate that silver points can be used satisfactorily in teeth that are to receive posts (Fig 1).

I find that properly inserted silver points do not remain loose in canals. In fact, a great deal of force is required for their removal. With the use of long-shank, contra-angle burs, magnifying lenses, and care, I have obtained a high success rate in the preparation of the post holes.

In my opinion, it is unlikely, also, that a gutta-percha filling produces a "hermetic" seal. If it is used without a sealant, "with an apically well fitted master cone and additional smaller gutta-percha points, voids will still be present because the cones will not stick together or adhere to the canal walls."⁴ If Langeland⁴ and Luks⁵ are cor-

rect and if gutta-percha is used with a sealant, the sealant will dissolve. If it is used with chloroform, on evaporation of the chloroform, a dimensional change may take place in the filling.⁵ Wollard and co-workers⁶ found that most root canal fillings do not completely obturate root canals and that none of the techniques that they used for inserting gutta-percha into the root canal was effective in obliterating the root canal space. There is other evidence that gutta-percha may not produce a good seal: its inability to produce a good seal from the oral environment between visits during root canal therapy, and when used as a temporary filling in operative dentistry.

Although it is unlikely that either gutta-percha or silver points produces "hermetic" seals, each is used with a high rate of success. I feel more comfortable with silver points for narrow canals, especially if they are long and curved, and find that gutta-percha is advantageous for use in most other canals. However, other disadvantages to the use of gutta-percha, even in wider canals, are that if a gutta-percha point goes beyond the apex surgery may be required for correction and the filling procedure with gutta-percha may produce a split root.

Although the profession is obsessed with the need for gutta-percha or silver points to effect "hermetic" seals, it may be overlooking the possibility that this is not the role of the root canal filling. A "hermetic" seal, and perhaps the root canal filling, may not be the crux of, or even essential for, successful root canal therapy.

First, it is unlikely that a "hermetic" seal can be produced in practice.

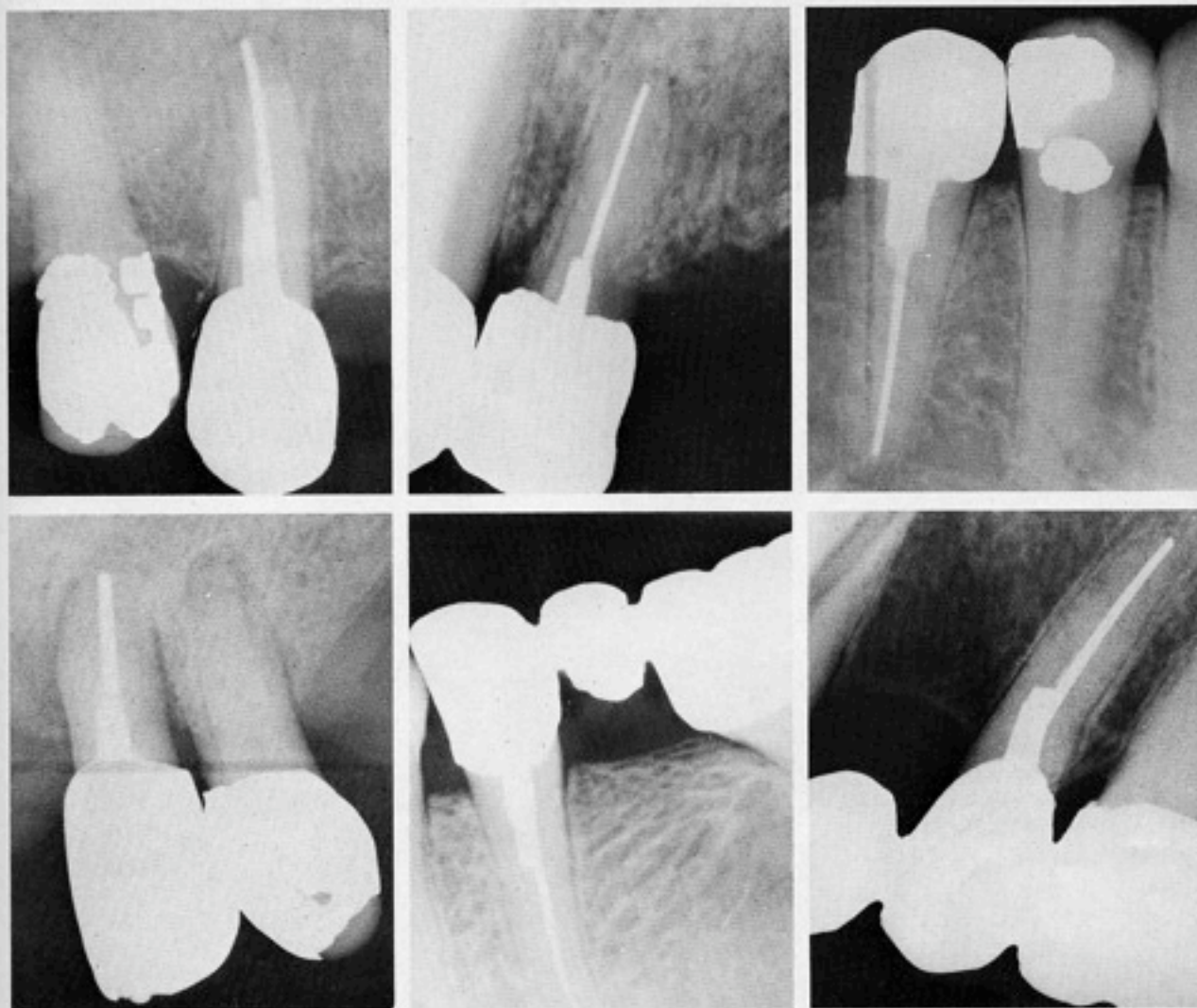


Fig 1 ■ Radiographs showing that silver points can be used satisfactorily in teeth that are to receive posts.

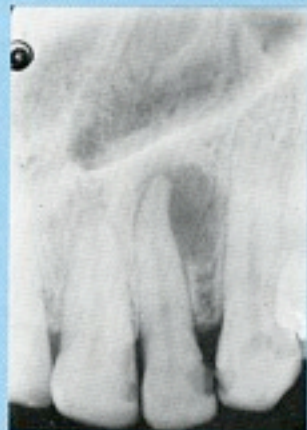Second, success or failure attributed to the quality of the root canal fillings may be the result of other factors. Some may attribute a treatment failure to a poorly placed root canal filling and suggest that success would result on re-treatment with a properly placed filling. However, the lack of success of the filling may be an indication that poor technique may have been used throughout the entire procedure and that that resulted in the failure; the success of a filling may be an indication of proper technique throughout the entire procedure. I have successfully re-treated cases involving radiolucent periapical areas that persisted long after canals were first obturated, by removal of the old root canal filling and by debridement and sterilization with camphorated monochlorophenol or Formocresol alone; the areas disappeared before the canals were refilled. It is common to attribute treatment failure to improperly placed root canal fillings, but the failure may be a result of improper debridement or im-

proper sterilization and aseptic techniques. I have observed instances of incompletely filled canals in retained, healthy teeth, for which treatment involved good debridement, good asepsis, and the attainment of a dry canal. On the other hand, periapical surgery has been required for teeth in which the canals were apparently filled with a great deal of precision. How often do accessory and lateral canals remain unfilled in teeth that have been successfully treated?

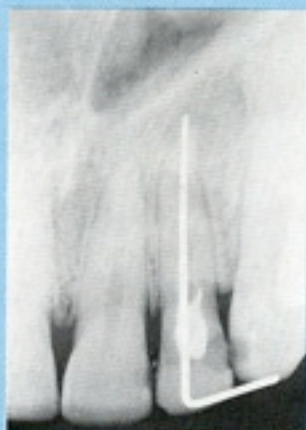Third, my evidence suggests that tissue fluids may not enter canals that have been properly debrided, sterilized, and dried. Naidorf⁷ said that "improper obturation will permit tissue fluids to enter dead spaces in canals which can subsequently become infected" either by oral organisms or hematogenously after transient hyperemias. According to Luks,⁸ "the sole purpose in filling a root canal is to prevent the ingress of tissue fluids." However, in the seven cases (Fig 2), some of the canals remained unfilled for a year or

Fig 2 • For each of the seven cases, the radiographs on the left show the periapical area before treatment; the center radiographs show healing that has taken place before filling of the canal; and the radiographs on the right show the healing of the area at the time the canal was filled or shortly thereafter.

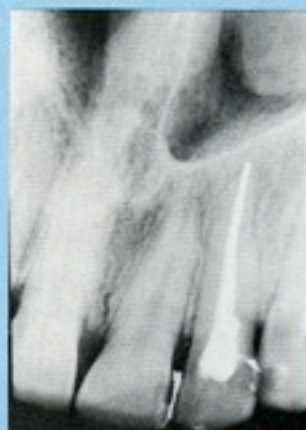Case no. 1



February 1960

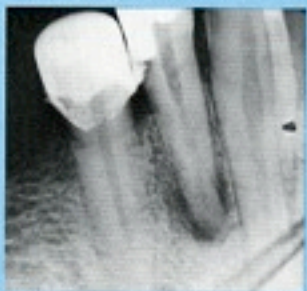

January 1961

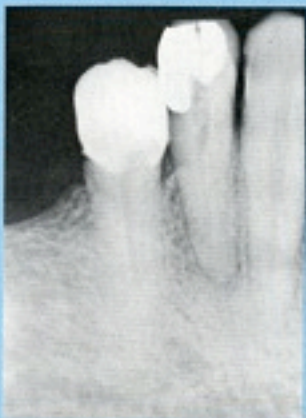

March 1961

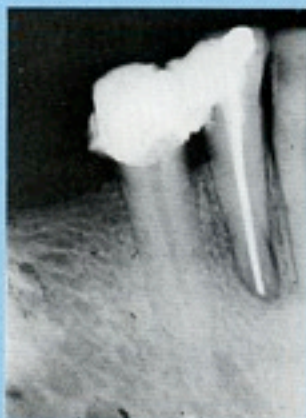Case no. 2



June 1954

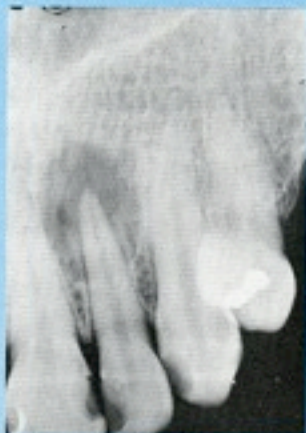

March 1955

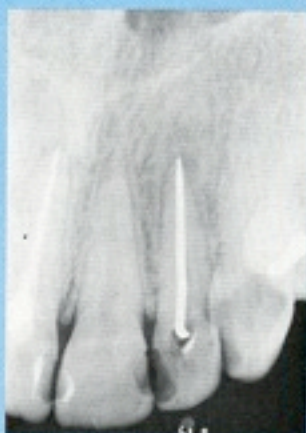

October 1955

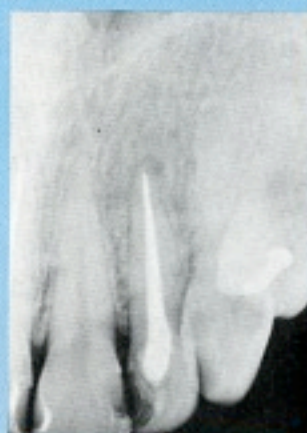Case no. 3



June 1957

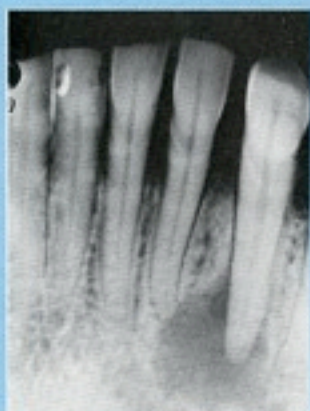

September 1958

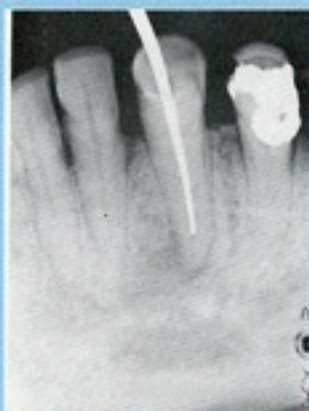

June 1959

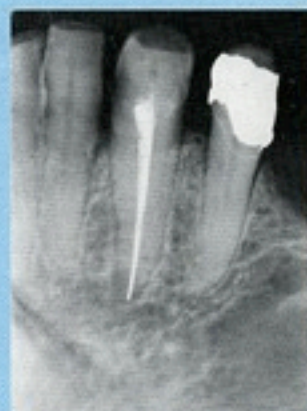Case no. 4



July 1958

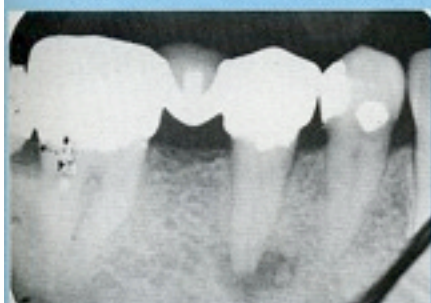

October 1958

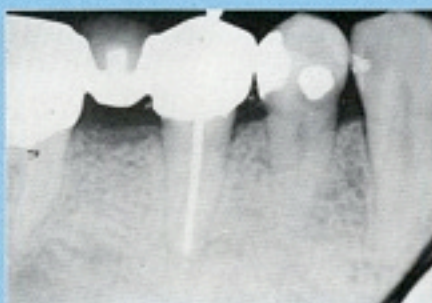


June 1959

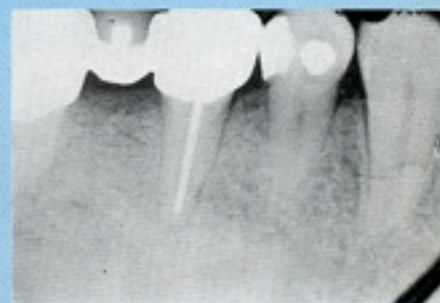
Case no. 5



July 1964

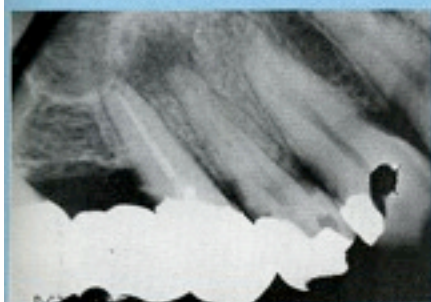


November 1964

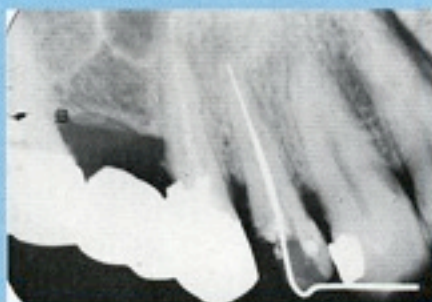


January 1965

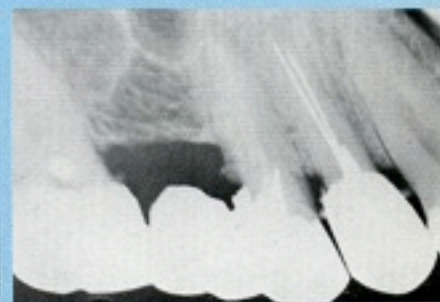
Case no. 6



January 1965

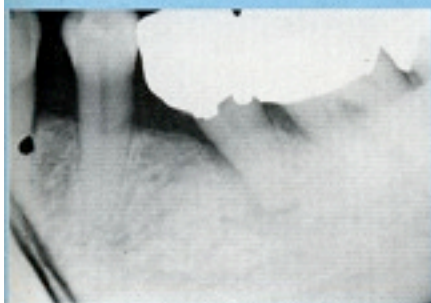


June 1965

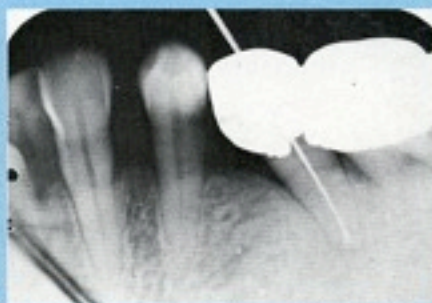

July 1965

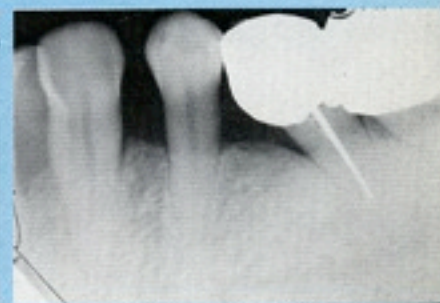Case no. 7



January 1966



November 1966



January 1967

longer, and paper points inserted into the canals were removed dry. Although this is a subjective finding, it suggests the possibility that tissue fluids may not have entered the canals after healing had occurred.

Fourth, the seven cases show that root canal fillings are not necessary for healing (Fig 2). The teeth that had radiolucent periapical areas were treated by debridement and with germicidal dressings of camphorated monochlorophenol or Formocresol; good seals were maintained between visits; and the areas filled in with bone even though root canal fillings were not placed until healing occurred. The results with this procedure are consistent and repeatable, and I have found the success rate to be high.⁹ The validity of the procedure was confirmed by G. D. C. Kennedy and M. S. Simpson at the University of Glasgow dental school in information they sent me.

Conclusion

Both gutta-percha and silver points can be used as root canal fillings with a high success rate although it is unlikely that either produces a "hermetic" seal. In the cases cited here, the canals remained dry even though they were not obturated for a considerable length of time (in one in-

stance, for two years); this indicates that tissue fluids did not accumulate in the canals. Moreover, my findings indicate that root canal fillings are not necessary for healing. These observations indicate the need for investigation of the validity of the current concept of the role of the root canal filling in treatment.

Radiographs in Figure 2 (case 1 right, case 3 left, case 3 right, and case 4 right) reproduced with permission from the *New York State Dental Journal*.

Dr. Dubrow's address is 1815 Cornaga Ave. Far Rockaway, NY 11691.

1. Luks, S. *Practical endodontics*. Philadelphia, J. B. Lippincott Co., 1974, p 118.
2. Cathey, G.M. Molar endodontics. *Dent Clin North Am* 18:345 April 1974.
3. Auslander, W.P. "Guttapercha" the sacred cow? *NY State Dent J* 40:533 Nov 1974.
4. Langeland, K. Root canal sealants and pastes. *Dent Clin North Am* 18:309 April 1974.
5. Luks, S. *Practical endodontics*. Philadelphia, J. B. Lippincott Co., 1974, p 105.
6. Wollard, R.R., and others. Scanning electron microscope examination of root canal filling materials. *J Endodont* 2:98 April 1976.
7. Naidorf, T.J. Clinical microbiology in endodontics. *Dent Clin North Am* 18:329 April 1974.
8. Luks, S. *Practical endodontics*. Philadelphia, J. B. Lippincott Co., 1974, p 104.
9. Dubrow, H. A method of treating nonvital teeth with radiolucent periapical areas. *NY State Dent J* 30:155 April 1964.