

---

## REVIEW

---

# Soft Tissue Management in Endodontic Surgery

Peter Velvart, DMD, and Christine I. Peters, DMD

**Modern endodontic surgery involves both root-end preparation and proper sealing of all apical portals of exit. Both components are requirements for mechanical and biological success, but the management of soft tissues becomes increasingly important for an esthetically successful treatment. A healthy appearance of soft tissues plays an important role in the esthetic outcome of periradicular surgery. This is true considering maintenance of attachment levels and regarding the amount of possible recession after surgical procedures. Complete, recession-free and predictable healing of gingival tissue is one important goal of endodontic surgical treatment. A critical review of currently used techniques based on clinical and scientific data reveals great potential for improvements. Possible reasons for scar formation and recession specifically in healthy periodontal conditions requiring surgical endodontic intervention are highlighted. Based on anatomical considerations various incision types are evaluated and recommendations made. Clear understanding of wound closure and tissue-healing patterns call for the use of atraumatic procedures, nonirritating suture materials and adequate suturing techniques. This article gives an overview and guidance for integrating current and new successful flap designs and wound closure methods. The methods described have the intention of maintaining the attachment level and avoiding postoperative recession after surgical endodontic therapy.**

Endodontic failures that do not respond to conventional root canal retreatment require surgical treatment (1, 2). The prime objective of surgical treatment is the same as in conventional root canal therapy, which is to provide conditions such that healing and repair of the periradicular tissue can take place. These conditions include removal of necrotic tissue and tissue breakdown products from the apical part of the root canal system, elimination of bacterial or-

ganisms persisting in the root canal system and removing the root tip. A fluid-tight seal of the apical part of the root canal with a material that is biologically compatible is created (3). Several studies have identified factors that influence the prognosis of endodontic surgery (4–11). According to Friedman (12) they can be divided into preoperative-, operative-, and postoperative factors. Success rates vary between 25% and 98% depending on the study (13, 14). The assessment of success and failure after endodontic surgery is mostly based on clinical and radiographic criteria of healing of the periradicular tissues (15, 16). In the literature, the contributing factor of present periodontal conditions in relation to the postoperative success of apical surgery has not been considered extensively. In a study by Jansson and coworkers (17), a persisting endodontic infection has been shown to be a contributing risk factor for progressing marginal attachment loss after periradicular surgery. In the long-term perspective, periodontal healing in teeth with root canal infection, evident as periradicular radiolucency, may result in retarded or impaired healing after periodontal therapy (18). On the other hand, before endodontic surgery is undertaken, the periodontium should be treated in cases where periodontitis is present (4, 12, 17, 19–21).

The ultimate goal in modern dentistry, after pathologic processes have been eradicated, is to achieve “white” and “pink” esthetics in obviously visible areas (22). “White esthetics” refers to the natural dentition or tooth-colored restoration of dental hard tissues with suitable materials. This notion has reached a very high level of importance (23). “Pink esthetics” refers to the surrounding soft tissues and ultimately the underlying bone, which are equally important for an esthetic result. Treatment of these tissues with adequate surgical and reconstructive techniques and maintenance of the results are a challenge in modern esthetic dentistry and the primary objective of preservation of the dentition is no longer acceptable without consideration of esthetic consequences (24). For many years, periodontal surgery has been associated with creating esthetic problems, but it should be understood that periodontal disease itself is disfiguring and that great care must be exercised during surgery to minimize the unaesthetic impact of therapy. The term “periodontal plastic surgery,” first suggested by Miller (25), was defined in a consensus report as surgical procedures performed to prevent or correct anatomical, development, traumatic or plaque disease-induced defects of gingiva, alveolar mucosa, or bone (26, 27). Furthermore, periodontal microsurgery was introduced, which is defined as refinements in existing basic surgical techniques that are made possible by the use of the

surgical microscope and microsurgical instruments (28). Improvements in flap design and soft tissue manipulation are considered key elements in improving the outcomes of regenerative periodontal surgery. Improved visual perception and better soft tissue handling hold great promise to further improve predictability of periodontal treatment (29). The same basic microsurgical principles apply to endodontic surgical interventions (30, 31).

## ANATOMY

Gingival tissue comprises epithelial and connective tissue, the latter consisting to about 55 to 60% of supragingival fibers, which attach gingiva to teeth and provide the basis for its firmness and biomechanical resistance during mastication (32). The gingival tissue reaches from papilla to mucogingival junction where it joins the alveolar mucosa and attaches to teeth and to the alveolar process (22, 32). The height of the gingiva from the mucogingival junction to the gingival margin is highest on the labial aspect of maxillary incisors (33). The gingival tissue between two adjacent teeth, the papilla, was considered roughly pyramidal and triangular in shape (34). The embrasure contour and the anatomy of its adjacent teeth determine the shape of a papilla (32, 35–37). The papilla has a lingual and a buccal peak, joined by a concave col (22, 35, 36, 38). It contains both nonkeratinized sulcular and col epithelium as well as keratinized oral epithelium (32, 35, 36). The col area consists of squamous stratified nonkeratinized epithelium. In mesio-distal direction, the midsection of the col slopes towards each tooth. On these slopes, the epithelium gradually changes its appearance toward the characteristics of the epithelial cuff (epithelial attachment). The width of the col between the buccal and lingual papilla and the depth of concavity in the col area increases gradually from the anterior to the posterior teeth (36).

The presence or absence of the interdental papilla depends upon the distance between the contact point and the crest of bone (37). When the distance from the contact point to the bone was 5 mm or less, the papilla was present almost 100% of the time. With a distance of 6 mm, the papilla was present 56% of the time, and when the distance measured 7 mm or more, the papilla was present 27% of the time or less. Holmes (38) excised interdental papillae in sixteen dental students, one from the anterior and one from the posterior area of each student. From 32 specimens, 22 papillae did not regenerate to their original shape and height. The regenerated papillae appeared flatter, did not fill the embrasure as completely as before excision and the cols were less concave.

An important anatomical consideration during endodontic surgery is the course of blood vessels supplying alveolar mucosa and gingiva. Four interconnected pathways of blood supply exist: The subepithelial capillaries of the gingiva and alveolar mucosa, the vascular network within the periosteum, the intraseptal arteries in the bone marrow and the plexus of the periodontium. The periosteal and the periodontal plexus communicate directly via Volkmann's canals without participation of the vessels of the bone marrow, thus unified histological responses to surgical wounding are observed (39) (Fig. 1). The gingiva and periosteum are blood-supplied mainly through suprapariosteal vessels, which run roughly parallel to the teeth's long axis, branch and subdivide in the lamina propria of the gingiva and form the vascular network on the periosteum (39–41). To a lesser degree, rami perforantes of the intraseptal arteries penetrating the interdental bone and the periodontal ligament vessels supply the gingiva with blood, the vessels finally ending in loops in the tips of the connective tissue papillae,

termed the gingival plexus (22, 31, 32, 42–44). The multiple interconnections between different plexus through numerous anastomoses and collateral pathways of circulation establish adequate blood supply, if single vessels are severed surgically (39–41, 43, 44). Mörmann and Ciancio (45) studied the effect of various types of surgical procedures on the gingival capillary blood circulation by means of fluorescein angiography. The circulation changes observed suggested that flaps receive their major blood supply from their apical aspect, but interestingly not exclusively. Short and long full thickness flaps in clinically healthy gingiva revealed that, functionally, orientation of blood supply was mainly from the vestibule to the gingival margin (Fig. 2). On the other hand, internal beveled incisions severed the anastomosis between gingival and periodontal vasculature and between gingival and interdental vasculature. Angiographically, separations from either vas-

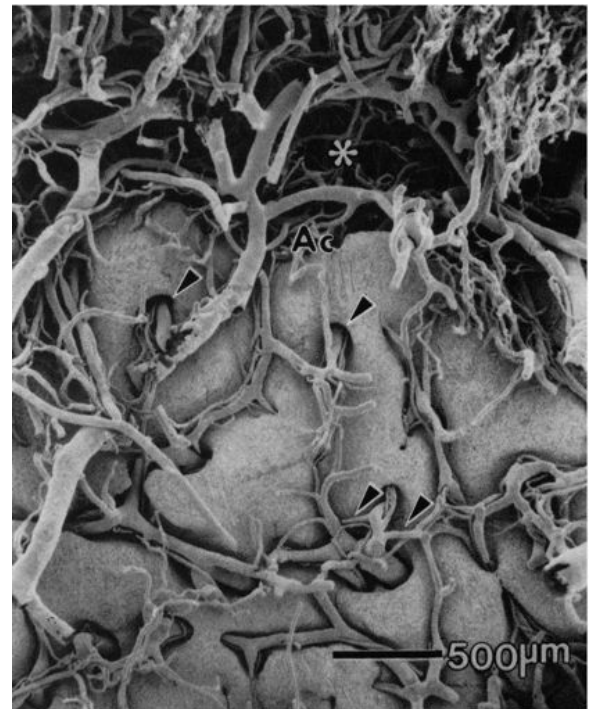

FIG 1. Collateral circulation through blood vessels communicating between the periodontal plexus and the periosteal plexus. Reprinted with permission from (39).

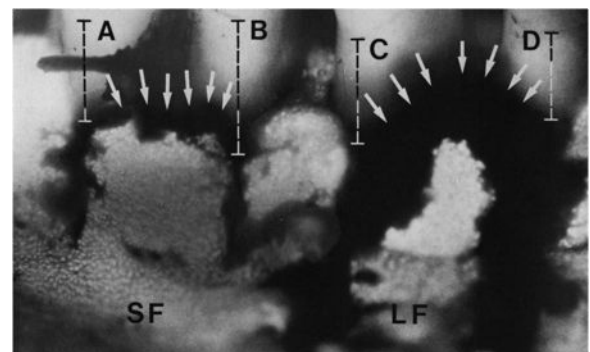


FIG 2. Difference in circulation disturbance in a short full thickness flap (SF) versus a long full thickness flap (LF) as shown by fluorescein angiography. (A–D) Indicated the distances from the cemento-enamel junction. Reprinted with permission from (45).

culature showed no effect on blood circulation within free and alveolar gingiva. When flaps were raised the greater the ratio of flap length to base, the greater was the amount of circulatory disturbance. Flap perfusion was maintained up to the point, where the ratio of length to width of the parallel pedicle flap equaled 2:1.

### ACCESSING THE APICAL PATHOLOGY

The outcome of any surgical procedure depends among other factors upon the extent to which an adequate access is possible. Endodontic surgery first requires exposure of the bone overlaying the tip of the root(s) and then revealing the root end(s) *per se* (Fig. 3). To access the bone, a full thickness flap must be raised. This comprises a soft tissue flap, which consists of gingival and mucosal tissue as well as periosteum. To mobilize the flap various modes of incisions can be selected including horizontal incisions, sulcular and submarginal, and vertical releasing incisions. The flap can be in its entirety a full thickness flap or a combination of a full and a split thickness flap.

Certain basic principles must be considered before deciding on the type of incision and flap design: Firstly, regional anatomical structures such as the location and the path of the blood vessels and nerves should be evaluated, protected and preserved during the surgical procedure. Recognition of the position of the root within the mandible or the maxilla, its inclination and thickness of the bone between the surface and root structure is important. Furthermore, periodontal conditions play an essential role in the decision making process. Probing depth, attachment loss, recessions and signs of periodontal inflammation in terms of bleeding on probing should be evaluated presurgically. The width of the attached gingiva and the location of the mucogingival junction are measured. In addition, presence, type and quality of restorations in special reference to the position of the restoration margin to the gingiva need to be determined and are critical to the esthetic outcome. Moreover, an evaluation of the size and position of the expected periradicular pathology in relation to the root, neurovascular structures and the sinus has to take place, including assessment of the local blood supply to the soft tissues in and around the designated flap area. Clear understanding of the reaction pattern of the tissues involved and the healing principles after the wound closure are important.

Quality assurance of endodontic therapy is an important issue (46) and microsurgical techniques have been applied in endodontic surgery for several years. They have even become a standard in postgraduate education in endodontics (47). Many endodontic surgical failures have been directed to poor visibility and ability to diagnose and treat the minute causes of apical pathology (30). The microsurgical approach has been purported to improve the prognosis of surgical treatment outcome (48).

In a series of studies our group has investigated soft tissue healing results after microsurgical endodontic treatment. We assumed that microsurgical treatment would be beneficiary to soft tissue healing. Based on and in analogy to the periodontal literature, microsurgical treatment should allow manipulation of the tissues in a more delicate and less traumatic way when compared to macrosurgery as it is used up to this point in time (49). The question was whether improved healing was achievable, when microsurgical instruments and techniques were applied. Three areas of interest have been identified as esthetically relevant: The interdental papilla, the cervical marginal area and the attached gingival and mucosa. Specifically the shape, dimensions, surface

texture, recession, scar formation, and attachment level were studied.

### FLAP DESIGN

Various flap designs have been discussed in the literature (3, 13, 50, 51). Examples include marginal mucoperiosteal flaps with one (triangular flap) or two (trapezoidal or rectangular flap) releasing vertical incisions, submarginal mucoperiosteal flaps with the horizontal incision within the attached gingiva and its modifications and semilunar flaps.

The wide variety of flap designs reflects the number of variables to be considered before choosing an appropriate flap. As conditions vary with each individual patient and specific situation, there will always be a need to select the best flap design for every single case. The literature is replete with basic rules and recommendations (52). A brief discussion will review the pros and cons of the classic flaps.

#### Triangular Flap

This type of surgical flap comprises a horizontal incision extending at least one tooth mesially and distally to the involved area combined with one releasing vertical incision forms a triangular flap (Fig. 4). Usually, the releasing incision is performed on the mesial part of the flap. This flap-technique exposes mostly marginal areas of the tooth in question and does not create enough access to the apical region. The triangular flap is mainly indicated

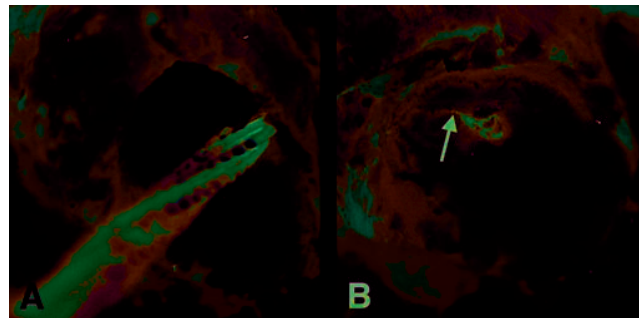


FIG 3. (A) Root end resection on an upper lateral incisor. (B) Resected root end with exposed obturation material and a lateral canal (arrow).

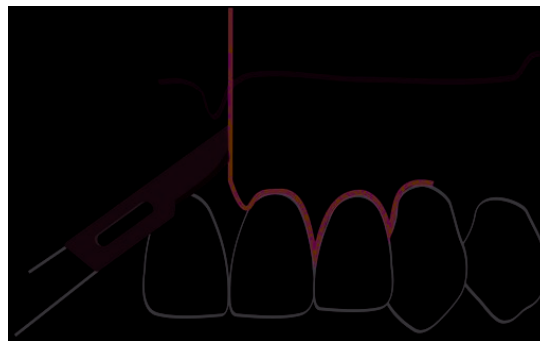


FIG 4. A triangular flap is formed by a mesial vertical and sulcular incision extending to at least two teeth distal from the releasing incision. Reprinted with permission from (3).

for correction of problems in the cervical and mid-root portions, such as in cases with cervical root resorptions, perforations and in resections of very short roots. The main advantages of this flap design are minimal disruption of the blood supply to the mobilized tissues and easy repositioning of the wound edges. As in all intrasulcular horizontal incisions, recession may result after the healing process.

### Rectangular and Trapezoidal Flap

Rectangular and trapezoidal flaps are an extension of the triangular flap with a second vertical releasing incision (Fig. 5). Rectangular flaps are the most frequently used flaps in endodontic surgery (3). Both flaps provide excellent access to the apical area. If required, releasing incision may be extended in apical direction for tension-free retraction. The difference between the rectangular and the trapezoidal flap is the degree of divergence of the releasing incisions. As the blood vessels run mostly parallel to the long axis of the teeth from the apical to the coronal direction, one consideration is to disrupt the least number of vascular structures. A vertical incision parallel to the path of the vessels would best comply with the above statement, thus favoring the rectangular flap (43, 53). Survival and blood supply of mobilized tissue appeared to be best, when the basis was broader than the proximal end of the flap. On the other hand, blood supply to the unreflected

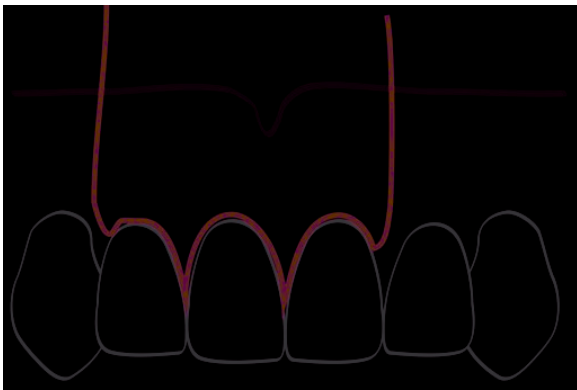


FIG 5. A rectangular flap comprising two releasing incisions connected by a sulcular horizontal incision. Reprinted with permission from (3).

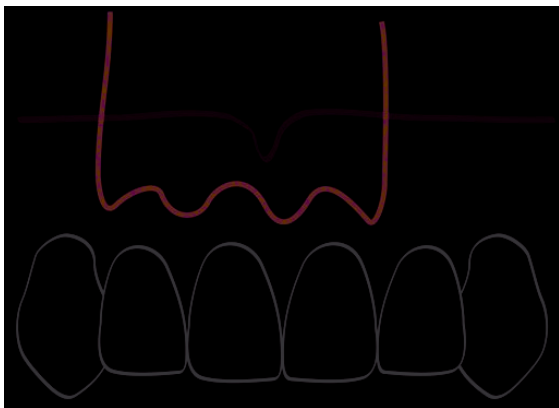


FIG 6. A submarginal incision formed by a scalloped horizontal incision within the attached gingiva and two releasing vertical incisions. Reprinted with permission from (3).

tissues was compromised by this approach (43). The longer the flap length the more important is the ratio between the length and width of the flap (54). Several authors advocate a length-width ratio of 2:1 (45, 55). The length-width ratio requirement usually favors a slightly trapezoidal shape of the flap, or extending the flap one tooth further mesially or distally. In all instances, converging releasing incisions must be avoided.

Repositioning and wound closure is easy in trapezoidal and rectangular flaps. In esthetically critical areas with prosthetic restorations involving subgingivally placed crown margins, a postoperative sequel can result in recession, leading to esthetically compromising exposure of the crown margins.

### Submarginal Flap

The most popular submarginal flap is the flap design by Ochsenbein and Luebke (56). Two releasing vertical incisions are connected by a scalloped horizontal incision (Fig. 6). The submarginal flap is only to be used, when there is a broad zone of attached gingiva with a minimum of 2 mm (57). In addition, the underlying apical lesion or surgical bony access must not extend to the flap margins. This flap design has the advantage of leaving the marginal gingiva untouched and it does not expose any restoration margins. As crestal bone is not denuded, the risk of attachment loss is minimized. In rare situations, because of insufficient treatment planning and poor surgical technique, necrosis of the unreflected tissue might occur because of deprivation of blood supply to this area. The recession resulting from such tissue breakdown can have devastating effects on the esthetic outcome of surgical treatment. Possible scar tissue formation is another disadvantage of the submarginal flap.

Vreeland and Tidwell modified the submarginal incision (50) by placing a scalloped horizontal incision 1 to 2 mm below the gingival margin. An inverse-bevel incision splits the tissue until 1 to 2 mm below the crest of bone, from which point on a full thickness flap is reflected. After closure, the flap should cover the area of unreflected split thickness tissue. The authors claim that less exact replacement of the flap is required when using this approach. The type of incision described bears a high risk of postoperative necrosis, as the only blood supply to the unreflected marginal tissue is derived from the periodontal ligament (39, 45). In addition, when 4/0 sutures are used, this critical area is further traumatized. Although the authors claim that scarring is "not much of a problem" the clinical pictures in the publication clearly demonstrate marked scar tissue formation, typical for submarginal incisions (50).

### Semilunar Flap

Placing either a straight or a curved horizontal incision in the alveolar mucosa that extends all the way to the bone creates a semilunar flap. The only advantage of this flap design is the fact that the marginal tissue remains untouched and thus no recession will occur. On the other hand, many disadvantages accompany its use. A semilunar flap will provide only limited access to the surgical area. Additionally, placement of the incision over the bony defect means that the wound cannot be closed over sound bone structure. Furthermore, the content of elastic fibers and muscle attachments of alveolar mucosa is high, both of which exert pulling forces on the reapproximated surgical wound margins. Not only is

suturing difficult, but constant tension will be present on the flap, resulting in poor alignment of wound edges, gap formation, and insufficient healing. Dehiscence in the incision line will result in secondary healing and scar formation. Moreover, placement of a curved, horizontal incision will sever a maximum of blood vessels. Because of the many drawbacks mentioned a semilunar flap design is no longer recommended (52).

### SURGICAL SITE CLOSURE

After irrigation with saline solution to remove debris, the wound edges are reapproximated carefully to allow primary intention healing (52).

Compression of the repositioned flap with a saline-moistened piece of gauze is necessary to create a thin fibrin layer between flapped tissue and cortical bone (53, 58, 59). Replacement of a thin blood clot with parallel fibrin fibers by new fibrous tissue results in collagen adhesion (58).

### SUTURES: TECHNIQUES AND MATERIALS

Sutures are needed to hold the reapproximated flap in place and to allow healing of the wound by primary intention (49). Accidental premature loss of sutures leads to delayed healing by secondary intention (60). Bacterial colonization is an important factor leading to tissue reactions to intraoral sutures (61–65).

#### Materials

When comparing histological tissue response of different suture materials, monofilament sutures (e.g. nylon, gut, steel, and chromic gut) produced smaller inflammatory reaction than multifilament materials (e.g. silk, siliconized silk, polyester, teflonized polyester, cotton, or linen) (61–64). Systemic antibiotics did not alter these reactions (62). While some materials are no longer recommended today, fact remains that bacteria invade suture tracks; this phenomenon is most predominant with multifilament materials with wicking action (61, 66). Accordingly, nonabsorbable silk sutures are easy to tie and handle but are no longer recommended as they accumulate plaque, allow rapid bacterial colonization and are uncomfortable to remove because of ingrowth of tissue (66, 67). However, some multifilament suture materials seem to inhibit bacterial transmission (65).

Polyglactin (e.g. Vicryl) sutures are colonized more slowly than silk and offer the advantage of being absorbable (31). Surgical gut, polyglactin 910, polyglecaprone, and polidioxanone are absorbable materials recommended for periodontal surgery (49). Polyglactin 910 (coated Vicryl) is absorbed in 7 to 10 days, has shown very little inflammatory reaction, that subsided after 3 days (in comparison to reactions to polypropylene, silk, or catgut) and good results with respect to wound infection in skin wounds (68, 69). In general, monofilament synthetic sutures are least traumatic, allow less bacterial migration and are the materials of choice (66). Nylon sutures, e.g. Gore-Tex monofilament sutures or other synthetic monofilament suture elicited a mild inflammatory tissue response (66). A polytetrafluoroethylene (PTFE) impregnated monofilament suture has good handling characteristics and less bacterial colonization (31, 66, 70). If a multilayered flap is used, absorbable suture materials (e.g. polyglecaprone, polyglactin) are used for inner layers only and nonabsorbable materials (e.g. polypropylene) for

outer layers and whenever else possible, to minimize inflammation during the healing process (28, 69).

Microsuturing makes use of fine needles and suture materials. Round-bodied needles (5/8-circular, 1/2-circular, 3/8-circular) are used for soft tissues, such as mucosa, but each situation may require different needle sizes (Fig. 13) (31). Most needles used in dentistry are 3/8 curvature needles but ophthalmic spatula needles with 140 degrees curvatures are also recommended (49).

To avoid necrosis of papillae by inserting too much suture material, # 6–0 to # 8–0 suture sizes are recommended in microsurgical techniques, and are mandatory for layered suturing (22, 28, 49). Other authors recommend nonabsorbable monofilament 5-0 sutures (21). Sutures should not act as ligatures and tension created by sutures should be minimal (45). Tension can be reduced by using a greater number of sutures and by choosing fine microsurgical materials (28).

#### Techniques

Postoperative gingival recession is a difficult therapeutic dilemma that can be a sequel of conventional flap and suturing techniques (71). Esthetically disappointing results are a major concern both for the clinician and the patient involved. Suture materials can cause inflammation and foreign body reactions (66, 72). Some authors recommend using only the minimal amount of sutures necessary to secure the flap as both the suture and the knot itself cause inflammation and delay wound healing (52).

The techniques employed include interrupted sutures, anchor sutures, continuous sling sutures, and vertical mattress sutures (Fig. 7) (31, 73). While full flaps are best secured using vertical mattress sutures and anchor sutures, limited flaps are best retained using interrupted, fine-diameter sutures (74).

Avoiding any thinning of the papillae, even in cases of periodontitis and using internal (vertical) mattress sutures, supports the interdental papilla in a coronal direction, and results in less loss of papillary height (67). Partial thickness flaps in very thin tissue may not provide sufficient blood supply for flap survival (45). Minimal tension during reapproximation and after suturing is important to avoid impairment of circulation in a flap (45,

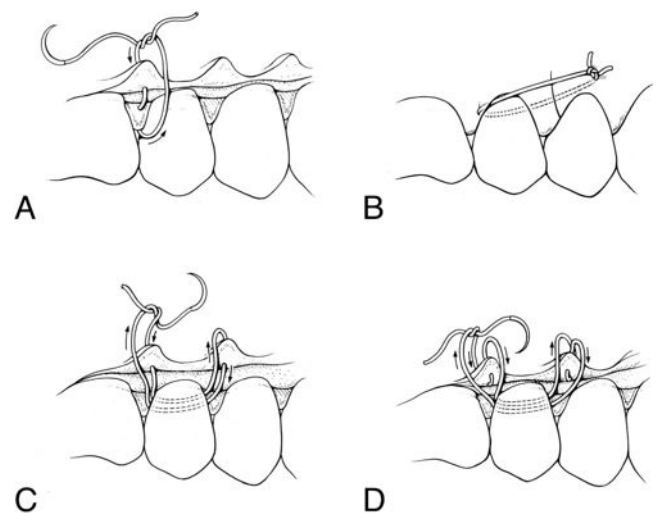


FIG 7. Examples of commonly employed suture techniques. (A) interrupted suture, (B) anchor suture, (C) sling suture, and (D) vertical mattress suture. Reprinted with permission from (102).

71). An example of a technique that takes advantage of suture pulling forces would be the ramp mattress suture, a horizontal mattress suture that pulls the buccal flap in coronal direction and the palatal flap in a more apical direction, resulting in a gingival slope or ramp to the palate (75).

### SUTURE REMOVAL

A perisutural epithelial sleeve develops at 3 days and can enrobe the entire suture track after 7 days (66). An intense inflammatory response to suture materials and the trauma of suture placement is visible after 3 days (66). As resealing of epithelium at the wound margin is evident within 2 days, suture removal can take place after 48 h but should take place no longer than 96 h after placement (53, 59, 74, 76).

### CRITICAL REVIEW OF SOFT TISSUE HEALING

The healing capacity of oral tissues is excellent. Only seldom are there serious postsurgical complications, such as tissue necrosis, nerve damage, profound bleeding, or serious infections. When general basic rules are followed, fair healing of the soft tissues can be expected. Recession is a frequent sequel to healing after periodontal surgery. Its extent and differences in terms of recession location have not been studied extensively. The goal of periodontal surgery is to alter, treat and heal diseased gingival tissues and crestal bone through a host of invasive measures, thereby removing selected areas that are not retainable (52, 77, 78). The healing behavior of tissues, where attachment has been lost, but that are healthy, has only been studied in recent years, with the development of periodontal plastic surgery. This treatment of healthy periodontal tissue mainly involved restoration of lost attachment and augmentation procedures (28, 79). The goal has increasingly shifted, towards restoration of the natural shape, position, color, and appearance of soft tissues as present before trauma, disease, or treatment induced changes of the tissues (27, 79).

When a lesion resulting of endodontic pathology develops on a specific tooth and needs surgical intervention, frequently marginal soft tissues may be healthy (53). With the aid of contemporary techniques such as magnification under a microscope, suitable materials and the use of microinstruments, endodontic surgery has evolved to microsurgery and will result in a predictably successful outcome in teeth treated (14, 21, 30, 48).

### Healing Process

Healing takes place in several phases that overlap and coexist: wounding, clotting and inflammation, epithelial healing, connective tissue healing, proliferation, maturation, and remodeling (53, 59, 78, 80). While a multitude of immune defense mechanisms exists, and the details of intercellular communication pathways and interdependent signaling processes during hemostasis and wound healing are beyond the scope of this article, the main events are described below. Within 24 h, polymorphonuclear leukocytes and macrophages start migrating into a blood clot. Stimulated macrophages play a central role in angiogenesis and new collagen synthesis (58, 76, 78, 80, 81). Inflammatory and reparative cells migrate along fibrin strands, followed by capillary buds. The microvascularization in the flap itself remains patent, providing nutrition for the mucogingival flap, in concert with contributions

from remaining periosteal, periodontal, and bone microvascular networks (60). Parallel fibrin strands after wound compression and a thin hiatus between wound edges accelerate this process (20, 59, 76). Epithelial streaming as a sheet or as fingers is observed after 2 days, eventually resulting in a multilayered seal (74, 82). After 4 days an epithelial barrier has formed (76). Other authors described complete epithelial healing in the sulcus at 14 days and after 28 days the wound healing process was accomplished (59, 60, 83). Healing and reattachment of an elevated flap to cortical bone is a slower procedure, the periosteum does not survive reflection (58). Granulation tissue replaces the thin fibrin clot between the flap and cortical bone after 4 days, and fibrous connective tissue replaces granulation tissue by 14 days (58). Because of early epithelial bridging, suture removal is therefore advocated after 2 to 3 days (76). Initial resistance to rupture forces is attributed to regeneration of epithelial attachment to tooth surfaces (20, 74, 82). Other authors do not recommend suture removal before 4 days, as stainable collagen content in granulation tissue, which determines tensile wound strength, is only present after 3 days (59). While healing wounds that are subject to small amounts of mechanical stress, demonstrate an increase in collagen strength and formation, excessive forces disrupt the neovasculature and collagen fibers and delay healing (80).

More and more variables of wound healing, including patient nutritional status, bacterial infection, wound care and available tissue oxygen, are being researched. Consequently, novel therapies are evolving, such as growth factor therapy (84). Growth factors may lead to new strategies in improvement of soft tissue healing, including skin, mucosa, and nerve tissues (85).

### Strategies and Procedures

The choice of flap designs should allow maintenance of optimal blood perfusion during surgery. This implies using a design where

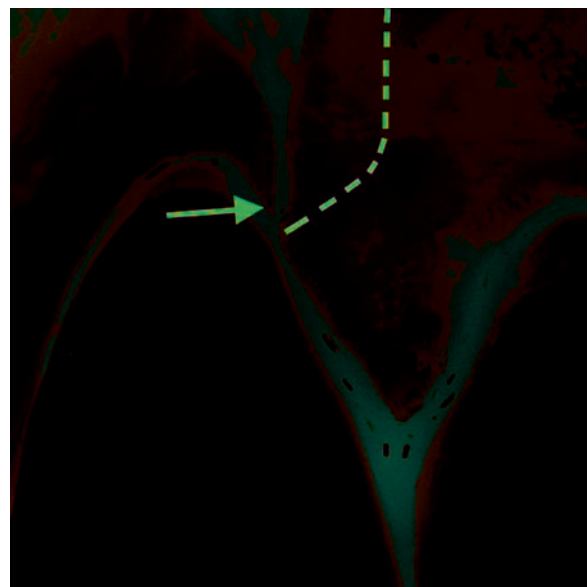


FIG 8. Vertical releasing incision that creates a compromised tissue area (arrow). The proximal, unreflected tissue portion will most probably necrotize because of insufficient blood supply. A dashed line indicates the desired incision course, beginning in a 90-degree angle to the gingival marginal.

vertical releasing incisions run vertical, parallel to the tooth axis and to suprapariosteal blood vessels in the mucosa and gingiva, resulting in minimal vascular disruption (30, 31, 43, 45, 53). Paramedian rather than mid-axial releasing incisions are recommended to minimize recession risks (Fig. 8) (43). Healing is influenced by flap shrinkage and the resulting difficult reapproximation with more sutures than usually necessary. This is true in particular for submarginal flap types. A vertically oriented releasing incision and secondary blood supply from the crestal bone to papillae and attached gingiva can avoid sloughing of unreflected tissue (43, 86). Unlike horizontal incisions further apically, an incision severing the anastomosis between gingival and periodontal vasculature as used in every full mucoperiosteal flap or sulcular flap showed no effect on the circulation in free and alveolar gingiva (45). Tissue trauma through stretching, distorting or tearing a flap can be avoided through appropriate magnification and careful manipulation with microsurgical instruments (72, 79).

After reflecting a mucogingival flap, scaling of root-attached tissues and tissue tags on cortical bone should be avoided to allow rapid reattachment and protection against bone resorption (31, 53, 58). Preservation of the papilla in the col area during elevation and reflection is another key point for healing by primary intention (76). Careful handling, undermining elevation and retraction using the groove technique are helpful to avoid unnecessary injuries to the reflected tissue (21, 30, 52). Keeping the flap moist at all times helps avoid shrinkage and dehydration (76).

#### Patient Related Factors

Both the type of tissue involved and the type of surgical wound determine the healing process (78). Patients with a "thick" tissue biotype tend to display coronal soft tissue regrowth to the former level in crown lengthening procedures, whereas patients with a thin tissue biotype do not (71, 87). Next to thickness and width of the gingival tissue, the integrity and thickness of underlying bone plays a role in mucogingival stability (79).

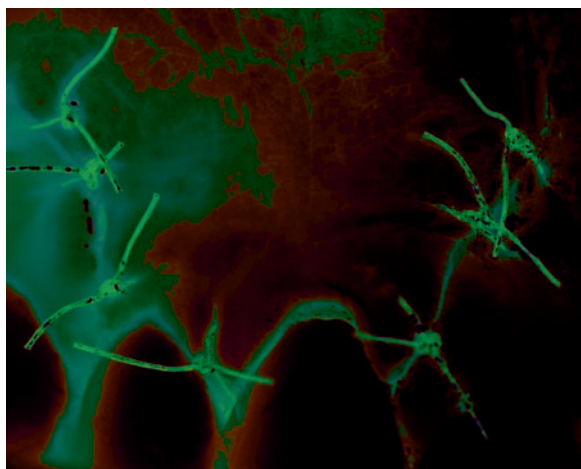


FIG 9. A trapezoidal flap secured with 4/0 sutures. Postoperative result using traditional macrosurgical techniques and instruments.

#### MACROSURGICAL VERSUS MICROSURGICAL OUTCOME

As stated before, healing results using a macrosurgical approach are generally regarded as fair. Figure 9 shows a representative result of flap closure using traditional techniques; in this case, a trapezoidal mucogingival flap was raised. Wound closure was accomplished using polyamide 4/0 single knot sutures. The vertical releasing incisions were closed with three sutures each and the papilla with a single knot suture. Wound margin adaptation was considered as sufficient at that time. The healing result after 1 wk postsurgically displayed acceptable healing without any complications and was described as good. Figure 10 shows the surgical site before and directly after suture removal. When the surgical area is examined more carefully and critically, following observations can be made: At 7 days, the vertical incision displays complete closure of the wound edges in the apical part. A discrete tissue indentation in the entire extent of the vertical incision is clearly distinguishable. This indentation becomes more pronounced at the marginal level and ends in a wound dehiscence, which is esthetically the most critical area. This comes as no surprise as at the time of conclusion of the surgery the wound edges in the marginal portion were not properly reapproximated. The healing process requires closure of the hiatus between the reflected and the unreflected tissue with connective tissue and epithelium (76). When adaptation of the tissue edges is ideal and the tissues are positioned in very close proximity in the vertical and horizontal dimension to each other, only few cells need to be generated to bridge the gap. Close adaptation will expedite wound closure, epithelial cells being the fastest (see section "Wound Healing"). Healing of the vertical incision (Fig. 10B) must be judged as by secondary intention, specifically in the marginal area, resulting in scar tissue formation and tissue defects. The area of the papilla seems to be well preserved during the surgical procedure and sutured at its proper position. However, the most coronal portion of the papilla has shrunk, resulting in a rounded papilla shape and loss of height.

In another case, a submarginal incision was performed using microsurgical techniques and instruments. Flap closure was per-

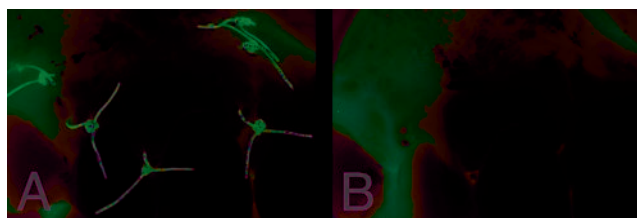


FIG 10. Same surgical site as in Fig. 9, 7 days postoperatively. The clinical situation is shown (A) before and (B) directly after suture removal. Wound dehiscence visible after suture removal.

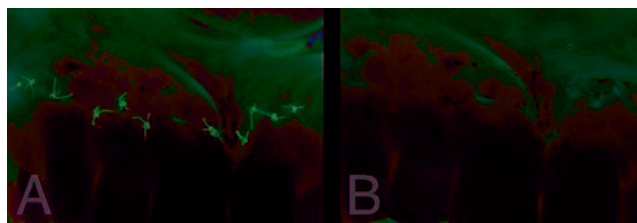


FIG 11. Situation of 6/0 sutures after 4 days (A) before and (B) after removal. The incision is faintly visible, perfectly healed as well as poorly healed areas and areas with fair healing are evident.

formed with polyamide 6/0 sutures. At suture removal after 4 days (Fig. 11) areas with better healing are visible and the incision is barely recognizable, just adjacent to a poorly healed portion with a tissue dehiscence and some areas with fair healing. In this clinical example, there are incision sections with perfect and poor healing results directly adjoining to each other. As the surgical technique was the same, and the same types of tissues were manipulated it must be assumed that the different healing patterns were a consequence of varying degrees of tissue adaptation after the suturing process. It is obvious in this example that there is potential for improved healing even after very short periods of time. Wound closure seems to be quite critical in terms of healing outcome. Considerable understanding has been generated from research in mucogingival surgery, specifically in recession coverage and soft tissue grafting procedures, as well as in general plastic surgery (22, 35, 36, 88).

It has been also pointed out, that if periodontal plastic surgery is performed, esthetic outcome is often the only important factor and function becomes secondary for example in recession coverage or papilla reconstruction (27). Incision design and suturing technique critically influence the postoperative wound healing process in terms of blood supply and flap survival (45). If both factors are not guaranteed, esthetic as well as functional success become unpredictable (28).

Among other principles (incision and flap design, atraumatic and gentle tissue management), a passive and tension-free wound closure is fundamental for proper wound healing and for a successful functional and esthetic outcome. In earlier days, the suturing process was solely regarded as bringing the wound edges together and keeping them in this position until body has healed the defect. It was customary to leave the sutures in place for 7 to 10 days and the clinical findings seemed to confirm this protocol. In an animal experiment the papilla suture was simulated with a

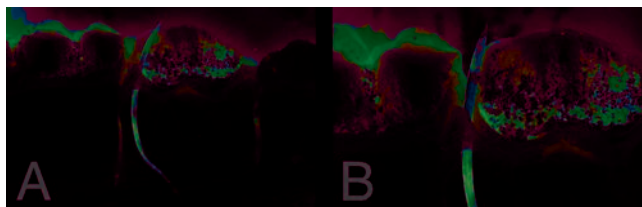


FIG 12. Animal model using 4/0 sutures (A) and the same area in 4 $\times$  magnification (B). Overly traumatic needle tract as needle penetrates through the papilla.

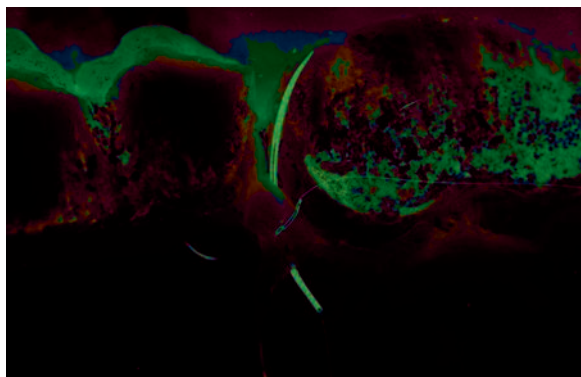


FIG 13. Same model as in Fig. 12, showing a 7/0 and 8/0 microsuture.

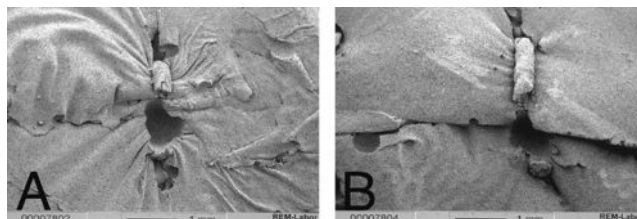


FIG 14. Scanning electron microphotographs in 30 $\times$  magnification. (A) Reveals tissue tension because of excessive suture pulling forces. (B) Displays a small vertical discrepancy in alignment of the tissues adjacent an area on the left, where both wound edges are positioned more closely.

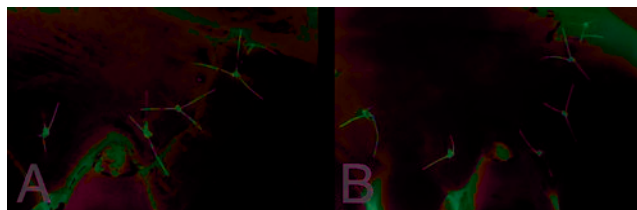


FIG 15. A microsutured surgical tissue area viewed directly postoperatively (A) and after 4 days just before suture removal (B). Close adaptation of the wound margins and atraumatic tissue handling allow superior healing patterns.

needle corresponding to a 4/0 suture (Fig. 12A). The same area was photographed with a magnification of 4 $\times$  (Fig. 12B). It is obvious that already the needle tract penetrating through the tissue almost dissects the papilla in half. This generates a large defect, which might compromise tissue survival. Changing the size of the suture material and accordingly the size of the needle as in microsuturing, it is evident in Fig. 13 that this is much less traumatic. In the same animal experiment excessive suture pulling forces on the two tissue parts resulted in crushing and further trauma to the wound. The scanning electron microphotograph (SEM, Fig. 14A) illustrates the amount of tissue damage inflicted. Note the highly wrinkled and squeezed tissue beneath the suture. If a suture is applied in such a traumatic way, the healing process will have to repair additional and considerable damage induced by both the size and excessive tightness of the suture. It is of no surprise that healing will take longer and will result in esthetically unpleasant healing patterns. Figure 14B (SEM) displays how even minute tissue misalignment of the wound edges may delay wound healing. In the center of the picture, there is a small vertical discrepancy in alignment of the tissues. This translates to a larger distance for the cells to cover, as compared to the area on the left, where both wound edges touch each other closely. In addition, note small wrinkles in the upper tissue portion, which led to tearing of the tissues at the point of the needle penetration. Perfect adaptation and atraumatic tissue handling will allow improved healing results (Fig. 15).

### Papilla Preservation/Protection

The interdental papilla, the portion of the gingiva between two adjacent teeth, is critical for functional, phonetic and esthetic reasons. Complete and predictable restoration of lost interdental papillae is one of the biggest challenges in periodontal reconstructive surgery (22). Therefore, it is imperative to maintain the integrity of the papilla during surgical procedures. Most frequently, a

sulcular full thickness flap is used in periradicular surgery. In this flap technique the buccal papilla is mobilized and becomes part of the flap (89). Ideally, the sulcular incision should dissect the buccal from the lingual papilla. In narrow interproximal spaces, complete mobilization of the papilla is often difficult and may cause tissue loss. Shrinkage of the papilla during the healing phase can occur, and may initiate the ultimate loss of papilla height. Zimmermann and coworkers (90), in a preliminary study, investigated the shrinkage of papillae after sulcular flaps in patients with healthy periodontal tissues. The reduction of papillary height increased gradually during healing. Immediately postoperatively papilla height loss because of surgical manipulation resulted in a recession ranging from 1 quarter ( $n = 14$ ) to one-quarter to one-half ( $n = 3$ ) of the original height. At suture removal, six sites had a loss of height of up to one-half the original position. None of the 17 sites remained at preoperative levels at any time.

A quantitative study analyzed recession of the interdental papilla in periodontally healthy situations after apical surgery using sulcular flap incisions (91). All experimental sites exhibited a significant loss of papilla height at 1 month ( $p < 0.003$ ) and 3 months ( $p < 0.004$ ). Main loss of papilla height occurred between baseline and the 1-month recall situation ( $-1.1 \pm 0.8$  mm), while a small but significant further loss occurred between the one and 3-month recall appointment ( $p < 0.05$ ,  $0.2 \pm 0.3$  mm). At 3 months retractions increased in 10 sites, while in three sites the loss had diminished compared to the value after 1 month. These results suggest that the conventional sulcular flap results in considerable retraction of papilla height after 1 month and 3 months postsurgically.

The issue of papilla preservation has been largely addressed in periodontal therapy. In anterior periodontal surgery, a papillary retention procedure is advocated to maintain papillary height to maximize postoperative esthetics (67, 92). Cortellini and coworkers (93, 94) suggested a modification of the papilla preservation technique, which allows primary closure of the interdental space over a bioabsorbable membrane. A horizontal incision is performed at the base of the papilla. The papilla is subsequently elevated to the buccal side. After coronal repositioning of the buccal flap over the membrane, the interproximal area is covered with the papilla, which is attached to the buccal flap. Primary closure over the membrane was obtained in all treated sites using the modified preservation technique. Probing attachment level gains and pocket depth reduction were observed after one year when using this technique.

In endodontic surgical access, Lubow et al. (51) suggested an alternative to classical full thickness flaps with the mobilization of the papilla. In the technique described, the flap involved full thickness dissection with easily recognizable landmarks and straight-line incisions. A beveled horizontal incision was designed to incorporate the maximum amount of facial keratinized tissue into the body of the flap, while leaving the interproximal tissue untouched. Healing was described as rapid and with excellent esthetic results.

Preservation of the papilla in periodontal therapy is an accepted procedure as described by several authors in the literature (29, 92, 95). Straight-line incisions during endodontic surgery, without mobilization or inclusion of the papilla into the buccal flap, lead to a clear indentation line where the incision was placed. Figure 16 represents a clinical example of such an incision. The same type of result is also visible in the publication by Lubow et al. (51). This result was described as esthetically excellent, while in today's critical and microscope-enhanced judgment it is no longer consid-

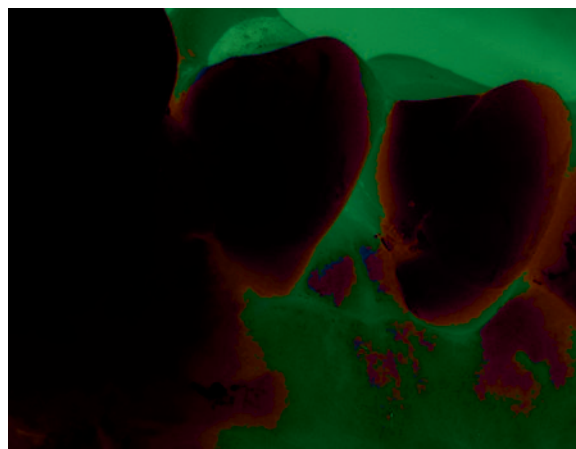


FIG 16. A single straight horizontal incision as seen in Fig. 17 (red line). A marked indentation line indicates an insufficient incision placement.




FIG 17. Schematic drawing with a red line representing a single straight incision directed to the crestal bone. The green line represents the papilla base incision with a shallow incision placed at the level of the lower third of the papilla in a slight curved line connecting one side of the papilla to the other. In a second step, the scalpel is placed to the base of the previously created incision inclined apically, almost parallel to the long axis of the tooth and directed towards the crestal bone margin.

ered as such. A further, nevertheless important factor is the location and microconfiguration of the flapped and unreflected tissue in vertical incisions. In the cross-sectional diagram (Fig. 17), the red line represents a paramarginal, single straight incision directed to the crestal bone. The pointed tissue ending will necrotize at its very end, creating a small, but visible defect and a recession. This type of incision is simple to perform, but will result in a poor healing result. It is evident in the drawing that the mobilized tissue has a sharp edge at the coronal end of the flap. The tissue margin comprises unsupported epithelial cells without the epithelial base cells, which are responsible for formation of a multilayered seal of epithelial cells. The connective tissue at the proximal end of the flap forms a sharp and thin edge, which is not sufficiently vascu-

larized for survival. The healing process will result in localized necrosis with a small tissue defect, visible as a clearly detectable indentation (Fig. 16).

Consequently, the incision line should begin in a 90-degree angle to the outer contour of the marginal gingiva as shown and marked with a green line in Fig. 17. This rule applies to any type of incision, to avoid thinning out of tissues and allowing sufficient blood supply to reach the area, promoting better healing.

The importance of proper incision and surgical technique in obtaining recession-free and esthetically improved healing was pointed out by a recent clinical study on the papilla base flap (96). A papilla base flap consists of two vertical releasing incisions, connected by a papilla base incision and an intrasulcular incision. The marginal incision commences by the preparation of the papilla base using a microsurgical blade. The size of the blade should not exceed 2.5 mm in width. Suitable shapes are blades with rounded end (BB 369, Aesculap, Tuttlingen, Germany) or standard 15C blades (Fig. 18). The crucial point is controlled movement of the scalpel blade within the small dimensions of the interproximal space.

The papilla base incision requires two different incisions at the base of the papilla. The first shallow incision separates epithelium on the surface of the gingiva and connective tissue up to a depth of 1.5 mm. The incision is placed at the level of the lower third of the papilla in a slightly curved line, connecting one side of the papilla to the other (Fig. 19). The incision begins and ends in a 90-degree angle to the tooth and gingiva (see lines in Fig. 17). This shallow incision prevents thinning of the coronal aspect of the flap.

In the second step, the scalpel is placed to the base of the previously created incision and subsequently inclined apically, almost parallel to the long axis of the tooth, directed towards the

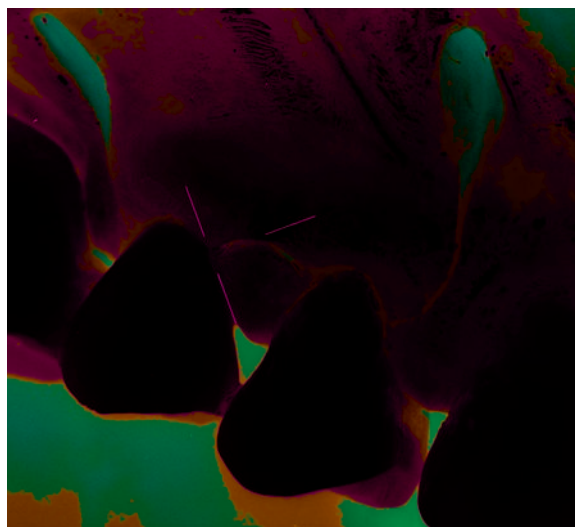


FIG 19. The line of incision horizontally connects one side of the papilla to the other in a curved line. Reprinted with permission from (96).

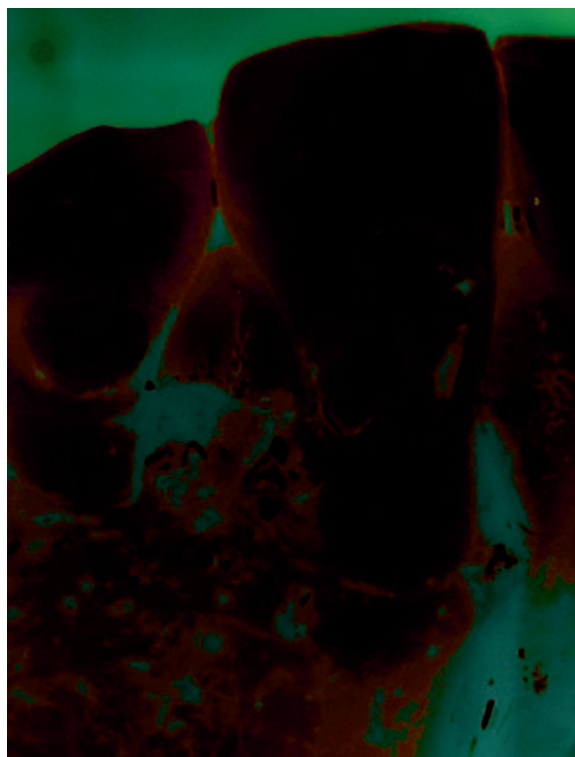


FIG 20. Reflected full thickness mucoperiosteal flap after a papilla base incision. Reprinted with permission from (96).




FIG 18. Comparison of different sizes of scalpel blades. Top is the regular blade size #15, middle blade represents the smaller #15C and bottom shows the microblade with double sided cutting edges.

crestal bone margin. With this second incision, a split thickness flap is prepared in the apical third of the base of the papilla. The incision terminates at crestal bone level, and separates the periosteum from the bone (Fig. 17). From this level on the preparation continues as a full thickness mucoperiosteal flap (Fig. 20).

While the papilla base incision (PBI) is challenging to perform, its use can lead to predictable results. Firstly, atraumatic handling of the soft tissues is mandatory to obtain good results. Secondly, two different incisions are needed for good healing and to avoid

excessive scar formation or an indentation at the site of the incision. The key point of the PBI is to avoid thinning of the split flap. The epithelium of the partial thickness portion of the flap needs support by underlying connective tissue, which has to be thick enough to maintain vitality through sufficient blood supply. If this goal cannot be obtained, the tissue will necrotize, resulting in a tissue defect, followed by scar formation. On the other hand, excessive thickness of the connective tissue layer of the split flap portion could compromise the survival of the unreflected buccal papilla. The ideal thickness of a partial thickness flap is unknown. Epithelium thickness varies between 111 to 619  $\mu\text{m}$  with a mean of 364  $\mu\text{m}$  (97). The recommended thickness of free gingival grafts was reported to be 1 to 2 mm (98, 99). Based on gingival graft studies a thickness of 1 to 1.5 mm was chosen for the split flap in PBI. The selected thickness resulted in excellent healing patterns.

As mentioned previously, flap closure using atraumatic and tension free sutures is a key factor to improved healing. The correct size of the needle and appropriate suture thickness are equally critical. Depending on the incision site, the following materials have been used: Vertical incisions should be sutured with 6/0 sutures, because of close proximity to inserting muscles in the mucosa, which might exert some tension to the wound during mastication and speech. As nylon monofilament materials are somewhat stiff in size 6/0, softer material, such as polyamide (Supramid®) was preferred. This material is a multifilament suture, with a coating providing monofilamentous appearance with a smooth surface.

For closure of the horizontal incision and the delicate area of the papillae, we recommend polypropylene interrupted sutures with a size of 7/0 or smaller (Fig. 21). As the wound edges should be perfectly adapted to each other, depending on the dimensions of the papilla two or three interrupted sutures are needed.

Suture removal performed after 3 to 5 days promoted rapid healing. The critical area for suture removal after 2 to 3 days is the apical portion of the vertical releasing incision—the mucosal wound, in particular in the region with muscle tension, which might require 24 to 48 h longer to initiate healing (59, 76, 78).

The evaluation of healing patterns of the papilla base incisions after 3 months revealed mainly completely undetectable or only partially detectable incision lines and generally demonstrated excellent healing. None of the operated sites displayed any measurable loss of papilla height, or other complications (96).

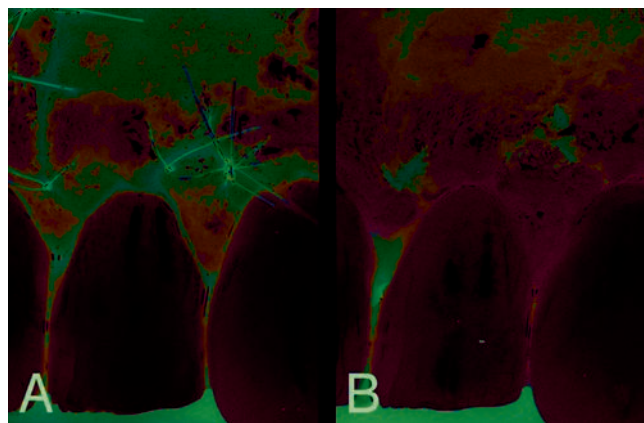


FIG 21. Size 7/0 polypropylene sutures. The clinical situation (A) at the conclusion of the surgery and (B) directly after suture removal at 4 days. Reprinted with permission from (96).

Another study analyzed degrees of papilla shrinkage, when papilla base flaps and sulcular full-thickness flaps were raised (100). The comparison revealed significant loss of papilla height, when the papilla was mobilized during the surgical procedure. In contrary, the papilla base incision resulted in rapid and predictable recession-free healing. To avoid opening of the interproximal space in esthetically relevant areas, the use of the PBI was recommended for periradicular surgical procedures. A further study (101) investigated surgical outcomes concerning main vertical loss of height during 12 months. After three months, only minor vertical changes took place; in nine out of 12 sites, increases in recession depth were observed, while in three sites a small gain of papilla height occurred, compared to the 1-month situation. At 12 months two sites exhibited further recession, the remaining sites showed a certain degree of tissue “creeping.” However, the observed gain of the papilla height was not significant, when compared to short-term observation periods and the preoperative situation. In cases of full thickness flap elevation, mean papilla loss of height after 1 yr was 0.98 mm (Fig. 22).

In contrast to full mobilization of the papilla, the PBI resulted in significantly lower ( $p < 0.001$ ) recession depths of only  $0.07 \pm 0.09$  mm at 1 month,  $0.10 \pm 0.15$  mm at three months and  $-0.062 \pm 0.21$  mm after one year.

## CONCLUSIONS

The introduction of microsurgery to surgical endodontics attempted to minimize trauma and enhance surgical results. In combination with magnification and illumination, resected roots reveal intricate anatomical details. In conjunction with ultrasonic root-end preparation and tight sealing of the root end cavity, the requirements for mechanical and biological success are more adequately fulfilled. Although application of basic rules leads to fair soft tissue healing after endodontic surgery, there is a great potential for improvements in postsurgical esthetic outcome. As in other dental fields, “pink esthetics” of oral soft tissues become increasingly important and efforts are made to minimize scar formation and recessions after surgical procedures. This is even more the case when larger restorations are present and healthy periodontal tissues are reflected as access flaps for periradicular surgeries. Microsurgery alone will not accelerate epithelial healing rates, but through perfect tissue adaptation of wound edges, it can create smaller distances for epithelial migration during the healing process. More




FIG 22. Clinical example of endodontic microsurgery. The preoperative situation, the status presenting immediately postoperatively and the result after 1, 3, and 12 months. Reprinted with permission from (101).

rapid soft tissue healing is a result of reduced tissue trauma and enhanced wound closure during microsurgical procedures.

To achieve these goals several measures are necessary, including accurate preoperative treatment planning in reference to the condition and quality of the tissue to be manipulated. Minimal trauma should be inflicted during incision and raising of the flap. Both the flap and unreflected tissue remaining on the tooth surface should be kept moist during the entire procedure, especially in situations where excellent hemostasis can be achieved. Finally, sensitive handling of the soft tissues during suturing is mandatory, with wound edges being reapproximated without tension and held in place with nonabsorbable atraumatic sutures. The flap design plays an important role as to how much recession will occur postoperatively. Papilla base flaps have allowed virtually recession free healing after endodontic surgery.

The authors would like to thank Dr. Ove Peters for helpful criticism.

Peter Velvart, DMD, has a private practice in Zurich. Christine I. Peters, DMD, is affiliated with the Department of Preventive Dentistry, Periodontology and Cariology, University of Zurich, Switzerland and University of the Pacific, San Francisco, CA.

Address requests for reprints to Dr. Peter Velvart, Rennweg 58, CH-8001 Zurich, Switzerland; E-mail address: endo@velvart.ch.

## References

- Friedman S, Stabholz A. Endodontic retreatment—case selection and technique. Part 1: criteria for case selection. *J Endod* 1986;12:28–33.
- Danin J, Stromberg T, Forsgren H, Linder LE, Ramsköld LO. Clinical management of nonhealing periradicular pathosis. Surgery versus endodontic retreatment. *Oral Surg Oral Med Oral Pathol Oral Radiol Endod* 1996;82:213–7.
- Velvart P. Surgical retreatment. In: Bergenholtz G, Hørsted-Bindslev P, Reit C, eds. *Textbook of endodontology*. Oxford: Blackwell Munksgaard, 2003:312–26.
- Rud J, Andreasen JO, Jensen JF. A multivariate analysis of the influence of various factors upon healing after endodontic surgery. *Int J Oral Surg* 1972;1:258–71.
- Rud J, Andreasen JO, Jensen JE. Radiographic criteria for the assessment of healing after endodontic surgery. *Int J Oral Surg* 1972;1:195–214.
- Rud J, Andreasen JO. A study of failures after endodontic surgery by radiographic, histologic and stereomicroscopic methods. *Int J Oral Surg* 1972;1:311–28.
- Altonen M, Mattila K. Follow-up study of apicoectomized molars. *Int J Oral Surg* 1976;5:33–40.
- Mikkonen M, Kullää-Mikkonen A, Kotilainen R. Clinical and radiologic re-examination of apicoectomized teeth. *Oral Surg Oral Med Oral Pathol* 1983;55:302–6.
- Forssell H, Tammisalo T, Forssell K. A follow-up study of apicoectomized teeth. *Proc Finn Dent Soc* 1988;84:85–93.
- Friedman S, Lustmann J, Shaharabany V. Treatment results of apical surgery in premolar and molar teeth. *J Endod* 1991;17:30–3.
- Maddaloni M, Gagliani M. Periapical endodontic surgery: a 3-year follow-up study. *Int Endod J* 2003;36:193–8.
- Friedman S. Treatment outcome and prognosis of endodontic therapy. In: Ørstavik D, Pitt Ford T, eds. *Essential endodontology: prevention and treatment of apical periodontitis*. Oxford: Blackwell Science, 1998:388–91.
- Gutmann J, Harrison J. Success, failure, and prognosis in periradicular surgery. In: Gutmann J, Harrison J, eds. *Surgical endodontics*. Oxford: Blackwell Scientific Publications, 1991:338–84.
- Rubinstein RA, Kim S. Short-term observation of the results of endodontic surgery with the use of a surgical operation microscope and Super-EBA as root-end filling material. *J Endod* 1999;25:43–8.
- Ørstavik D. Reliability of the periapical index scoring system. *Scand J Dent Res* 1988;96:108–11.
- Huomonen S, Lenander-Lumikari M, Sigurdsson A, Ørstavik D. Healing of apical periodontitis after endodontic treatment: a comparison between a silicone-based and a zinc oxide-eugenol-based sealer. *Int Endod J* 2003;36:296–301.
- Jansson L, Sandstedt P, Laftman AC, Skoglund A. Relationship between apical and marginal healing in periradicular surgery. *Oral Surg Oral Med Oral Pathol Oral Radiol Endod* 1997;83:596–601.
- Ehnevid H, Jansson L, Lindsöck S, Blomlöf L. Periodontal healing in teeth with periapical lesions. A clinical retrospective study. *J Clin Periodontol* 1993;20:254–8.
- Chen S, Wang H, Glickman G. The influence of endodontic treatment upon periodontal wound healing. *J Clin Periodontol* 1997;24:449–56.
- Wirthlin MR. The current status of new attachment therapy. *J Periodontol* 1981;52:529–44.
- Zuolo ML, Ferreira MO, Gutmann JL. Prognosis in periradicular surgery: a clinical prospective study. *Int Endod J* 2000;33:91–8.
- Blatz MB, Hürzeler MB, Strub JR. Reconstruction of the lost interproximal papilla—presentation of surgical and nonsurgical approaches. *Int J Periodontics Restorative Dent* 1999;19:395–406.
- McLean JW. Long-term esthetic dentistry. *Quintessence Int* 1989;20:701–8.
- Allen EP. Use of mucogingival surgical procedures to enhance esthetics. *Dent Clin North Am* 1988;32:307–30.
- Miller PD, Jr. Regenerative and reconstructive periodontal plastic surgery. Mucogingival surgery. *Dent Clin North Am* 1988;32:287–306.
- Consensus report. Mucogingival therapy. *Ann Periodontol* 1996;1:702–6.
- Rocuzzo M, Bunino M, Needleman I, Sanz M. Periodontal plastic surgery for treatment of localized gingival recessions: a systematic review. *J Clin Periodontol* 2002;29(Suppl 3):178–94; discussion 95–6.
- Hürzeler MB, Weng D. Functional and esthetic outcome enhancement of periodontal surgery by application of plastic surgery principles. *Int J Periodontics Restorative Dent* 1999;19:36–43.
- Cortellini P, Tonetti MS. Microsurgical approach to periodontal regeneration. Initial evaluation in a case cohort. *J Periodontol* 2001;72:559–69.
- Kim S. Principles of endodontic microsurgery. *Dent Clin North Am* 1997;41:481–97.
- Carr G, Bentkover S. *Surgical Endodontics*. In: Cohen S, Burns R, eds. *Pathways of the pulp*. St Louis, MO: Mosby Inc., 1998:608–56.
- Schroeder HE, Listgarten MA. The gingival tissues: the architecture of periodontal protection. *Periodontol* 2000 1997;13:91–120.
- Bimstein E, Machtei E, Eidelman E. Dimensional differences in the attached and keratinized gingiva and gingival sulcus in the early permanent dentition: a longitudinal study. *J Pedod* 1986;10:247–53.
- Orban B, Wentz F, Everett F, Grant D. *Periodontics*. St. Louis: Mosby, 1958:22.
- Kohl JT, Zander HA. Morphology of interdental gingival tissues. *Oral Surg Oral Med Oral Pathol* 1961;14:287–95.
- Pilot T. [Macro-morphology of the interdental papilla]. *Dtsch Zahnarztl Z* 1973;28:1220–1.
- Tarnow D, Magner APF. The effect of the distance from the contact point to the crest of bone on the presence or absence of the interproximal dental papilla. *J Periodontol* 1992;63:995–6.
- Holmes CH. Morphology of the interdental papillae. *J Periodontol* 1965;36:455–60.
- Nobuto T, Yanagihara K, Teranishi Y, Minamibayashi S, Imai H, Yamaoka A. Periosteal microvasculature in the dog alveolar process. *J Periodontol* 1989;60:709–15.
- Keller GJ, Cohen DW. India ink perfusions of the vascular plexus of oral tissues. *J Oral Surg (Chic)* 1955;8:539–42.
- Folke LE, Stallard RE. Periodontal microcirculation as revealed by plastic microspheres. *J Periodontol Res* 1967;2:53–63.
- Castelli WA, Dempster WT. The periodontal vasculature and its responses to experimental pressures. *J Am Dent Assoc* 1965;70:890–905.
- Mörmann W, Meier C, Firestone A. Gingival blood circulation after experimental wounds in man. *J Clin Periodontol* 1979;6:417–24.
- Holmstrup P. Anatomy of the Periodontium. In: Wilson T, Kornmann K, eds. *Fundamentals of periodontics*. Carol Stream, IL: Quintessence Publishing Co., Inc., 2003:21–38.
- Mörmann W, Ciancio SG. Blood supply of human gingiva following periodontal surgery. A fluorescein angiographic study. *J Periodontol* 1977;48:681–92.
- Maggio JD, Bray KE, Hartwell GR, Lindemann MB, Pisano JV, E.M. R. Appropriateness of care and quality assurance guidelines, 3 ed. Chicago: American Association of Endodontists, 1998:24–32.
- Commission on Dental Accreditation of the American Dental Association. Standards for Advanced Specialty Education Programs in Endodontics 1998 (revised 2004). <http://www.ada.org/prof/ed/accred/standard/endo.pdf>. Accessed Nov. 16, 2004.
- Rubinstein RA, Kim S. Long-term follow-up of cases considered healed one year after apical microsurgery. *J Endod* 2002;28:378–83.
- Belcher JM. A perspective on periodontal microsurgery. *Int J Periodontics Restorative Dent* 2001;21:191–6.
- Vreeland DL, Tidwell E. Flap design for surgical endodontics. *Oral Surg Oral Med Oral Pathol* 1982;54:461–5.
- Lubow RM, Wayman BE, Cooley RL. Endodontic flap design: analysis and recommendations for current usage. *Oral Surg Oral Med Oral Pathol* 1984;58:207–12.
- Peters LB, Wesselink PR. Soft tissue management in endodontic surgery. *Dent Clin North Am* 1997;41:513–28.
- Gutmann JL, Harrison WH. Flap designs and incisions. In: Gutmann JL, Harrison WH, eds. *Surgical endodontics*. St. Louis, Missouri: Ishijaku EuroAmerica, Inc., 1994:162–75.

54. Patterson TJ. The survival of skin flaps in the pig. *Br J Plast Surg* 1968;21:113-7.
55. Ohmori S, Kurata K. Experimental studies on the blood supply to various types of skin grafts in rabbits using isotope P32. *Plast Reconstr Surg* 1960;25:547-55.
56. Luebke RG. Surgical endodontics. *Dent Clin North Am* 1974;18:379-91.
57. Lang NP, Loe H. The relationship between the width of keratinized gingiva and gingival health. *J Periodontol* 1972;43:623-7.
58. Harrison J, Jurosky K. Wound healing in the tissues of the periodontium following periradicular surgery. 2. The dissectional wound. *J Endod* 1991;17:544-52.
59. Selvig K, Torabinejad M. Wound healing after mucoperiosteal surgery in the cat. *J Endod* 1996;22:507-15.
60. Kon S, Caffesse RG, Castelli WA, Nasjleti CE. Revascularization following a combined gingival flap-split thickness flap procedure in monkeys. *J Periodontol* 1984;55:345-51.
61. Lilly GE. Reaction of oral tissues to suture materials. *Oral Surg Oral Med Oral Pathol* 1968;26:128-33.
62. Lilly GE, Armstrong JH, Salem JE, Cutcher JL. Reaction of oral tissues to suture materials. 2. *Oral Surg Oral Med Oral Pathol* 1968;26:592-9.
63. Lilly GE, Salem JE, Armstrong JH, Cutcher JL. Reaction of oral tissues to suture materials. 3. *Oral Surg Oral Med Oral Pathol* 1969;28:432-8.
64. Lilly GE, Cutcher JL, Jones JC, Armstrong JH. Reaction of oral tissues to suture materials. 4. *Oral Surg Oral Med Oral Pathol* 1972;33:152-7.
65. Lilly GE, Osbon DB, Hutchinson RA, Heflich RH. Clinical and bacteriologic aspects of polyglycolic acid sutures. *J Oral Surg* 1973;31:103-5.
66. Selvig KA, Biagiotti GR, Leknes KN, Wikesjo UM. Oral tissue reactions to suture materials. *Int J Periodontics Restorative Dent* 1998;18:474-87.
67. Michaelides PL, Wilson SG. A comparison of papillary retention versus full-thickness flaps with internal mattress sutures in anterior periodontal surgery. *Int J Periodontics Restorative Dent* 1996;16:388-97.
68. Yaltirik M, Dedeoglu K, Bilgic B, et al. Comparison of four different suture materials in soft tissues of rats. *Oral Dis* 2003;9:284-6.
69. Parell GJ, Becker GD. Comparison of absorbable with nonabsorbable sutures in closure of facial skin wounds. *Arch Facial Plast Surg* 2003;5:488-90.
70. van der Horst C, Martinez Portillo FJ, Melchior D, Bross S, Alken P, Juenemann KP. Polytetrafluoroethylene versus polypropylene sutures for Es-sed-Schroeder tunicular plication. *J Urol* 2003;170:472-5.
71. Caudill RF, Oringer RJ, Langer L, Langer B, Bahat O, Handelsman M. Esthetic periodontics (periodontal plastic surgery). In: Wilson T, Kornmann K, eds. *Fundamentals of periodontics*. Carol Stream, IL: Quintessence Publishing Co., Inc., 2003:540-61.
72. Bahat O, Handelsman M. Periodontal reconstructive flaps—classification and surgical considerations. *Int J Periodontics Restorative Dent* 1991;11:480-7.
73. Nelson EH, Funakoshi E, O'Leary TJ. A comparison of the continuous and interrupted suturing techniques. *J Periodontol* 1977;48:273-81.
74. Wirthlin MR, Hancock EB, Gaugler RW. The healing of atraumatic and traumatic incisions in the gingivae of monkeys. *J Periodontol* 1984;55:103-13.
75. Tinti C, Benfental S. The ramp mattress suture: a new suturing technique combined with a surgical procedure to obtain papillae between implants in the buccal area. *Int J Periodontics Restorative Dent* 2002;22:63-9.
76. Harrison J, Jurosky K. Wound healing in the tissues of the periodontium following periradicular surgery. I. The incisional wound. *J Endod* 1991;17:425-35.
77. Pihlstrom BL, McHugh RB, Oliphant TH, Ortiz-Campos C. Comparison of surgical and nonsurgical treatment of periodontal disease. A review of current studies and additional results after 61/2 years. *J Clin Periodontol* 1983;10:524-41.
78. Harrison JW. Healing of surgical wounds in oral mucoperiosteal tissues. *J Endod* 1991;17:401-8.
79. Tibbetts LS, Shanelec D. Current status of periodontal microsurgery. *Curr Opin Periodontol* 1996;3:118-25.
80. Wong ME, Hollinger JO, Pinero GJ. Integrated processes responsible for soft tissue healing. *Oral Surg Oral Med Oral Pathol Oral Radiol Endod* 1996;82:475-92.
81. Hunt TK, Knighton DR, Thakral KK, Goodson WH, 3rd, Andrews WS. Studies on inflammation and wound healing: angiogenesis and collagen synthesis stimulated in vivo by resident and activated wound macrophages. *Surgery* 1984;96:48-54.
82. Wirthlin MR, Yeager JE, Hancock EB, Gaugler RW. The healing of gingival wounds in miniature swine. *J Periodontol* 1980;51:318-27.
83. Afshar-Mohajer K, Stahl SS. The remodeling of human gingival tissues following gingivectomy. *J Periodontol* 1977;48:136-9.
84. Hom DB. A new era of discovery in facial plastic surgery. *Arch Facial Plast Surg* 2000;2:166-72.
85. Hom DB, Thatcher G, Tibesar R. Growth factor therapy to improve soft tissue healing. *Facial Plast Surg* 2002;18:41-52.
86. Kindlova M. The blood supply of the marginal periodontium in *Macacus rhesus*. *Arch Oral Biol* 1965;10:869-74.
87. Pontoriero R, Carnevale G. Surgical crown lengthening: a 12-month clinical wound healing study. *J Periodontol* 2001;72:841-8.
88. Nemcovsky C. Interproximal papilla augmentation procedure: a novel surgical approach and clinical evaluation of 10 consecutive procedures. *Int J Periodontics Restorative Dent* 2001;21:553-9.
89. Beer R, Baumann M, Kim S. *Endodontology*. Stuttgart: Thieme Verlag, 2000:238-9.
90. Zimmermann U, Ebner J, Velvart P. Papilla healing following sulcular full thickness flap in endodontic surgery. *J Endod* 2001;27:219.
91. Velvart P, Ebner-Zimmermann U, Ebner JP. Papilla healing following full thickness flap in endodontic surgery. (in press)
92. Takei H, Han T, Carranza FJ, Kenney E, Lekovic V. Flap technique for periodontal bone implants. Papilla preservation technique. *J Periodontol* 1985;56:204-10.
93. Cortellini P, Prato GP, Tonetti MS. The modified papilla preservation technique. A new surgical approach for interproximal regenerative procedures. *J Periodontol* 1995;66:261-6.
94. Cortellini P, Pini Prato G, Tonetti MS. The modified papilla preservation technique with bioresorbable barrier membranes in the treatment of intrabony defects. Case reports. *Int J Periodontics Restorative Dent* 1996;16:546-59.
95. Takei H, Yamada H, Hau T. Maxillary anterior esthetics. Preservation of the interdental papilla. *Dent Clin North Am* 1989;33:263-73.
96. Velvart P. Papilla base incision: a new approach to recession-free healing of the interdental papilla after endodontic surgery. *Int Endod J* 2002;35:453-60.
97. Soehren SE, Allen AL, Cutright DE, Seibert JS. Clinical and histologic studies of donor tissues utilized for free grafts of masticatory mucosa. *J Periodontol* 1973;44:727-41.
98. Mörmann W, Schaer F, Firestone A. The relationship between success of free gingival grafts and transplant thickness. Revascularization and shrinkage—one-year clinical study. *J Periodontol* 1981;52:74-80.
99. Wennström J, Pini Prato G. *Mucogingival therapy*. In: *Clinical periodontology and implant dentistry*, 3rd ed. Copenhagen: Munksgaard, 1998: 550-96.
100. Velvart P, Ebner-Zimmermann U, Ebner JP. Comparison of papilla healing following sulcular full-thickness flap and papilla base flap in endodontic surgery. *Int Endod J* 2003;36:653-9.
101. Velvart P, Ebner-Zimmermann U, Ebner JP. Comparison of long term papilla healing following sulcular full thickness flap and papilla base flap in endodontic surgery. *Int Endod J* (in press).
102. Gutmann JL, Harrison JW. Closure of the surgical site and postsurgical management. In: Gutmann JL, Harrison JW, eds. *Surgical endodontics*. St. Louis: Ishiyaku EuroAmerica, 1994:278-99.