

This material may be protected by Copyright Law (Title 17  
U.S. code)



ILLiad TN: 176393

**Book Author or Journal Title:**  
Chinese journal of dental research

**Book Title or Article Author:**  
Wang, Pei

**Edition/Year:** 2010

**Article Title:** Evaluation of dental root fracture using cone-beam computed tomography

**Volume:** 13 **Issue:** 1 **Month:** - **Pages:** 31-5

**Special Instructions:** Library Staff Use Only = NO CHARGE

Library Use Only:

# of Items Pulled \_\_\_\_\_

# of Pages Copied/Scanned/Printed (circle one) \_\_\_\_\_

XLstats?

ILLiadstats?

**Call #:** Chinese journal of dental research

**Location:** E-Journals

**MaxCost:** \$0

**Is this a Rush request?:** No


**Delivery Method:**

**Status:** POSTDOC

**Department:** ADVENDO

**Patron:** Weed, Scott  
weeddds@gmail.com

Scott Weed (weeddds)  
5220 Shearin Avenue  
Los Angeles, CA 90041



## Evaluation of Dental Root Fracture Using Cone-beam Computed Tomography

Pei WANG<sup>1</sup>, Xue Bing YAN<sup>2</sup>, Deng Gao LIU<sup>3</sup>, Wan Lin ZHANG<sup>3</sup>, Zu Yan ZHANG<sup>3</sup>,  
Xu Chen MA<sup>3</sup>

**Objective:** To evaluate the application of cone-beam computed tomography (CBCT) in the detection of dental root fractures and to analyse the demographic profile of these fractures.

**Methods:** The study group comprised 398 teeth that were examined by CBCT for determining whether they had a root fracture. Patient characteristics were recorded, and the location, fractured roots, fracture types and three-dimensional images of the related skeletal structures were analysed. Two experienced oral radiologists independently analysed each case and reached a consensus, and the diagnosis was graded in one of the following three categories: fracture definitely present (FDP), fracture probably present (FPP) and no visible fracture (NVF).

**Results:** Among these teeth, 155 (39.0%) were diagnosed as FDP, 14 (3.5%) as FPP and 229 (57.5%) as NVF in the consensus reading. During follow-up, all teeth diagnosed as FDP and 4 of the 14 teeth diagnosed as FPP were intra-operatively demonstrated to be fractured. In FDP cases, 60.0% of the patients were aged from 50 to 69 years. In total, 107 FDP teeth were non-endodontically treated, and the remaining were endodontically treated with ( $n = 16$ ) or without ( $n = 32$ ) crown placement. The maxillary and mandibular molars were most frequently affected (81.9%). The fractured roots were mostly palatal (65.7%) in maxillary molars and mesial (84.2%) in mandibular molars. The fractures were characterised as vertical ( $n = 84$ ), horizontal ( $n = 34$ ), oblique ( $n = 5$ ) and complicated ( $n = 32$ ) fractures.

**Conclusion:** The application of CBCT is valuable for the diagnosis of root fracture.

**Key words:** cone-beam computed tomography, dental root fracture, imaging diagnosis

Teeth with root fractures have a complete or an incomplete fracture that extends through the root of the tooth<sup>1</sup>. Often, these fractures extend through the pulp to the periodontal ligament. The presence of a root fracture is often associated with a poor prognosis. Depending on the size and location of the fracture, treatment ranges from partial root resection to extraction<sup>2</sup>. A

definitive diagnosis is essential to avoid inappropriate treatment. However, it is often difficult to reach an accurate diagnosis on the basis of the presenting signs and symptoms because these symptoms are often variable or nonspecific<sup>1,2</sup>. Conventional radiographs can be helpful for the diagnosis when the x-ray beam is parallel to the plane of the fracture, but this is not likely to occur most of the time. Superimposition of neighboring structures further limits the ability to detect root fractures when using conventional radiographs<sup>3</sup>. Cone-beam computed tomography (CBCT) provides high-resolution images in three planes and is now commonly used in dental practice<sup>4</sup>. Despite the above-mentioned advantages of this technique, a comprehensive analysis of the value of CBCT images in the diagnosis of root fracture needs to be performed<sup>5</sup>. The aim of this study is to evaluate the application of CBCT for the diagnosis of root fractures that do not originate from emergent trauma, and to determine the demographic profile of these fractures.

- 1 Department of Oral Radiology and General Dentistry, School of Stomatology, Fourth Military Medical University, Xi'an, P.R. China.
- 2 Special Dental Department of the First Stomatology Clinic, Peking University School and Hospital of Stomatology, Beijing, P.R. China.
- 3 Department of Oral and Maxillofacial Radiology, Peking University School and Hospital of Stomatology, Beijing, P.R. China.

**Corresponding author:** Dr Deng Gao LIU, Department of Oral and Maxillofacial Radiology, Peking University School and Hospital of Stomatology, #22 Zhongguancun Nandajie, Haidian District, Beijing 100081, P.R. China. Tel: 86-10-62179977 ext 5373; Fax: 86-10-62173402. E-mail: kqldg@bjmu.edu.cn

## Materials and methods

The CBCT images of 398 teeth from 375 consecutive patients were analysed. The patients were referred to oral radiologists by endodontists or periodontists to determine the presence of a dental root fracture between May 2004 and Dec 2008. CBCT was performed in response to the existence of a suspicious fracture line on dental radiographs, or the existence of one or a combination of the following manifestations: long-term pain, periodontal pocket, abscess, sensitivity to palpation or percussion, and a fracture line that was not definitively observed on dental radiographs. In all cases, the initial dental radiographs had been read carefully and the necessity of a CBCT examination had been justified by oral radiologists. The purpose of performing a CBCT examination included: (i) to determine the presence of a root fracture, (ii) to determine the location and size of the fracture, and (iii) to analyze the appearance of the periapical and periradicular bone. Teeth for which clear and legible CBCT images could not be obtained were excluded from the present study. Cases of root fractures that might be related to emergent trauma were also excluded.

The 3DX CT (3D Accuitomo, J Morita, Kyoto, Japan) had a radiation field 30 mm in height and 40 mm in width at the centre of rotation. The imaging time was 17.5 s at 80 kV and 5 mA. Reconstructed slices of 0.5 mm thickness and 360° rotation were routinely used. The voxel dimension of the reconstructed image was 0.125 × 0.125 × 0.125 mm. The 3DX images were optimised for the visualisation of the affected teeth by adjusting the re-slicing angle in the 3D planes.

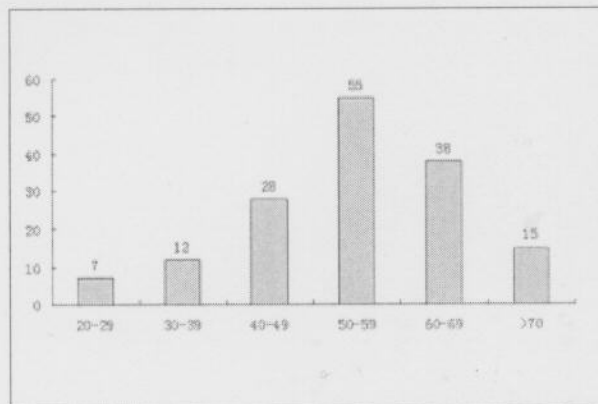
For each case, the following parameters were documented (all of these were collected from the CBCT database and the medical records of the patients):

- age
- gender
- tooth number and location
- treatment history
  - no root canal treatment
  - root canal treatment
  - root canal treatment with crown placement
- radiographic appearance of the neighboring alveolus
  - nearly normal appearance
  - periapical lesion (bone loss at the apex of the tooth that is considered more than a thickened periodontal ligament)
  - periradicular lesion (bone loss at the lateral surfaces of the root)
  - combined periodontal-endodontic lesion.

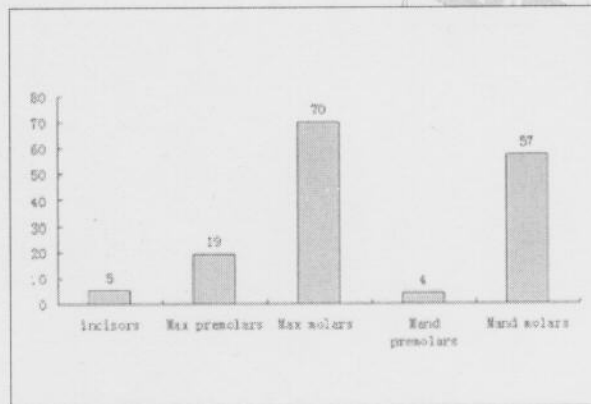
The images were independently examined by two experienced oral radiology specialists. They were encouraged to browse through the images and to modify brightness and contrast and to assess the presence or absence of a root fracture. They recorded their response on a three-point probability scale as follows: 1 = fracture definitely present (FDP), 2 = fracture probably present (FPP) and 3 = no visible fracture (NVF). The CBCT findings of root fractures were characterised by separation of the adjacent root segments on at least two contiguous sections without the continuation of the hypoattenuated line into the adjacent tissue; moreover, the hypoattenuated line must be detectable in at least two of the 3D planes. Cases with metallic restorations or root fillings usually exhibited multiple hypoattenuated and hyperattenuated linear artefacts. These artefacts often traversed the root and adjacent bone and were usually considered negative for root fracture. These criteria were based upon the standards of conventional CT suggested by Youssefzadeh<sup>6</sup> and were slightly modified according to the authors' experience. After independently reading the images, the two oral radiologists compared their findings, discussed and achieved a consensus. Teeth diagnosed as FDP or FPP in consensus were followed up for a period of 3 to 6 months and assessed at surgery (namely extraction, amputation or root-end resection). During surgery, fractures were diagnosed when a separation of fragments was observed or when lines were darker than the surrounding tooth structure. For each tooth, special care was taken to avoid intraoperative damage to the involved roots. Statistical analyses were conducted using SPSS (version 11.0, SPSS, Chicago, IL, USA). The kappa coefficient was calculated to determine the reliability and reproducibility of the CBCT evaluation of the two radiologists. The level of significance was set at  $P < 0.05$ .

## Results

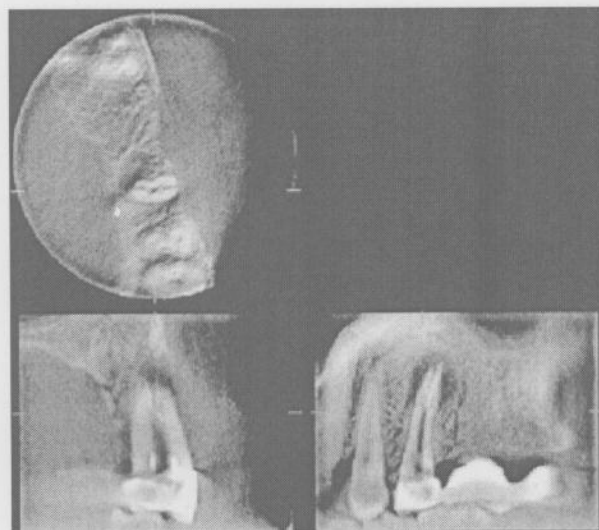
Out of the 375 patients, 190 were female and 185 were male. Their ages ranged from 12 to 81 years, with a median of 50 years. Among the 398 teeth evaluated, 199 teeth had never been endodontically treated; the remaining 199 teeth had been endodontically treated with ( $n = 79$ ) or without ( $n = 120$ ) crown placement. The two oral radiologists were referred to as radiologist A and radiologist B. Radiologist A diagnosed 163 teeth as FDP, 17 teeth as FPP and 218 teeth as NVF. Radiologist B diagnosed 154 teeth as FDP, 19 teeth as FPP and 225 teeth as NVF. In a consensus reading, 155 teeth were diagnosed as FDP, 14 teeth were FPP and 229 teeth were NVF. The kappa coefficient between the two radiologists was 0.81; between the readings



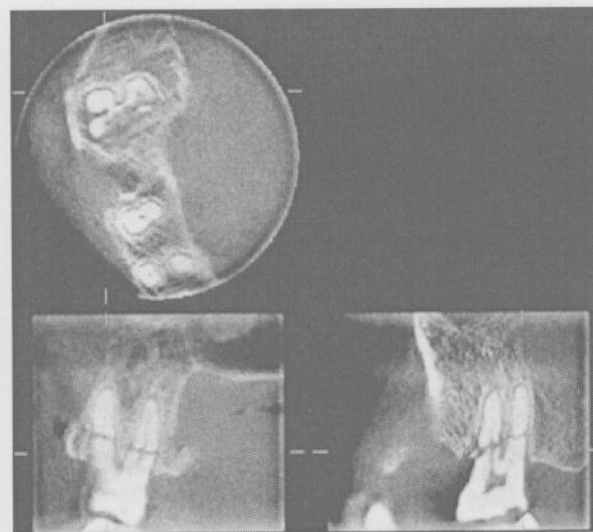
**Fig 1** Age distribution of 143 patients with teeth diagnosed as 'fracture definitely present'.



**Fig 2** Distribution of tooth locations of 155 teeth diagnosed as 'fracture definitely present'.



**Fig 3** Vertical root fracture of the left maxillary 2nd premolar.



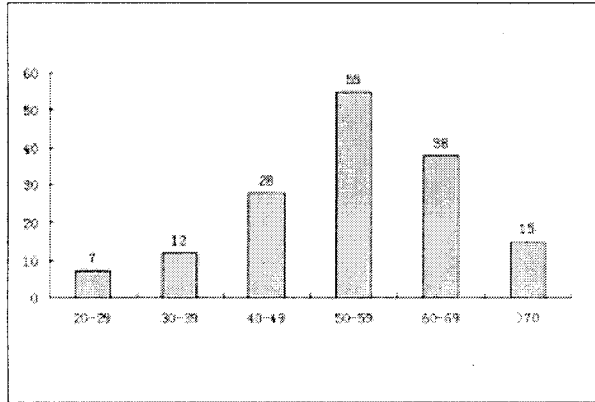
**Fig 4** Horizontal fracture affecting three roots of the right maxillary 2nd molar.

of radiologist A and the consensus reading, 0.88; and between the readings of radiologist B and the consensus reading, 0.91.

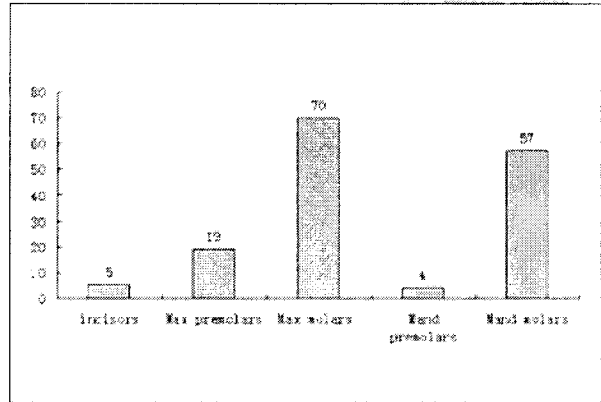
The 155 teeth diagnosed as FDP in the consensus reading were acquired from 143 patients. Among these patients, 134 suffered root fracture of a single tooth, whereas nine patients presented with two teeth fractured. Among these teeth, 107 had never been endodontically treated, and the remaining 48 teeth had been endodontically treated with ( $n = 16$ ) or without ( $n = 32$ ) crown placement. The distribution of patients' age and tooth location is shown in Figures 1 and 2, respectively. During the follow-up, 150 teeth were extracted and root fracture was confirmed during extraction; the remaining five teeth had the affected root amputated, and there was also evidence of root fracture. Finally, the clinical

signs and symptoms were completely eliminated for these teeth after extraction or amputation.

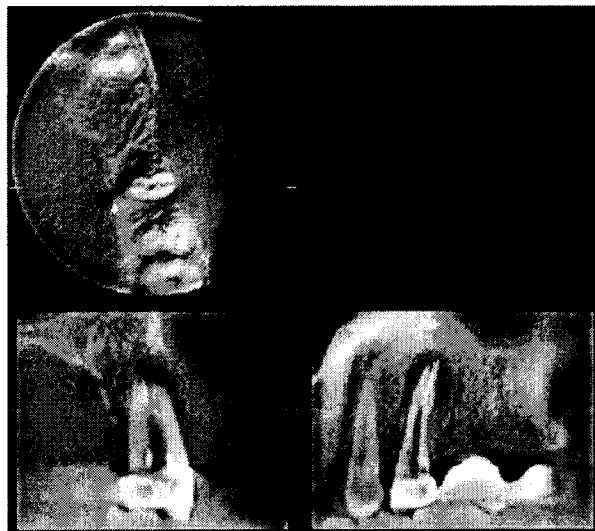
A total of 134 teeth showed a fracture occurring in only one root (Fig 3), and the remaining 21 teeth showed a fracture occurring in at least two roots (Fig 4). Among the 134 teeth with one fractured root, 84 teeth showed vertically oriented fractures (Figs 3 and 5), 34 teeth showed horizontally oriented fractures (Fig 4), five teeth showed obliquely orientated fractures (Fig 6), and 11 teeth showed complicated fractures (Fig 7). Therefore, the root fractures were characterised as vertical fracture, horizontal fracture, oblique fracture or complex fracture. Among the 70 maxillary molars diagnosed as FDP, palatal root fracture was present in 46 (65.7%) molars. Among the 57 mandibular molars diagnosed as FDP, the mesial root fracture was present in 48 (84.2%) molars.



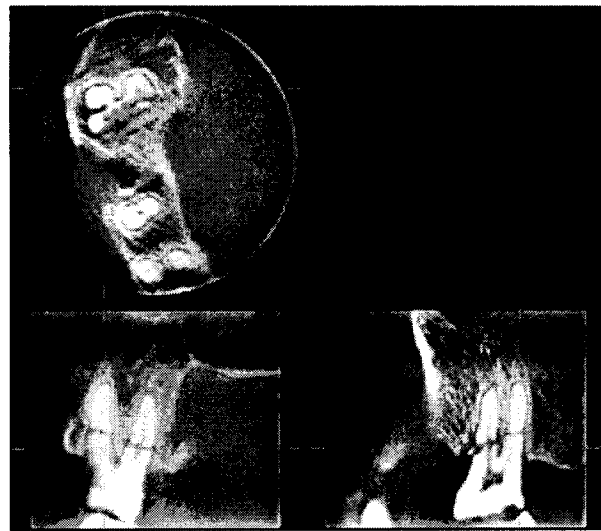
**Fig 1** Age distribution of 143 patients with teeth diagnosed as 'fracture definitely present'.



**Fig 2** Distribution of tooth locations of 155 teeth diagnosed as 'fracture definitely present'.



**Fig 3** Vertical root fracture of the left maxillary 2nd premolar.



**Fig 4** Horizontal fracture affecting three roots of the right maxillary 2nd molar.

of radiologist A and the consensus reading, 0.88; and between the readings of radiologist B and the consensus reading, 0.91.

The 155 teeth diagnosed as FDP in the consensus reading were acquired from 143 patients. Among these patients, 134 suffered root fracture of a single tooth, whereas nine patients presented with two teeth fractured. Among these teeth, 107 had never been endodontically treated, and the remaining 48 teeth had been endodontically treated with ( $n = 16$ ) or without ( $n = 32$ ) crown placement. The distribution of patients' age and tooth location is shown in Figures 1 and 2, respectively. During the follow-up, 150 teeth were extracted and root fracture was confirmed during extraction; the remaining five teeth had the affected root amputated, and there was also evidence of root fracture. Finally, the clinical

signs and symptoms were completely eliminated for these teeth after extraction or amputation.

A total of 134 teeth showed a fracture occurring in only one root (Fig 3), and the remaining 21 teeth showed a fracture occurring in at least two roots (Fig 4). Among the 134 teeth with one fractured root, 84 teeth showed vertically oriented fractures (Figs 3 and 5), 34 teeth showed horizontally oriented fractures (Fig 4), five teeth showed obliquely orientated fractures (Fig 6), and 11 teeth showed complicated fractures (Fig 7). Therefore, the root fractures were characterised as vertical fracture, horizontal fracture, oblique fracture or complex fracture. Among the 70 maxillary molars diagnosed as FDP, palatal root fracture was present in 46 (65.7%) molars. Among the 57 mandibular molars diagnosed as FDP, the mesial root fracture was present in 48 (84.2%) molars.

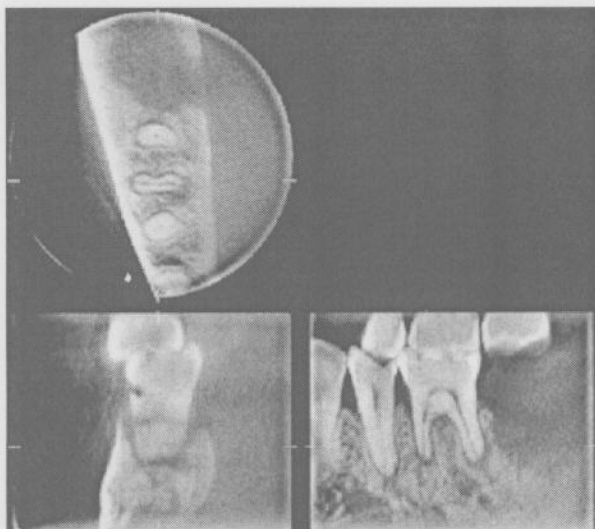


Fig 5 Vertical root fracture of the mesial root of the right mandibular 1st molar.

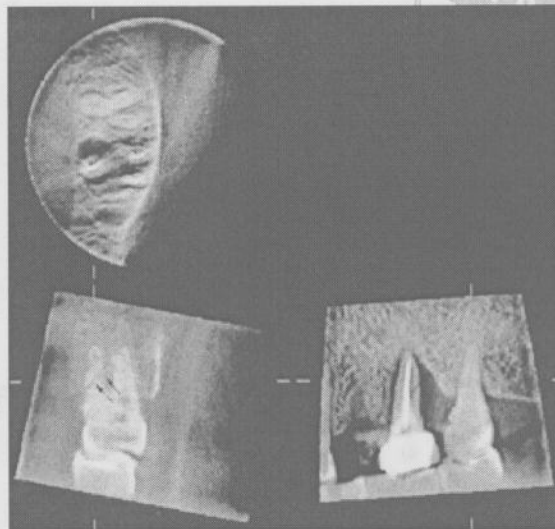


Fig 6 Oblique root fracture of the left maxillary 2nd molar (double arrow) and vertical root fracture of the left maxillary 1st molar.

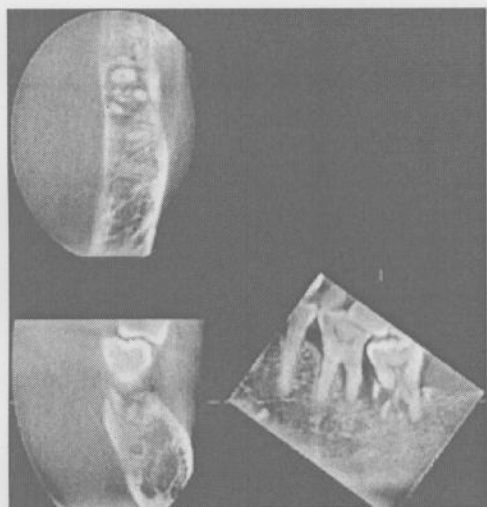


Fig 7 Complicated fracture in the mesial root of the left mandibular 2nd molar.

The skeletal appearance of teeth in the FDP group is shown in Figure 8. Among the 14 teeth diagnosed as FPP, four teeth were extracted and confirmed with root fracture during the 6-month follow-up. Among the 229 teeth diagnosed as NVF, two teeth were extracted and found to have minimal root fractures during the follow-up.

**Discussion**

A number of radiographic signs provide either conclusive or suggestive evidence of root fracture, including actual separation of root fragments, radiolucent fracture lines, radiopaque signs, halo-like apical radiolucency, periodontal-like bone lesions and loosening of retrofilling material<sup>2</sup>. However, the radiographic evidence of fracture is often absent even when the fracture is readily apparent at surgical exposure. In a study of 375 cases, Rud et al<sup>6</sup> found that a fracture line was observed on dental radiographs in only 35.7% of the cases. In Youssefzadeh's<sup>7</sup> study, 28 teeth were proven to be fractured at the time of the operation, and the sensitivity of dental radiography in the assessment of vertical fractures was 25%. The factors influencing the sensitivity may include the following: the plane of the x-ray beam may not be parallel to the plane of the fracture; the fracture may be obscured by neighboring skeletal structures, posts or root canal filling materials; or early stages of incomplete fracture, in which there are subtle fissures with no separation of the adjacent segments, are not detectable<sup>2,7,8,9</sup>. The advantages of CBCT over conventional CT are lower cost, smaller machine size and smaller radiation dose<sup>5,10</sup>. The probability of detecting root fractures is

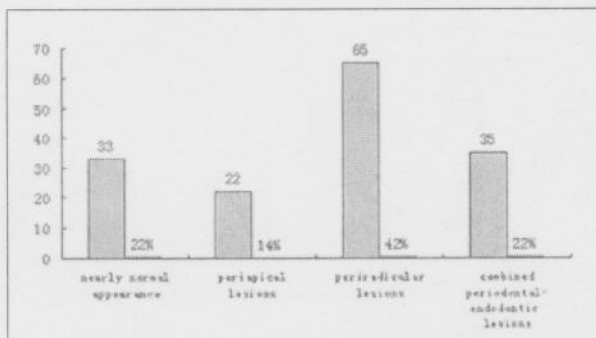
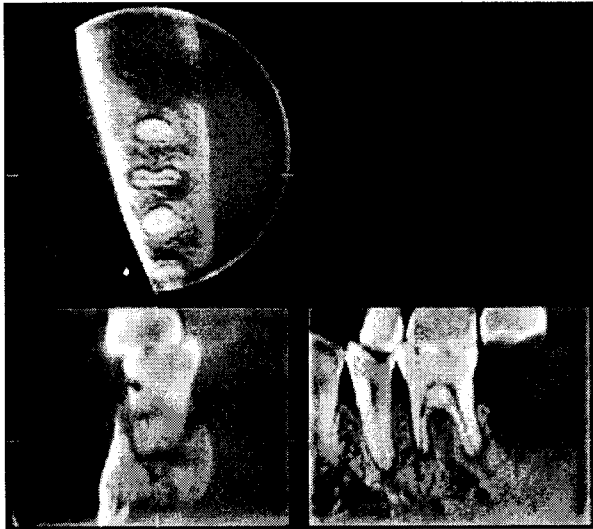
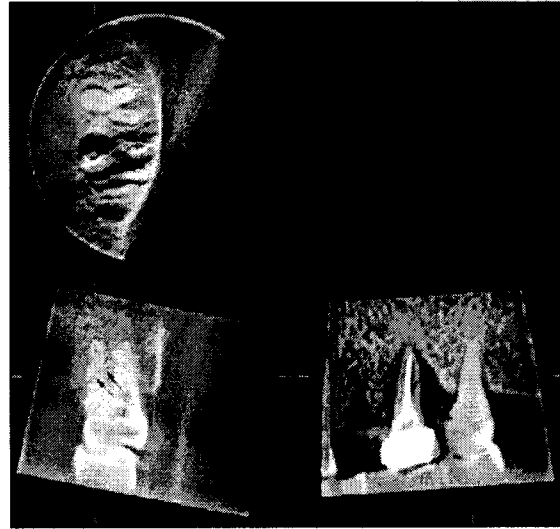


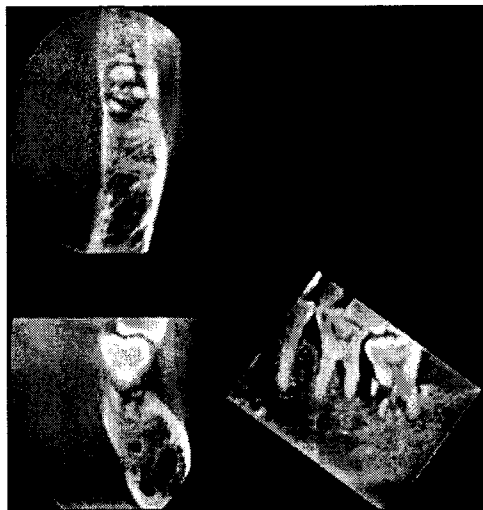
Fig 8 Appearance of the periapical and periradicular bone of the 155 teeth diagnosed as 'fracture definitely present'.



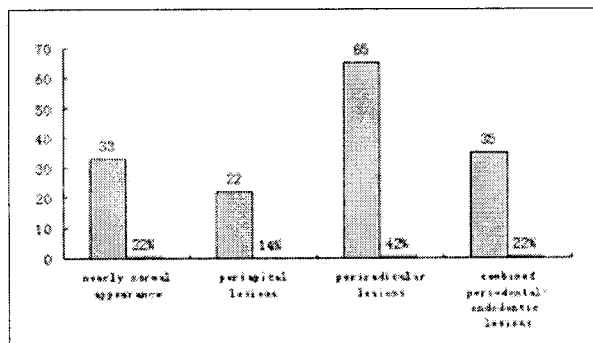
**Fig 5** Vertical root fracture of the mesial root of the right mandibular 1st molar.



**Fig 6** Oblique root fracture of the left maxillary 2nd molar (double arrow) and vertical root fracture of the left maxillary 1st molar.



**Fig 7** Complicated fracture in the mesial root of the left mandibular 2nd molar.



**Fig 8** Appearance of the periapical and periradicular bone of the 155 teeth diagnosed as 'fracture definitely present'.

The skeletal appearance of teeth in the FDP group is shown in Figure 8. Among the 14 teeth diagnosed as FPP, four teeth were extracted and confirmed with root fracture during the 6-month follow-up. Among the 229 teeth diagnosed as NVF, two teeth were extracted and found to have minimal root fractures during the follow-up.

**Discussion**

A number of radiographic signs provide either conclusive or suggestive evidence of root fracture, including actual separation of root fragments, radiolucent fracture lines, radiopaque signs, halo-like apical radiolucency, periodontal-like bone lesions and loosening of retrofilling material<sup>2</sup>. However, the radiographic evidence of fracture is often absent even when the fracture is readily apparent at surgical exposure. In a study of 375 cases, Rud et al<sup>6</sup> found that a fracture line was observed on dental radiographs in only 35.7% of the cases. In Youssefzadeh's<sup>7</sup> study, 28 teeth were proven to be fractured at the time of the operation, and the sensitivity of dental radiography in the assessment of vertical fractures was 25%. The factors influencing the sensitivity may include the following: the plane of the x-ray beam may not be parallel to the plane of the fracture; the fracture may be obscured by neighboring skeletal structures, posts or root canal filling materials; or early stages of incomplete fracture, in which there are subtle fissures with no separation of the adjacent segments, are not detectable<sup>2,7,8,9</sup>. The advantages of CBCT over conventional CT are lower cost, smaller machine size and smaller radiation dose<sup>5,10</sup>. The probability of detecting root fractures is

expected to be higher due to the high spatial resolution and convenience of 3D adjustment for visualisation.

In the present study, approximately 39% of the teeth were diagnosed as FDP, which meant that at least one fracture line was identified among the teeth. Moreover, these teeth were confirmed to be fractured during the follow-up. This indicated that the diagnostic criteria in this study were highly reliable for detection of a root fracture. A total of 57.5% of the study samples were diagnosed as NVF. Nevertheless, it should be pointed out that the artefacts from metallic restorations and filling materials might shield the fracture line on CBCT slices, and this might cause an underestimation of the occurrence of root fractures. On the basis of the symptoms and the CBCT images, these teeth could be followed up after endodontic or periodontal treatment; or otherwise, they should be extracted if they were found at the time of the operation to be truly fractured. In any case, the CBCT images showing the microanatomy of the tooth and adjacent structures were helpful in deciding the treatment options. Merely 3.5% of the study population was diagnosed as FPP. This indicated that while a fracture line was seen, it could not be fully differentiated from the artefacts of imaging. These cases necessitated intensive follow-up. Although root fracture was diagnosed on the basis of the authors' experience, the inter- and intra-rater reliability was good, as demonstrated by the statistical analysis.

Age seems to predispose the patient to a root fracture. Tamse et al<sup>11</sup> evaluated 92 vertically fractured endodontically treated teeth from 90 patients and found that more than 50 patients were more than 45 years of age. In the Cohen et al<sup>12</sup> study of 227 teeth with vertical root fractures, 86.79% of the patient population was older than 40 years. This was confirmed in the present study, in which the age of 60% of the patient population ranged from 50 to 69 years. The reasons why older individuals may have a tendency to develop these fractures could be that their teeth have been in physical use for a long period, and these individuals are more likely to have had extensive operative or endodontic procedures.

The location of the affected tooth is also a factor that influences root fractures. In the Tamse<sup>11</sup> study, root fractures were predominantly observed in premolars (52%). Cohen's<sup>12</sup> study indicated that vertical root fractures were statistically more prevalent in maxillary premolars (23.35%) and mandibular molars (42.74%) than the other teeth. However, in the present study, fractures were observed more frequently in the maxillary molars (45%) and mandibular molars (37%) – the maxillary premolars were affected in only 12% of the group. This was probably due to the sampling difference and the status of treatment.

The CBCT appearance of the adjacent alveolar bone was also helpful for the diagnosis<sup>13</sup>. In Cohen's<sup>12</sup> study, periradicular lesions were present in about half of the cases. In Tamse's<sup>11</sup> study, lateral radiolucency plus the combination of periapical and lateral radiolucency was present in 63% of the cases. In the present study, periradicular radiolucency plus combined periodontal-endodontic lesions were present in 64.5% of the FDP cases. In cases where progressive periradicular bone loss was detected following root canal treatment, a root fracture would be suspected, even if a fracture line was not definitively identified.

In summary, CBCT provided high-quality images that were helpful for the detection of root fractures and related radiographic signs.

## References

1. Mora MA, Mol A, Tyndall DA, Rivera EM, Hill C. *In vitro* assessment of local computed tomography for the detection of longitudinal tooth fractures. *Oral Surg Oral Med Oral Pathol Oral Radiol Endod* 2007;103:825-829.
2. Pitts DL, Natkin E. Diagnosis and treatment of vertical root fractures. *J Endod* 1983;9:338-346.
3. Kositbowornchai S, Nuansakul R, Sikram S, Sinahawattana S, Saengmontri S. Root fracture detection: a comparison of direct digital radiography with conventional radiography. *Dentomaxillofac Radiol* 2001;30:106-109.
4. Nair MK, Nair UP, Gröndahl HG, Webber RL. Accuracy of tuned aperture computed tomography in the diagnosis of radicular fractures in non-restored maxillary anterior teeth—an *in vitro* study. *Dentomaxillofac Radiol* 2002;31:299-304.
5. Suomalainen AK, Salo A, Robinson S, Peltola JS. The 3DX multi image micro-CT device in clinical dental practice. *Dentomaxillofac Radiol* 2007;36:80-85.
6. Rud J, Omnell KA. Root fractures due to corrosion. *Scand J Dent Res* 1970;78:397-403.
7. Youssefzadeh S, Gahleitner A, Dorffner R, Bernhart T, Kainberger FM. Dental vertical root fractures: value of CT in detection. *Radiology* 1999;210:545-549.
8. Tsesis I, Kamburoglu K, Katz A, Tamse A, Kaffe I, Kfir A. Comparison of digital with conventional radiography in detection of vertical root fractures in endodontically treated maxillary premolars: an *ex vivo* study. *Oral Surg Oral Med Oral Pathol Oral Radiol Endod* 2008;106:124-128.
9. Hannig C, Dullin C, Hülsmann M, Heidrich G. Three-dimensional, non-destructive visualization of vertical root fractures using flat panel volume detector computer tomography: an *ex vivo in vitro* case report. *Int Endod J* 2005;38:904-913.
10. Sakabe J, Kuroki Y, Fujimaki S, Nakajima I, Honda K. Reproducibility and accuracy of measuring unerupted teeth using limited cone beam X-ray CT. *Dentomaxillofac Radiol* 2007;36:2-6.
11. Tamse A, Fuss Z, Lustig J, Kaplavi J. An evaluation of endodontically treated vertically fractured teeth. *J Endod* 1999;25:506-508.
12. Cohen S, Berman LH, Blanco L, Bakland L, Kim JS. A demographic analysis of vertical root fractures. *J Endod* 2006;32:1160-1163.
13. Nicopoulou-Karayianni K, Bragger U, Lang NP. Patterns of periodontal destruction associated with incomplete root fractures. *Dentomaxillofac Radiol* 1997;26:321-326.