

# Evidence-Based Decision Making: Replacement of the Single Missing Tooth

Paul A. Fugazzotto, DDS

## KEYWORDS

• Treatment algorithms • Augmentation • Implants

Single-tooth replacement may be effected through use of a resin-bonded fixed partial denture (RBB), a conventional fixed partial denture (FPD), a removable prosthesis, or a single implant-supported crown (SIC). The use of a removable prosthesis is excluded from consideration because the final treatment result of a removable prosthesis for replacement of a single missing tooth is considered a compromise in all situations.

Although the introduction of newer therapeutic modalities, surgical and restorative techniques, and restorative materials has significantly expanded available treatment options, a greater demand is now placed on the diagnostic and treatment planning acumen of the clinician. Mastery of available treatment techniques by the surgeon and the restorative dentist may be easily and predictably accomplished. The questions confronting each clinician are when to apply each treatment modality and how to use these therapeutic approaches to their maximum benefit for the patient.

This article focuses on the factors that should be considered when making such clinical decisions and offers a framework within which to formulate appropriate treatment algorithms.

## COMPARING SUCCESS RATES OF VARIOUS SINGLE TOOTH REPLACEMENT TREATMENTS

The lack of direct comparative studies assessing treatment outcomes following the use of SICs or tooth-supported FPDs does not allow indisputable proclamations to be made regarding which therapy is most appropriately employed in such situations. Section 3 of the State of the Science of Implant Dentistry Consensus Conference (held by the Academy of Osseointegration in 2006) analyzed the available literature with the aim of answering the question, "In patients requiring single tooth replacement, what are the outcomes of implant- as compared to tooth-supported restorations?"<sup>1</sup> In an

---

25 High Street, Milton, MA 02186, USA  
E-mail address: [progressiveperio@aol.com](mailto:progressiveperio@aol.com)

Dent Clin N Am 53 (2009) 97–129  
doi:10.1016/j.cden.2008.10.001

0011-8532/08/\$ – see front matter © 2009 Published by Elsevier Inc.

[dental.theclinics.com](http://dental.theclinics.com)

effort to assess an adequate number of published articles to draw conclusions, inclusion criteria demanded only a minimum 2-year length of study. Fifty-one articles were assessed from the implant literature and 41 articles were examined from the FPD literature. The success rate of single-implant restorations at 60 months was 95.1%. The cumulative success rate of FPD and RBB was 84.0%. When conventional FPDs were assessed independently of RBBs, however, the 60-month success rate for FPDs was 94.0%. The higher failure/complication rate noted for RBBs is in agreement with that reported by Pjetursson and colleagues<sup>2</sup> in 2008. These investigators conducted a meta-analysis of 93 articles and reported an estimated survival rate for RBBs of 87.7% after 5 years. Failures of RBBs were most often due to debonding or recurrent caries.

Failures of FPDs were most frequently attributed to caries, periodontal disease, and endodontic pathology. Failures of retention and abutment fracture were also noted.

Valderhaug<sup>3</sup> assessed the status of crowned teeth over 25 years and noted caries, endodontic involvement, and periodontics pathology as the primary causes of complications with or without tooth loss.

The principal causes of implant loss or a failing implant, as defined by Albrektsson and colleagues<sup>4</sup> criteria, were failure to osseointegrate following initial insertion, progressive bone loss in the face of persistent inflammation, or mechanical overload. Other complications that did not lead to implant loss included abutment loosening/fracture and crown fracture.

Salinas and Eckert<sup>1</sup> noted higher failure rates in data reported in older studies. The significance of this observation is subsequently discussed.

A meta-analysis of 5- and 10-year survival rates of FPDs and SICs was performed by Pjetursson and colleagues.<sup>5</sup> This meta-analysis included cantilevered FPDs and implant-supported FPDs. The estimated 5-year survival rates for FPDs, cantilevered FPDs, and SICs were 93.8%, 91.4%, and 94.5%, respectively. The estimated survival rates after 10 years of function for FPDs, cantilevered FPDs, and SICs were 89.2%, 80.3%, and 89.4%, respectively.

Attempts to compare 5 and 10 years' cumulative success rates of FPDs and SICs in a tooth-bounded space are complicated by a number of factors in addition to the lack of studies performing direct comparisons between the two treatment modalities.

The assessment of older studies, which may have employed techniques and materials that differ significantly from those currently used, must be undertaken with great caution. There is no doubt that today's restorative dentist has a greater number of options available for tooth preparation techniques, restorative materials, and cementation than in the past. The field of implant therapy has evolved at least as quickly as that of restorative dentistry in general. In addition to the use of a wider variety of implant diameters, lengths and morphologies, implant surface technology has dramatically altered many of the basic tenants of implantology. The time necessary to attain osseointegration has been significantly shortened, and the initial strength of the osseointegrative bond has been dramatically increased. Most germane to this discussion is that implant success and survival rates have been reported for rough-surface implants that are significantly higher than those previously reported for their smooth-surface counterparts.<sup>6-9</sup> Success rates for rough-surface implants exceed those in the meta-analyses already discussed for FPDs and SICs.

Finally, the understanding of implant capabilities in the face of various load applications and inflammatory insults continues to evolve. There is no doubt that older studies often reported on implants placed in less than ideal situations because of limitations in available bone and implant sizes and morphologies, or because of a more primitive

understanding of implant capabilities in various scenarios. Such considerations account, at least in part, for the lesser 5- and 10-year cumulative success rates of implants reported on in older studies, compared with studies, published within the last 3 to 4 years.

The cumulative success rates of rough-surface implants supporting single crowns are at least equal to those reported on for three-unit FPDs. The questions to be answered are when to use each treatment approach and how best to maximize treatment outcomes with each therapeutic modality.

## DIAGNOSTIC REQUIREMENTS

Before the initiation of active therapy, a thorough examination must be performed, a diagnosis made, and a comprehensive interdisciplinary treatment plan formulated. A full series of high-quality radiographs must be taken. When necessary, three-dimensional images are also used. Panoramic films are not utilized because their accuracy is insufficient for providing useful information for comprehensive therapy. The components of a thorough clinical examination, including periodontal probing depths, hard and soft tissue examination, models and face-bow records, are well established and not discussed here. It is important to realize, however, that a thorough examination begins with an open discussion with the individual patient. It is crucial that the clinician determine the patient's needs and desires. In this way, treatment plans may be formulated that are in the best interest of the patient and that represent a greater value for the patient.

Before formulating a comprehensive treatment plan, all potential etiologies must be identified and assessed. In addition to systematic factors, these etiologies include periodontal disease, parafunction, caries, endodontic lesions, trauma, and so forth.

The treating clinician should always formulate an "ideal" treatment plan and present it to the patient. Appropriate and predictable treatment alternatives must also be offered to the patient, thus allowing the patient to choose the treatment option to which he or she is best suited physically, financially, and psychologically.

Clinicians who fail to incorporate regenerative and implant therapies into their treatment armamentaria are depriving their patients of predictable therapeutic possibilities that afford unique treatment outcomes in a variety of situations.

Conversely, teeth that can be predictably restored to health through reasonable means should be maintained if their retention is advantageous to the final treatment plan. Clinicians who claim to be implantologists—performing only implant therapy while ignoring periodontal and other pathologies—do a disservice to patients. Such clinicians include practitioners who perform inadequate periodontal therapy to predictably halt the disease process or who remove teeth that could be treated through predictable periodontal techniques.

## ABUTMENT-TOOTH CONSIDERATIONS

When assessing the appropriateness of the use of specific teeth as abutments for a three-unit FPD, it is assumed that a comprehensive diagnosis has been made and a treatment plan has been formulated, that all dental disease in other areas of the mouth has been managed, and that a nonpathologic occlusal scheme has been created. In such a situation, the abutment teeth themselves must be assessed on a number of levels (**Box 1**).

**Box 1****Abutment-tooth considerations**

Overall health of the dentition  
 Occlusal stability  
 Presence of parafunction  
 Periodontal stability  
 Extent of attachment loss  
 Restorative margin position related to the gingival margin  
 Clinical crown available for preparation  
 Amount of tooth remaining following caries excavation  
 Amount of tooth remaining following preparation  
 Need for endodontic therapy  
 Ability to perform endodontic therapy  
 Amount of tooth remaining following endodontic therapy  
 Presence of adequate keratinized tissue

***Periodontal Stability***

Pocket depths beyond 3 mm are nonideal. Pocket depths of 5 mm or greater should be considered problematic, if not pathologic. Periodontal pockets are recognized as complicating factors in thorough patient and professional plaque control. Waerhaug<sup>10</sup> demonstrated that flossing and brushing are only effective to a depth of about 2.5 mm subgingivally. Beyond this depth, significant amounts of plaque remain attached to the root surface following a patient's oral hygiene procedures. Professional prophylaxis results are also compromised in the presence of deeper pockets. The failure of root planing to completely remove subgingival plaque and calculus in deeper pockets is well documented in the literature.<sup>11–15</sup> Through the examination of extracted teeth that had been root planed until they were judged plaque-free by all available clinical parameters, Waerhaug<sup>10</sup> demonstrated the correlation between pocket depth and failure to completely remove subgingival plaque. Instrumentation of pockets measuring 3 mm or less was successful (with regard to total plaque removal) in 83% of the cases. In pockets of 3 to 5 mm in depth, 61% of the teeth exhibited retained plaque after thorough root planing. When pocket depths were 5 mm or more, failure to completely remove adherent plaque was the finding 89% of the time. Tabita and colleagues<sup>16</sup> noted that no tooth demonstrated a plaque-free surface 14 days after thorough root planing when the pretreatment pocket depths were 4 to 6 mm, even in situations in which patients exhibited excellent supragingival plaque control. This is not the forum in which to discuss pocket elimination periodontal surgical therapy. However, care must be taken to ensure no probing depths in excess of 3 to 4 mm are present around potential abutment teeth.

Furcation involvements must also be assessed and eliminated through resection or regeneration if teeth are to be considered good candidates to serve as abutments for an FPD. Periodontally involved furcations cannot be predictably "maintained" through root planning, curettage, and repeated maintenance care sessions. In a longitudinal study of patients who refused active periodontal therapy and who underwent only continuing maintenance care, Becker and colleagues<sup>17</sup> reported an overall rate of tooth loss of 9.8% in the mandible and 11.4% in the maxilla. The same patients

demonstrated a rate of tooth loss of 22.5% for mandibular furcated teeth and 17% for maxillary teeth with furcation involvements.

Goldman and colleagues<sup>18</sup> assessed tooth loss in 211 patients treated in periodontal private practices and maintained for 15 to 34 years on a 3- or 6-month recall schedule. Patients were treated with root planning, curettage, and open-flap debridement. Furcation involvements were not eliminated. The overall rate of tooth loss experienced over the course of patient care was 13.4%. However, the incidence of tooth loss of maxillary and mandibular teeth with furcation involvements was 30.7 and 24.2%, respectively. Teeth that exhibited furcation involvements were lost at a greater rate than nonfurcated teeth.

McFall<sup>19</sup> reported on tooth loss in 100 treated patients who had periodontal disease and were maintained for 15 years or longer following active periodontal therapy. Therapy did not eliminate furcation involvements: 11.3% of all teeth were lost over the course of observation. Maxillary teeth that demonstrated furcation involvements were lost at a rate of 22.3%. Mandibular furcated teeth were lost at a rate of 14.7%. Similar findings are repeated throughout the literature.<sup>20-22</sup>

A study by Fleisher and colleagues<sup>23</sup> underscored the inability to adequately debride a periodontally involved furcation with curettes and ultrasonic instrumentation. Fifty molars were treated through closed curettage or open-flap debridement. All teeth were treated by experienced operators. The teeth were then extracted and stained for the presence of plaque and calculus. Assessment of the extracted and stained teeth demonstrated that only 68% of the tooth surfaces facing the involved furcation were plaque- and calculus-free.

Although there is no doubt that the use of microscopy and appropriate instrumentation greatly improves on this level of efficacy of furcation debridement, the three-dimensional structure of the involved furcation remains. The net result is repopulation of this area by plaque, and re-initiation of a periodontal inflammatory lesion in the area. Such an approach “slows down” the progression of bone and attachment loss and may prove valuable in an older patient, or in one who does not wish to undergo more comprehensive therapy. Most situations, however, require therapy to be aimed at eliminating the periodontally involved furcation and providing the patient with a milieu amenable to appropriate plaque-control efforts.

The treatment approach chosen, whether it is resection, regeneration, a combination of resection and regeneration, or tooth removal and implant placement, depends upon the involved furcation morphology.

### ***Extent of Periodontal Attachment Loss***

---

Following comprehensive periodontal therapy, abutment teeth should demonstrate a lack of probing beyond 3 mm and no furcation involvements. When active periodontal disease has been treated, however, varying degrees of supporting bone and attachment loss will have occurred. In severe cases, the tooth demonstrates mobility due to secondary occlusal trauma, defined as the development of mobility under normal load application due to reduced periodontal support. Teeth demonstrating such mobility may be ill suited to serve as abutments for a three-unit FPD.

### ***Restorative Margin Position Related to the Gingival Margin***

---

Restorative margin position may also influence long-term periodontal health. Plaque accumulation at the restorative margin-tooth interface is a consistent finding in research and in clinical practice.<sup>24-31</sup> When this margin is subgingival, the resultant increased plaque accumulation often leads to acceleration of periodontal breakdown and recurrent caries.<sup>31</sup> Appropriate preparation of the periodontium for restorative

dentistry, including management of supporting bone, covering soft tissues and the tooth–bone interface, has been discussed in detail.<sup>32</sup>

### ***Clinical Crown Available for Preparation and the Development of Appropriate Retention/Resistance Form***

---

A detailed discussion of related concepts and techniques may be found elsewhere.<sup>32</sup> It is imperative that an assessment of the need or the lack of need for such therapy is completed before determining a final course of treatment, because such an assessment has a direct bearing on the physical and financial impacts of care.

### ***The Need for Endodontic Therapy***

---

In addition to impacting the financial ramifications of care when the tooth in question is to serve as an abutment for an FPD, the influence of endodontic therapy on the long-term prognosis of the tooth must be considered. Can endodontic therapy be performed appropriately? Will the residual tooth structure following endodontic therapy be sufficient to withstand load application over time as an abutment for a three-unit FPD? Areas of specific concern are two rooted maxillary first bicuspid following endodontic therapy are of specific concern, because the residual tooth structure in the isthmus of the tooth may be highly prone to fracture; and the aspect of the mesial buccal root of a lower molar that faces the furcation. The ribbon shaped nature of this root also renders it highly susceptible to perforation during endodontic therapy, or fracture at the time of post preparation or insertion, or in subsequent function.

### ***The Presence of an Adequate Band of Attached Keratinized Tissue***

---

Although a number of studies exist that assess the ability to maintain periodontal health in the face of minimal bands of attached keratinized tissue, none of these studies takes into account the added inflammatory insult placed on the periodontium when a restorative margin is placed intrasulcularly. All restorative margins trap some degree of plaque at the restorative margin tooth interface. Therefore, it is prudent to ensure that a stable band of attached keratinized tissue is present to help afford a “fiber barrier,” which, in conjunction with an attachment apparatus consisting of approximately 1 mm of connective tissue attachment and a short junction of epithelium (~1 mm or less), helps prevent the initiation and propagation of periodontal disease in the area. Such a band of attached keratinized tissue, in addition to having sufficient thickness to prevent recession in the face of inflammation, trauma, or both, must demonstrate an apico coronal dimension of at least 3 mm. In the best of situations, the aforementioned short junctional epithelium and connective tissue attachment will have a dimension of 2 mm. Therefore, it is only when a third millimeter of attached keratinized tissue is present that the aforementioned “fiber barrier” overlays the alveolar bone crest.

## **IMPLANT RECEPTOR SITE CONSIDERATIONS**

When contemplating implant placement, a number of site-specific considerations must be assessed (**Box 2**). These considerations include not only the quantity and quality of available bone for implant placement, but also the position of such bone. When adequate bone is present to place an implant but such placement will result in a nonideal implant position/angulation from a restorative or force distribution point of view, the bone that is present must be classified as inadequate. A comprehensive patient workup must include appropriate diagnostic wax-ups, to allow assessment of ideal implant position and dimension when necessary. The role of implant length and width in long-term success is often misunderstood. The misconceptions that “longer

**Box 2****Implant receptor site considerations**

Overall periodontal stability  
Overall restorative stability  
Overall occlusal stability  
Quantity of available bone  
Quality of available bone  
Position of available bone  
Potential encroachment on vital structures

implants are better” and that the maximum-sized implant should be placed whenever possible lead to the need for a greater degree of augmentation therapy and possible encroachment on vital structures.

**THE ROLE OF IMPLANT DIMENSION IN LONG-TERM SUCCESS**

Crown-to-root ratios and Ante’s law are considered cornerstones of treatment planning periodontally healthy and periodontally compromised patients who require prosthetic intervention. The “normal” values for the crown-to-root ratio are 0.60 for maxillary teeth and 0.55 for mandibular teeth. It is important to realize, however, that such numbers are not an indicator of periodontal health or of the absence of periodontal attachment loss around teeth. When excessive wear has occurred and attachment loss is present, the crown-to-root ratio could still be within the normal range. Therefore, a normal crown-to-root ratio should not be interpreted as an indicator of a periodontally healthy situation.

After the introduction of osseointegrating implants to the dental community, it was assumed that longer implants would be more advantageous because they would present a greater surface area for potential osseointegration and a more favorable lever arm following force application. Such a belief seemed to be borne out in early studies documenting the use of machined-screw Brånemark implants (Waltham, Massachusetts).<sup>33–36</sup> It is important to realize that all these studies were performed on smooth-surface hex-topped implants.

The use of shorter implants significantly impacted the development of appropriate treatment algorithms and the delivery of care. Shorter-implant use allowed the clinician to avoid vital structures such as the sinus floor and the inferior alveolar canal. Their use also eliminated the need for augmentation therapy in many situations. Even when augmentation was still required, a simpler procedure was necessary than for placement of longer implants in the same situation. Unfortunately, the use of shorter implants, has long been viewed as a compromise in patient care.

Do the available finite element analyses and clinical studies support the use of shorter implants to attain treatment outcomes comparable to those attained using longer implants?

Lum<sup>37</sup> found that occlusal forces were distributed primarily to the crestal bone regardless of implant length and were well tolerated by the crestal bone. Parafunctional forces, were not well tolerated by the crestal bone, leading Lum to state that parafunctional forces must be attenuated. Lum<sup>37</sup> also suggested the use of wider implants and a greater number of implants in patients demonstrating a significant parafunctional habit.

Pierriesnard and colleagues<sup>38</sup> performed a finite element analysis on 3.75-mm wide hex-headed screw implants with lengths of 6 mm, 7 mm, 8 mm, 9 mm, 10 mm, 11 mm, and 12 mm, and found that the magnitude and distribution of bone stress was constant and independent of implant length.

Lai and colleagues<sup>39</sup> applied 35 newton centimeters (Ncm) of vertical load to implant cylinders and found that the greatest stress was always concentrated at the neck of the implant. Peak stress was independent of implant length, but it was inversely proportional to the extent of osseointegration.

Holmgren and colleagues<sup>40</sup> reported that implant length had no effect on peak stress magnitude or stress distribution. Stress was concentrated at the bone crest regardless of implant length.

Himmlova and colleagues<sup>41</sup> also found that the greatest force concentration upon force application was always at the bone crest.

The preponderance of finite element analyses demonstrates that peak stresses are always found at the bone-implant interface at the bone crest and are independent of implant length.

## CLINICAL STUDIES

Buser and colleagues<sup>7</sup> demonstrated no difference in implant success rates between shorter and longer lengths in an 8-year life table analysis of 2359 titanium plasma-sprayed Straumann implants (Andover, Massachusetts).

Feldman and colleagues<sup>42</sup> examined 5-year survival rates of 2294 rough-surface Osteotite implants (West Palm Beach, Florida) and 2597 smooth machine-surfaced implants. The difference in cumulative success rates between shorter and longer, rough-surfaced implants was 0.7% and was not statistically significant. The difference in cumulative success rates for smooth-surface implants when assessing implant length was 2.2%, which was statistically significant. Implant surface must be considered in the decision to use shorter implants in various clinical situations.

Deporter and colleagues<sup>43</sup> documented the survival rates of 46 mandibular overdentures, each supported by three short Endopore implants (Toronto, Ontario, Canada). The cumulative implant survival rate 5 to 6 years post therapy was 93.4%.

A publication assessing the clinical results of 5526 Straumann implants documented the use of implants of different lengths in a variety of clinical applications.<sup>6</sup> The implants were followed for a minimum of 72 months in function. The mean time in function was 32 months. Implant length had no influence on the reported cumulative success rates.

Anitua and colleagues,<sup>9</sup> in a retrospective study examining 532 implants of between 7 and 8.5 mm in length with a diameter of 3.3 to 5.5 mm, demonstrated a cumulative survival rate of 99.2%.

Even in the face of a large number of studies supporting the high long-term success rates of shorter implants, another question remains. If the patients in the aforementioned studies were reconstructed at a reduced vertical dimension due to the severity of their oral health problems, a crown-to-“root” ratio approaching the “ideal” numbers quoted for the natural dentition would have resulted. Therefore, the influence of the crown-to-implant ratio on implant success and failure rates must be examined.

Rokni and colleagues<sup>44</sup> examined 199 implants that had been restored with fixed prostheses. Implant length ranged from 5 to 12 mm. The mean crown-to-implant ratio was 1.5. The implants were in function for an average of 4 years. Crown-to-implant ratio and implant length had no effect on the supporting bone levels around the implants.

Tawil and colleagues<sup>45</sup> assessed 262 machined-surfaced Branemark implants in function for a mean time of 53 months, and they found no relationship between crown-to-implant ratio and peri-implant bone loss or implant success/failure rates.

Blanes and colleagues,<sup>46</sup> in a 10-year prospective study of Straumann implants placed in the posterior maxilla, reported no influence of crown-to-implant ratio on implant success in function. A recent publication documenting long-term success of 2073 implants of 6 to 9 mm in length in various applications demonstrated a cumulative success rate of 98.1% to 99%, depending on the clinical application, over a mean time in function of 36.2 months.<sup>47</sup>

If shorter implants are to succeed in function, they must be employed within the parameters already discussed, including appropriate diagnosis and case workup, development of a comprehensive treatment plan, and amelioration of parafunctional forces.

In addition, appropriate regenerative therapy must be performed to determine the need or the lack of need for regenerative therapy to allow placement of an implant of ideal diameter for the tooth to be replaced (Figs. 1–3). It is imperative that implant diameter not be chosen by the available bone. Rather, an implant diameter should be selected that is ideal for the tooth to be replaced. After this implant diameter has been chosen, it must be positioned ideally on the model, as determined by the diagnostic wax-up/surgical stent. It is only at this point that a determination is made of whether regenerative therapy is required. Adequate bone must be present or regenerated to ensure buccal and palatal/lingual bone thickness of at least 2 mm following implant placement. Failure to provide such a thickness of bone significantly increases the chances of bone resorption and implant body exposure under function over time.

Fig. 4 demonstrates a patient who presented missing a maxillary central incisor. Flap reflection revealed a fairly atrophic residual alveolar ridge. Although adequate bone was present to allow implant placement within the remaining alveolar bone, such placement would have represented a threefold compromise. Because the alveolar ridge was deficient, a soft tissue graft would have been necessary to improve the final esthetic treatment outcome. More important, the implant would have been placed off angle and subjected to traumatic off-axis loading. Hsu and colleagues<sup>48</sup> assessed off-angle loading at 0°, 30° and 60° using finite element analyses. They demonstrated that, for each 30° increase in off-angle loading, stress to the crestal bone increased

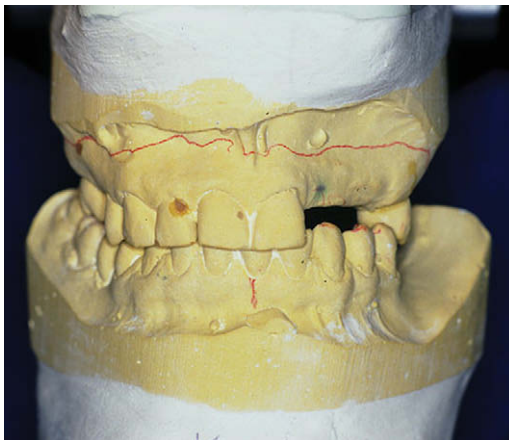
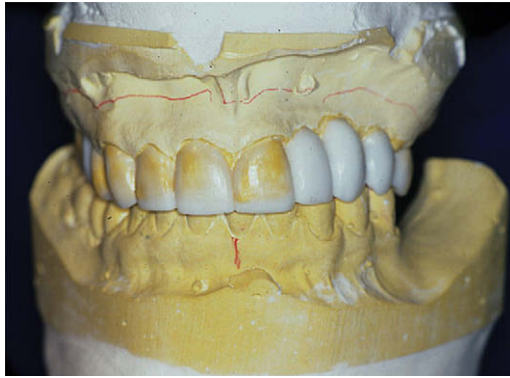


Fig. 1. Face-bow mounted models demonstrate the maxillary hard and soft tissue deficiencies that must be managed if appropriate implant reconstructive therapy is to be performed.



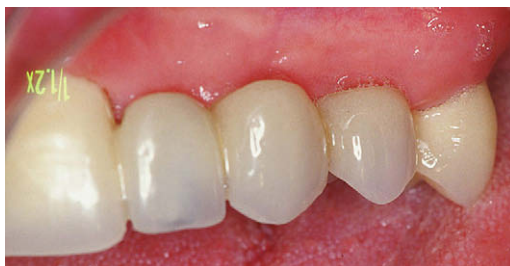**Fig. 2.** A diagnostic wax-up was performed on the face-bow mounted models. The wax-up can be cut now back to the desired level so that a temporary fixed prosthesis can be fabricated, which will also serve as a regenerative guide.

three to four times. Finally, an implant of a narrower than ideal diameter would have been placed, resulting in less surface area for potential osseointegration at the bone crest, the area subjected to the greatest stresses. These stresses, in turn, would be magnified due to the off-angle loading that would occur.

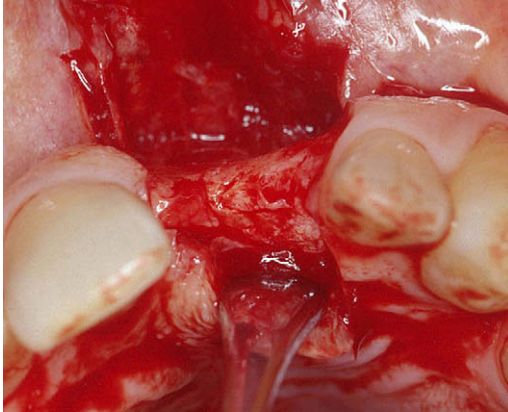
To avoid these problems, appropriate regenerative therapy was performed using particulate graft material beneath a titanium-reinforced Gore-Tex membrane. The net result was an ideal ridge form that allowed placement of an implant of the desired diameter in a restoratively driven position (**Fig. 5**).

In addition to choosing implant diameter by the dimension of the tooth to be replaced, the implant chosen should demonstrate a rough surface and an internal abutment connection. The advantages of rough-surface implants as opposed to their smooth-surface counterparts have already been discussed. Meadd and colleagues<sup>49</sup> applied 30 Ncm of vertical and horizontal load to implants with internal or external abutment connections. Increased strain at the cervical area was noted around external abutment connection fixtures compared with internal abutment connection implants. Load also was found to be better distributed around internal connection implants than around external connection implants.

The use of wider implants has been called into question by a number of investigators. Ivanoff and colleagues<sup>50</sup> found a significant relationship between wider implant diameters and implant failure. Eckert and colleagues<sup>51</sup> found a higher failure rate of



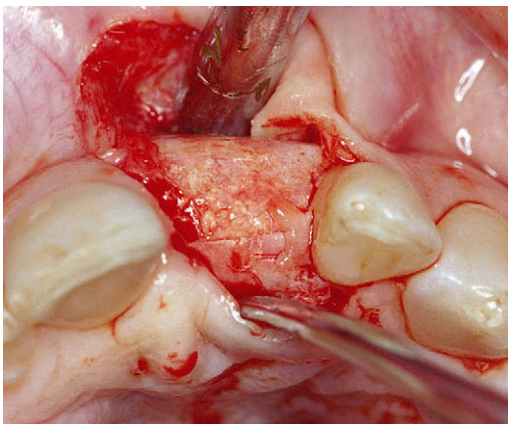
**Fig. 3.** Following regenerative therapy, hard and soft tissues are rebuilt to the desired levels in anticipation of implant placement and restoration.



**Fig. 4.** A patient presented with a severely atrophic alveolar ridge in the area of a missing central incisor.

wide-diameter implants as opposed to 3.75-mm diameter implants. Shin and colleagues<sup>52</sup> reported a statistically significant higher failure rate of wider diameter implants compared with standard-diameter implants. However, such a finding may be due to a number of factors, including the necessary learning curve when placing wider-diameter implants and the need to minimize thermal and mechanical damage to the cortical bone during preparation. Equally important is assurance that adequate bone will remain on the buccal and palatal/lingual aspects of the implant to attain osseointegration and maintain itself under function. As already discussed, such a concern may mandate regenerative therapy even when no implant exposure is noted following placement.

Bischof and colleagues,<sup>53</sup> in a 5-year life table analysis of 263 wide-neck implants, reported a cumulative success rate of 94.3% for the SICs and of 96.21% for the FPDs in the study.



**Fig. 5.** The region was treated using Bio-Oss (Luitpold, Shirley, New York) and a fixed, titanium-reinforced Gore-Tex covering membrane. Note the ideal ridge form that has been attained to facilitate appropriate implant placement.

Mericske-Stern and colleagues<sup>54</sup> reported a 5-year cumulative survival rate of 99.1% for wide-neck implants supporting single crowns.

An implant design may also be used that is characterized by a 4.8-mm-wide body with parallel walls, which broadens to a 6.5-mm-wide platform supracrestally (**Fig. 6**). Such a design helps maintain bone buccally and palatally/lingually to the implant if the implant is placed in a ridge that has undergone resorption, atrophy, or both following tooth removal. The use of a more conventional tapered, wide-platform implant design, which begins to flare to its final restorative platform subcrestally necessitates removal of a greater amount of bone, resulting in a lesser dimension of bone buccally and lingually/palatally following placement (**Fig. 7**). Such a situation is inherently less stable under function.

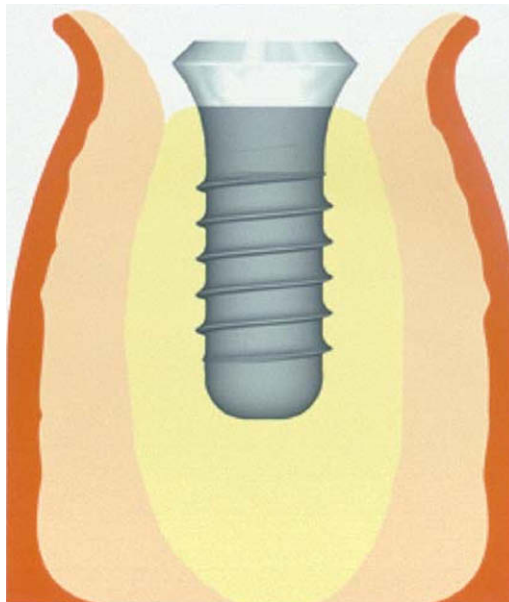
When used appropriately, short implants afford a predictable means of replacing missing teeth in the least traumatic manner possible for patients (see **Fig. 6**).

#### UNDERSTANDING THERAPEUTIC POSSIBILITIES

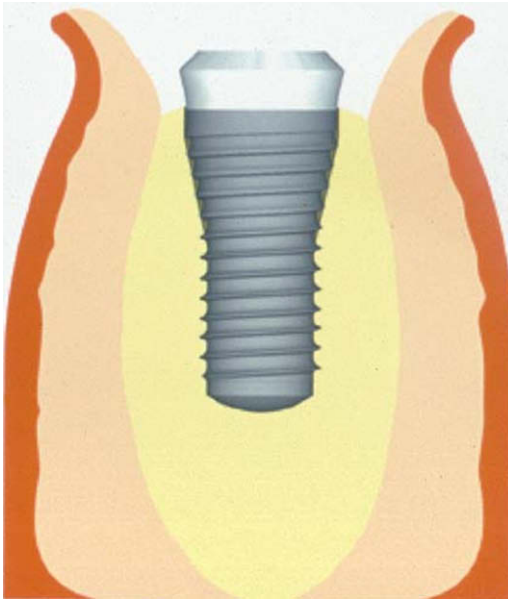
Before developing treatment algorithms, it is important to be fluent in all therapeutic options for a given situation. Advances in regenerative therapy, adjunctive surgical procedures, and implant design afford the opportunity to simplify and shorten the course of therapy when faced with scenarios previously thought to be complex in nature. Three of these areas have direct bearing on the topic under discussion.

#### *Tooth Replacement at the Time of Maxillary Molar Extraction*

The ability to place an implant at the time of maxillary molar removal offers a number of advantages, including fewer surgical insults to the patient, a shorter course



**Fig. 6.** Placement of a 4.8-mm-wide parallel-walled body implant with a restorative platform that expands to 6.5 mm supracrestally preserves the maximum amount of bone on the buccal and lingual/palatal aspects of the implant.



**Fig. 7.** Placement of a tapered implant, which begins to broaden to the final restorative platform subcrestally, results in thinner bone buccally and lingually/palatally than when using the implant design demonstrated in **Fig. 6**.

of therapy, avoidance of postextraction alveolar bone resorption and the subsequent need for regenerative therapy, and a lower overall cost of therapy. Such treatment, however, should be performed only when an ideal implant position will result.

When implant placement is to be effected at the time of maxillary molar tooth extraction, it is imperative that an implant of ideal diameter be placed in a restoratively driven position. This is easily accomplished through specific surgical techniques. It must be realized, however, that adequate interradicular bone must be present for manipulation in such a manner as to secure the implant in an ideal position following its placement. When the implant may not be so placed, augmentation must first be performed using particulate graft material and the appropriate covering membrane. The implant is placed in an ideal position following maturation of the regenerating bone (**Figs. 8–10**).

When adequate bone is present to secure the implant in an ideal position, the implant is placed at the time of maxillary molar trisection and extraction, with or without concomitant implosion of the floor of the sinus to attain additional height for the planned implant (**Figs. 11–13**).

A patient presented with a hopeless maxillary first molar and radiographic evidence of significant periapical pathology (**Fig. 14**). Following tooth removal, defect debridement, and manipulation of the interradicular bone, an implant with a 4.1-mm base and a 6.5-mm-wide restorative platform was placed. Concomitant regenerative therapy was performed (**Fig. 15**). The implant was subsequently restored with an abutment and cemented crown. After 5+ years in function, the crestal peri-implant bone is stable radiographically (**Fig. 16**).

Using this approach, 391 implants were placed at the time of maxillary molar extraction.<sup>55</sup> A cumulative success rate of 99.5% was reported after a mean time in function of 30.9 months.

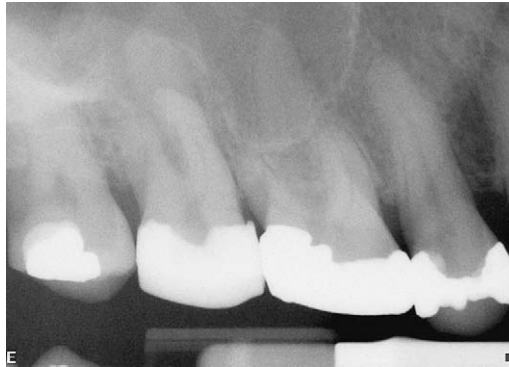

Fig. 8. A patient presented with a hopeless prognosis for a maxillary right second molar.

**Figs. 17–20** demonstrate a different course of therapy. A patient presented with a hopeless maxillary left first molar and a buccal fistula that had destroyed the buccal plate of bone and a significant portion of the interradicular bone (**Fig. 17**). The tooth was extracted, the defect debrided, and the interradicular bone imploded using a previously published technique.<sup>56</sup> Particulate graft material and a titanium membrane were used to effect bone regeneration (**Fig. 18**). An implant was subsequently placed in the imploded and regenerated bone (**Fig. 19**). The implant has been in function for over 5 years following restoration with an abutment and crown. A radiograph demonstrates the stability of the peri-implant crestal bone (**Fig. 20**).

#### ***Implant Placement at the Time of Mandibular Molar Extraction***

When adequate bone is not present to secure the appropriate-diameter implant in a restoratively driven position, augmentation is performed, and an implant is subsequently placed and restored. When sufficient interradicular bone is present, however, it may be manipulated in such a manner as to secure the implant in the desired position. Concomitant regenerative therapy is then performed, as was described for the maxillary arch. When an implant is to be placed at the time of mandibular molar extraction,

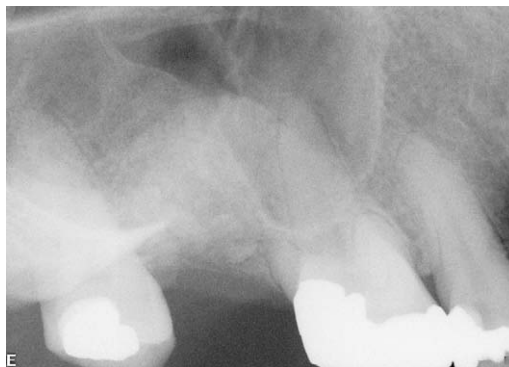
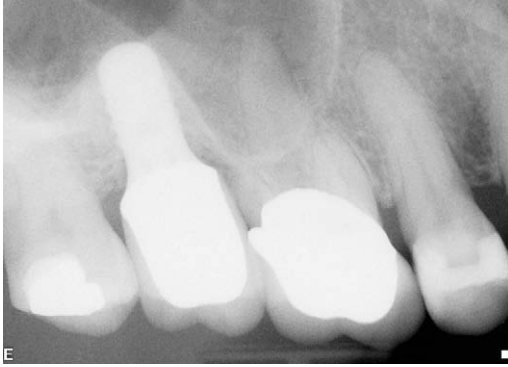
Fig. 9. Six months following tooth extraction and appropriate interradicular bone core implosion and regenerative therapy, marked bone regeneration in the extraction socket and preservation of the interproximal bone on the adjacent teeth are evident.

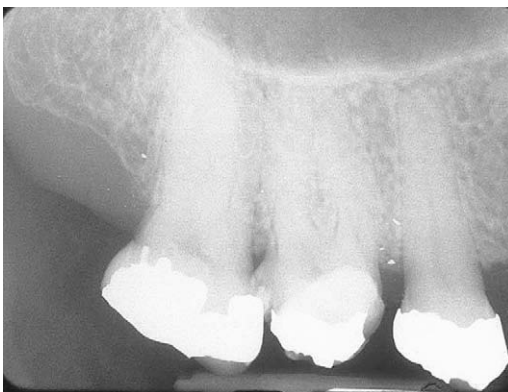

**Fig. 10.** A radiograph taken 5+ years after implant restoration demonstrates stable peri-implant hard tissues.

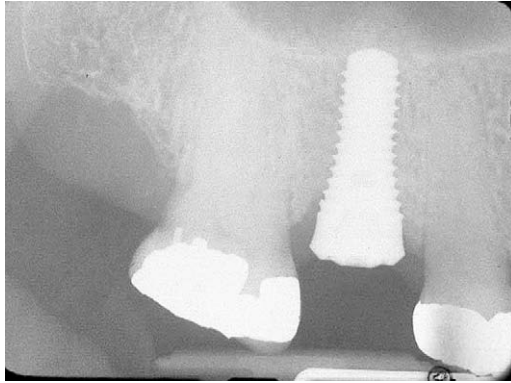
the tooth is hemisected, each root is removed individually, and any inflammatory lesions that are present are debrided. An initial osteotomy is made into the interradicular bone and a guide pin is placed (**Fig. 21**). Following the use of a differential pressure osteotomy preparation technique, a parallel-walled implant with a 4.8-mm-wide body and a 6.5-mm-wide restorative platform is placed and secured by the interradicular bone (**Fig. 22**). Concomitant regenerative therapy is performed. The implant is restored with an abutment and crown following completion of bone regeneration and osseointegration. After 5+ years in function, stable peri-implant crestal bone levels are evident (**Fig. 23**).

#### ***Augmentation of the Edentulous Posterior Maxilla***

Sinus augmentation therapy, with or without concomitant buccal/palatal ridge augmentation, is a highly predictable technique by which to gain adequate bone for ideal



**Fig. 11.** A patient presented with a vertically fractured maxillary first molar. Radiographically, inadequate bone appears to be present for implant placement at the time of tooth removal. However, the radiograph shows only the bone between the buccal roots and gives no indication of the quantity of bone between the buccal roots and the palatal root.



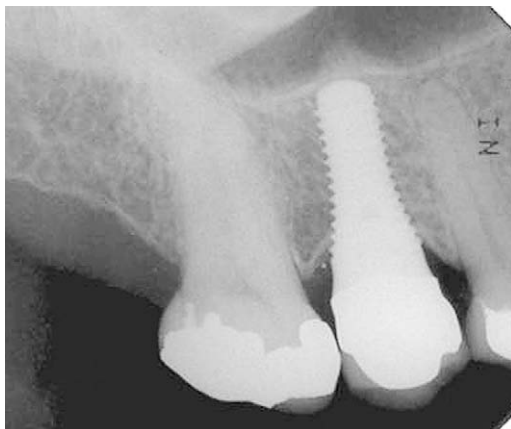
**Fig. 12.** A radiograph taken 6 months post interradicular bone manipulation and implosion, implant placement, and concomitant regenerative therapy demonstrates complete bone fill around the implant.

positioning of appropriate-diameter implants. However, such therapy involves a moderately invasive surgical procedure and significant protraction of the course of therapy.

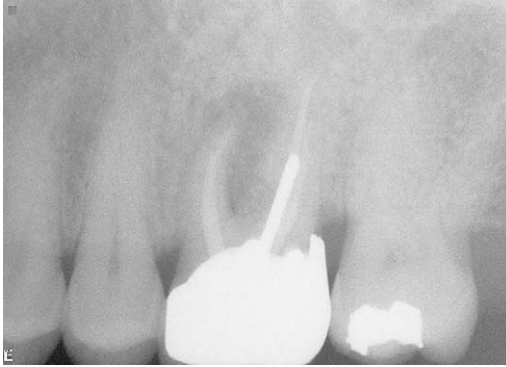
In many situations, a simpler treatment alternative exists. First developed by Summers,<sup>57</sup> osteotomes may be used in conjunction with grafting materials to implode the floor of the sinus. This technique has proved highly predictable, within limits.

Coatoam and Krieger<sup>58</sup> placed 89 implants in osteotome-lifted sinuses of 77 patients and reported a 92% cumulative success rate of implants in function for 6 to 42 months. The length of the implant and implant success were not evaluated in relation to residual alveolar bone crestal to the floor of the sinus preoperatively. In addition, no effort was made to document the gain in apical alveolar bone height.

Zitzmann and Scharer<sup>59</sup> placed 59 implants in osteotome-lifted sinuses of 20 patients and reported a 95% cumulative success rate for the implants in function for 30 months. An apical alveolar bone height gain of 3.5 mm was reported following the osteotome procedure. The investigators stated that a minimum of 6 mm of residual



**Fig. 13.** A radiograph taken 7 years post restoration demonstrates stable peri-implant bone levels.



**Fig. 14.** A patient presented with a fistulating and hopeless maxillary first molar.

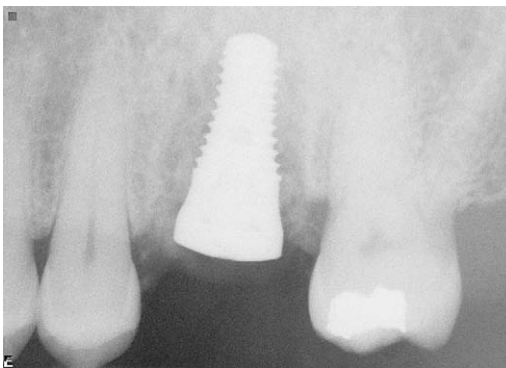
bone crestal to the floor of the sinus must be present to employ an osteotome approach with simultaneous implant placement.

Bruschi and colleagues<sup>60</sup> reported the results of 499 implants placed in 303 patients following the use of a localized management sinus floor technique and reported a cumulative success rate of 97% for implants in function for 2 to 5 years.

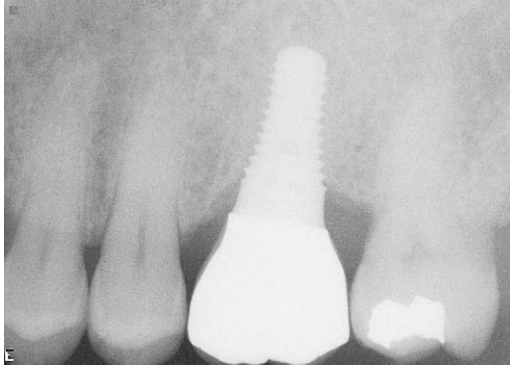
Emmerich and colleagues<sup>61</sup> performed a meta-analysis of sinus floor elevation using osteotomes in 2005. They concluded that the “short-term clinical success/survival ( $\leq 3$  years) of implants placed with an osteotome sinus floor elevation technique seems to be similar to that of implants conventionally placed in the partially edentulous maxilla.”

Ferrigno and colleagues<sup>62</sup> reported cumulative survival and success rates of 94.8% and 90.8%, respectively, in a 12-year life table analysis of 588 implants placed at the time of osteotome use and followed for a mean observation time of 59.7 months.

It is important to realize that there are limitations to this technique. All the studies in the literature that fulfill the basic criteria of reporting at least 10 cases and of documenting the residual bone present at the time of implant placement and the length



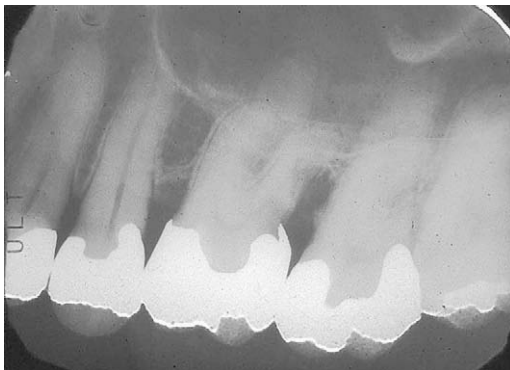**Fig. 15.** Following tooth trisection and extraction, defect debridement, and manipulation of the interradicular bone, a 10-mm long tapered-end implant with a 4.1-mm-wide “apex” and a 6.5-mm-wide restorative platform is placed. Appropriate regenerative materials may now be used.



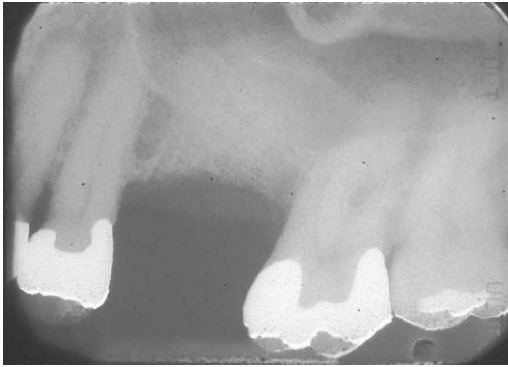**Fig. 16.** A radiograph taken 38 months after implant restoration demonstrates the stability of the crestal peri-implant bone.

of implant placed demonstrate a strict correlation between implant success and residual alveolar bone height.

This correlation is especially evident in the work of Cavicchia and colleagues.<sup>63</sup> These investigators placed 97 implants in 86 sinuses using a modification of the osteotome approach. Eight implants were mobile at uncoverly and 3 were lost in function, yielding a cumulative success rate of 88.6% after 6 to 90 months in function. Patients were treated using this approach when at least 5 mm of residual bone was present crestal to the floor of the sinus preoperatively. These investigators reported sinus displacement of 1 to 6 mm using the osteotome approach, with a mean sinus displacement of 2.9 mm apically. Six 8-mm long implants, twenty-eight 10- or 11-mm long implants, forty-seven 13-mm long implants, and sixteen 15-mm long implants were placed. Of the 8 implants mobile at uncoverly, 6 were placed in patients in whom the amount of preoperative residual alveolar bone was less than 50% of the implant length. One patient demonstrated 5 to 6 mm of preoperative residual bone and had a 10-mm implant placed. Implants 13 mm in length were placed in two patients who exhibited 9 to 10 mm of preoperative alveolar bone, and a 13-mm long implant was placed in a patient who exhibited 8 mm of preoperative alveolar bone.



**Fig. 17.** A patient presented with a buccal fistula and a hopeless prognosis for a maxillary first molar. The remaining bone protecting the mesial furcation of the second molar is at risk.

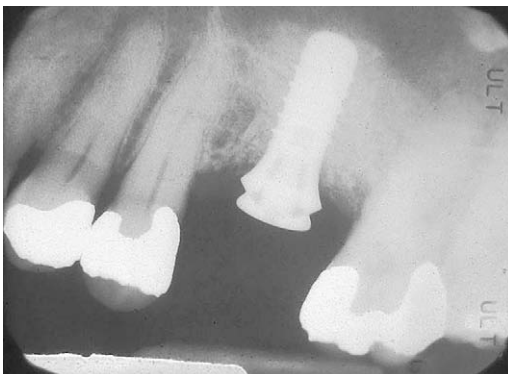

**Fig. 18.** Six months following tooth extraction, implosion of the interradicular bone, and the use of appropriate regenerative materials, bone regeneration and preservation of the bone protecting the entrance to the mesial furcation of the second molar is evident radiographically.

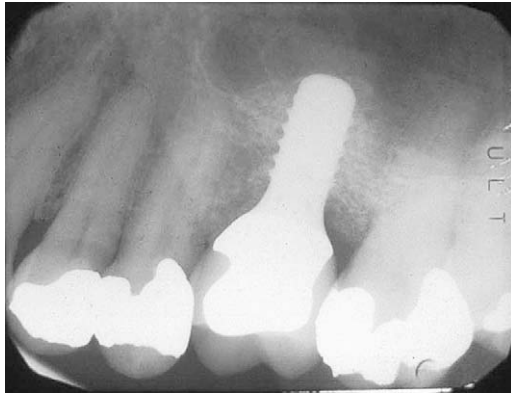
A modification of the Summers<sup>57</sup> osteotome technique is advocated that implodes a core of alveolar bone to lift the floor of the sinus.<sup>64</sup> The implant is then inserted. In this manner, the implant and the graft material never touch the sinus membrane. Rather, the core of imploded bone is further displaced by the inserting implant. This core lifts the floor of the sinus, providing an “autogenous bone buffer” between the implant and the sinus floor. In addition, this core of bone supplies autogenous bone to help hasten regeneration (**Figs. 24–26**).

This technique may be used to place an implant of  $2x - 2$  millimeters in length at the time of bone implosion, with  $x$  being the height of the residual alveolar bone crestal to the floor of the sinus.

A decision tree for augmentation of the posterior maxilla, whether it be by Caldwell-Luc sinus augmentation surgery, by osteotomes and trephines with or without simultaneous implant placement, or by a double osteotome and trephine technique with implant placement during the second entry, has been described.<sup>65</sup> It is imperative that all treating clinicians understand the capabilities of various therapeutic



**Fig. 19.** A wide platform implant is placed in the imploded and regenerated bone.



**Fig. 20.** A radiograph taken 8+ years in function demonstrates stable peri-implant crestal bone.

approaches. Although the restorative dentist will not perform the surgical therapies just described, he or she must be fluent in the limitations and applications of such treatment approaches to properly assess therapeutic and financial cost/benefit ratios for the patient and develop appropriate treatment algorithms.

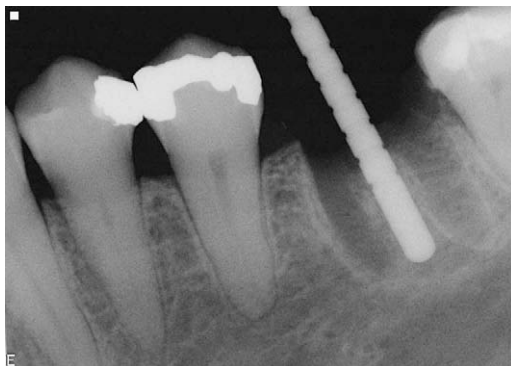#### **DEVELOPING TREATMENT ALGORITHMS TO REPLACE THE SINGLE MISSING TOOTH**

A number of factors must be considered when developing the most appropriate course of therapy for an individual patient. Naturally, the paramount consideration is the patient's well-being and overall health. If a patient is ill suited to be a surgical candidate, even for a minor procedure such as implant placement, such therapy should never be considered. In these situations, attempts should be made at placing a three-unit FPD.

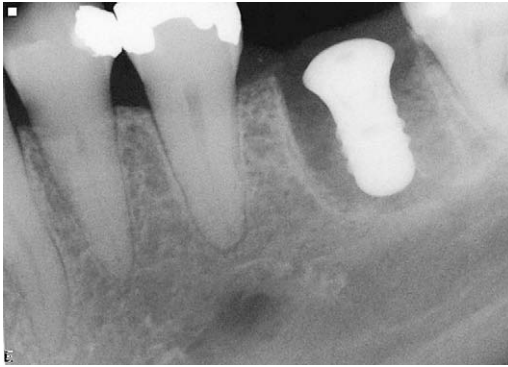Assuming that a patient is healthy, psychologically able to face each therapeutic option, and willing to proceed along the course of treatment suggested by the clinician, a number of factors must be assessed.

#### ***Cost of Therapy***

The five primary costs of therapy are biologic, esthetic, temporal, financial, and psychologic.



**Fig. 21.** Following hemisection and removal of a mandibular first molar, an osteotomy was performed in the interdental bone and a guide pin was placed.

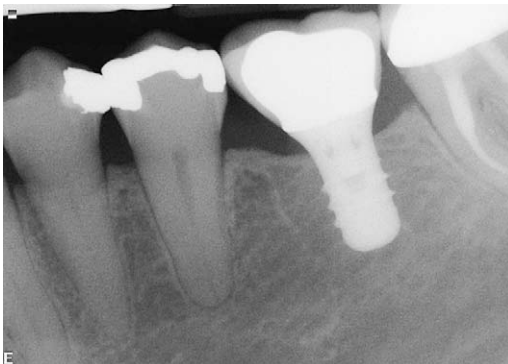

**Fig. 22.** A straight-walled implant with a 4.8-mm diameter and a 6.5-mm restorative platform diameter has been placed in the interradicular bone. Primary stability was attained. Regenerative therapy will now be performed.

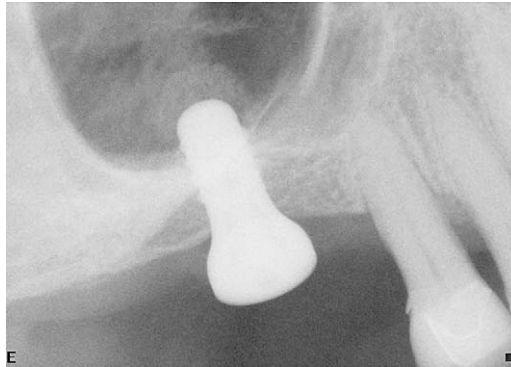### ***Biologic cost***

The biologic costs of maintaining a decayed tooth that requires crown lengthening include compromise of the tooth to be maintained and compromise of the adjacent teeth. Depending on the tooth preparation technique to be employed, 3 to 4 mm of tooth structure must be exposed between the alveolar crest and the planned position of the final restorative margin. In situations in which a patient presents with a short root form or with caries on the root surface, which would require removal of extensive amounts of osseous support, the tooth may be unduly compromised following crown-lengthening osseous surgery. When such a procedure would result in periodontal instability or the development of secondary occlusal trauma, crown-lengthening surgery should not be employed.

The effect of crown-lengthening osseous surgery on the entrance to a furcation of a multirouted tooth to be crown lengthened, and on an adjacent tooth, must also be considered. If attainment of an adequate amount of exposed tooth structure for restorative intervention and development of a healthy attachment apparatus results in the development of an untreatable furcation involvement, such a therapeutic approach is ill advised. Should a Class I furcation involvement result following crown-lengthening osseous surgery, it is easily eliminated through odontoplasty. Development of a furcation of any degree greater than Class I must be avoided.



**Fig. 23.** A radiograph taken 54 months after implant restoration demonstrates stability of the crestal peri-implant bone.



**Fig. 24.** A core of autogenous bone was implosion using a trephine and osteotome technique before implant placement.

**Figs. 27** and **28** demonstrate two patients who presented with similar clinical problems, although their specific situations mandated different treatment approaches.

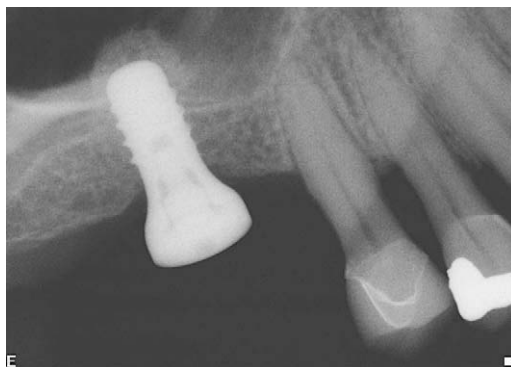#### ***Esthetic cost***

The effect of crown-lengthening osseous surgery on the patient's esthetics must be assessed. Although palatal caries on a maxillary anterior tooth may be safely exposed for restoration, the same procedure performed interproximally or buccally often results in an unacceptable esthetic treatment outcome. In such situations, other treatment options should be explored.

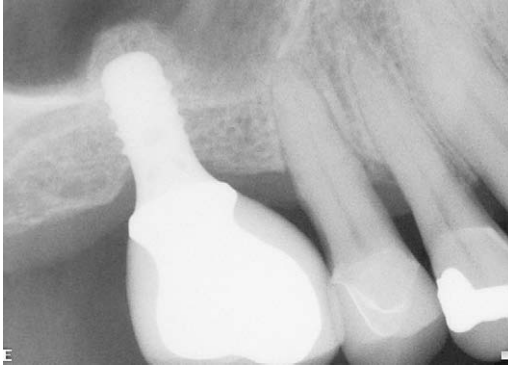
These same considerations must be taken into account when assessing potential abutment teeth. Just as a decayed tooth may be compromised by the necessary crown-lengthening osseous surgery or be rendered esthetically unacceptable, an abutment tooth may be at similar risk. When necessary crown-lengthening osseous surgery would cause an abutment tooth to be compromised, it should not be considered as an abutment, and an implant replacement approach should be used for the tooth that is missing.

#### ***Temporal cost***

If tooth retention necessitates an excessive number of visits to perform the necessary periodontal, endodontic, and restorative therapies on the abutment teeth for the



**Fig. 25.** Six months after bone implosion and implant placement, the autogenous bone is well consolidated around the "apex" of the implant.

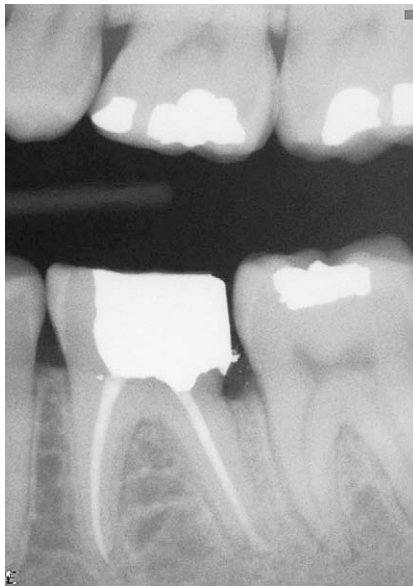

**Fig. 26.** After 6+ years in function, the crestal and “apical” bones around the implant are stable.

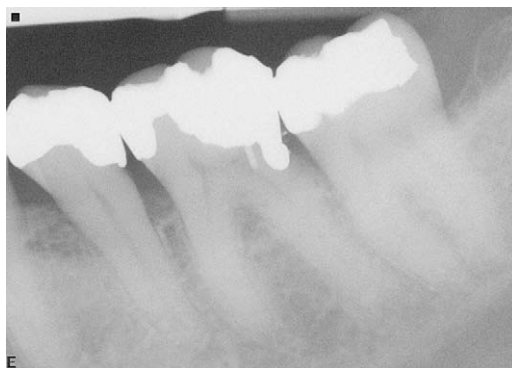planned fixed prosthesis, the patient is often better served through implant placement and subsequent restoration. Following appropriate healing, two to three restorative visits usually is required. Such a time commitment is significantly less than that necessary when multidisciplinary treatment of abutment teeth is anticipated.

#### **Financial cost**

A recent survey polled 100 dentists in various metropolitan areas throughout the United States.<sup>66</sup> The costs for assorted periodontal surgical therapies, endodontic treatment of single- and multirooted teeth, posts and cores on natural teeth, tooth extraction, implant placement, implant abutments, and implant crowns were assessed relative to a given value X (**Table 1**). Such information must be taken into account by the clinician when formulating and presenting treatment options to the patient.



**Fig. 27.** A patient presents with subgingival caries on the distal aspect of a mandibular first molar. The position and extent of this caries renders the tooth an excellent candidate for crown-lengthening osseous surgery and subsequent restoration.



**Fig. 28.** A patient presents with subgingival caries on the distal aspect of a lower first molar. The extent of apical and buccal caries renders this tooth a poor candidate for crown-lengthening osseous surgery. Such a procedure would unduly compromise the second molar and would invade the buccal furcation of the first molar.

### ***Plaque Control***

The ability of the patient to perform appropriate home care efforts is crucial to the long-term success of therapy and to the selection of the appropriate treatment modality. There is no doubt that it is easier for the average patient to perform the necessary home care around an SIC than around an FPD. Although many patients demonstrate the necessary level of home care around an FPD, this treatment approach must be considered a relative hindrance to home care efforts compared with an SIC.

### ***Retreatment Ramifications***

Finally, the commitment necessary regarding retreatment must be carefully weighed by the clinician and by the patient. When the crown of an SIC fails, it necessitates

<b>Table 1</b>	
<b>Relative fees for various therapies</b>	
<b>Therapy</b>	<b>Fee as a Factor of "X"</b>
Endodontic—single root	0.9X
Endodontic—multiple root	1.3X
Core buildup—natural tooth	0.6X
Crown—natural tooth	1.3X
Three unit FPD	4.0X
Crown-lengthening periodontal surgery	1.1X
Regenerative periodontal surgery	1.9X
Orthodontic supereruption	2.8X
Extraction	0.3X
Implant	2.1X
Implant abutment (stock) and crown	2.2X
Implant abutment (custom) and crown	2.7X
Regenerative therapy at tooth extraction	0.7X–1.4X
Sinus augmentation	2.5X
Osteotome sinus lift	0.9X
Osteotome sinus lift at time of implant placement	no charge

<b>Treatment Option</b>	<b>Advantages</b>	<b>Disadvantages</b>
Three-unit fixed bridge	Avoid implant surgical therapy Avoid vital structures Eliminate the need for regenerative therapy Slightly lesser cost of therapy than implant placement and restoration, if no endodontic therapy is required on abutment teeth	Involvement of adjacent teeth Potential for endodontic therapy Greater cost of treatment if endodontic therapy is required More difficult to perform adequate home care
Implant placement and restoration with a stock abutment and crown	No involvement of adjacent teeth Greater ease of home care Greater long-term predictability	Need to avoid vital structures Potential need for regenerative therapy Possibility of second surgical visit

replacement of the crown. Should the implant of an SIC fail, a new implant and crown are required. However, implant failure following attainment of osseointegration in a healthy patient who exhibits appropriate home care is a relatively rare occurrence.

Many clinicians advocate the use of an SIC when the teeth on either side have never been restored, citing the need to avoid involving “virgin” teeth at all costs. These same clinicians advocate use of a three-unit FPD when one or more of the adjacent teeth are heavily restored or require large restorations.

Although it is certainly logical to attempt to replace a missing tooth with an SIC if the teeth on either side have never been restored, it is illogical to cite the need for restoration of the adjacent teeth as an indication for placing a three-unit FPD. Such teeth are compromised and present with an even poorer prognosis as abutments for an FPD than previously unrestored teeth. Should one of these teeth demonstrate problems in the future, the patient would be forced to undergo more extensive, expensive treatment.

When one of the abutments of a three-unit FPD demonstrates recurrent caries, a new three-unit FPD is required. If one of the abutments fractures or becomes hopeless due to periodontal disease, a new three-unit FPD is also necessary. It also is possible that a longer-span FPD will be required, or that implant placement is necessary to effect tooth replacement in such a scenario.

<b>Treatment Option</b>	<b>Cost as a Factor of “X”</b>
Three-unit fixed bridge	4.0X
Three-unit fixed bridge with endodontic therapy and buildup on one abutment	5.5X–5.9X
Three-unit fixed bridge with endodontic therapy and buildups on two abutments	7.0X–7.4X
Implant placement, stock abutment and crown	4.3X
Implant placement, regeneration, stock abutment and crown	5.0X–6.4X

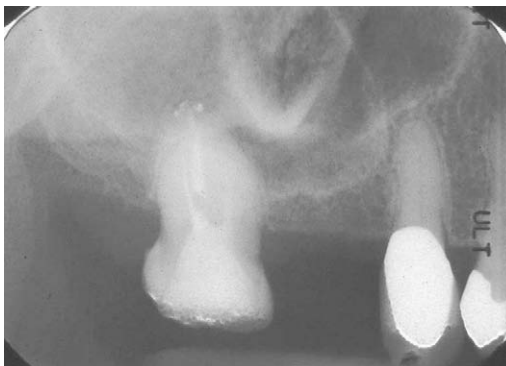
<b>Treatment Option</b>	<b>Advantages</b>	<b>Disadvantages</b>
Three-unit fixed bridge	Avoid potential regenerative therapy Slightly lesser cost of therapy Significantly lesser cost of therapy if regenerative therapy is required for implant placement	Possible need for endodontic intervention Greater difficulty in plaque control efforts Potential need for periodontal surgical therapy on the second molar Second molar is often ill suited to serve as a terminal abutment
Implant placement without regenerative therapy followed by restoration with a stock abutment and crown	No involvement of adjacent teeth No need for endodontic therapy Greater ease of plaque control efforts Greater long-term predictability	Slightly higher cost of therapy than a three-unit fixed bridge without endodontic therapy
Implant placement with concomitant osteotome use, followed by restoration with a stock abutment and crown	No involvement of adjacent teeth No need for endodontic therapy Greater ease of plaque control efforts Greater long-term predictability	Slightly higher cost of therapy than a three-unit fixed bridge without endodontic therapy
Implant placement with concomitant sinus augmentation therapy, followed by restoration with a stock abutment and crown	No involvement of adjacent teeth No need for endodontic therapy Greater ease of plaque control efforts Greater long-term predictability	Greater cost of therapy than a three-unit fixed bridge without endodontic therapy
Sinus augmentation therapy followed by implant placement at a second surgical visit, followed by restoration with a stock abutment and crown	No involvement of adjacent teeth No need for endodontic therapy Greater ease of plaque control efforts Greater long-term predictability	Greater cost of therapy than a three-unit fixed bridge without endodontic therapy Need for a second surgical visit

Treatment options for replacement of a single missing tooth other than a maxillary molar in a tooth-bounded space and the cost analysis of each treatment option are presented in **Tables 2** and **3**. The cost analyses are based on the aforementioned survey of 100 practitioners throughout the United States. The financial costs of a three-unit fixed bridge or of an implant placement and restoration with a stock abutment and crown are essentially interchangeable. However, the biologic advantages of implant use in such an area, as already discussed, are significant.

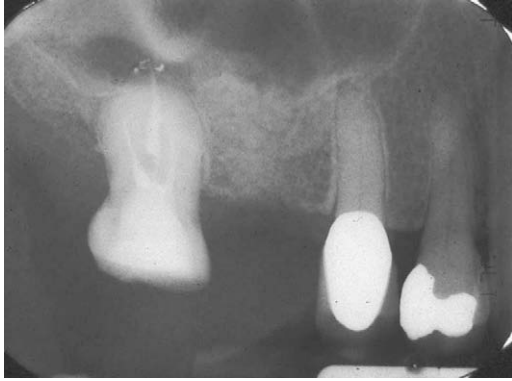
<b>Treatment Option</b>	<b>Cost as a Factor of "X"</b>
Three-unit fixed bridge	4.0X
Three-unit fixed bridge with crown lengthening surgery	5.1X
Three-unit fixed bridge with one endodontic therapy	4.9X–5.3X
Three-unit fixed bridge with two endodontic therapies	6.2X
Implant placement and restoration with a stock abutment and crown	4.3X
Implant placement with concomitant osteotome therapy and restoration with a stock abutment and crown	4.3X
Implant placement with concomitant sinus augmentation therapy and restoration with a stock abutment and crown	6.8X
Osteotome therapy followed by implant placement at a second surgical visit, followed by restoration with a stock abutment and crown	5.2X
Sinus augmentation therapy with simultaneous implant placement followed by restoration with a stock abutment and crown	6.0X
Sinus augmentation therapy followed by implant placement at a second surgical visit followed by restoration with a stock abutment and crown	6.8X

When replacing a missing maxillary molar, additional considerations come into play. Sinus pneumatization may require some type of augmentation therapy. In addition, because a wide-platform implant must be used to appropriately replace a missing maxillary molar in most situations, buccal ridge augmentation therapy may also be required. The delineation of the available treatment options and the costs attendant with each option may be seen in **Tables 4** and **5**. Because of the need for Caldwell-Luc sinus augmentation therapy with concomitant implant placement or with implant placement in a second visit, which significantly protracts the course of therapy and increases the cost of treatment, care must be taken during the diagnostic phase of therapy to ensure that a simpler, less invasive approach is not feasible.

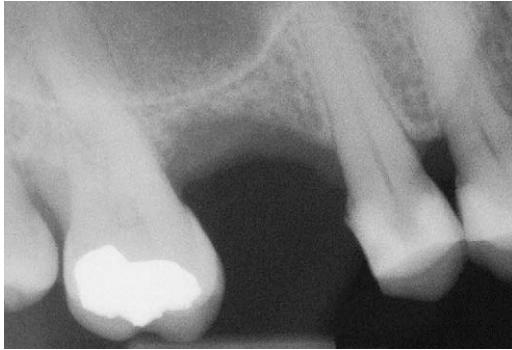Osteotomes and trephines may often be used to effect sinus floor repositioning and augmentation before implant placement (**Figs. 29** and **30**).



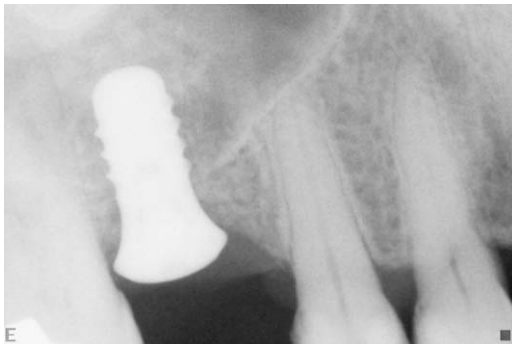
**Fig. 29.** A patient presented with inadequate bone crestal to the floor of the sinus for appropriate implant placement.



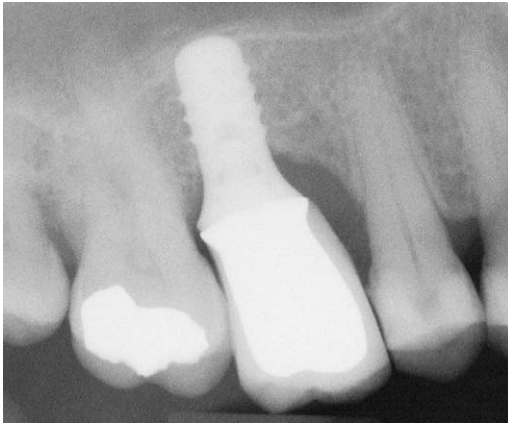
**Fig. 30.** Five months after an autogenous core of bone was imploded using the aforementioned trephine and osteotome technique, adequate bone is present for appropriate implant placement.



**Fig. 31.** A patient presented with 3.5 mm of bone crestal to the floor of the sinus. This bone is to be imploded using an osteotome and trephine technique, to a depth 1 mm less than its vertical height.



**Fig. 32.** Eight weeks after initial bone implosion, the developing bone is again imploded to a depth of 1 mm less than its vertical height. The implant is placed at this time.



**Fig. 33.** Following final healing and restoration, note the level of the repositioned sinus floor and the regenerated bone in the absence of a lateral wall sinus augmentation procedure.

Even in severe cases, a double osteotome and trephine technique may often prove feasible. When a patient presents with approximately 3 to 3.5 mm of bone crestal to the floor of the sinus and adequate buccopalatal dimension for ideal positioning of an appropriate diameter implant (**Fig. 31**), an osteotome and trephine are used to implode the bone approximately 2 to 2.5 mm. Six weeks later, the newly formed bone, which now has a vertical height of 5 to 6 mm, is again imploded to a depth 1 mm less than its vertical height. An implant is placed during this visit (**Fig. 32**). The implant may be restored with an abutment and crown approximately 8 weeks after it has been inserted. **Fig. 33** demonstrates the restored implant in function for 5+ years. This therapeutic approach is significantly less invasive and less expensive than Caldwell-Luc sinus augmentation therapy followed by implant placement.

## SUMMARY

Appropriate diagnosis and case workup followed by the development of a comprehensive interdisciplinary treatment plan is the cornerstone of conscientious care. Such an approach mandates an understanding of the therapeutic indications, contraindications, and possibilities of all available surgical and restorative treatment modalities. It is only in this manner that treatment algorithms may be formulated that best address individual patient needs.

## REFERENCES

1. Salinas TJ, Eckert SE. In patients requiring single tooth replacement, what are the outcomes of implants as compared to tooth supported restorations? *Int J Oral Maxillofac Implants* 2007;22:71–92.
2. Pjetursson BE, Tan WC, Bragger U, et al. A systematic review of the survival and complication rates of resin-bonded bridges after an observation period of at least five years. *Clin Oral Implants Res* 2008;19:131–41.
3. Valderhaug J, Jokstad A, Ambjornsen E, et al. Assessment of the periapical and clinical status of crowned teeth over 25 years. *J Dent* 1997;25:97–105.

4. Albrektsson T, Zarb G, Worthington P, et al. The long-term efficacy of currently used dental implants: a review and proposed criteria of success. *Int J Oral Maxillofac Implants* 1986;1:11–25.
5. Pjetursson BE, Bragger U, Lang NP, et al. Comparison of survival and complication rates of tooth-supported fixed dental prostheses (FDPs) and implant-supported FDPs and single crowns (SCs). *Clin Oral Implants Res* 2007;18(Suppl 3):97–113.
6. Fugazzotto PA, Vlassis J, Butler B. ITI implant use in private practice: clinical results with implants followed to 72+ months in function. *Int J Oral Maxillofac Implants* 2004;19:408–12.
7. Buser D, Mericske-Stern R, Bernard JP, et al. Long-term evaluation of non-submerged ITI implants. *Clin Oral Implants Res* 1997;8:161–72.
8. Ferrigno N, Laureti M, Fanali S, et al. A long-term follow-up study of non-submerged ITI implants in the treatment of totally edentulous jaws. *Clin Oral Implants Res* 2002;13:260–73.
9. Anitua E, Orive G, Aguirre JJ, et al. Five-year clinical evaluation of short dental implants placed in posterior areas: a retrospective study. *J Periodontol* 2008;79:42–8.
10. Waerhaug J. Healing of the dento-epithelial junction following subgingival plaque control. II: as observed on extracted teeth. *J Periodontol* 1978;49:119–34.
11. Stambaugh RV, Dragoo M, Smith DM, et al. The limits of subgingival scaling. *Int J Periodontics Restorative Dent* 1981;1(5):30–42.
12. Buchanan S, Robertson P. Calculus removal by scaling/root planing with and without surgical access. *J Periodontol* 1987;58:159–63.
13. Jones WA, O’Leary TJ. The effectiveness of root planing in removing bacterial endotoxin from the roots of periodontally involved teeth. *J Periodontol* 1978;49:337–42.
14. Rabbani GM, Ash MM, Caffesse RG. The effectiveness of subgingival scaling and root planing in calculus removal. *J Periodontol* 1981;52:119–23.
15. Caffesse R, Sweeney PL, Smith BA. Scaling and root planning with and without periodontal flap surgery. *J Clin Periodontol* 1986;13:205–10.
16. Tabita PV, Bissada NF, Maybury JE. Effectiveness of supragingival plaque control on the development of subgingival plaque and gingival inflammation in patients with moderate pocket depth. *J Periodontol* 1981;52:88–93.
17. Becker W, Becker BE, Berg L, et al. New attachment after treatment with root isolation procedures. Report for treated class III and class II furcations and vertical osseous defects. *Int J Periodontics Restorative Dent* 1998;8(3):8–23.
18. Goldman MJ, Ross IF, Goteiner D. Effect of periodontal therapy on patients maintained for 15 years or longer. A retrospective study. *J Periodontol* 1986;57:347–53.
19. McFall WT. Tooth loss in 100 treated patients with periodontal disease—a long-term study. *J Periodontol* 1982;53:539–49.
20. Wood WR, Greco GW, McFall WT Jr. Tooth loss in patients with moderate periodontitis after treatment and long-term maintenance. *J Periodontol* 1989;60:516–20.
21. Hirschfeld L, Wasserman B. A long-term study of tooth loss in 600 treated periodontal patients. *J Periodontol* 1978;49:225–37.
22. Wang HL, Burgett FG, Shyr Y, et al. The influence of molar furcation involvement and mobility of future clinical periodontal attachment loss. *J Periodontol* 1994;65:25–9.
23. Fleischer HC, Mellonig JT, Brayer WK, et al. Scaling and root planning efficacy in multi-rooted teeth. *J Periodontol* 1989;60:402–9.

24. Karlson K. Gingival reaction to dental restorations. *Acta Odontol Scand* 1970;28:895–9.
25. Waerhaug J. Tissue reactions around artificial crowns. *J Periodontol* 1953;24:172–85.
26. Newcomb GM. The relationship between the location of subgingival crown margins and gingival inflammation. *J Periodontol* 1974;45:151–4.
27. Renggli HH, Regolati B. Gingival inflammation and plaque accumulation by well adapted supragingival and subgingival proximal restorations. *Helv Odontol Acta* 1972;16:99–101.
28. Waerhaug J. Effect of rough surfaces upon gingival tissues. *J Dent Res* 1956;35:323–5.
29. Silness J. Periodontal conditions in patients treated with dental bridges. II. The influence of full and partial crowns on plaque accumulation, development of gingivitis and pocket formation. *J Periodont Res* 1970;5:219–24.
30. Mormann W, Regolatti B, Renggli HH. Gingival reaction to well fitted subgingival gold inlays. *J Clin Periodontol* 1974;1:120–5.
31. Gilmore N, Sheiham A. Overhanging dental restorations and periodontal disease. *J Periodontol* 1971;42:8–12.
32. Fugazzotto PA. Preparation of the periodontium for restorative dentistry. St. Louis (MO): Ishiyaku EuroAmerica, Inc.; 1989.
33. Adell R, Eriksson B, Lekholm U, et al. A long term follow-up study of osseointegrated implants in the treatment of totally edentulous jaws. *Int J Oral Maxillofac Surg* 1990;5:347–59.
34. Albrektsson T. A multi center report on osseointegrated oral implants. *J Prosthet Dent* 1988;60:75–84.
35. Fugazzotto PA, Gulbransen H, Wheeler S, et al. The use of IMZ osseointegrated implants in partially and completely edentulous patients: success and failure rates of 2,023 implant cylinders up to sixty plus months in function. *Int J Oral Maxillofac Implants* 1993;8:635–40.
36. Albrektsson T, Dahl E, Enbom L, et al. Osseointegrated oral implants: a Swedish multi center study of 8,139 consecutively inserted Nobelpharma implants. *J Periodontol* 1998;59:287–96.
37. Lum LB. A biomechanical rationale for the use of short implants. *J Oral Implantol* 1991;17:126–31.
38. Pierriesnard L, Reinouard F, Renoult P, et al. Influence of implant length and bi-cortical anchorage on implant stress distribution. *Clin Implant Dent Relat Res* 2003;5:254–62.
39. Lai H, Zhang F, Zhang B, et al. Influence of percentage of osseointegration on stress distribution around dental implants. *Chin J Dent Res* 1998;1:7–11.
40. Holmgren EP, Seckinger RJ, Kilgren LM, et al. Evaluating parameters of osseointegrated dental implants using finite element analysis: a two dimensional comparative study examining the effects of implant diameter, implant shape, and load direction. *J Oral Implantol* 1998;24:80–8.
41. Himmlova L, Dostalova T, Kacovsky A, et al. Influence of implant length and diameter on stress distribution: a finite element analysis. *J Prosthet Dent* 2004;1:20–5.
42. Feldman S, Boitel N, Weng D, et al. Five year survival of short machined surface/osteotite implants. *Clin Implant Dent Relat Res* 2004;6:16–23.
43. Deporter D, Watson P, Pharoah M, et al. Five to six year results of prospective clinical trials using the Endopore dental implant and a mandibular overdenture. *Clin Oral Implants Res* 1999;10:95–102.
44. Rockni S, Todescan R, Watson P, et al. Assessment of crown to root ratios with short sintered porous surface implants. *Int J Oral Maxillofac Implants* 2005;20:69–76.

45. Tawil G, Aboujaoude N, Younan R. Influence of prosthetic parameters on the survival and complication rates of short implants. *Int J Oral Maxillofac Implants* 2006; 21:275–82.
46. Blanes RJ, Bernard JP, Blanes ZM, et al. A ten year prospective study of ITI implants in the posterior maxilla: influence of crown implant ratio. *Clin Oral Implants Res* 2007;18:707–14.
47. Fugazzotto PA. Shorter implants in clinical practice: rationale and treatment results. *Int J Oral Maxillofac Implants* 2008;23:487–96.
48. Hsu M-L, Chen F-C, Kao H-C, et al. Influence of off access loading on an anterior maxillary implant: a three dimensional finite element analysis. *Int J Oral Maxillofac Implants* 2007;22:301–9.
49. Meada Y, Satoh T, Sogo M. In vitro differences of stress concentrations for internal and external hex connections. *J Oral Rehabil* 2006;33:75–8.
50. Ivanoff CJ, Grondahl K, Sennerby L, et al. Influence of variations in implant diameters: a 3 to 5 year retrospective clinical report. *Int J Oral Maxillofac Implants* 1999;14:173–80.
51. Eckert SE, Meraw SJ, Weaver AL, et al. Early experience with Wide Platform Mk II implants. Part I: implant survival. Part II: evaluation of risk factors involving implant survival. *Int J Oral Maxillofac Implants* 2001;16:671–7.
52. Shin SW, Bryant SR, Zarb GA. A retrospective study on the treatment outcome of wide bodies implants. *Int J Prosthodont* 2004;17:52–8.
53. Bischof M, Nedir R, Abi Najm S, et al. A five-year life table analysis on wide neck ITI implants with prosthetic evaluation and radiographic analysis; results from private practice. *Clin Oral Implants Res* 2006;17:512–20.
54. Mericske-Stern R, Grutter L, Rosch R, et al. Clinical evaluation and prosthetic complications of single tooth replacements by non-submerged implants. *Clin Oral Implants Res* 2001;12:309–18.
55. Fugazzotto PA. Implant placement at the time of maxillary molar extraction: treatment options and reported results. *J Periodontol* 2008;79:216–23.
56. Fugazzotto PA. Sinus floor augmentation of the maxillary molar extraction socket: a modified technique to increase bone height. *Int J Oral Maxillofac Implants* 1999;14:536–42.
57. Summers RB. A new concept in maxillary implant surgery: the osteotome technique. *Compend Contin Educ Dent* 1994;15:152–60.
58. Coatoam GW, Krieger JT. A four-year study examining the results of indirect sinus augmentation procedures. *J Oral Implantol* 1997;23:117–27.
59. Zitzmann NU, Scharer P. Sinus elevation procedures in the resorbed posterior maxilla. Comparison of the crestal and lateral approaches. *Oral Surg Oral Med Oral Pathol* 1998;85:8–17.
60. Bruschi GB, Scipioni a, Calesini G, et al. Localized management of the sinus floor with simultaneous implant placement: a clinical report. *Int J Oral Maxillofac Implants* 1998;13:219–26.
61. Emmerich D, Att W, Stappert C. Sinus floor elevation using osteotomes: a systematic review and meta-analysis. *J Periodontol* 2005;76:1237–51.
62. Ferrigno N, Laureti M, Fanali S. Dental implants placement in conjunction with osteotome sinus floor elevation: a 12-year life-table analysis from a perspective study on 558 ITI implants. *Clin Oral Implants Res* 2006;17:194–205.
63. Cavicchia F, Bravi F, Petrelli G. Localized augmentation of the maxillary sinus floor through a coronal approach for the placement of implants. *Int J Periodontics Restorative Dent* 2001;21:475–85.

64. Fugazzotto PA. Immediate implant placement following a modified trephine/osteotome approach: success rates of 116 implants to 4 years in function. *Int J Oral Maxillofac Implants* 2002;73:39–44.
65. Fugazzotto PA. Augmentation of the posterior maxilla. A proposed hierarchy of treatment selection. *J Periodontol* 2003;74:1682–91.
66. Fugazzotto PA, Hains F. The effect of therapeutic costs on development of treatment algorithms in the partial edentulous patient. A comparative fee survey and treatment planning philosophy *J Amer Dent Assoc* 2008; submitted for publication.