

Treatment Strategy for Guided Tissue Regeneration in Combined Endodontic-Periodontal Lesions: Case Report and Review

Se-Lim Oh, DMD MS,* Asbraf F. Fouad, BDS, DDS, MS,[†] and Sang-Hoon Park, DDS, MS[‡]

Abstract

Introduction: Endodontic-periodontal combined lesion is a clinical dilemma because making a differential diagnosis and deciding a prognosis are difficult. **Methods:** Twenty-six cases from 14 articles involving the successful management of endodontic-periodontal lesions with concurrent regenerative procedures were reviewed. This article also presents successful treatment of an endodontic-periodontal combined lesion involving a grade II mesial furcation of a maxillary molar with root canal treatment and multiple regenerative procedures. **Results:** A treatment algorithm is outlined for the application of the guided tissue regeneration (GTR) in managing endodontic-periodontal combined lesion. This treatment algorithm consists of 4 phases: (1) presurgical phase (determining periodontal/regenerative prognosis), (2) endodontic phase, (3) periodontal surgical phase, and (4) post-GTR reevaluation protocol. **Conclusions:** The proposed 4-phase treatment algorithm might provide a beneficial guideline in managing the endodontic-periodontal combined lesions. (*J Endod* 2009;35:1331–1336)

Key Words

Combined endodontic-periodontal lesion, furcation, guided tissue regeneration

From the *Department of Health Promotion and Policy, [†]Department of Endodontics, Prosthodontics and Operative Dentistry, and [‡]Department of Periodontics, Dental School, University of Maryland, Baltimore, Maryland.

Address requests for reprints to Sang-Hoon Park, DDS, MS, Assistant Professor, Department of Periodontics, Room 4203, Dental School, University of Maryland, 650 W Baltimore St, Baltimore, MD, 21201. E-mail address: spark@umaryland.edu. 0099-2399/\$0 - see front matter

Copyright © 2009 American Association of Endodontists. doi:10.1016/j.joen.2009.06.004

Endodontic-periodontal lesion is a clinical manifestation of the pathologic/inflammatory intercommunication between pulpal and periodontal tissues via open structures such as apical foramina, lateral, accessory canals, and dentinal tubules (1). On the basis of the pathologic origin, Simon et al (2) classified endodontic-periodontal lesions into primary endodontic lesions, primary endodontic lesions with secondary periodontic involvement, primary periodontic lesions, primary periodontic lesions with secondary endodontic involvement, or true combined lesions. Formulating a differential diagnosis among combined lesions has been challenging because most often clinicians do not have a complete history of the course of disease progression.

Therefore, diagnostic steps should include thorough patient-reported dental history, visual inspection for presence of sinus tract and severe inflammation in association with large restoration and anatomic anomalies such as palatal grooves (3), radiographic confirmation with tracing the sinus track, results of clinical findings including percussion and palpation, routine periodontal assessment for presence of mobility or deep probing depth, testing for coronal cracks, and pulp vitality testing (1). The latter tests are customarily accepted as being reliable in differentiating between pulpal and periodontal disease. However, it is also recognized that false responses might be elicited with available tests (4, 5), particularly in cases of multi-rooted teeth that might have partial pulp necrosis. Therefore, completing the entire recommended diagnostic steps is critical in management of endodontic-periodontal lesions.

The treatment of endodontic-periodontal combined lesions requires both endodontic therapy and periodontal regenerative procedure. The success rate of the endodontic-periodontal combined lesion without a concomitant regenerative procedure has been reported to range from 27%–37% (6, 7). This is significantly lower than the reported success rate of 95% with conventional nonsurgical root canal therapy (8–10). A long junctional epithelium formed over the dehiscenced root surface has been suggested to be a contributing factor for the poor therapeutic prognosis (9). With the aid of the microscope-assisted regenerative procedure and methylene blue staining, its success rate has been shown to improve to 77.5% during a period of 5 years (11). Therefore, case selection and the appropriate treatment modalities are essential for the successful treatment outcome.

Guided tissue regeneration (GTR) therapy introduced in 1980s has been widely used to regenerate lost periodontium from periodontal disease. Both human and animal studies have demonstrated various degrees of regeneration of bone and attachment apparatus (12–15). GTR therapy has also been implemented in the endodontic surgeries as a concomitant treatment during the management of the endodontic-periodontal lesions (3, 9, 16–28).

This article presents successful management of an endodontic-periodontal combined lesion affecting a molar with a mesial furcation involvement, with multiple GTR applications. Treatment strategies are suggested on the basis of 26 cases in which the endodontic-periodontal lesions are successfully managed with concurrent regenerative procedure.

Case Report

A 50-year-old healthy, nonsmoker female patient presented for a pre-prosthetic periodontal evaluation. Overall periodontal status was stable. However, tooth #3 showed a localized deep probing depth of 9 mm and a 5-mm gingival recession on

the mesiopalatal aspect of the tooth with grade II mobility. It responded to neither the electrical pulp test (EPT) nor the cold test (Endo Ice; Hygenic Corp, Akron OH). There was no pain on percussion test. Periapical radiographic views showed a deep vertical bony defect extending to root apex of tooth #3, in addition to the periapical radiolucencies to the mesiobuccal root (Fig. 1*a*). Initial diagnosis was pulp necrosis and asymptomatic apical periodontitis, and the tooth was thought to have primary endodontic involvement. However, the pattern of periodontal bone loss, with a wide base coronally and narrow extent apically, coupled with generalized marginal periodontitis elsewhere in the mouth, suggested that there was also primary periodontal involvement in this case (29). Therefore, the overall classification of this case was an endodontic-periodontal combined lesion. The periodontal prognosis was determined as poor to questionable according to the prognostication system of McGuire (30).

Root canal treatment and initial scaling and root planing (SRP) were simultaneously performed during disease control phase (Fig. 1*b* and *c*). On access opening, a mesiobuccal 2 could not be located in the tooth. The canals were cleaned and shaped by using stainless steel files and nickel-titanium rotary instruments, irrigated with 5.25% sodium hypochlorite. The canals were obturated with gutta-percha and sealer (AH Plus; Dentsply Maillefer, Tulsa, OK). After 1 month, GTR procedure was performed on tooth #3 by using autogenous bone graft and nonabsorbable expanded polytetrafluoroethylene (e-PTFE) membrane (W. L. Gore, Newark, DE). Under local infiltration anesthesia, complete granulomatous tissue removal and thorough SRP were performed after a full-thickness flap was elevated. The osseous defect morphology was a 2-to-3 wall combination defect with mesial grade II furcation involvement (Fig. 1*d*). One capsule of 250 mg tetracycline HCl diluted with saline was applied repeatedly onto the involved root surface by using cotton pellets for 3 minutes (31).

Autogenous bone chips harvested from the buccal exostosis of tooth #3 were gently packed into mesial furcation area, and a wraparound e-PTFE membrane was secured with the Gore-Tex suture

(W. L. Gore). The flap was repositioned and secured with the Gore-Tex suture. One-week course of amoxicillin 500 mg, 3 times a day and 2% chlorhexidine mouth rinse were prescribed.

A slight membrane exposure was observed at 2 weeks between teeth #2 and #3 with minimal inflammation. Weekly postoperative care was provided until membrane removal at 7 weeks. On membrane removal, "soft rubbery tissue" filled the defect. A provisional bridge was then fabricated and cemented.

Radiographic evaluation 10 months after membrane removal showed a substantial radiographic bone fill (Fig. 2*a*). However, tooth #3 still had a 6-mm probing depth associated with the incompletely resolved vertical defect. With the patient's consent, the second GTR procedure was attempted. On a full-thickness flap, it was evident that the previous grade II furcation was reduced to grade I furcation (Fig. 2*b*). Root surface was once again conditioned with tetracycline HCl after thorough SRP. Demineralized-freeze-dried bone allograft (LifeNet, CA) was used to avoid the second surgical site. An absorbable collagen membrane (BioGide, BIOMET 3i; Osteohealth, Shirley, NY) was placed because future membrane removal was not planned. Primary wound closure over the barrier was achieved. One-week course of amoxicillin 500 mg, 3 times a day and 3 weeks of 2% chlorhexidine mouth rinse were prescribed. Weekly postoperative care was provided for 4 weeks.

A final prosthesis was cemented 5 months after the second GTR surgery (Fig. 2*c*). The 10-month follow-up periapical radiographic view showed complete resolution of the previous vertical defect (Fig. 2*d*). The remaining pocket depth was reduced from 6 to 3 mm, with 2.0-mm gingival recession. No bleeding on probing was found. The patient was periodontally maintained at 3-month intervals throughout the entire treatment.

Literature Review Results

An electronic search of PubMed up to April 1, 2009 without language restrictions was performed by using the terms "Guided Tissue

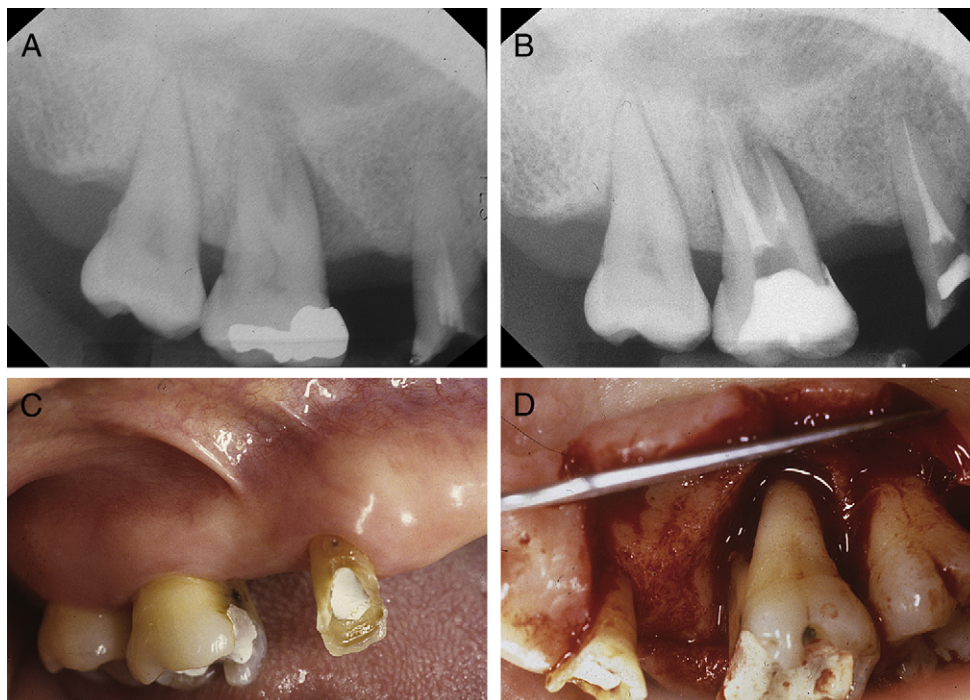


Figure 1. (A) Initial vertical bony defect extended to root apex of tooth #3. (B) Radiograph after root canal treatment and SRP. (C) Preoperative clinical photo. (D) Flap retracted and defect debrided.

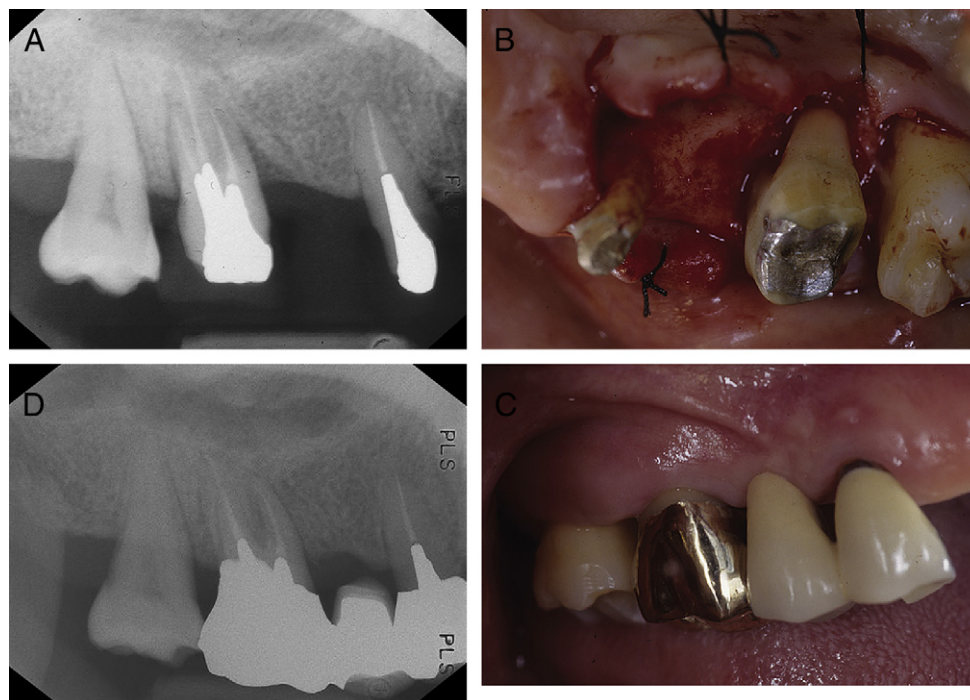

Figure 2. (A) Ten-month follow-up radiograph after the first GTR procedure. (B) Remaining bony defect at 10-month re-entry surgery. (C) Final prosthesis delivered 5 months later. (D) Ten-month follow-up radiograph after the second GTR procedure.

Regeneration” AND “Endodontic.” Hand searching included a perusal of bibliographies of relevant articles and review articles. A total of 14 articles with 26 cases were found, demonstrating the successful management of endodontic-periodontal lesion(s) with the concomitant regenerative procedures (3, 9, 16–27). Table 1 summarizes the reported endodontic-periodontal lesions classified by the classification of Simon et al (2), tooth type, arch location, and bone destruction patterns. Of 26 cases, 17 cases involved teeth in the maxilla, and 9 cases involved teeth in the mandible. Most cases reported involved single-rooted teeth: maxillary incisors (30.8%), maxillary premolars (23.1%), and mandibular incisors (23.1%). Very few cases involving mandibular premolars were reported (3.8%). A total of 19 cases reported involved both periapical lesions with concomitant marginal bone loss.

Table 2 summarizes the clinical and radiographic signs and symptoms of the endodontic-periodontal lesions reported in these case reports. Lack of pulp vitality, periapical radiolucency, and localized deep periodontal pocket depths were the most common features. A radiographic vertical defect was not always observed because these lesions frequently involved the buccal aspect of the affected tooth.

Of 26 cases, nonabsorbable membrane was used in 15 cases, whereas absorbable membranes and enamel matrix protein were applied in 8 and 3 cases, respectively. Simultaneous root-end resection and filling were performed in 19 cases. In 3 cases root conditioning agent was administered during the GTR procedures (3, 17, 27).

TABLE 1. Reported Endodontic-Periodontal Lesions by Location and Bone Destruction Patterns

Classification of lesions*	Tooth type	Defect	No. of cases	Reference
Primary endodontic	Maxillary incisors	Periapical lesion without marginal loss	1	25
	Maxillary premolar	Periapical lesion without marginal loss	1	18
	Mandibular incisors	Periapical lesion without marginal loss	2	9
Primary endodontic with secondary periodontic	Maxillary molar	No periapical lesion with buccal furcation involvement	2	9, 17
Primary periodontic	Mandibular incisors	Periapical lesion and concomitant marginal loss	1	9
Primary periodontic with secondary endodontic	Mandibular incisors	Periapical lesion and concomitant marginal loss	2	23
True combined lesions	Maxillary incisors	Periapical lesion and concomitant marginal loss	6	3, 9, 16, 24–26
	Maxillary incisors	No periapical lesion with presence of concomitant marginal loss	1	27
	Maxillary premolar	Periapical lesion and concomitant marginal loss	5	18, 21, 22
	Maxillary molar	Periapical lesion with buccal furcation involvement	1	20
	Mandibular incisors	Periapical lesion and concomitant marginal loss	1	25
	Mandibular premolar	Periapical lesion and concomitant marginal loss	1	25
Mandibular molar	Periapical lesion and concomitant marginal loss	2	18, 20	

*Classification scheme from Simon et al (2).

TABLE 2. Reported Clinical and Radiographic Manifestations Related to Endodontic-Periodontal Lesions

Reported clinical/radiographic manifestation	No. of cases*
Periapical radiolucency [†]	22
Deep pocket depths	12
No pocket depths	1
Swelling	6
Fistula, sinus tract	7
Pus discharge	1
Acute pain	2
Mobility	4
No vitality [‡]	25
Normal response to vitality tests	1
Percussion sensitivity	2
Continuous discomfort	1
Gingival irritation with bleeding	1
Root perforation	2

*Total of 26 teeth from 14 articles (3, 9, 16–27).

[†]Periapical radiolucency includes apical periodontitis and periapical pathology.

[‡]No vitality includes no responses to vitality tests, pulp necrosis, and previous root canal treatment.

Discussion

Endodontic-periodontal combined lesion is a true challenge. Its management requires thorough understanding of wound healing process involving both endodontic and periodontal complex. Kim et al (11) reported that even with the aid of a microscope, the treatment success of the endodontic-periodontal combined lesion remained significantly lower than the treatment of the isolated endodontic lesions. Of 40 endodontic-periodontal combined lesions treated in their study, only 57% showed a complete healing with the reestablishment of the lamina dura. Therefore, recognizing the treatment difficulty and need for strategic approach are the essential components in treating the endodontic-periodontal combined lesion.

This case report presents a successfully treated endodontic-periodontal combined lesion, involving a grade II mesial furcation of

a maxillary molar, via multiple regenerative procedures. A total of 26 cases from 14 articles involving the regenerative procedures were also reviewed to formulate the treatment strategies for managing the endodontic-periodontal combined lesion.

From the review of 26 cases, single-rooted teeth were the most reported tooth type with successful results (Table 1). On the contrary, a total of 5 molar cases have been reported (9, 17, 18, 20). As a result of the surgical difficulties and unpredictable outcomes, extractions are often favored over retreatment/regenerative combined procedures. This might have underestimated the treatment success of the truly combined endodontic-periodontal lesions in molars. Of 21 single-rooted teeth, 17 cases presented with both periapical lesions and the concomitant marginal bone loss (3, 9, 16, 18, 21–26).

All 26 cases did not establish the differential diagnosis for the subclasses of endodontic-periodontal lesions as a result of lack of a complete history of disease progression. One case presented with a denuded root surface on labial and mesial side, as a result of pathology of the adjacent endodontic-periodontal combined lesion (25). One case report showed a loss of vitality after the regenerative procedure (23). Therefore, a primary periodontal case progressed to involve a secondary endodontic lesion as a result of the therapy provided.

The most common clinical/radiographic features of the endodontic-periodontal lesions reported were the periapical radiolucency and deep pocket depths with a nonvital pulp status (Table 2). Deep pockets were often localized and reached the full length of the root, which resembled a vertical root fracture. A shallow pocket observed in one case report might be due to the incorrect probing depths, or it might have been misdiagnosed (9). In addition to the localized deep probing depths, most of the teeth reported showed minimal mobility attributing to the partial support from the intact palatal or lingual plate. Only 4 cases reported a grade I or grade II mobility (21, 25, 27).

A treatment strategy for the application of the regenerative procedures is outlined in Fig. 3 on the basis of the 26 successful cases reported (3, 9, 16–27). The decisions are made at various levels:

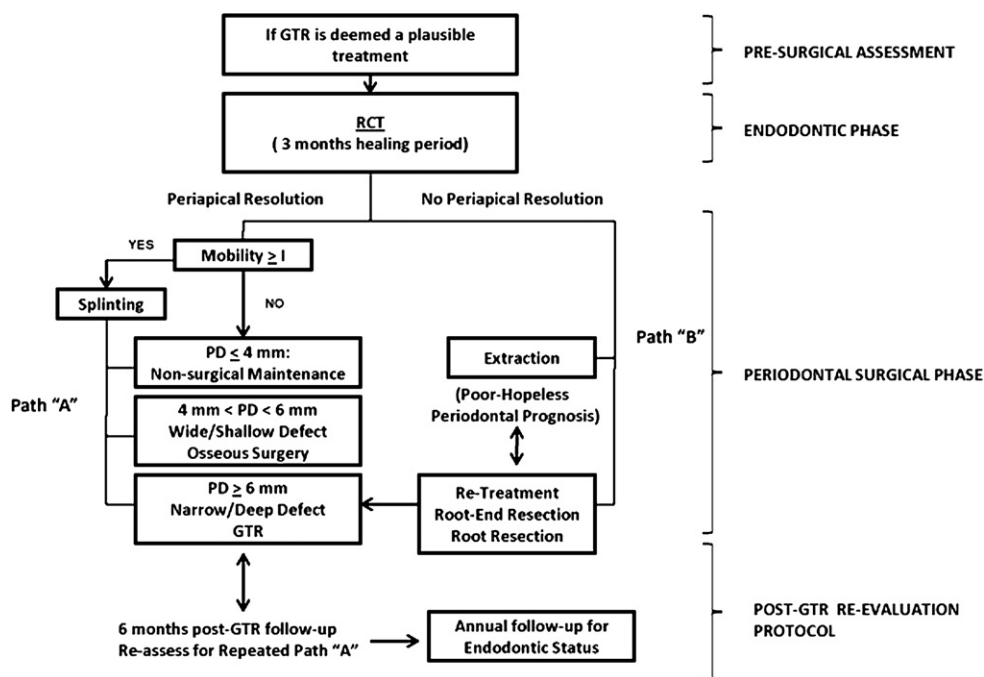


Figure 3. Treatment algorithm for periodontic-endodontic combined lesions.

presurgical assessment, post-root canal treatment, intrasurgical assessment, and postsurgical outcomes. Factors influencing treatment outcome should also be considered at each level under patient-specific, defect-specific, and healing categories (32).

The presurgical assessment includes establishing and verifying the nonvital status of the pulp, the extent and severity of the periodontal destruction, and therapeutic prognosis of the planned regenerative procedure. One must distinguish an endodontic-periodontal combined lesion from a tooth with a vertical root fracture. A localized deep probing depth with minimal tooth mobility might have a favorable clinical outcome after the regenerative procedure. Cortellini et al (33) and others (34) have advocated splinting of the mobile tooth before GTR procedure because the baseline mobility has been associated with the smaller clinical attachment gain observed after GTR. However, the question still remains as to when the splinting should be removed. This could depend on individual situations. In the case described here, a provisional bridge served as a postoperative splint, and the final bridge served as a permanent splint.

Once the therapeutic prognosis of the periodontal regenerative procedure is determined to be favorable, the endodontic therapy is provided. Healing time should be longer for the cases with periapical radiolucency to ensure adequate time for initial tissue healing (17, 29, 35). The size of the periapical lesion in an isolated endodontic lesion has been reported to be not adversely affecting the clinical outcome (11). However, presently, there is no consensus on the effect of the lesion size on the healing of the endodontic-periodontal combined lesions (11). Unsatisfactory healing after root canal treatment might be further addressed with a surgical approach. Extraction is an alternative decision, especially when clinical mobility has significantly increased. After a successful root canal therapy, tooth mobility is further assessed to determine the necessity for splinting.

The intrasurgical assessment includes morphology of the periodontal defect, defect type, material of choice to fill the defect and augment healing, control of patient's oral hygiene, and wound stabilization (36, 37). In this case, a 2-to-3 wall combination defect was present, with mesial grade II furcation involvement. Because of difficult surgical access from the complicated intrinsic trifurcation morphology, some clinical studies have found that the outcome of GTR on mesial and distal maxillary molar furcation was not predictable (38–40). However, the involved furcation in this case was sufficiently wide for good access to a mechanical instrumentation. Radiographic vertical defect was deep (≥ 4 mm) and narrow (≤ 25 degrees), which has been shown to be a favorable defect for the GTR procedure (41, 42). Therefore, regenerative procedure was a plausible treatment option. The periapical lesion was likely contributing to the bone resorption in the mesial defect. Therefore, root-end resection was considered at the time of GTR to provide more definitive treatment and to avoid additional surgical intervention.

Bone graft of choice for the first regenerative procedure in our case was autogenous bone graft and e-PDGF membrane because this combination has been shown to result in the most favorable regenerative outcome (43). Most of the reported cases, however, used allograft or xenograft with various types of membranes, most likely as a result of an insufficient donor site. At the second GTR surgery, the combination of demineralized-freeze-dried bone allograft and an absorbable collagen membrane was chosen to avoid membrane removal procedure and to evaluate bone fill with radiographic follow-ups.

Furthermore, treatment planning should include potential additional surgical intervention as a part of postsurgical management. In current literature, there have been no suggested retreatment protocols for management of the deep residual pockets and bony defects after

GTR. Studies have shown that 18.6% of GTR-treated teeth still had ≥ 6 mm of residual pocket depths, and 57.5% of GTR-treated intrabony sites showed a partial bone fill (44, 45). Despite the presence of the residual defects and probing depths, many clinical studies (39, 40, 45, 46) performing reentry did not provide any supplementary GTR procedure to further close the partially filled furcation. In this case, a complete bone fill in the vertical intrabony defect area was observed on the follow-up radiograph (Fig. 2d) after the second GTR procedure. This is likely related to the healing of the endodontic component of bacterial irritation. The remaining pocket depth was reduced from 6 to 3 mm. The multiple GTR procedures could be justified by getting additional bone fill and reducing remaining pocket depths.

Conclusion

This case report demonstrated that with the stringent case selection criteria, multiple regenerative procedures could successfully treat an endodontic-periodontal combined lesion involving a mesial furcation of a maxillary molar. The treatment strategies and the clinical outcome depend on the extent of the periodontal disease and assessment of the therapeutic prognosis, with the intended regenerative procedure, presence or absence of periapical radiolucency, tooth mobility, properly performed root canal treatment, and appropriate healing time.

References

- Meng HX. Periodontic-endodontic lesions. *Ann Periodontol* 1999;4:84–90.
- Simon JH, Glick DH, Frank AL. The relationship of endodontic-periodontic lesions. *J Periodontol* 1972;43:202–8.
- Schwartz SA, Koch MA, Deas DE, Powell CA. Combined endodontic-periodontic treatment of a palatal groove: a case report. *J Endod* 2006;32:573–8.
- Peters DD, Baumgartner JC, Lorton L. Adult pulpal diagnosis: I—evaluation of the positive and negative responses to cold and electrical pulp tests. *J Endod* 1994;20:506–11.
- Petersson K, Soderstrom C, Kiani-Anaraki M, Levy G. Evaluation of the ability of thermal and electrical tests to register pulp vitality. *Endod Dent Traumatol* 1999;15:127–31.
- Hirsch JM, Ahlstrom U, Henrikson PA, Heyden G, Peterson LE. Periapical surgery. *Int J Oral Surg* 1979;8:173–85.
- Skoglund A, Persson G. A follow-up study of apicoectomized teeth with total loss of the buccal bone plate. *Oral Surg Oral Med Oral Pathol* 1985;59:78–81.
- Molven O, Halse A. Success rates for gutta-percha and chloroperka N-0 root fillings made by undergraduate students: radiographic findings after 10–17 years. *Int Endod J* 1988;21:243–50.
- Rankow HJ, Krasner PR. Endodontic applications of guided tissue regeneration in endodontic surgery. *J Endod* 1996;22:34–43.
- Imura N, Pinheiro ET, Gomes BP, Zaia AA, Ferraz CC, Souza-Filho FJ. The outcome of endodontic treatment: a retrospective study of 2000 cases performed by a specialist. *J Endod* 2007;33:1278–82.
- Kim E, Song JS, Jung IY, Lee SJ, Kim S. Prospective clinical study evaluating endodontic microsurgery outcomes for cases with lesions of endodontic origin compared with cases with lesions of combined periodontal-endodontic origin. *J Endod* 2008;34:546–51.
- Nyman S, Gottlow J, Karring T, Lindhe J. The regenerative potential of the periodontal ligament: an experimental study in the monkey. *J Clin Periodontol* 1982;9:257–65.
- Nyman S, Lindhe J, Karring T, Rylander H. New attachment following surgical treatment of human periodontal disease. *J Clin Periodontol* 1982;9:290–6.
- Gottlow J, Nyman S, Lindhe J, Karring T, Wennstrom J. New attachment formation in the human periodontium by guided tissue regeneration: case reports. *J Clin Periodontol* 1986;13:604–6.
- Bowers GM, Chadroff B, Carnevale R, et al. Histologic evaluation of new attachment apparatus formation in humans: part II. *J Periodontol* 1989;60:675–82.
- Abramowitz PN, Rankow H, Trope M. Multidisciplinary approach to apical surgery in conjunction with the loss of buccal cortical plate. *Oral Surg Oral Med Oral Pathol* 1994;77:502–6.
- Duggins LD, Clay JR, Himel VT, Dean JW. A combined endodontic retrofill and periodontal guided tissue regeneration technique for the repair of molar endodontic furcation perforations: report of a case. *Quintessence Int* 1994;25:109–14.
- Kellert M, Chalfin H, Solomon C. Guided tissue regeneration: an adjunct to endodontic surgery. *J Am Dent Assoc* 1994;125:1229–33.

19. Tseng CC, Chen YH, Huang CC, Bowers GM. Correction of a large periradicular lesion and mucosal defect using combined endodontic and periodontal therapy: a case report. *Int J Periodontics Restorative Dent* 1995;15:377–83.
20. Uchin RA. Use of a bioresorbable guided tissue membrane at an adjunct to bony regeneration in cases requiring endodontic surgical intervention. *J Endod* 1996;22:94–6.
21. Tseng CC, Harn WM, Chen YH, Huang CC, Yuan K, Huang PH. A new approach to the treatment of true-combined endodontic-periodontic lesions by the guided tissue regeneration technique. *J Endod* 1996;22:693–6.
22. Milano F, Melsen B. Guided tissue regeneration using bioresorbable membranes: what is the limit in the treatment of combined periapical and marginal lesions? *Int J Periodontics Restorative Dent* 1997;17:416–25.
23. Blank BS, Levy AR. Combined treatment of a large periodontal defect using GTR and DFDBA. *Int J Periodontics Restorative Dent* 1999;19:481–7.
24. Brugnami F, Mellonig JT. Treatment of a large periapical lesion with loss of labial cortical plate using GTR: a case report. *Int J Periodontics Restorative Dent* 1999;19:243–9.
25. Pompa DG. Guided tissue repair of complete buccal dehiscences associated with periapical defects: a clinical retrospective study. *J Am Dent Assoc* 1997;128:989–97.
26. Kerezoudis NP, Siskos GJ, Tsatsas V. Bilateral buccal radicular groove in maxillary incisors: case report. *Int Endod J* 2003;36:898–906.
27. John V, Warner NA, Blanchard SB. Periodontal-endodontic interdisciplinary treatment: a case report. *Compend Contin Educ Dent* 2004;25:601.
28. Pecora G, Kim S, Celletti R, Davarpanah M. The guided tissue regeneration principle in endodontic surgery: one-year postoperative results of large periapical lesions. *Int Endod J* 1995;28:41–6.
29. Rotstein I, Simon JH. Diagnosis, prognosis and decision-making in the treatment of combined periodontal-endodontic lesions. *Periodontol* 2000;2004(34):165–203.
30. McGuire MK. Prognosis versus actual outcome: a long-term survey of 100 treated periodontal patients under maintenance care. *J Periodontol* 1991;62:51–8.
31. Sterrett JD, Simmons J, Whitford G, Russell CM. Tetracycline demineralization of dentin: the effects of concentration and application time. *J Clin Periodontol* 1997;24:457–63.
32. Bashutski JD, Wang HL. Periodontal and endodontic regeneration. *J Endod* 2009;35:321–8.
33. Cortellini P, Tonetti MS, Lang NP, et al. The simplified papilla preservation flap in the regenerative treatment of deep intrabony defects: clinical outcomes and postoperative morbidity. *J Periodontol* 2001;72:1702–12.
34. Schulz A, Hilgers RD, Niedermeier W. The effect of splinting of teeth in combination with reconstructive periodontal surgery in humans. *Clin Oral Investig* 2000;4:98–105.
35. Zehnder M, Gold SI, Hasselgren G. Pathologic interactions in pulpal and periodontal tissues. *J Clin Periodontol* 2002;29:663–71.
36. Tonetti MS, Prato GP, Cortellini P. Factors affecting the healing response of intrabony defects following guided tissue regeneration and access flap surgery. *J Clin Periodontol* 1996;23:548–56.
37. Trombelli L, Kim CK, Zimmerman GJ, Wikesjo UM. Retrospective analysis of factors related to clinical outcome of guided tissue regeneration procedures in intrabony defects. *J Clin Periodontol* 1997;24:366–71.
38. Metzler DG, Seamons BC, Mellonig JT, Gher ME, Gray JL. Clinical evaluation of guided tissue regeneration in the treatment of maxillary class II molar furcation invasions. *J Periodontol* 1991;62:353–60.
39. Pontoriero R, Lindhe J. Guided tissue regeneration in the treatment of degree II furcations in maxillary molars. *J Clin Periodontol* 1995;22:756–63.
40. Avera JB, Camargo PM, Klokkevold PR, Kenney EB, Lekovic V. Guided tissue regeneration in class II furcation involved maxillary molars: a controlled study of 8 split-mouth cases. *J Periodontol* 1998;69:1020–6.
41. Cortellini P, Carnevale G, Sanz M, Tonetti MS. Treatment of deep and shallow intrabony defects: a multicenter randomized controlled clinical trial. *J Clin Periodontol* 1998;25:981–7.
42. Cortellini P, Tonetti MS. Focus on intrabony defects: guided tissue regeneration. *Periodontol* 2000;2000(22):104–32.
43. Camelo MC, Nevins ML, Nevins M. Treatment of class II furcations with autogenous bone grafts and e-PTFE membranes. *Int J Periodontics Restorative Dent* 2000;20:233–43.
44. Tonetti MS, Cortellini P, Suvan JE, et al. Generalizability of the added benefits of guided tissue regeneration in the treatment of deep intrabony defects: evaluation in a multi-center randomized controlled clinical trial. *J Periodontol* 1998;69:1183–92.
45. Cortellini P, Pini Prato G, Tonetti MS. Periodontal regeneration of human intrabony defects: II—re-entry procedures and bone measures. *J Periodontol* 1993;64:261–8.
46. Bowers GM, Schallhorn RG, McClain PK, Morrison GM, Morgan R, Reynolds MA. Factors influencing the outcome of regenerative therapy in mandibular class II furcations: part I. *J Periodontol* 2003;74:1255–68.