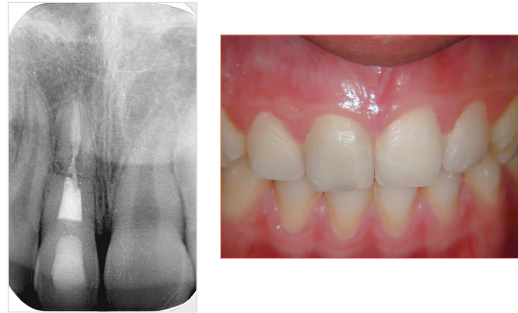

Horizontal root fracture

Marga Ree

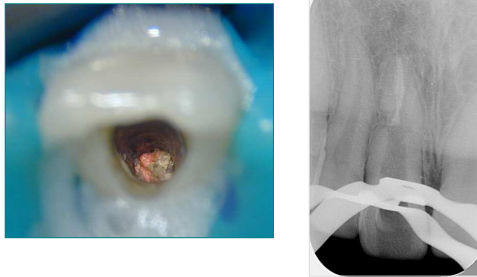
M.Ree

Persistent complaints following trauma in a 13 year old boy



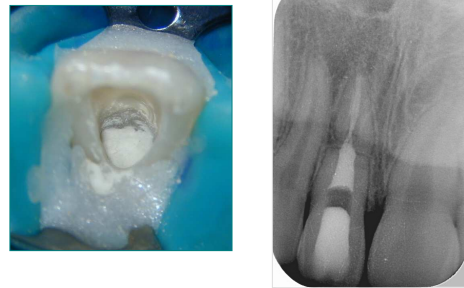
M.Ree

Retreatment till fracture level



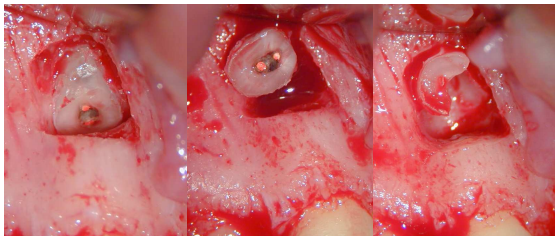
M.Ree

Coronal segment filled with MTA



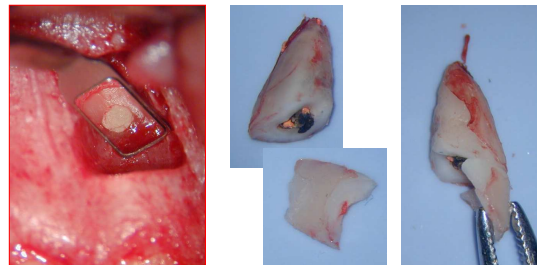
M.Ree

Removal of apical fragment in 2 parts



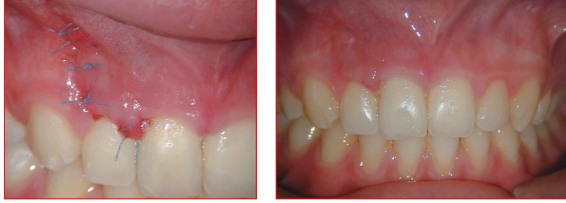M.Ree

Inspection fracture surface and reconstruction of fracture line



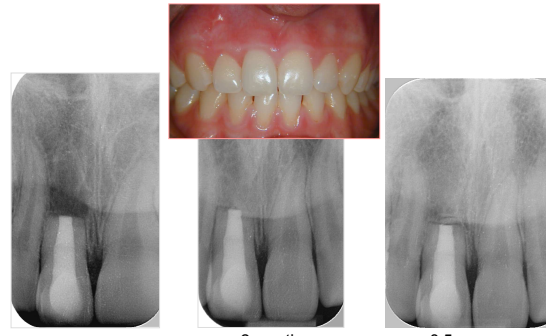M.Ree

5 days post surgery



M.Ree

Follow-up



2 months

3.5 years

M.Ree