

A micro-computed tomographic evaluation of apical root canal preparation using three instrumentation techniques

J. Moore, P. Fitz-Walter & P. Parashos

Melbourne Dental School, The University of Melbourne, Melbourne, Victoria, Australia

Abstract

Moore J, Fitz-Walter P, Parashos P. A micro-computed tomographic evaluation of apical root canal preparation using three instrumentation techniques. *International Endodontic Journal*, 42, 1057–1064, 2009.

Aim To investigate the morphological changes in the apical third of the root canal after preparation with three techniques.

Methodology Forty molar teeth were scanned using micro-computed tomography before and after instrumentation with: Group 1 – stainless steel K-files using the balanced force technique; Group 2 – stainless steel K-files (balanced force) and then refining the apical preparation with the equivalent size 0.04 taper FlexMaster instrument; Group 3 – a hybrid ProTaper/FlexMaster (ProFile for sizes 45 and 60) sequence. Eight canals were excluded because of artefacts in the images or unnegotiable blockages leaving 110 canals that could be analysed. Apical root canal preparation was evaluated with respect to the amount of dentine removed, canal roundness, transportation and how the dimensions of the prepared

apical root canal correlated with those of the final instrument used.

Results The median apical preparation sizes for the three groups respectively were: 30, 30 and 40. Despite the larger size and less experienced operator, the volumetric change (the amount of dentine removed) in canals prepared with a hybrid rotary nickel–titanium instrumentation technique remained small and, a more rounded preparation ($P < 0.001$) that closely matched the final instrument dimensions ($P < 0.001$) was produced. There was a trend for less canal transportation using rotary nickel–titanium instruments.

Conclusions Stainless steel hand preparation was not conservative of apical dentine. When used correctly, even by less experienced operators, rotary nickel–titanium instruments were able to precisely ‘machine’ a canal to larger apical sizes with minimal risk of iatrogenic damage.

Keywords: apical preparation, micro-computed tomography, rotary NiTi, transportation.

Received 15 November 2008; accepted 15 July 2009

Introduction

It is well established that intra-radicular microbial infection is the primary cause of apical periodontitis (Kakehashi *et al.* 1965, Sundqvist 1976, Möller *et al.* 1981). Instrumentation forms an integral part of the

process of eliminating or reducing the number of microorganisms to a level that will allow healing of the periapical tissues (Byström & Sundqvist 1981).

Technically, the goal of endodontic instrumentation is to remove all necrotic and vital pulp tissue along with heavily infected radicular dentine. Instrumentation also shapes the root canals for improved irrigation, placement of intracanal medicaments and facilitates obturation to a high technical standard (Haapasalo *et al.* 2005). However, any instrumentation that removes excessive dentine and substantially changes the canal anatomy will not only lead to iatrogenic

Correspondence: Peter Parashos, Melbourne Dental School, Faculty of Medicine Dentistry and Health Sciences, The University of Melbourne, 720 Swanston Street, Melbourne, Vic. 3010, Australia (Tel.: +613 9341 1472; fax: +613 9341 1599; e-mail: parashos@unimelb.edu.au).

preparation errors (Weine *et al.* 1975, 1976) but it may adversely affect the strength of the tooth (Sathorn *et al.* 2005, Versluis *et al.* 2006).

Micro-computed tomography (micro-CT) is a nondestructive analytical method that has enabled researchers to examine the effects of root canal instrumentation in three-dimensions (Nielsen *et al.* 1995, Peters *et al.* 2000, Rhodes *et al.* 2000, Bergmans *et al.* 2001). A number of investigations have now been carried out using micro-CT to examine the effects of different hand and rotary instrumentation techniques on root canal anatomy (Peters *et al.* 2001a,b, 2003, Bergmans *et al.* 2002, 2003, Hübscher *et al.* 2003). However, none has specifically focussed on the apical portion of the root canal or how the preparation dimensions relate to the final instrument used.

This is an area of interest, as there is evidence that the apical portion of the root canal may harbour a critical level of microorganisms that could maintain apical periodontitis (Nair *et al.* 1990) and that increased apical debridement improves reduction in the microbial levels (Siqueira *et al.* 1999, Shuping *et al.* 2000, Card *et al.* 2002, Rollison *et al.* 2002). Larger apical preparation sizes will decrease the amount of infected dentine, pulpal debris and canal irregularities (Tan & Messer 2002), as well as improving efficacy of irrigant solutions (Shuping *et al.* 2000, Khademi *et al.* 2006) and potentially clinical outcomes. Furthermore, considering that the average size of the apical canal is approximately 0.30–0.35 mm (Kuttler 1955, Kerekes & Tronstad 1977), preparation to larger apical sizes appears logical (Spångberg 2001).

Despite these benefits and knowledge of the apical canal anatomy, the concept of larger apical sizes has not been widely adopted because of concern over iatrogenic apical preparation errors. The aim of this study was to investigate the morphological changes in the apical third of root canals after preparation with three instrumentation techniques using micro-CT scanning.

Materials and methods

Ethics approval for this research project was obtained from the Health Sciences Human Ethics Sub-Committee, The University of Melbourne, Melbourne, Victoria, Australia (Ethics ID: 0714905).

Preparation of specimens

Twenty-one maxillary and nineteen mandibular first molar teeth with no history of endodontic treatment

were used. All teeth were stored in 0.9% saline solution. Caries and restorations were removed and access cavities prepared with a high speed diamond bur. The occlusal surface was reduced by 2 mm to provide reproducible reference points and positioning in the micro-CT scanners (SkyScan 1072 and SkyScan 1076, Kontich, Belgium).

Teeth were mounted in the scanners with the flat occlusal surfaces against an SEM stub (SkyScan 1072, Kontich, Belgium) or resin disc (SkyScan 1076, Kontich, Belgium) to allow reproducible orientation in the pre- and post-instrumentation micro-CT scans. All teeth were scanned by micro-CT prior to negotiation of canals. No attempt was made to instrument second mesio-buccal canals because their anatomy was too variable and it may have compromised the assessment of the main mesio-buccal canal.

Canals were negotiated to patency with size 8 and 10 Hedström files (Dentsply Maillefer, Ballaigues, Switzerland) and working length was set 1 mm from the apical foramen. Digital radiographs were taken from buccolingual and mesio-distal directions with size 10 Hedström files (Dentsply Maillefer, Ballaigues, Switzerland) in the canals to allow calculation of canal angles and radius of curvature using image processing software (ImageTool v3.0; UT Health Science Centre, San Antonio, TX, USA) for incorporation into the statistical analysis (Schneider 1971, Pruett *et al.* 1997). Teeth were divided evenly, ensuring an equitable distribution of canal numbers, canal curvatures and radii between the two operators and the canals were allocated into groups representing three instrumentation protocols.

Group 1 was prepared by one operator using Gates Glidden burs 2 and 3 (Dentsply Maillefer) for coronal flaring and gaining straight line access to the middle third, and the balanced force technique (Roane *et al.* 1985) with stainless steel K-files (Dentsply Maillefer) for the remaining preparation. All the mesio-buccal canals of maxillary and mandibular teeth in Group 1 were refined with the corresponding FlexMaster 0.04 taper (VDW, Munich, Germany) rotary nickel-titanium instrument (e.g. 30 K-file refined with size 30, 0.04 taper FlexMaster) used in a torque-controlled handpiece (Endo IT Professional, VDW, Munich, Germany) at manufacturer recommended settings. Those canals were then considered a separate group (Group 2) in the analysis of the results. Group 3 was prepared by the second operator using a hybrid rotary instrumentation technique similar to that described by Walsch (2004). After negotiation

with a size 15 Hedström file (Dentsply Maillefer), ProTaper S1, S2 and F1 (Dentsply Maillefer) were used to working length. The apical preparation was finished with a FlexMaster 0.04 taper nickel–titanium instrument (VDW). In situations where 0.04 taper instruments larger than size 40 were required but not available in the FlexMaster range, ProFile 0.04 taper rotary nickel–titanium instruments (Dentsply Maillefer) were used (i.e. sizes 45 and 60). All rotary nickel–titanium instruments were used in a torque-controlled handpiece (Endo IT Professional, VDW, Munich, Germany) at manufacturer recommended settings.

New instruments were used for each tooth and 1% sodium hypochlorite was used as an irrigant. The method used to determine the final apical preparation size in Groups 1 and 2 (where the balanced force technique was utilized) was based on the original Grossman criterion of three sizes larger than the first file that bound at working length (Grossman *et al.* 1988). In Group 3, the operator observed the apical portion of the instrument for the presence of dentine debris. Once the instrument flutes in the apical third were loaded with dentine debris, the apical preparation was considered to be complete. The minimum, median and maximum master apical file sizes for each group are presented in Table 1. The preparation technique described for Group 1 was chosen because that operator had successfully used it in private specialist endodontic practice for over 20 years. The technique described in Group 2 was a recent modification to it. The canal preparation technique used for Group 3 was what is taught in the graduate endodontic programme at the Melbourne Dental School and as such the second operator was familiar with it, having used it exclusively for over 2 years.

Micro-CT measurements and evaluations

The micro-CT machines (SkyScan 1072 and 1076, Kontich, Belgium) were used at 80 kV to scan the specimens. Two machines were used in order to allow scanning in the shortest period of time. Both scanners produced the same resolution images and all the scans were analysed with the same software. The same machine was used for a specific tooth before and after instrumentation to avoid inter-machine variability. Typically 700–900 slices (voxel size $17.4 \times 17.4 \times 17.4 \mu\text{m}$) were scanned per tooth. Canals were reconstructed using NRecon volumetric reconstruction software (v1.4.4. SkyScan, Kontich, Belgium) and analysed with CT Analyser image analysis software (v1.6.1.1. SkyScan, Kontich, Belgium). Of the original 118 root canals, eight (two from Group 1, one from Group 2 and five from Group 3) had to be excluded because of artefacts in either the pre or post-instrumentation images or blockages that prevented negotiation to the apical foramen. This left a total of 110 root canals that could be analysed quantitatively.

The volume of interest was set using the technique described by Peters *et al.* (2000). However, the vertical range was limited to 7 mm from the apical foramen allowing calculation of the amount of dentine removed and the roundness of the apical 6 mm of canal preparation. In contrast, canal transportation and the difference between the canal dimensions and those of the final instrument used were only calculated over the apical 1 mm of canal preparation (located 1–2 mm from the apical foramen).

The amount of dentine removed was represented by the change in volume (Δ Volume) and was calculated as the difference between the pre- and post-instrumentation canal values. The post-instrumentation struc-

Table 1 Group information and morphometric scores evaluating apical canal preparation (mean \pm SD)

Group	<i>n</i>	Minimum, Median, Maximum MAF	Δ Volume (mm^3)	Structural model index	Δ Centroid (mm)	Δ Diameter (mm)
1	39	25, 30, 35	1.00 ± 0.66	2.63 ± 0.18	0.060 ± 0.047	0.026 ± 0.020
2	18	25, 30, 30	0.94 ± 0.58^c	2.66 ± 0.15	0.076 ± 0.052	0.023 ± 0.018^d
1/2	57	25, 30, 35	0.98 ± 0.63	2.64 ± 0.17	0.065 ± 0.049	0.025 ± 0.019
3	53	30, 40, 60	0.96 ± 0.47	2.83 ± 0.12^a	0.052 ± 0.057	0.013 ± 0.012^b

Master apical file (MAF) values refer to the minimum, median or maximum final instrument size used in any canal in that particular group.

^aStatistically different from Group 1 ($P < 0.001$), Group 2 ($P = 0.003$) and combined Group 1/2 ($P < 0.001$).

^bStatistically different from Group 1 ($P = 0.007$) and combined Group 1/2 ($P < 0.001$).

^cMean is less than Group 1 because this group does not contain any P or D canals which had the highest mean Δ Volume scores (1.03 and 1.27 mm^3 respectively).

^dMean is less than Group 1 because the average instrument diameter is larger, making the difference between the preparation and instrument dimensions smaller.

tural model index (SMI) was recorded to quantify the canal 'roundness' (Lorensen & Cline 1987, Hildebrand & Rügsegger 1997b, Peters *et al.* 2000). SMI values will range between 0 and 4, where 0 corresponds to an ideal plate, 3 an ideal cylinder and 4 a sphere (Hildebrand & Rügsegger 1997b). In an endodontic application of this morphological parameter, the closer a value is to 3, the closer the preparation represents a cylinder and the 'rounder' the canal (Peters *et al.* 2000).

The average canal diameter, described by Hildebrand & Rügsegger (1997a), was calculated over the apical 1 mm of the preparation and compared to the theoretical average diameter of the master apical file (MAF). Any difference was recorded as Δ Diameter and indicated how the preparation dimensions correlated with those of the MAF. Transportation (Δ Centroid) over the apical 1 mm of canal preparation was also recorded. This involved calculating the three-dimensional distance between the centre of the canal and the centre of the external root surface using a Euclidean distance calculator (Teknomo 2006). Any change between the pre- and post-instrumentation distances represented transportation.

Statistical analysis

Means and standard deviations were calculated for each test group and analysed using Minitab[®] 15.1.1.0 (2007). ANOVA tests were conducted to determine if there was any statistical difference between the experimental groups for a special outcome variable at $P = 0.05$. Where a statistical difference between groups was noted, pair-wise analysis was undertaken using Fisher's LSD (least significant difference) test.

To determine the impact of any pre- or intra-operative variable (working length, canal angle, radius of curvature, presence of an s-shaped canal and MAF), the ANOVA model was refit and pair-wise analysis using Fisher's LSD test was used when a statistical difference was noted between groups. Analysis was conducted without the pre-operative variables of S-shaped canals because of the lack of a unique canal angle or radius. The complete statistical analysis was repeated after data from Groups 1 and 2 were combined.

Results

Scanning of the canals before and after instrumentation produced cross-sectional images that were examined for shape and the presence of any procedural

errors. The cross-sections were subsequently reconstructed and analysed to quantify the three-dimensional morphological changes in each canal. Generally, as is demonstrated in Fig. 1, rotary nickel–titanium instruments maintained the original canal position, produced round, uniformly tapered preparations and were free from procedural errors. Canals prepared with stainless steel instruments had a more irregular cross-sectional appearance and taper, with deficiencies noted apically and where Gates Glidden instruments were used to remove dentine irregularities and interferences.

A summary of the data is presented in Table 1. As Group 2 was essentially the same preparation technique as Group 1, but with the final canal shape refined using a rotary nickel–titanium instrument, those two groups were combined for further statistical analysis (Group 1/2). The mean (\pm SD) bucco-lingual angle and radius of curvature for all the canals were 20.03 ± 13.23 degrees and 5.60 ± 1.55 mm respectively; and the mean (\pm SD) mesio-distal canal angle and radius of curvature were 13.65 ± 11.21 degrees and 5.61 ± 1.64 mm respectively.

The only statistical differences observed between the experimental groups were how 'round' the canals were (SMI) and how close the prepared canal dimensions were to the final instrument used (Δ Diameter). The SMI in Group 3 (2.83 ± 0.12) was statistically different from Group 1 and Group 2 as well as the combined Group 1/2 ($P < 0.001$, $P = 0.003$ and $P < 0.001$ respectively). With respect to the Δ Diameter, Group 3 was statistically different from Group 1 and the combined Group 1/2 ($P = 0.007$ and $P < 0.001$ respectively). The amount of dentine removed (Δ Volume) and the canal transportation (Δ Centroid) were less in Group 3 compared to Group 1 and the combined Group 1/2 however, the results were not statistically different.

Structural model index and Δ Diameter were further analysed using an ANOVA model adjusting for pre- and intra-operative variables. Group 1 always remained statistically different from Group 3 with respect to both SMI and Δ Diameter. However, increasing the MAF had a detrimental effect on canals in Group 2 with the Group 2–3 comparison of Δ Diameter becoming statistically significant ($P = 0.036$). When examining the effect of the canal angle, as it increased, the mean Δ Diameter of Groups 1 and 2 became significant ($P < 0.001$). These results indicated that the two influential factors on the results were the final instrument size (MAF) and the canal angle. As either of those was increased, the difference between the instrumen-

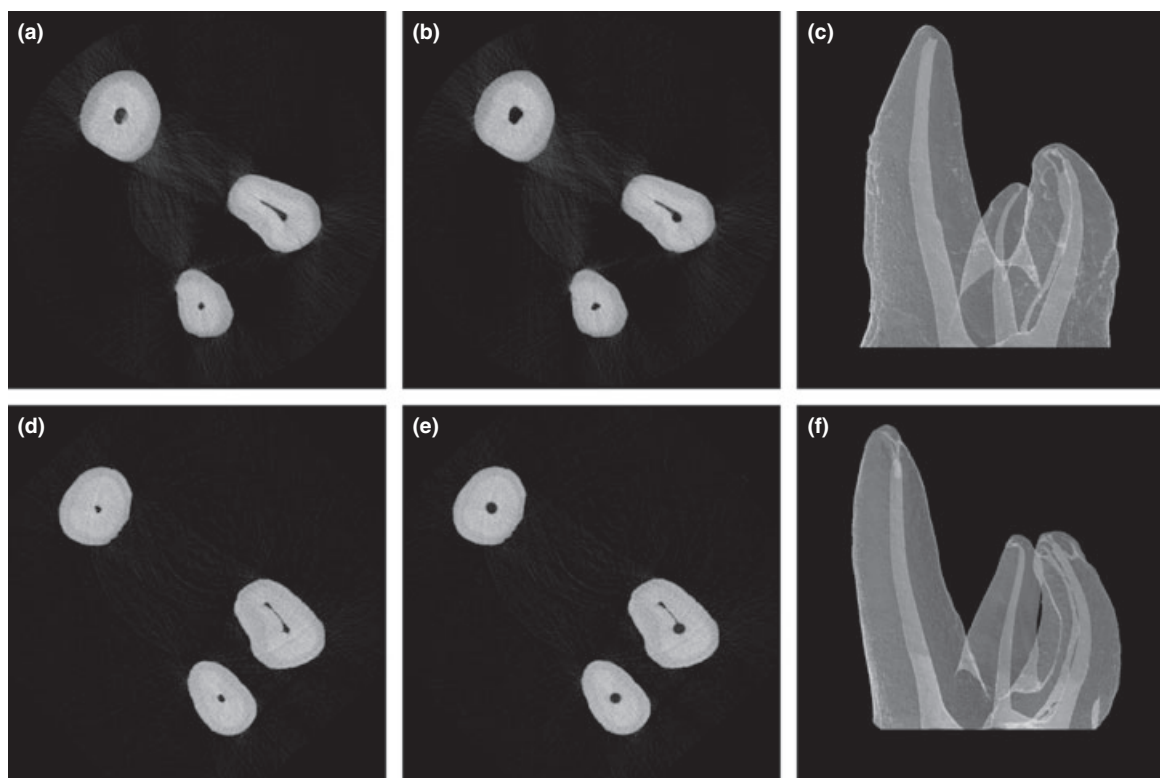


Figure 1 Examples of micro-computed tomography (micro-CT) cross-sectional images from the apical third of root canals and the three-dimensional reconstructions. Pre-instrumentation (a) and post-instrumentation (b) micro-CT slices of a tooth prepared using Gates Glidden drills and stainless steel K-files then refined with a rotary nickel–titanium instrument in the MB canal (final preparation sizes: MB 30/0.04, DB 25/0.02, P 35/0.02); three-dimensional reconstruction of tooth presented in a–b (c); pre-instrumentation (d) and post-instrumentation (e) micro-CT slices of a tooth prepared using rotary nickel–titanium instruments (final preparation sizes: MB 40/0.04, DB 40/0.04, P 45/0.04); three-dimensional reconstruction of tooth presented in d–e (f). Note the rounder, more centered preparations in canals prepared with rotary nickel–titanium instruments (e) and the excessive dentine removal from Gates Glidden preparation steps (c).

tation techniques became more noticeable. When Groups 1 and 2 were combined and the analysis repeated, no pre- or intra-operative variable was found to be influential. As the preparation in each group was only performed by one operator, it was not possible to determine the effect of group over operator in the statistical analysis.

Discussion

The principal limitations concerning the methodology of this study were the fact that the final instrument size (MAF) was not standardized and that the experience of the operators varied greatly. The nonstandardized apical preparation sizes do make a direct comparison of the change in volume (Δ Volume) and the conclusions drawn from it initially seem invalid. However,

when consideration is given to the fact that the median MAF in Group 3 is the largest, yet the change in volume remains small, it would appear that the results do in fact support the hypothesis that rotary nickel–titanium instruments are conservative in the total amount of dentine they remove. A similar argument could be proposed with respect to operator variability and the effect on the results. Whilst it cannot be ruled out statistically, as the less experienced operator actually achieved better results, this would seem to offer support to the notion that it was the technique rather than the operator that had the greatest effect on the results seen in this investigation.

The morphological parameters measured in this study have been previously described and applied to endodontic investigations in the literature (Peters *et al.* 2000, 2001a,b, 2003, Bergmans *et al.* 2002, 2003,

Hübscher *et al.* 2003). However, the results of this study are not directly comparable because of the different area of interest. All of the previous studies (Peters *et al.* 2001a,b, 2003, Bergmans *et al.* 2002, 2003, Hübscher *et al.* 2003) examined the entire length of the canal (apical foramen to furcation) whereas this study was only interested in the apical portion. Consequently, Δ volume was not as large as that seen in Peters *et al.* (2001a,b, 2003), Bergmans *et al.* (2002, 2003) or Hübscher *et al.* (2003) and postoperative SMI was smaller because of the more complex apical morphology.

The results for transportation were similar to previous studies, though again, it is difficult to compare them because Peters *et al.* (2001a,b, 2003) and Hübscher *et al.* (2003) measured changes in centroid over a larger range and Bergmans *et al.* (2002, 2003) measured movement in eight different directions, not stating an overall figure. A recent study (Cheung & Cheung 2008) has compared the final canal dimensions to that of the final instrument used and concluded similarly to this study, that the final preparation taper and dimensions closely match those of the rotary nickel–titanium instruments used. However, whilst a similar trend is observed, because they did not state the actual values in their paper, a direct comparison of results is not possible.

The results of this study indicated that a hybrid rotary instrumentation technique (Group 3) (Walsch 2004), removed similar or less dentine despite the largest median MAF size. The hybrid technique also produced the least mean transportation although both these findings were not statistically significant. Canals prepared by rotary nickel–titanium instruments (Group 3) were statistically rounder and the dimensions more closely matched that of the final instrument used. This correlates well with the results showing less dentine removal (Δ Volume) and less transportation (Δ Centroid). Investigation into the effects of pre- and intra-operative variables revealed that the canal angle and MAF had an impact on the results. As the canal angle or the MAF size was increased, the difference between Group 3 and either Group 1 or 2 became more obvious, reflecting the advantages of rotary nickel–titanium instruments over that of stainless steel in curved root canals. Clinically, this would equate to a more ‘conservative’ and ‘safer’ preparation despite the increased apical debridement.

The results of this study agree with previous investigations into the advantages of rotary nickel–titanium instruments over stainless steel instruments (Esposito &

Cunningham 1995, Glossen *et al.* 1995). However, they are not as dramatic because the methodology in this study did not specify an MAF size. Instead, each was prepared to a size determined by the operator to be appropriate for the specific canal which may be less scientifically valuable but more clinically relevant.

The clinical implications of this study are that using a predominantly stainless steel hand preparation technique may not be as conservative of apical root canal dentine and that when used correctly, even by less experienced practitioners, rotary nickel–titanium instruments are able to precisely prepare a canal to larger apical sizes with minimal risk of iatrogenic damage.

Conclusion

The results of this study suggest that a hybrid rotary nickel–titanium instrumentation technique produces rounder canals ($P < 0.001$) whose dimensions more closely match those of the final instrument used ($P < 0.001$). They also highlight the trend that despite a larger median apical preparation size, rotary nickel–titanium instruments remove less total dentine and result in less transportation. This was especially the case in canals with more severe curvatures where undesired apical dentine removal by stainless steel instruments became more pronounced.

Based on this evidence and that of previous studies comparing stainless steel hand preparation with rotary nickel–titanium instrumentation, using rotary nickel–titanium instruments to prepare root canals to larger apical sizes (around 0.40 mm) is supported and carries a minimal risk of iatrogenic damage even in the hands of less experienced operators.

Acknowledgements

This study was supported by a grant from the Australian Society of Endodontology Incorporated. All endodontic instruments were donated by Dentsply (Australia) Pty Ltd and Gunz Dental. Sandy Clarke, from the Statistical Consulting Centre, University of Melbourne provided statistical support.

References

- Bergmans L, Van Cleynenbreugel J, Wevers M, Lambrechts P (2001) A methodology for quantitative evaluation of root canal instrumentation using microcomputed tomography. *International Endodontic Journal* **34**, 390–8.

- Bergmans L, Van Cleynenbreugel J, Beullens M, Wevers M, Van Meerbeek B, Lambrechts P (2002) Smooth flexible versus active tapered shaft design using NiTi rotary instruments. *International Endodontic Journal* **35**, 820–8.
- Bergmans L, Van Cleynenbreugel J, Beullens M, Wevers M, Van Meerbeek B, Lambrechts P (2003) Progressive versus constant tapered shaft design using NiTi rotary instruments. *International Endodontic Journal* **36**, 288–95.
- Byström A, Sundqvist G (1981) Bacteriologic evaluation of the efficacy of mechanical root canal instrumentation in endodontic therapy. *Scandinavian Journal of Dental Research* **89**, 321–8.
- Card SJ, Sigurdsson A, Ørstavik D, Trope M (2002) The effectiveness of increased apical enlargement in reducing intracanal bacteria. *Journal of Endodontics* **28**, 779–83.
- Cheung LHM, Cheung GSP (2008) Evaluation of a rotary instrumentation method for c-shaped canals with micro-computed tomography. *Journal of Endodontics* **34**, 1233–8.
- Esposito PT, Cunningham CJ (1995) A comparison of canal preparation with nickel–titanium and stainless steel instruments. *Journal of Endodontics* **21**, 173–6.
- Glossen CR, Haller RH, Dove SB, del Rio CE (1995) A comparison of root canal preparations using Ni–Ti hand, Ni–Ti engine-driven, and K-Flex endodontic instruments. *Journal of Endodontics* **21**, 146–51.
- Grossman LI, Oliet S, del Rio CE (1988) Preparation of the root canal: equipment and technique for cleaning, shaping and irrigation. In: Grossman LI, Oliet S, del Rio CE, eds. *Endodontic practice*, 11th edn. Philadelphia: Lea & Febiger, pp. 179–227.
- Haapasalo M, Endal U, Zandi H, Coil JM (2005) Eradication of endodontic infection by instrumentation and irrigation solutions. *Endodontic Topics* **10**, 77–102.
- Hildebrand T, Rügsegger P (1997a) A new method for the model-independent assessment of thickness in three-dimensional images. *Journal of Microscopy* **185**, 67–75.
- Hildebrand T, Rügsegger P (1997b) Quantification of bone microarchitecture with the structural model index. *Computer Methods in Biomechanics and Biomedical Engineering* **1**, 15–23.
- Hübscher W, Barbakow F, Peters OA (2003) Root-canal preparation with FlexMaster: canal shapes analysed by micro-computed tomography. *International Endodontic Journal* **36**, 740–7.
- Kakehashi S, Stanley HR, Fitzgerald RJ (1965) The effect of surgical exposures of dental pulps in germ-free and conventional laboratory rats. *Oral Surgery Oral Medicine Oral Pathology Oral Radiology and Endodontology* **20**, 340–9.
- Kerekes K, Tronstad L (1977) Morphometric observations on the root canals of human molars. *Journal of Endodontics* **3**, 114–8.
- Khademi A, Yazdizadeh M, Feizianfard M (2006) Determination of the minimum instrumentation size for penetration of irrigants to the apical third of root canal systems. *Journal of Endodontics* **32**, 417–20.
- Kuttler Y (1955) Microscopic investigation of root apices. *Journal of the American Dental Association* **50**, 544–52.
- Lorensen WE, Cline HE (1987) Marching cubes: a high resolution 3D surface construction algorithm. *Computer Graphics* **21**, 163–9.
- Möller AJ, Fabricius L, Dahlén G, Öhman AE, Heyden G (1981) Influence on periradicular tissues of indigenous oral bacteria and necrotic pulp tissue in monkeys. *Scandinavian Journal of Dental Research* **89**, 475–84.
- Nair PRN, Sjögren U, Krey G, Kahnberg KE, Sundqvist G (1990) Intraradicular bacteria and fungi in root-filled, asymptomatic human teeth with therapy-resistant periapical lesions: a long-term light and electron microscopic follow-up study. *Journal of Endodontics* **16**, 580–8.
- Nielsen RB, Alyassin AM, Peters DD, Carnes DL, Lancaster J (1995) Microcomputed tomography: an advanced system for detailed endodontic research. *Journal of Endodontics* **21**, 561–8.
- Peters OA, Laib A, Rügsegger P, Barbakow F (2000) Three-dimensional analysis of root canal geometry by high-resolution computed tomography. *Journal of Dental Research* **79**, 1405–9.
- Peters OA, Laib A, Göhring TN, Barbakow F (2001a) Changes in root canal geometry after preparation assessed by high-resolution computed tomography. *Journal of Endodontics* **27**, 1–6.
- Peters OA, Schönenberger K, Laib A (2001b) Effects of four Ni–Ti preparation techniques on root canal geometry assessed by micro computed tomography. *International Endodontic Journal* **34**, 221–30.
- Peters OA, Peters CI, Schönenberger K, Barbakow F (2003) ProTaper rotary root canal preparation: effects of canal anatomy on final shape analysed by micro CT. *International Endodontic Journal* **36**, 86–92.
- Pruett JP, Clement DJ, Carnes DL Jr (1997) Cyclic fatigue testing of nickel–titanium endodontic instruments. *Journal of Endodontics* **23**, 77–85.
- Rhodes JS, Ford TR, Lynch JA, Liepins PJ, Curtis RV (2000) A comparison of two nickel–titanium instrumentation techniques in teeth using microcomputed tomography. *International Endodontic Journal* **33**, 279–85.
- Roane JB, Sabala CL, Duncanson MG (1985) The “balanced force” concept for instrumentation of curved canals. *Journal of Endodontics* **11**, 203–11.
- Rollison S, Barnett F, Stevens RH (2002) Efficacy of bacterial removal from instrumented root canals in vitro related to instrumentation technique and size. *Oral Surgery Oral Medicine Oral Pathology Oral Radiology and Endodontology* **94**, 366–71.
- Sathorn C, Palamara JEA, Messer HH (2005) A comparison of the effects of two canal preparation techniques on root fracture susceptibility and fracture pattern. *Journal of Endodontics* **31**, 283–7.

- Schneider SW (1971) A comparison of canal preparations in straight and curved root canals. *Oral Surgery Oral Medicine Oral Pathology Oral Radiology and Endodontology* **32**, 271–5.
- Shuping GB, Ørstavik D, Sigurdsson A, Trope M (2000) Reduction of intracanal bacteria using nickel–titanium rotary instrumentation and various medications. *Journal of Endodontics* **26**, 751–5.
- Siqueira JF, Lima KC, Magalhães FA, Lopes HP, de Uzeda M (1999) Mechanical reduction of the bacterial population in the root canal by three instrumentation techniques. *Journal of Endodontics* **25**, 332–5.
- Spångberg L (2001) The wonderful world of rotary root canal preparation. *Oral Surgery Oral Medicine Oral Pathology Oral Radiology and Endodontology* **92**, 479.
- Sundqvist G (1976) *Bacteriological studies of necrotic dental pulps* (Dissertation). Umeå, Sweden: Umeå University.
- Tan BT, Messer HH (2002) The quality of apical canal preparation using hand and rotary instruments with specific criteria for enlargement based on initial apical file size. *Journal of Endodontics* **28**, 658–64.
- Teknomo K (2006) Similarity measurement. [Website, updated 2006]. URL <http://people.revoledu.com/kardi/tutorial/Similarity/EuclideanDistance.html> [accessed on 14 December 2007].
- Versluis A, Messer HH, Pintado MR (2006) Changes in compaction stress distributions in roots resulting from canal preparation. *International Endodontic Journal* **39**, 931–9.
- Walsch H (2004) The hybrid concept of nickel–titanium rotary instrumentation. *Dental Clinics of North America* **48**, 183–202.
- Weine FS, Kelly RF, Lio PJ (1975) The effect of preparation procedures on original canal shape and on apical foramen shape. *Journal of Endodontics* **1**, 255–62.
- Weine FS, Kelly RF, Bray KE (1976) Effect of preparation with endodontic handpieces on original canal shape. *Journal of Endodontics* **2**, 298–303.