

# Bone level around endodontically treated teeth in periodontitis patients

M.F. Timmerman<sup>1,2</sup> and  
G.A. Van der Weijden<sup>1,2</sup>

<sup>1</sup>Department of Periodontology, ACTA, Amsterdam, The Netherlands; <sup>2</sup>Clinic for Periodontology Utrecht, Utrecht, The Netherlands

Timmerman MF, Van der Weijden GA. Bone level around endodontically treated teeth in periodontitis patients. *J Clin Periodontol* 2006; 33: 620–625. doi: 10.1111/j.1600-051X.2006.00958.x

## Abstract

**Objectives:** This retrospective study compared the marginal bone level of teeth with root canal fillings with contra-lateral teeth without.

**Methods:** Of 286 consecutive patients ( $\geq 35$  years), referred to practice for periodontology in the Netherlands, 67 full sets of radiographs contained  $\geq 1$  endodontically treated tooth and its contra-lateral tooth without root canal treatment. Bone level at the mesial and distal of these teeth was scored from the CEJ. In multi-rooted teeth, the presence of interradiolar radiolucency was assessed. The presence of posts, and periapical radiolucencies was assessed. Analysis for differences between treated teeth and contra-laterals was controlled for tooth surface, presence of a post and tooth type.

**Results:** The mean distance from the root filling to the apex was 2.6 mm. Periapical radiolucencies were found in 14%. The mean bone level was at 4.3 mm for endodontically treated teeth and at 3.7 mm for contra-laterals. Significantly more bone loss (0.6 mm) was found at the endodontically treated teeth. No difference was found between mesial and distal, teeth without and with posts and different tooth types. The presence of interradiolar radiolucency was more frequent in endodontically treated teeth (OR 2.1,  $p_{\text{McNemar test}} = 0.039$ ).

**Conclusion:** In periodontitis patients, teeth with endodontic treatment had more bone loss as compared with untreated contralaterals.

Key words: bone loss; periodontitis; root canal filling; root canal treatment

Accepted for publication 1 June 2006

In daily periodontal practice, patients who present themselves with periodontal disease frequently have one or more endodontically treated teeth. In patients without periodontal disease, no influence of the quality of endodontic treatment could be established on the periodontium (Miyashita et al. 1998). However, in periodontitis-prone patients, the presence of a periapical lesion was found to be associated with a lower marginal bone level (Jansson et al. 1995), less favourable healing response of periodontal tissues after periodontal therapy (Ehnevid et al. 1993a, b), deeper pockets (Jansson et al. 1993a), a higher risk of losing periodontal attachment (Jansson et al. 1993b) and a higher rate of progression of periodontal disease

(Jansson et al. 1995). In these studies, primarily the influence of the presence of radiographically diagnosed periapical lesions was investigated, rather than the effect of the presence of root canal fillings per se as characteristics of endodontic involvement. Furthermore, several forms of combined pathology of periodontal and endodontic origin have been described, mostly regarding severely advanced conditions, compromising the prognosis of the future of such teeth in a dramatic way (Simon et al. 1972, Zehnder et al. 2002, Bergenholtz & Hasselgren 2003)

The presence of a root canal filling could be considered as a definitive feature of endodontic involvement. The aim of the present retrospective study

was to investigate radiographically in periodontitis patients as to whether the presence of a root canal filling in a tooth has an effect on the marginal bone level as compared with the contra-lateral tooth without endodontic treatment.

## Material and Methods

This retrospective study was performed on a referral population of a practice limited to periodontology, in the city of Utrecht, located in the centre of the Netherlands. All consecutive patients who had their first consultation in a continuous period of 6 months and who were diagnosed as having chronic periodontitis were included in the study. All patients  $\geq 35$  years of age and

documented with a full set of radiographs were selected for further examination of the radiographs.

The set of radiographs consisted of periapical exposures of all apices (16 for a full dentition), made with the help of commercially available bite blocks and aiming instruments (XCP, DentsplyRinn, Elgin, IL, USA) supplemented with four vertical bitewing radiographs, exposed with the help of an aiming instrument (Paro-Bite, KerrHawe, Bio-gio, Switzerland). Radiographs were taken by different operators according to a standardized procedure prescribing placement of film holders and order of areas to be exposed. Radiographs were exposed using a commercially available dental X-ray tube (Heliodent EC, 60 kV, 7 mA, Siemens Dental, Bensheim, Germany). In the lateral segments, 8 radiographs were made (two in each post-canine compartment, Kodak Insight IP-22, 31 × 41 mm, Rochester, NY, USA). For the distal radiograph, the bite block was placed distally from the mesial part of the first molar; for the mesial radiograph, the bite block was placed mesially from the distal part of the first molar. Radiographs were exposed for 0.32 s in the upper jaw and for 0.25 s in the lower jaw. In the frontal area, another eight periapical radiographs were made (two in each side of each jaw, Kodak Insight IP-12, 24 × 40 mm). For exposures of the canines, bite blocks were placed with the centre of the block at the cusp of the canine. The other radiographs were made with the centre of the block coinciding with the long axis of each of the first incisors. Radiographs were exposed for 0.25 s in the upper jaw and for 0.16 s in the lower jaw. Of the four vertical bite wings (Kodak Insight IP-22, 31 × 41 mm), the two most distal were exposed with the bite block between the second molars on each side. The bite blocks for mesial bite wings were placed mesially from the distal part of the first molar. Vertical bite wings were exposed for 0.32 s. All radiographs were processed in a commercially available daylight processor (Periomat Plus, Dürr Dental, Bietigheim-Bissingen, Germany) using a developer and fixer (Periomat-Intra, Dürr Dental, Bietigheim-Bissingen, Germany) that was replaced each 5 days.

All films of each patient were mounted in a commercially available frame for dental radiographs (Pocket-mount PM620 V, Adamount<sup>®</sup>, Milwaukee, WI, USA). Frames with full sets of

radiographs were studied on a commercially available X-ray viewer (X-ray viewer 31332, Clive Craig Co., Oxnard, CA, USA) in a separate room with dimmed light. For the purpose of the study, all radiographs were examined by two independent examiners. Measurements were performed under the same conditions and at different occasions. The results were compared. In those cases where differences occurred, final agreement on scores was reached through discussion. All sets of radiographs were screened for the presence of at least one endodontically treated tooth in combination with a contra-lateral tooth without a root canal treatment. Teeth restored either with or without a post were included in the study.

At these pairs of teeth, the marginal bone level was scored as the distance from the most coronal point with a periodontal membrane space of normal width (Schei et al. 1959) to the cemento-enamel junction (CEJ), both on the mesial and distal aspect of the tooth using a calibrated 15 mm periodontal probe (PCPUNC, HuFriedy, Chicago, IL, USA) under a magnification viewer (X-producter, Malmö, Sweden). When the CEJ was not detectable because of the presence of dental restorations, the distance was measured from the apical margin of the restoration.

Furthermore, furcation involvement was assessed by recording the presence of an inter-radicular radiolucency in multi-rooted teeth. The vertical distance from the radiographic roof of the furcation to the most apical margin of the inter-radicular bone level was recorded.

For each of the filled roots, the following data were recorded:

- root-filling material (silver cones, most probable gutta percha, other techniques);
- length of the root filling;
- distance from the radiographic contour of the apex to apical end of the root filling;
- distance of the coronal end of the root filling to the CEJ, constructed as the line connecting the mesial and distal level of the CEJ;
- length of the filled root measured as the shortest distance from the radiographic contour of the apex to the (constructed) CEJ;
- presence of a post;
- length of post, measured as the distance from the apical end of the post to the (constructed) CEJ; and

- distance from the apical end of the post to the coronal end of the remaining root filling.

In cases where teeth were restored with a crown, with the approximal margin more apically placed than the CEJ, the line connecting the mesial and distal margin of the crown was used as a reference.

Teeth were examined for apical pathology, by assessing the presence of periapical radiolucencies (radiolucency in connection with the apical part of the root, exceeding at least two times the width of the lateral part of the periodontal ligament, De Moor et al. 2000), lateral radiolucencies, widening of the periodontal ligament (widening of the apical part of the periodontal ligament not exceeding two times the width of the lateral periodontal ligament space, De Moor et al. 2000) and periapical radiopacities. The size of the radiolucent lesions was measured as the largest diameter that could be measured. Of the contra-lateral tooth, the root length was determined as described above.

From both teeth, the presence of caries and overhanging restorations was recorded.

On multi-rooted teeth for mesial/mesio-buccal roots, only the measurements of the bone level of the mesial aspect were recorded and for distal/disto-buccal roots only those of the distal aspect were recorded.

To reduce the influence of confounding factors, tooth pairs were eliminated that showed poor image quality, differences in projection geometry between radiographs of test and control teeth, a non-visible reference point (CEJ), inclined or rotated teeth or suspected iatrogenic injury.

#### Data analysis

Data on bone level for mesial and distal surface were analysed both separately and pooled as a mean score per tooth. Differences between endodontically treated teeth and their contra-laterals were tested using a Wilcoxon's test for matched pairs. A repeated-measures analysis was used to test for possible influences of the surface measured (mesial *versus* distal), presence of a post and tooth types on the differences between the endodontically treated teeth and their untreated contra-laterals. Regression analysis was applied to test for association of periodontal attach-

ment level with the presence of a radiolucency, distance of the endodontic filling from the radiographic apex and distance of the endodontic filling from the CEJ. The presence of inter-radiolar radiolucency in the endodontically treated, multi-rooted and in the untreated contra-laterals was compared using a McNemar test. To quantify the size of the effect, odds ratios were calculated.

*P*-values <0.05 were accepted as being statistically significant.

## Results

Evaluation of the full sets of radiographs provided 67 patients, in whom pairs of teeth were found to fulfill the selection criteria. The patient population consisted of 27 males and 40 females with an age ranging from 35 to 70 years (mean 47, SD 6.8). In these patients, a total of 108 pairs of teeth were present that could be examined. In 48 patients, endodontically treated teeth were restored without a post. This patient group provided 70 pairs of teeth: one pair in 28 subjects, two pairs in 18 subjects and three pairs in two subjects. In 30 patients, teeth with endodontic treatment were restored with a post, providing 38 pairs of teeth: one pair in 23 subjects, two pairs in six subjects and three pairs in one subject. In 11 patients, both teeth with and without a post could be examined.

## Endodontic conditions

The 108 endodontically treated teeth included 175 roots, of which, in 91% of these roots, the radiologic appearance of the canal obturation was very suggestive for gutta percha techniques. As is shown in Table 1, the mean distance of the apical end of the root canal filling to the radiologic terminus of the root was 2.6 mm ( $\pm$  2.3). Of these root fillings, 60% did not exceed a distance from the apex of 2 mm and 16% was found at 3 mm. A distance of between 6 and 11 mm was found for 10% of the roots. In seven roots, this measurement could not be performed.

The frequency of periapical radiolucencies was 14%. The mean diameter of periapical lesions was 3.0 mm (SD 2.4). Widening of the periodontal ligament was found in 11% of roots. A radiopaque aspect of the periapical region was found at 5% of roots (Table 1). No periapical radiolucencies, neither

Table 1. Characteristics of endodontic treatments of all evaluated roots, evaluated roots of teeth without a post and roots with a post

	All teeth	Teeth without a post	Teeth with a post	All roots
<i>N</i>	108	70	38	175
Distance apex–root canal filling (mm)	2.7 ( $\pm$ 2.4)	3.0 ( $\pm$ 2.6)	2.2 ( $\pm$ 1.8)	2.6 ( $\pm$ 2.3)
Length of root canal filling (mm)	9.6 ( $\pm$ 4.4)	11.5 ( $\pm$ 3.7)	6.0 ( $\pm$ 3.5)	9.3 ( $\pm$ 4.4)
Distance of CEJ–root canal filling (mm)	2.3 ( $\pm$ 3.9)	0.7 ( $\pm$ 2.5)	5.4 ( $\pm$ 4.2)	2.3 ( $\pm$ 3.8)
Number of apical radiolucencies	17 (16%)	10 (14%)	7 (18%)	25 (14%)
Widening of periodontal ligament	14 (13%)	9 (13%)	5 (13%)	20 (11%)
Number of apical radiopacities	5 (5%)	2 (3%)	3 (8%)	9 (5%)
Vertical dimension radiolucencies (mm)	3.1 ( $\pm$ 2.6)	3.6 ( $\pm$ 3.1)	2.4 ( $\pm$ 1.8)	3.0 ( $\pm$ 2.4)
Number gutta percha obturations	95 (88%)	64 (93%)	31 (82%)	158 (91%)
Number of sealer obturations	9 (8%)	4 (6%)	5 (13%)	13 (7%)
Number of silver cone obturations	2 (2%)	1 (1%)	1 (3%)	3 (2%)
Number without obturation	2 (2%)	1 (1%)	1 (3%)	1 (1%)

Standard deviation or % in parentheses.

No periapical radiolucencies, or widening of the periodontal ligament, or apical radiopacities were found for the contra-lateral study teeth without a root filling.

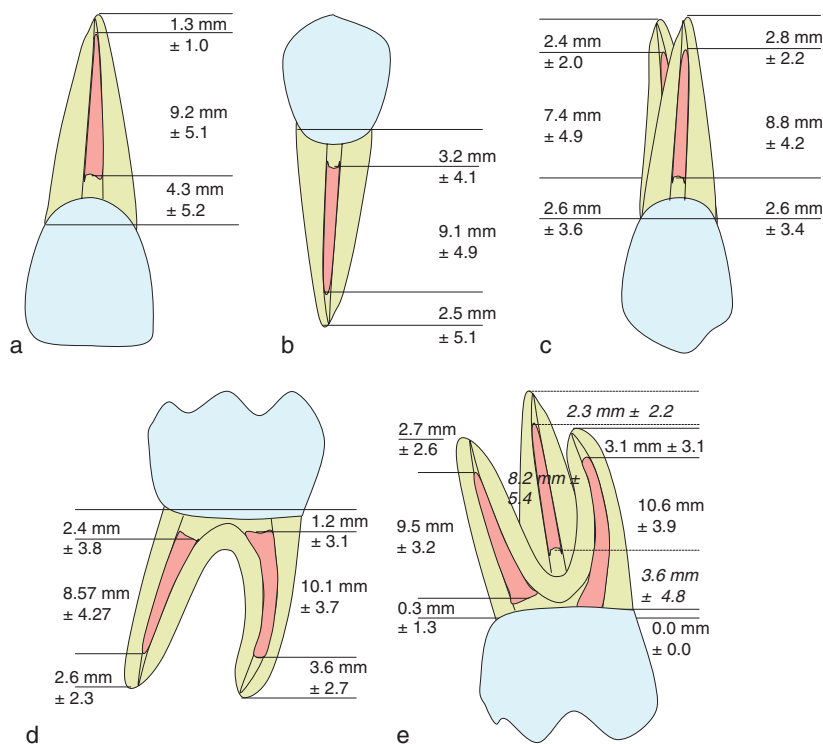


Fig. 1. Measures of endodontic fillings in (a) incisors and canines ( $n = 16$ ), (b) single rooted premolars, (c) 2-rooted premolars, (d) 2-rooted (lower) molars and (e) 3-rooted (upper) molars.

widening of the periodontal ligament, nor apical radiopacities were found for the contra-lateral study teeth without a root filling.

Figures 1a–e shows findings for the dimensions of root canal fillings in relation to the distribution of the number of roots in front teeth, pre-molars and molars. With 1.3 mm ( $\pm$  1.0), the mean distance from the apex to the apical end of the root filling is the smallest in incisors and canines (Fig. 1a). The largest mean for this distance was found at

the mesial apex of lower molars, with 3.6 mm ( $\pm$  3.6, Fig 1e).

In Table 2, the distribution of the teeth over the different tooth types is shown. The upper first molars were most frequently assessed, followed by upper and lower second pre-molars, lower first molars and upper first pre-molars.

## Periodontal conditions

The mean bone loss for the 70 endodontically treated teeth restored without

Table 2. Mean distance from cemento-enamel junction (CEJ) to marginal bone level (MBL) in mm. at mesial and distal aspects of roots of teeth with endodontic treatments compared with their untreated contralateral teeth, divided by tooth type and by presence or absence of posts

Tooth number	n (no post)	Distance CEJ-MBL		Distance CEJ-MBL contra lateral		n (post)	Distance CEJ-MBL		Distance CEJ-MBL contra lateral	
		mesial	distal	mesial	distal		mesial	distal	mesial	distal
11, 21	6	3.2 (1.2)	3.8 (1.0)	3.0 (0.9)	3.7 (1.2)	2	3.0 (0.0)	4.0 (0.0)	3.0 (0.0)	2.5 (0.7)
12, 22	2	6.0 (1.4)	6.0 (1.4)	3.5 (0.7)	4.0 (1.4)	3	4.3 (2.5)	4.0 (1.0)	3.3 (1.5)	4.3 (1.5)
13, 23	–					–				
14, 24	7	4.4 (2.8)	4.1 (1.6)	3.3 (1.0)	3.0 (1.0)	6	4.0 (2.2)	3.6 (1.3)	3.0 (1.1)	3.5 (0.5)
15, 25	7	3.3 (1.0)	3.9 (1.2)	3.4 (0.8)	4.7 (1.0)	8	4.3 (1.5)	4.1 (1.2)	3.4 (1.4)	4.1 (1.7)
16, 26	11	4.8 (1.7)	5.1 (2.2)	4.0 (1.9)	3.9 (1.6)	5	3.6 (1.3)	3.8 (0.8)	3.6 (1.1)	4.2 (1.3)
17, 27	3	5.3 (0.6)	6.3 (0.6)	4.7 (0.6)	4.3 (1.5)	–				
31, 41	–					–				
32, 42	1	4.0 (–)	5.0 (–)	4.0 (–)	5.0 (–)	–				
33, 43	2	8.5 (3.5)	5.0 (1.4)	4.5 (0.7)	5.0 (1.4)	–				
34, 44	6	2.3 (0.5)	3.3 (1.0)	2.2 (1.2)	2.7 (1.2)	1	5.0 (0.0)	4.0 (0.0)	3.0 (0.0)	4.0 (0.0)
35, 45	9	4.2 (2.2)	4.3 (1.4)	3.3 (0.7)	3.3 (1.5)	6	6.3 (5.4)	6.0 (5.4)	3.3 (0.5)	4.3 (1.5)
36, 46	9	3.9 (0.6)	4.6 (1.5)	3.6 (1.2)	4.4 (1.2)	5	3.6 (1.3)	4.2 (1.9)	3.4 (0.5)	4.6 (2.5)
37, 47	7	4.1 (1.8)	4.7 (1.6)	3.4 (1.0)	4.3 (2.0)	2	4.5 (0.7)	4.0 (0.0)	4.0 (1.4)	3.0 (0.0)
Total	70	4.2 (1.9)	4.5 (1.6)	3.5 (1.2)	3.9 (1.5)	38	4.3 (2.5)	4.3 (2.4)	3.3 (1.0)	4.0 (1.5)

Standard deviations in parentheses.

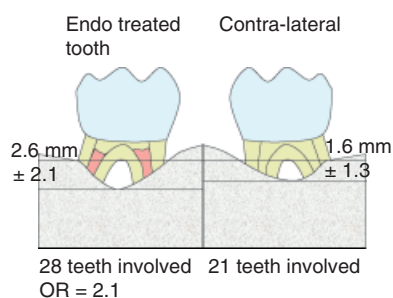


Fig. 2. Vertical component of inter-radicular radiolucency in endodontically treated teeth compared with untreated contralateral teeth ( $n = 30$ , no difference,  $p_{\text{Wilcoxon}} = 0.068$ ). Interradicular radiolucency more frequent in endodontically treated teeth ( $p_{\text{McNemar}} = 0.039$ ).

a post was 4.2 mm on the mesial aspect and 4.5 mm on the distal aspect. The untreated contra-lateral teeth showed a loss of 3.5 mm on the mesial and 3.9 mm on the distal aspect, respectively. A statistically significant difference with the contra-lateral tooth of 0.7 mm (SD 1.8, Wilcoxon's test,  $p = 0.0032$ ) was found for the mesial aspects and of 0.6 mm (SD 1.7, Wilcoxon's test,  $p = 0.0058$ ) for the distal aspects. For the 38 teeth with posts, both the mesial and the distal aspects showed a bone level at 4.3 mm. The contra-lateral teeth of this group showed 3.3 mm on the mesial and 4.0 mm on the distal aspect, respectively. A significant difference of 1.0 mm (SD 2.5, Wilcoxon's test,  $p = 0.0020$ ) was only found for the mesial aspects. For the distal aspects, this was 0.3 mm (SD 2.0).

The repeated-measures analysis, controlling for possible influences of the surface measured (mesial *versus* distal), presence of a post and for tooth types, showed a significant difference between the endodontically treated teeth and their untreated contra-laterals. No difference could be found between the mesial and distal aspects, nor between teeth without and with posts and between the different tooth types.

As shown in Fig. 2, the presence of inter-radicular radiolucency was more frequent in the endodontically treated teeth than in the untreated contra-lateral. The odds ratio was 2.1 (95% CFI (1.0, 4.5),  $p_{\text{McNemar test}} = 0.039$ ).

The vertical component of the furcation lesion (inter-radicular radiolucency) was  $2.6 \pm 2.1$  mm for endodontically treated teeth and  $1.6 \pm 1.3$  mm for untreated contra-laterals. No statistically significant difference was found for the vertical component of furcation lesions.

## Discussion

The present study investigated the possible influence of past endodontic therapy on periodontal attachment loss in periodontitis patients. As found in earlier studies, endodontic infection has an influence on several aspects of periodontal disease (Ehnevid et al. 1993a, b, Jansson et al. 1993a, b, 1995). The present sample was derived from a pool of radiographic information, gathered in one single practice restricted to periodontology.

Procedures for exposing and developing X-rays are well described and strictly followed in this centre. In this perspective, the radiographic material used can be considered as suitable for performing research in a conscientious way. To have the influence of the presence of a root canal filling as the most predominant factor involved, teeth with root canal fillings were compared with their untreated contra-laterals. This rules out inter-individual variance as a factor in the comparison between these two sets of teeth. A choice was made to perform measurements of marginal bone height in millimetres rather than as a percentage of the root length. Measuring the distance from the CEJ to the marginal bone crest is a difficult procedure. Independent measurements under magnification by two separate examiners reduce this problem.

As the underlying cause for the larger distance from the CEJ to the marginal bone at teeth that were endodontically treated as compared with their untreated contra-laterals, found in the present study, more demineralization and resorption of bone can be inferred. A trigger of bacterial origin is the first aetiological factor to be considered. As proposed by Ehnevid et al. (1993a), bacteria or bacterial products (endotoxins), present in the treated root canal (and in the dentinal tubules), leaking through possibly opened tubules may be held responsible. In case of intact root cementum, leakage through accessory canals is a possible route. However, diffusion of irritants through dentin

and root cementum cannot be ruled out. 's-Gravenmade et al. (1981) showed diffusion of aldehydes from the root canal to the outer surface of the root in extracted teeth. Ghazi et al. (2000) showed a higher concentration of gallium at the outer surface of the root cementum when gallium nitrate was allowed to diffuse from the root canal. These data suggest that even intact cementum may not present an impenetrable barrier between the periodontium and the internal parts of the tooth.

Armitage et al. (1983) observed a change in the cementum of teeth with heavily infected root canals. This change was very much like changes in the cementum of periodontally compromised teeth found in earlier studies, both considering their form and location (Bass 1951, Benson 1963, Armitage & Christie 1973, Armitage 1977, Bigarre & Yardin 1977). Although studies questioned the importance of "diseased" cementum for the results of periodontal therapy (Nyman et al. 1988, Corbet et al. 1993), the role of this feature in the pathogenesis of periodontitis was never denied nor confirmed in subsequent research. It may be hypothesized that bacteria or their (metabolic) products, still present in dentinal tubules after endodontic treatment, play a role in cementum alterations as described above. In this way, they might be attributed to periodontal attachment loss.

Furthermore, Sjögren et al. (1998) suggested in their study the ability of gutta percha to trigger macrophages to activate a bone-resorptive system. More studies have shown the ability of gutta percha to trigger inflammatory reactions (Molyvdas et al. 1989, Pascon et al. 1991, Tavares et al. 1994, Sjögren et al. 1995, Ricucci & Langeland 1998). Gutta-percha cones consist of two major components: gutta percha (14.5–20.4%) and zinc oxide (66.5–84.3%). A minor fraction consists of wax and resin (1.2–3.1%) and in some brands barium sulphate (0–11.4%) is present (Gurgel-Filho et al. 2003). Different brands of sealant cements offer a wider variety of compositing elements. Therefore, apart from the gutta percha itself, root canal fillings contain more substances that might leak or diffuse to the periradicular area and thus trigger the host response.

It is easily conceivable that in periodontitis patients, any of the above-mentioned triggers of the inflammatory process may result in a more pro-

nounced inflammatory response, with loss of marginal bone as the radiographically measurable sequela.

In the present sample of teeth, the radiographs were made after referral for periodontal treatment, but before the actual episode of treatment to be provided by the periodontist. It might, however, be possible, that these teeth had already been scaled and root planed before the X-rays were made, in which cases considerable amounts of root cement may have been removed before the teeth were studied. This could result in an opening of the dentinal tubules and may have provided an easy pathway for any of the above-mentioned mechanisms. The available radiographic data, however, do not allow for an analysis of the amount of cementum present in the area coronal to the periodontal attachment level.

In the present retrospective study design, it is impossible to distinguish between the mechanisms that may have resulted in the difference in marginal bone level as found for endodontically treated teeth. To distinguish between mechanisms of infection or contamination from the root filling per se, a different study design is needed. Longitudinal follow-up of a sample of periodontitis patients with teeth showing apical pathology before root canal treatment, as compared with patients having teeth without an infected pulp that need endodontic treatment, may give information on the effect of infection *versus* chemical irritation. The drawback of such a design is that these patients will also be treated and monitored for their periodontal health, thus decreasing the chances for finding any differences in changes of marginal bone level over time.

Another interesting finding concerns the higher frequencies of inter-radicular radiolucencies found in endodontically treated teeth as compared with their contra-laterals. This corroborates the earlier results of Jansson & Ehnevid (1998), who observed furcation involvement more frequently in endodontically infected lower molars. The presence of patent accessory canals, often found in the furcation area, may be a significant pathway for infectious spread of endodontic pathogens to the periodontium. This finding has the clinical implication that in periodontitis patients, root canal-treated multi-rooted teeth may have a less favourable prognosis, because of more frequent furcation involvement.

In conclusion, in periodontitis patients, teeth with endodontic treatment had more bone loss as compared with untreated contra-laterals, and higher odds for the presence of inter-radicular radiolucency in case of multi-rooted teeth. These findings might have consequences with regard to periodontal prognosis and treatment planning.

### Acknowledgements

We would like to thank Edwin J. W. Zeubring for selecting the patient group and being the second examiner of the radiographs. We would like to acknowledge Marga H. Ree and Ubele van der Velden for assistance during preparation of the manuscript.

### References

- Armitage, G. C. (1977) Alterations in exposed human cementum. *Journal of the Western Society of Periodontology* **25**, 60–68.
- Armitage, G. C. & Christie, T. M. (1973) Structural changes in exposed human cementum. II. Electron microscopic observations. *Journal of Periodontal Research* **8**, 356–365.
- Armitage, G., Ryder, M. & Wilcox, S. (1983) Cemental changes in teeth with heavily infected root canals. *Journal of Endodontics* **9**, 127–130.
- Bass, C. C. (1951) A previously undescribed demonstrable pathologic condition in exposed cementum and the underlying dentine. *Oral Surgery, Oral Medicine and Oral Pathology* **4**, 641–652.
- Benson, L. A. (1963) A study of a pathologic condition in the exposed cementum. *Oral Surgery, Oral Medicine and Oral Pathology* **16**, 1137–1144.
- Bergenholtz, G. & Hasselgren, G. (2003) Endodontics and periodontics. In: Lindhe, J., Karring, Th. & Lang, N. P. (eds). *Clinical Periodontology and Implant Dentistry*, 4th edition, pp. 318–351. Oxford: Blackwell Munksgaard. (chapter in book).
- Bigarre, C. & Yardin, M. (1977) Demonstration of lipids in the pathologic granules in cementum and dentin in periodontal disease. *Journal of Clinical Periodontology* **4**, 210–213.
- Corbet, E. F., Vaughan, A. J. & Kieser, J. B. (1993) The periodontally-involved root surface. *Journal of Clinical Periodontology* **20**, 402–410.
- De Moor, R. J., Hommez, G. M., De Boever, J. G., Delme, K. I. & Martens, G. E. (2000) Periapical health related to the quality of root canal treatment in a Belgian population. *International Endodontic Journal* **33**, 113–120.
- Ehnevid, H., Jansson, L., Lindskog, S. & Blomlöf, L. (1993a) Periodontal healing in teeth with periapical lesions. A clinical retrospective study. *Journal of Clinical Periodontology* **20**, 254–258.
- Ehnevid, H., Jansson, L. E., Lindskog, S. F. & Blomlöf, L. B. (1993b) Periodontal healing in

- relation to radiographic attachment and endodontic infection. *Journal of Periodontology* **64**, 1199–1204.
- Ghazi, A. M., Shuttleworth, S., Angulo, S. J. & Pashley, D. H. (2000) Gallium diffusion in human root dentin: quantitative measurements by pulsed Nd:YAG laser ablation combined with an inductively coupled plasma mass spectrometer. *Journal of Clinical Laser Medicine and Surgery* **18**, 173–183.
- 's-Gravenmade, E. J., Wemes, J. C. & Dankert, J. (1981) Quantitative measurements of the diffusion in vitro of some aldehydes in root canals of human teeth. *Oral Surgery, Oral Medicine and Oral Pathology* **52**, 97–100.
- Gurgel-Filho, E. D., Andrade Feitosa, J. P., Teixeira, F. B., Monteiro de Paula, R. C., Araujo Silva, J. B. & Souza-Filho, F. J. (2003) Chemical and X-ray analyses of five brands of dental gutta-percha cone. *International Endodontic Journal* **36**, 302–307.
- Jansson, L. E. & Ehnevid, H. (1998) The influence of endodontic infection on periodontal status in mandibular molars. *Journal of Periodontology* **69**, 1392–1396.
- Jansson, L., Ehnevid, H., Lindskog, S. & Blomlöf, L. (1993a) Relationship between periapical and periodontal status. A clinical retrospective study. *Journal of Clinical Periodontology* **20**, 117–123.
- Jansson, L. E., Ehnevid, H., Lindskog, S. F. & Blomlöf, L. B. (1993b) Radiographic attachment in periodontitis-prone teeth with endodontic infection. *Journal of Periodontology* **64**, 947–953.
- Jansson, L., Ehnevid, H., Lindskog, S. & Blomlöf, L. (1995) The influence of endodontic infection on progression of marginal bone loss in periodontitis. *Journal of Clinical Periodontology* **22**, 729–734.
- Molyvdas, I., Zervas, P., Lambrianidis, T. & Veis, A. (1989) Periodontal tissue reactions following root canal obturation with an injection-thermoplasticized gutta-percha technique. *Endodontology and Dental Traumatology* **5**, 32–37.
- Miyashita, H., Bergenholtz, G., Gröndahl, K. & Wennström, J. L. (1998) Impact of endodontic conditions on marginal bone loss. *Journal of Periodontology* **69**, 158–164.
- Nyman, S., Westfelt, E., Sarhed, G. & Karring, T. (1988) Role of "diseased" root cementum in healing following treatment of periodontal disease. A clinical study. *Journal of Clinical Periodontology* **15**, 464–468.
- Pascon, E. A., Leonardo, M. R., Safavi, K. & Langeland, K. (1991) Tissue reaction to endodontic materials: methods, criteria, assessment, and observations. *Oral Surgery, Oral Medicine and Oral Pathology* **72**, 222–237. Erratum in: *Oral Surgery, Oral Medicine and Oral Pathology* **73**, 347.
- Ricucci, D. & Langeland, K. (1998) Apical limit of root canal instrumentation and obturation, part 2. A histological study. *International Endodontic Journal* **31**, 394–409.
- Schei, O., Waerhaug, J., Lövdal, A. & Arnö, A. (1959) Alveolar bone loss related to oral hygiene and age. *Journal of Periodontology* **30**, 7–16.
- Simon, J. H., Glick, D. H. & Frank, A. L. (1972) The relationship of endodontic-periodontic lesions. *Journal of Periodontology* **43**, 202–208.
- Sjögren, U., Ohlin, A., Sundqvist, G. & Lerner, U. H. (1998) Gutta-percha-stimulated mouse macrophages release factors that activate the bone resorptive system of mouse calvarial bone. *European Journal of Oral Science* **106**, 872–881.
- Sjögren, U., Sundqvist, G. & Nair, P. N. (1995) Tissue reaction to gutta-percha particles of various sizes when implanted subcutaneously in guinea pigs. *European Journal of Oral Science* **103**, 313–321.
- Tavares, T., Soares, I. J. & Silveira, N. L. (1994) Reaction of rat subcutaneous tissue to implants of gutta-percha for endodontic use. *Endodontology and Dental Traumatology* **10**, 174–178.
- Zehnder, M., Gold, S. I. & Hasselgren, G. (2002) Pathologic interactions in pulpal and periodontal tissues. *Journal of Clinical Periodontology* **29**, 663–667.

Address:  
 Mark F. Timmerman  
 Department of Periodontology  
 Academic Centre for Dentistry Amsterdam  
 ACTA  
 Louwesweg 1  
 1066 EA Amsterdam  
 The Netherlands  
 Tel.: +31 20518 8307  
 E-mail: m.timmerman@acta.nl

### Clinical Relevance

*Scientific rationale for study:* Studies have shown the influence of periapical status on periodontal disease, but no influence of the quality of endodontic treatment in patients without periodontitis. Is there, in periodontitis patients, a difference between the marginal bone level of

teeth with a root-canal filling and their contra-laterals without?

*Principal findings:* Teeth with endodontic treatment show lower levels of marginal bone and higher odds for the presence of inter-radiolar radiolucency.

*Practical implications:* Not only should the presence of possible pulp

necrosis be taken into account, when considering endodontic aspects in periodontal treatment planning, in particular for multi-rooted teeth. The endodontic past, and even apparently satisfactory root canal fillings, could also significantly influence the prognosis.