

Evaluation of root canal debridement by use of a radiopaque medium

Stephen H. Littman, DDS, Baltimore

A radiopaque medium was introduced as a tool in the evaluation of root canal debridement. Three different instrumentation techniques, each used by three operators, were evaluated. The traditional preparation showed the best results. The thoroughness of the operator was determined to be the most important variation, thus emphasizing the significant role of the operator's ability in root canal debridement.

The removal of pulp tissue from the root canal system is achieved primarily through biomechanical preparation, which is the debridement or cleaning and shaping of the canal to accept a filling material. Many investigators¹⁻⁵ have meticulously detailed the anatomy of the root canal system. Their studies, however, have only implied that a relationship exists between anatomic detail and canal debridement. Early histologic studies by Hatton⁶ found that teeth which were considered endodontic failures contained a very high percentage of superficially cleaned root canals with much of the pulp tissue still remaining. Gutiérrez and García,⁷ in evaluating 120 mandibular incisors and canines after instrumentation, found that 78% to

85% of the canals had prolongations or fins. They concluded that a high incidence of the prolongations within the root canal were never touched by instrumentation.

More recently, Coffae and Brilliant,⁸ in comparing serial to nonserial preparations, microscopically found that 23% of the serial preparations and 54% of the nonserial preparations did not show significant removal of tissue at the 1-mm level. Klayman and Brilliant,⁹ in a similar study, compared removal of tissue on extracted mandibular molars prepared with either the Giromatic reamer or K-type files used in a serial preparation technique. Although they found that neither instrument nor technique was totally effective in removing all tissue from the root canal, serial preparation was the more effective. Moreover, the procedures were less effective in the apical than in the coronal portion of the canal.

With regard to the shaping of root canals, a number of studies have demonstrated the changes brought about through canal instrumentation. Davis, Brayton, and Goldman,¹⁰ using injectable silicone, found that the anatomy of the prepared canal was very dissimilar to the instruments used to prepare them, especially in the apical third. Standard instrumentation techniques tended to leave a considerable

portion of the canal wall untouched. Other studies have measured the diameter of canals, and the smoothness and regularity of the canal walls.¹¹⁻¹⁵ The relevance of the shape of the canal to successful endodontics, however, has never been demonstrated, especially because some techniques use gutta-percha in a form that enhances its ability to conform to existing space (that is, heat or chemical alteration).

The purpose of this study was to compare the effectiveness of three different instrumentation techniques used by three different operators. The debridement of the root canal was evaluated by using a radiopaque medium as a staining agent.

Materials and Methods

This study included 90 human first and second permanent premolars, randomly chosen from teeth extracted from all age groups at the University of Maryland, School of Dentistry, Baltimore. All teeth chosen had only one canal and a mature apex. The crowns of the teeth were opened to a clinically acceptable size with a high-speed no. 1552 bur; the canals were broached to remove most of the soft tissue. A size 15 file then was placed into each tooth to the anatomic apex to ensure that the apex was patent. The teeth then were soaked in 5%

sodium hypochlorite for 24 hours, followed by a 30-minute treatment in an ultrasonic cleaner filled with fresh 5% sodium hypochlorite. The teeth were rinsed in running tap water to remove salt accretions. The occlusal third of each crown was luted to the apex of a funnel, and the funnel placed in a filtering crucible and filtration flask assembly (Fig 1). A solution of sodium and meglumine diatrizoates (Hypaque-M, 90%)* was used as a radiopaque medium.

After passing a size 15 file through the apex, the radiopaque medium was drawn through the canal system—from the occlusal surface to the apex—by applying a vacuum¹⁶ of 2-mm mercury. When a few drops of opaque solution had passed through the apical foramen, the tooth and funnel assembly were removed from the vacuum.

The teeth then were radiographed at mesiodistal and buccolingual angles (Fig 2) at 70 kilovolt (peak) and 10 ma for four-fifths second. Focal distance of the film was 20 inches. All films were processed by hand. Teeth that were incompletely stained or showed voids on the radiograph were restained until complete opaqueness of the root canal was seen radiographically. Each tooth, therefore, had its own radiographic control. All teeth then were set aside for three hours, which allowed time for the aqueous portion of the Hypaque-M, 90%, to evaporate. This left a radiopaque, crystalline deposit in the root canal system.

The teeth were divided by random selection into nine groups of ten teeth each. Each of the three second-year endodontic postgraduate students then prepared the ten teeth by the following techniques: size 50 apical preparation using files; size 50 apical preparation using the Giromatic handpiece and Giromatic reamers†; and size 35 apical preparation followed by a 1-mm reduction in working length for each




Fig 1—Top: staining apparatus shows premolar luted to funnel, filtration crucible, and flask. Bottom: radiopaque medium drawn through root canal to apical foramen.

succeeding instrument up to size 60, using files.

Irrigating solutions were intentionally omitted to evaluate only the effect of mechanical cleansing. Each tooth was number-coded by an independent observer, and the nine groups of teeth were mixed together.

After biomechanical preparation, each tooth was radiographed both from mesiodistal and buccolingual angles. The radiographs were evaluated independently by three clinicians with the following criteria used: 2 desig-

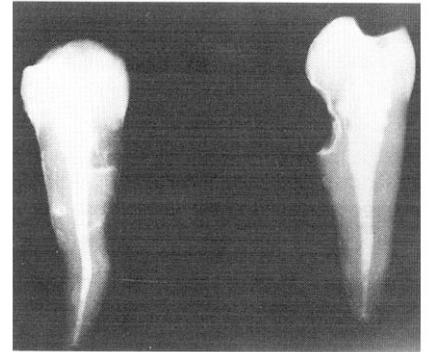

Fig 2—Radiograph of premolar shows outline of root canal before instrumentation. Left, faciolingual view, right, mesiodistal view.

nated stain throughout half of the root, 1 designated minimal amount of stain in distinct areas of the root, and 0 designated no stain in the root canal system.

Two scores were given for each view of each tooth, one for the apical half and one for the coronal half (Fig 3). After the code was broken, the results were categorized into their respective groups. By averaging the three evaluators' scores of the two views of each tooth, a pair of numbers was used to describe each tooth—an apical and a coronal number. Mean values then were determined for each technique and for each operator.

Results

The average (mean) debridement in the apical half of the root (Table 1) was best with the size 50 apex technique using files. Even more apparent, however, was the consistently lowest scores of operator 1 when compared with those of the other two operators. This represented more thorough debridement by operator 1. In the coronal half (Table 1), there was minimal difference in techniques. The Giromatic preparation produced the most consistent results whereas the sizes 35 to 60 taper preparation produced the widest range of results. Once again, operator 1 debrided the canal to a much higher degree than

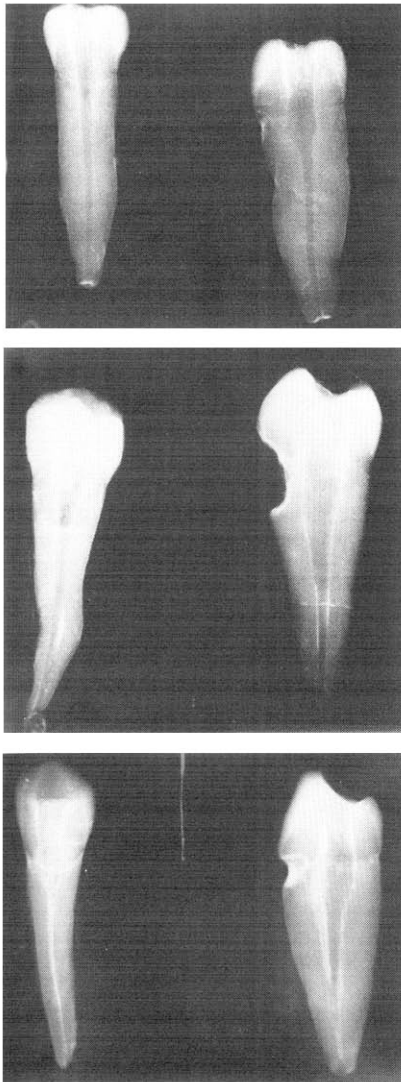


Fig 3—Radiographs show various levels of root canal debridement; evaluation included both apical (left) and coronal (right) sections. Top, radiograph received rating of 0; center, 1; and bottom, 2.

either of the other two operators. By comparing the overall averages of each technique and of each operator (Table 2), the differences between operators were demonstrated to be much greater than the differences between techniques. In both the apical and coronal halves, operator 1 had the best scores whereas operator 3 had the worst scores. Moreover, each operator debrided the apical half of the canal

Table 1 • Average (mean) debridement of apical and coronal halves of root canal.

Operator	Technique					
	Size 50 apex		Sizes 35-60 taper		Giromatic	
	Apical	Coronal	Apical	Coronal	Apical	Coronal
1	0.55	0.68	0.50	0.54	0.88	1.01
2	0.78	1.26	1.37	1.15	1.04	1.10
3	1.05	1.22	1.40	1.72	1.29	1.14

Table 2 • Average (mean) debridement by technique and by operator.

Location	Technique			Operator		
	Size 50 apex	Sizes 35-60 taper	Giromatic	1	2	3
Apical half	0.79	1.09	1.07	0.64	1.06	1.25
Coronal half	1.05	1.13	1.08	0.74	1.17	1.36

to a greater extent than the coronal half.

A two-way analysis of variance was performed to evaluate whether there were statistical differences between the procedures and between the operators. In the apical half, the difference between the size 50 apex technique and the other two techniques was not statistically significant, with an *F* ratio of 3:10. In the coronal half, the difference between techniques also was not statistically significant. With respect to the operators, in both the apical and coronal halves, the differences between operators were statistically significant. In the apical half, the *F* ratio was 10.72; in the coronal half, it was 15.37. In both cases, the *p* value was less than 0.001.

Discussion

This study is a preliminary investigation into the use of a radiopaque medium in endodontic research. Although carried out in vitro, this study deals with a fundamental question in endodontic preparation: When is debridement complete? Is it complete when, as Grossman¹⁷ has indicated, the canal has been enlarged at least three sizes greater than its original diameter"? Or is it when, as Weine¹⁸ has indicated, one finds "clean, white dentin shavings on the flutes of the reamers and files"? Because neither technique is reliable for all teeth, if

in fact for any, the determination of thorough debridement is still a totally subjective evaluation. The use of a radiopaque medium to stain and outline the root canal system before instrumentation is a means of evaluating debridement. A radiopaque medium will provide, initially, information as to the morphology of the root canal system. After thorough debridement, a radiograph will show the amount of residual opaque medium left in the root canal, representing areas of insufficient debridement. Only after further instrumentation has removed all opaque medium is biomechanical preparation complete.

The question as to what is being stained by the radiopaque medium has not as yet been answered. From a radiographic viewpoint, the medium does not penetrate the dentinal tubules and may be considered as a surface stain only. Radiographs of cross sections made at various levels both before and after instrumentation support this view. Attempts at histologic evaluation were unsuccessful because the stain was removed by the decalcification process.

The three techniques used, though not strictly comparable, were selected as representative of different philosophies of preparation that are currently practiced.¹⁸⁻²⁰ Because all operators had specific instructions on how the preparations were to be made, the dif-

ferences between the operators reflected differences of natural talent, developed skills, experience with the techniques, or thoroughness with which the instructions were carried out. Specifically, operator 1 showed superior performance with the two hand-instrumented techniques, both of which he was familiar with, as compared with the Giromatic preparation, which he had never used before. On the other hand, operator 3 was inexperienced with the Giromatic preparation; however, he performed better with the Giromatic preparation than with either of the hand-instrumented techniques, in most cases. Operator 1's superior results may be related to his meticulously wiping instruments clean after each time they were passed into the canal. Because no irrigating solution was used, this extra care may have accounted for the removal of a greater amount of radiopaque medium.

In the preparation of teeth with the Giromatic reamer, it was found by all operators to be difficult to prepare many teeth to the apex with sizes 45 and 50 reamers. Though very time-consuming in some instances, all teeth were eventually prepared to the apex. The use of the Giromatic reamer produced the most consistent results, especially in the coronal half.

It is apparent from this study that these three currently used techniques of instrumentation are inadequate in total root canal debridement. It is possible that successful endodontics may result despite the presence of tissue debris and dentin shavings left in the root canal before it is filled. This study showed that no technique removed all the debris from the root canal system, and it is in agreement with the studies of Mizrahi, Tucker, and Seltzer,²¹ Klayman and Brilliant,⁹ and Coffae and Brilliant.⁸ Performance of the operator appeared to have more significance than preparation technique.

Summary

The root canals of 90 extracted mandibular premolars were mechanically instrumented by three clinicians each using three different techniques. The root canal system was stained and then radiographed before and after instrumentation. The effectiveness of removing the radiopaque medium was found to correspond to the effectiveness of instrumentation in debriding a canal. The results strongly emphasized the significance of the operator's performance in debridement of the root canal system, regardless of the technique used. The study introduced the use of a radiopaque medium as a tool in the evaluation of root canal debridement.

*Winthrop Laboratories, New York.

†Medidenta, Woodside, NY.

The author thanks Drs. Stanley S. Andrews, David S. August, and Roger J. Spott, department of endodontics, School of Dentistry, University of Maryland, Baltimore, for their suggestions and assistance. The author also thanks Drs. Thomas E. Day and George W. Rupprecht, Jr., second-year postgraduate endodontic students, for their assistance in preparing and evaluating the teeth used in the project, as well as Dr. Arthur Bonito, assistant research professor, department of oral health care delivery, University of Maryland, for evaluating the statistical data.

Dr. Littman is currently in private practice in Baltimore. Requests for reprints should be directed to Dr. Stephen H. Littman, 6305 Belair Rd, Baltimore, 21206.

References

1. Pucci, F.M., and Reig, R. *Conductos radicales*, part 1. Montevideo, Uruguay, Barreiro y Ramos, 1944, p 145.
2. Pineda, F., and Kuttler, Y. Mesiodistal and buccolingual roentgenographic investigation of 7,275 root canals. *Oral Surg* 33:101 Jan 1972.
3. Green, D. A stereomicroscopic study of the root apices of 400 maxillary and mandibular anterior teeth. *Oral Surg* 9:1224 Nov 1956.
4. Green, E.N. Microscopic investigation of root canal diameters. *JADA* 57:636 Nov 1958.
5. Müller, W. Histology of root canals. *Bl Zahnk Zurich* 19:136 Oct 1958.
6. Hatton, E.H. Histologic studies of pulpless teeth. *Dent Cosmos* 70:49 Jan 1928.
7. Gutiérrez, J.H., and García, J. Microscopic and macroscopic investigation on results of mechanical preparation of root canals. *Oral Surg* 25:108 Jan 1968.
8. Coffae, K.P., and Brilliant, J.D. The effect of serial preparation versus non-serial preparation on tissue removal in the root canals of extracted mandibular human molars. *J Endod* 1:211 June 1975.
9. Klayman, S.M., and Brilliant, J.D. A comparison of the efficacy of serial preparation versus Giromatic preparation. *J Endod* 1:334 Oct 1975.
10. Davis, S.R.; Brayton, S.M.; and Goldman, M. The morphology of the prepared root canal: a study utilizing injectable silicone. *Oral Surg* 34:642 Oct 1972.
11. Jungmann, C.L.; Uchin, R.A.; and Bucher, J.F. Effect of instrumentation on the shape of the root canal. *J Endod* 1:66 Feb 1975.
12. Weine, F.S.; Kelly, R.F.; and Lio, P.J. The effect of preparation procedures on original canal shape and on apical foramen shape. *J Endod* 1:255 Aug 1975.
13. Schneider, S.W. A comparison of canal preparations in straight and curved root canals. *Oral Surg* 32:271 Aug 1971.
14. Haga, C.S. Microscopic measurements of root canal preparations following instrumentation. *J Br Endod Soc* 2:41 July-Sept 1968.
15. Vessey, R.A. The effect of filing versus reaming on the shape of the prepared root canal. *Oral Surg* 27:543 April 1969.
16. Mueller, A.H. Anatomy of the root canals of the incisors, cuspids, and bicuspid of the permanent teeth. *JADA* 20:1361, 1933.
17. Grossman, L.I. *Endodontic practice*, ed 7. Philadelphia, Lea & Febiger, 1970, p 216.
18. Weine, F.S. *Endodontic therapy*. St. Louis, C. V. Mosby Co., 1972, p 203.
19. Abramson, I.I., and Norris, J.P. *Atlas of endodontic technique*. St. Louis, C. V. Mosby Co., 1966, p 76.
20. Sargenti, A.G. *Endodontics*. Bern, Switzerland, H. Huber, 1973, p 63.
21. Mizrahi, S.J.; Tucker, J.W.; and Seltzer, S. A scanning electron microscopic study of the efficacy of various endodontic instruments. *J Endod* 1:324 Oct 1975.