

ORIGINAL RESEARCH

Second mesiobuccal canal detection in maxillary first molars using microscopy and ultrasonics

Tayfun Alaçam, DDS, PhD; Ali Cemal Tinaz, DDS, PhD; Özgür Genç, DDS; and Guven Kayaoglu, DDS, PhD

Department of Endodontics and Conservative Treatment, Faculty of Dentistry, Gazi University, Ankara, Turkey

Keywords

maxillary first molar, mesiobuccal second canal, operating microscope, ultrasound.

Correspondence

Associate Professor Ali Cemal Tinaz, Department of Endodontics and Conservative Treatment, Gazi University, Faculty of Dentistry, 82.sokak, 06510, Emek, Ankara, Turkey. Email: tinaz@gazi.edu.tr

doi:10.1111/j.1747-4477.2007.00090.x

Abstract

The aim of this study was to investigate whether the use of operating microscope in combination with ultrasonics increased the rate of second mesiobuccal (MB2) canal detection in permanent maxillary first molar teeth. A hundred extracted human maxillary first molars were assessed. After location of the main canals, the MB2 canal was sought in all teeth first without microscopy, then with the aid of the operating microscope and finally with the combined use of the operating microscope and ultrasonics. With these techniques, the MB2 canal was detected in 62%, 67% and 74% of the teeth, respectively. The combination of the operating microscope and ultrasonics detected significantly more MB2 canals than when no microscopy was utilized ($P < 0.05$). Sectioning of the roots disclosed the presence of the MB2 canal in 82% of the teeth. Twenty-nine per cent of the teeth had a separate MB2 canal orifice and separate apical foramina. The results of this study suggested that the combined use of the operating microscope and ultrasonics increased the detection of MB2 canals in maxillary first permanent molars.

Introduction

The maxillary first molar has one of the most complex root and canal anatomy (1). An inability to detect and treat a second mesiobuccal (MB2) canal is a reason for endodontic failure in maxillary first molars. Endodontically retreated teeth were found to contain more undetected MB2 canals than first-time treated teeth, suggesting that failure to treat existing MB2 canals leads to a poorer prognosis (2). *In vitro* studies have shown that a MB2 canal is present in more than 70% of maxillary first permanent molars (3–8). Clinically, the MB2 canal could be detected in less than 40% of maxillary first molars (9–14). The use of the operating microscope facilitates detection and negotiation of more MB2 canal in both *in vitro* and clinical studies (2,8,15–18).

Ultrasonics is particularly advantageous in MB2 canal location due to the cavitation effect (19). Ultrasonics is used by few endodontists for the purpose of MB2 canal search, and use of bur and explorer is preferred by the majority (17). The use of ultrasonic tips may be more conservative.

The aim of this study was to investigate whether the use of an operating microscope in combination with ultrasonics increased detection of MB2 canals in extracted permanent maxillary first molar teeth.

Materials and methods

One hundred randomly selected human maxillary permanent first molar teeth were used in this study. Before use, the teeth were stored in 1% thymol solution for 2 weeks. The teeth were mounted in cast stone and rhomboidal-shaped access cavities were prepared in all teeth by one operator. Clear visualization of the pulpal chamber floor as well as the main root canal orifices was attained. Slow-speed Mueller burs (Brasseler, Savannah, GA, USA) were then used with a brushing motion between the mesiobuccal and the palatal canal orifice to remove the dentinal shelves that overlie the anticipated MB2 canal orifice. This procedure was conducted using alternate irrigation with 2.6% NaOCl and 3% H₂O₂. All teeth were inspected without magnification for the presence of MB2 canals, using an explorer. Teeth in

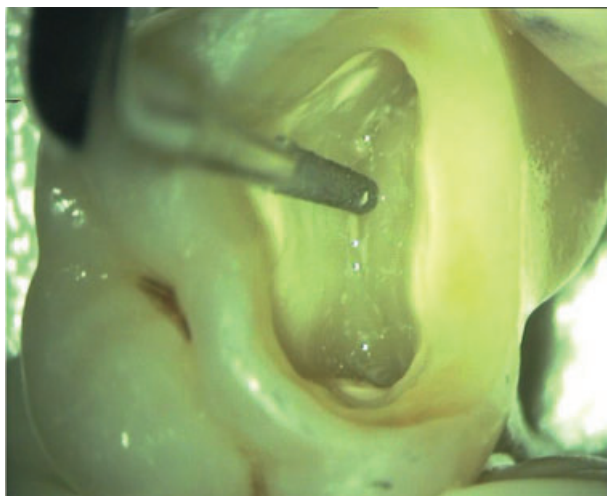


Figure 1 Second mesiobuccal canal orifice search with the ultrasonic tip.

which the MB2 canal orifice could not be located without magnification were examined with an operating microscope (Möller-Wedel, Denta 300, Rosengarten, Wedel, Germany) at $\times 16$ magnification. If the MB2 canal orifice could still not be found, an ultrasonic instrument was used along with the operating microscope. Ultrasonic diamond tip (ET40D tip, Satelec, Merignac, France, with Suprasson handpiece) (Fig. 1) was applied at medium speed and with light force along the mesiobuccal subpulpal groove extending palatally from the main mesiobuccal canal orifice, with continuous water irrigation.

If an MB2 orifice was located, attempts were made to negotiate the canal with size 6, 8 or 10 K-files. The teeth were removed from the cast stone and two digital radiographs were taken from the buccal and lateral aspects to demonstrate the pathway of the MB2 canal with files inserted into the main mesiobuccal canal and the MB2 canal. To eliminate overlapping structures, the distobuccal root was resected before the radiographs were taken. The mesiobuccal root canal system was classified according to a previous study (20).

The mesiobuccal roots in which the MB2 canal could not be located even after the employment of the ultrasonic technique were sectioned horizontally at 4 and 8 mm distance from the apex and observed under operating microscope at $\times 16$ magnification for the presence of the MB2 canal.

Statistical comparisons between the tested techniques were done by analysing the receiver operating characteristic (ROC) curves. ROC curves can be used to compare the diagnostic performance of laboratory or diagnostic tests. In this case, a curve for each MB2 canal detection technique was drawn according to its sensitivity (true

positive performance) and specificity (false positive performance). The area under each curve was calculated and compared pair-wise with the others. The statistical significance was established at 0.05. Statistical analysis was performed using the MedCalc Statistical Software (version 7.6.0.0).

Results

Without microscopy, the MB2 canal was located in 62 teeth (62%). With the use of the operating microscope, the MB2 canal was located in five additional teeth (67%). With the combined use of the ultrasonic tip and the operating microscope, the MB2 canal was located in seven more teeth (74%). Sectioning of the mesiobuccal root disclosed the presence of a MB2 canal in eight more teeth, while 18 teeth had a single canal in the mesiobuccal root. The ROC curves pertaining to the MB2 detection success of each technique is shown in Figure 2. Among the comparisons between no microscopy, microscopy and ultrasonics–microscopy combination, a statistically significant difference was found only between no microscopy group and ultrasonics–microscopy combination ($P < 0.05$). The number and type of canals in the mesiobuccal root are summarized in Table 1.

Discussion

The main finding in this study was that the use of the operating microscope in combination with ultrasonics increased the rate of MB2 canal detection in extracted permanent maxillary first molar teeth. The reason that there was no significant difference between no microscopy and microscopy applications regarding the detection rate of the MB2 canal may be that the teeth were examined under the most convenient conditions at the first stage (no microscopy): the operator was an experienced endodontist and extracted teeth were used for the study. These factors facilitated the detection of a large portion of the MB2 canals initially. Only few more could be detected using microscopy (no significant difference). This is similar to the findings of the Gorduysus study (8) where only one additional MB2 canal orifice was located with the use of the operating microscope (43/45 teeth) following the examination without microscopy (42/45 teeth). The findings of a recent study that was designed similarly to the study presented here, are in contrast, as a significant difference was found between no microscopy and microscopy applications for the detection of the MB2 canal (18). However, this study employed undergraduate students solely. Only a small percentage of the MB2 canals were detected initially. Differences between the findings of these studies can be explained by the qualifi-

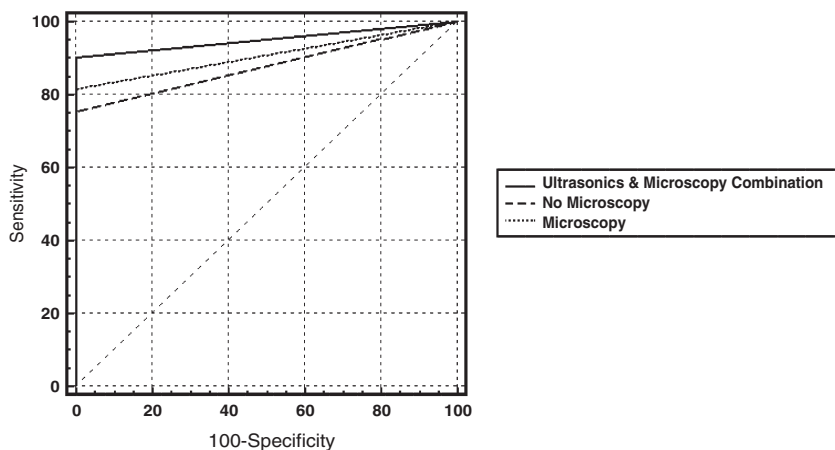


Figure 2 Receiver operating characteristic curves pertaining to the second mesiobuccal detection success of the tested techniques.

Table 1 Overview of the number and type of canals in the mesiobuccal root of 100 maxillary first molars

Single canal	Two canals (<i>n</i> = 82)			
	type II	type III	n-n MB2†	MB2 in sections
18	30	29	15	8

Type II: two distinct canals which merge and exit together through one apical foramen, type III: two distinct canals with two distinct apical foramina. †Non-negotiable or rudimentary MB2.

cation of the operators. In clinical conditions the operating microscope appears to significantly increase the detection rate of a MB2 canal in maxillary molars (16,17). Furthermore, when microscopy and ultrasonics were used as a part of clinical endodontic practice, a rate as high as 93% was reported for MB2 canal location (16), suggesting that the combined use of these instruments could be very effective. The findings of the presented study on the effectiveness of the ultrasonics–microscopy combination are in agreement with those of another study where significantly increased rate of success for the detection of the MB2 canal was reported using this combination in maxillary molars (18).

Overall, 82% of the teeth examined had two canals in the mesiobuccal root, a finding close to that of others (3,5,6,21).

Twenty-nine per cent of the teeth were found to have a type III mesiobuccal canal. This is similar to the previously reported occurrence (4,15,16). Failure to locate and treat these canals, considering their direct communication with the periradicular tissues, may lead to failure.

Conclusions

The results of this study suggested that the combined use of the operating microscope and ultrasonics

increased the detection of MB2 canals in permanent maxillary first molars. Their clinical use may improve treatment prognosis.

Editor's note

An increase in the detection of MB2 canals would most likely occur should ultrasonics alone be used to aid detection.

References

1. Vertucci FJ, Haddix JE, Britto LR. Tooth morphology and access cavity preparation. In: Cohen S, Hargreaves KM, eds. 9th ed. Pathways of the pulp. St. Louis: Mosby Elsevier; 2006. p. 203.
2. Wolcott J, Ishley D, Kennedy W, Johnson S, Minnich S, Meyers J. A 5 yr clinical investigation of second mesiobuccal canals in endodontically treated and retreated maxillary molars. *J Endod* 2005; 31: 262–4.
3. Gilles J, Reader A. An SEM investigation of the mesiolingual canal in human maxillary first and second molars. *Oral Surg Oral Med Oral Pathol* 1990; 70: 638–43.
4. Kulild JC, Peters DD. Incidence and configuration of canal systems in the mesiobuccal root of maxillary first and second molars. *J Endod* 1990; 16: 311–7.
5. Ibarrola JL, Knowles KI, Ludlow MO, McKinley IB. Factors affecting the negotiability of second mesiobuccal canals in maxillary molars. *J Endod* 1997; 23: 236–8.
6. Imura N, Hata GI, Toda T, Otani SM, Fagundes MIRC. Two canals in mesiobuccal roots of maxillary molars. *Int Endod J* 1998; 31: 410–4.
7. Weine FS, Hayami S, Hata G, Toda T. Canal configuration of the mesiobuccal root of the maxillary first molar of a Japanese sub-population. *Int Endod J* 1999; 32: 79–87.

8. Gorduysus MO, Gorduysus M, Friedman S. Operating microscope improves negotiation of second mesiobuccal canals in maxillary molars. *J Endod* 2001; 27: 683–6.
9. Seidberg BH, Altman M, Guttuso J, Suson M. Frequency of two mesiobuccal root canals in maxillary permanent first molars. *J Am Dent Assoc* 1973; 87: 852–6.
10. Green D. Double canals in single roots. *Oral Surg Oral Med Oral Pathol* 1973; 35: 689–96.
11. Pomeranz HH, Fishelberg G. The secondary mesiobuccal canal of maxillary molars. *J Am Dent Assoc* 1974; 88: 119–24.
12. Hartwell G, Bellizzi R. Clinical investigation of in vivo endodontically treated mandibular and maxillary molars. *J Endod* 1982; 8: 555–7.
13. Weller RN, Hartwell GR. The impact of improved access and searching techniques on detection of the mesiolingual canal in maxillary molars. *J Endod* 1989; 15: 82–3.
14. Sempira HN, Hartwell GR. Frequency of second mesiobuccal canals in maxillary molars as determined by use of an operating microscope: a clinical study. *J Endod* 2000; 26: 673–4.
15. Fogel HM, Peikoff MD, Christie WH. Canal configuration in the mesiobuccal root of maxillary first molar: a clinical study. *J Endod* 1994; 20: 135–7.
16. Stropko JJ. Canal morphology of maxillary molars: clinical observations of canal configurations. *J Endod* 1999; 25: 446–50.
17. Buhrey LJ, Barrows MJ, BeGole EA, Wenckus CS. Effect of magnification on locating the MB2 canal in maxillary molars. *J Endod* 2002; 28: 324–7.
18. Yoshioka T, Kikuchi I, Fukumoto Y, Kobayashi C, Suda H. Detection of the second mesiobuccal canal in mesiobuccal roots of maxillary molar teeth ex vivo. *Int Endod J* 2005; 38: 124–8.
19. Iqbal MK. Nonsurgical ultrasonic endodontic instruments. *Dent Clin North Am* 2004; 48: 19–34.
20. Weine FS, Healey HJ, Gerstein H, Evanson L. Canal configuration in the mesiobuccal root of the maxillary first molar and its endodontic significance. *Oral Surg Oral Med Oral Pathol* 1969; 28: 419–25.
21. Neaverth EJ, Kotler LM, Kaltenbach RF. Clinical investigation (in vivo) of endodontically treated maxillary first molars. *J Endod* 1987; 13: 506–12.