

REVIEW

New dimensions in endodontic imaging: Part 2. Cone beam computed tomography

S. Patel

Endodontic Postgraduate Unit, King's College London Dental Institute, London, UK, and 45 Wimpole Street, London, UK

Abstract

Patel S. New dimensions in endodontic imaging: Part 2. Cone beam computed tomography. *International Endodontic Journal*, 42, 463–475, 2009.

Cone beam computed tomography (CBCT) has been specifically designed to produce undistorted three-dimensional information of the maxillofacial skeleton, including the teeth and their surrounding tissues with a significantly lower effective radiation dose compared with conventional computed tomography (CT). Periapical disease may be detected sooner using CBCT compared

with periapical views and the true size, extent, nature and position of periapical and resorptive lesions can be assessed. Root fractures, root canal anatomy and the nature of the alveolar bone topography around teeth may be assessed. The aim of this paper is to review current literature on the applications and limitations of CBCT in the management of endodontic problems.

Keywords: cone beam computed tomography, endodontic diagnosis, management of endodontic problems, radiography.

Received 9 July 2008; accepted 1 December 2008

Introduction

The management of endodontic problems is reliant on radiographs to assess the anatomy of the tooth and its surrounding anatomy (Patel *et al.* 2007). Until recently, most of this core information would be obtained from conventional radiographs. However, such images have inherent limitations. The lack of three-dimensional information and masking of areas of interest by overlying anatomy (anatomic noise) are of particular relevance in endodontics.

This paper will review cone beam computed tomography (CBCT) technology and examine how this can be applied to management of endodontic problems.

Cone beam computed tomography

Cone beam computed tomography or digital volume tomography (DVT) utilizes an extraoral imaging scanner

(Fig. 1), which was developed in the late 1990's to produce three-dimensional scans of the maxillo-facial skeleton at a considerably lower radiation dose than conventional computed tomography (CT) (Mozzo *et al.* 1998, Arai *et al.* 2001). With CBCT, a three-dimensional volume of data is acquired in the course of a single sweep of the scanner, using a simple, direct relationship between sensor and source, which rotate synchronously through 180°–360° around the patient's head. The X-ray beam is cone-shaped (hence the name of the technique) and captures a cylindrical or spherical volume of data, described as the field of view (Fig. 2). The size of the field of view (FOV) is variable, large volume CBCT scanners (for example, i-CAT; Imaging Sciences International, Hatfield, PA, USA and NewTom 3G, QR, Verona, Italy) being capable of capturing the entire maxillofacial skeleton. Some CBCT scanners also allow the height of the cylindrical field of view to be adjusted to capture only the maxilla or mandible (for example, i-CAT). This has the advantage of reducing the patient radiation dose. Limited volume CBCT scanners (for example, the 3D Accuitomo, J Morita Corporation, Osaka, Japan) can capture a 40 mm high by 40-mm

Correspondence: Shanon Patel, Specialist Endodontist 45 Wimpole Street, London, W1G 8SB, UK (e-mail: shanonpatel@hotmail.com).

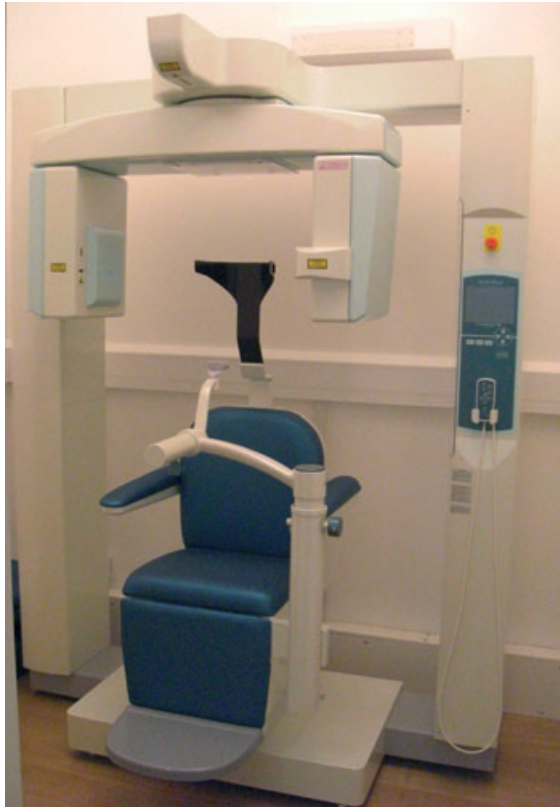

Figure 1 A typical cone beam computed tomography scanner (3D Accuitomo 80, J Morita, Kyoto, Japan), the overall footprint in similar to that of a panoramic machine making it ideal for dental practice.

diameter volume of data, which is similar in overall height and width to a periapical radiograph.

Cone beam computed tomography scan times are typically 10 to 40 s long, depending on the scanner used and the exposure parameters selected. The X-ray beam is pulsed, therefore the actual exposure time is a fraction of this (2–5 s), resulting in up to 580 individual ‘mini-exposures’ or ‘projection images’ during the course of the scan. This contrasts with the continuous exposure of CT and conventional tomography, and affords the major advantage over CT scanners of substantially reduced radiation exposure. Further reduction comes from fast scanning times and the use of advanced image receptor sensors.

Sophisticated software processes the collected data into a format that closely resembles that produced by medical CT scanners (Figs 3 and 4). Each mini-exposure or projection image generates a pixel matrix consisting of 262 144 (512×512) pixels. The result-

ing dataset from CBCT consists of up to 580 individual matrices, which are then reconstructed using powerful personal computers into three-dimensional data sets, consisting of over 100 million voxels (512^3). Reconstruction is achieved in minutes. To increase resolution, the number of pixels per matrix (projection image) may be increased from 512^2 to 1024^2 . The resulting reconstructed three-dimensional volume of data will then consist of 1024^3 voxels, each voxel being half its original size. However, this improved resolution comes at the expense of a two to threefold increase in radiation exposure (Scarfe & Farman 2008).

Tomographic slices, as thin as one voxel thick (80–400 μm), may be displayed in a number of different ways. One option is for the images to be displayed in the three orthogonal planes axial, sagittal and coronal simultaneously, allowing the clinician to gain a truly three-dimensional view area of interest (Fig. 5). Selecting and moving the cursor on one image simultaneously alters the other reconstructed slices, thus allowing the area of interest to be dynamically traversed in ‘real time’. For the first time, clinicians are not constrained by these predetermined views; multi-planar reconstructions are possible, which allow virtually any view to be selected. Surface rendering using software programs is also possible to produce truly three-dimensional images. As described in part 1 of this review paper, the image quality of CBCT scans is superior to helical CT for assessing the cancellous bone, periodontal ligament, lamina dura, enamel, dentine and pulp.

Cone beam computed tomography is set to revolutionize diagnosis and management of endodontic problems. As shown in part 1 of this review paper, the clinician can easily use simple software to assess the areas of interest in any plane. Cone beam CT scanners use simpler, less complicated and therefore less expensive hardware (X-ray source and detector) than CT scanners and use powerful, but low cost computers (Baba *et al.* 2004, Cotton *et al.* 2007), which means that the cost of a CBCT scanner is significantly less than a CT scanner. This has resulted in an increase in its uptake in dental practices (Arnheiter *et al.* 2006, Scarfe *et al.* 2006).

Effective dose

One of the major advantages of CBCT over CT is the significantly lower effective radiation dose to which patients are exposed (Table 1). The effective dose of CBCT scanners vary, but can be almost as low as a panoramic

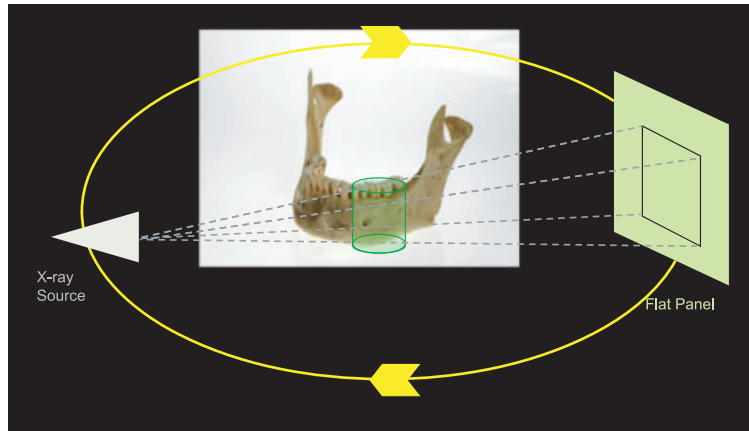


Figure 2 A cone-shaped X-ray beam and the detector rotate once around the patient and captures a cylindrical volume of data (field of view).

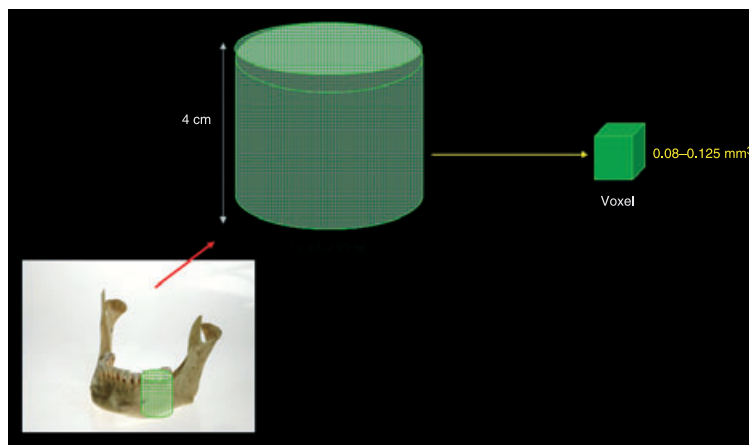


Figure 3 The collected data within the field of view is collated as voxels, therefore a typical field of view consists of millions of voxels. Software is used to reconstruct images for this dataset.

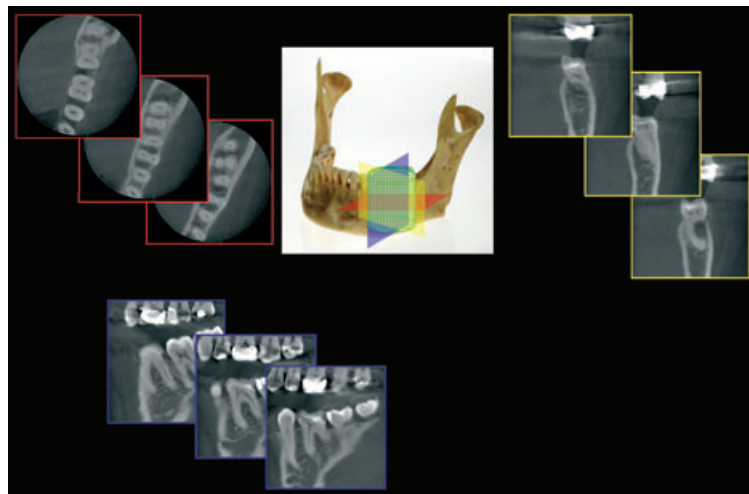


Figure 4 Typically cross-sectional images in three orthogonal views are generated from the cone beam computed tomography scan. The clinician selects the position and thickness of the slice selected from within cylindrical or spherical volume of data. The three views can be assessed simultaneously, traversing through one plane simultaneously alters the other two planes.

dental X-ray and considerably less than a medical CT scan (Ngan *et al.* 2003, Mah *et al.* 2003, Schulze *et al.* 2004, Ludlow *et al.* 2006, Lofthag-Hansen *et al.* 2008).

As would be expected, the limited volume scanners, which are specifically designed to capture information from a small region of the maxilla or mandible deliver a

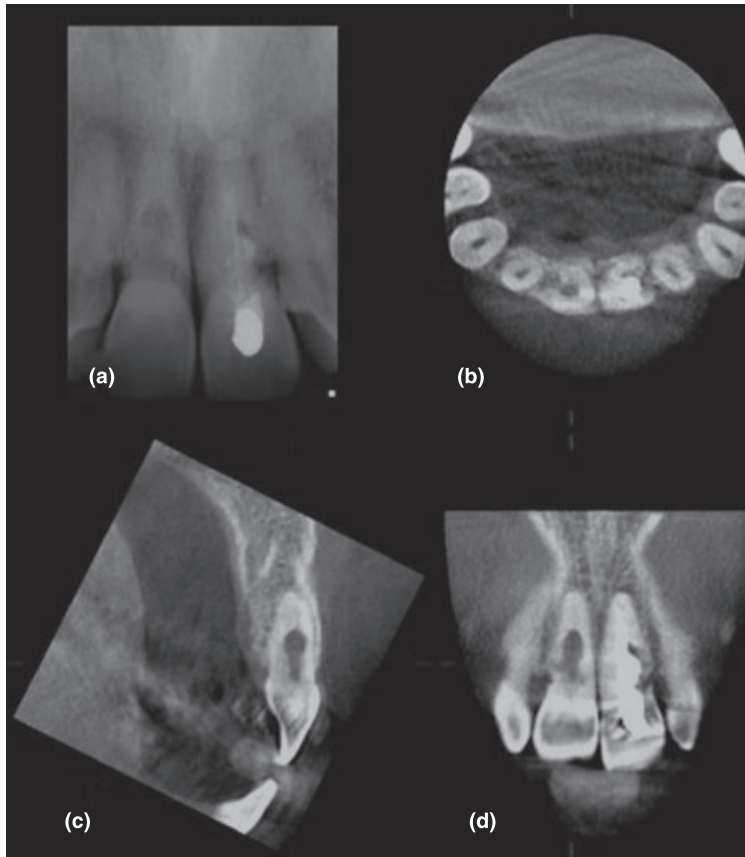


Figure 5 (a) A radiograph and (b–d) typical images produced by a limited cone beam computed tomography scanner (3D Accuitomo 80; J Morita, Kyoto, Japan), (b) axial, (c) sagittal and (d) coronal views of a patient with internal resorption of the maxillary right incisor and external cervical resorption of the maxillary left incisor teeth. The software reconstructs three-dimensional images with minutes of the scan being taken. The images can be re-sliced at any angle, producing a new set of reconstructed orthogonal images.

lower effective dose as less of the maxillo-facial skeleton is being exposed to radiation. The limited volume CBCT scanners is therefore best suited for endodontic imaging of only one tooth or two neighbouring teeth. Indeed, the effective dose of one CBCT scanner (3D Accuimotom, J Morita, Kyoto, Japan) has been reported to be in the same order of magnitude as two to three standard periapical radiographic exposures (Arai *et al.* 2001). The effective dose of another limited CBCT, the ortho-CT, was calculated to be 7.4, 6.3 and 11.7 μSv for views of the maxillary incisor, maxillary molar and mandibular molars respectively (Iwai *et al.* 2001). This again is comparable with conventional periapical radiographs.

Accuracy of reproduction

Computer tomography and CBCT data are composed of a huge volume of data consisting of millions of three-dimensional pixels called voxels. However, this is where the similarities end; CT voxels are anisotropic, the height of the voxel depends on the CT beam (slice) thickness, which limits the accuracy of reconstructed

images in certain planes (for example, sagittal plane). With CBCT data, the voxels are isotropic, i.e. they are equal in length, height and depth, which allows geometrically accurate measurements from CBCT data in any plane (Scarfe *et al.* 2006, Cotton *et al.* 2007).

Several studies have confirmed the three-dimensional geometric accuracy of CBCT (Kobayashi *et al.* 2004, Murmulla *et al.* 2005, Ludlow *et al.* 2007, Mischkowski *et al.* 2007, Stratemann *et al.* 2008). Lascala *et al.* (2004) took a series of 13 measurements from eight dry skulls before they were scanned and measured using CBCT software. CBCT was found to be extremely accurate. Ludlow *et al.* (2007) concluded that CBCT gave accurate two- and three-dimensional measurements regardless of skull orientation. They also concluded that CBCT was reliable for taking linear measurements of the maxillo-facial skeleton. Obenauer *et al.* (2007) has confirmed accurate volumetric analysis with CBCT, a feature, which could be useful in the objective monitoring of periapical lesion size.

Pinsky *et al.* (2006a,b) created simulated osseous defects of varying diameters and depths in an acrylic

Table 1 A comparison of the effective dosages and background equivalent of different sources of dental radiation

Radiographic source	Effective dose (μSv)	Dose as % annual background radiation
Cone beam CT		
3D Accuitomo (1½ inch) ^a	7.3	0.2
i-CAT ^b (12 inch FOV)	134.8	5.4
i-CAT ^b (9 inch FOV)	68.7	1.9
Conventional CT		
Conventional CT ^c	1400 (maxilla) 1320 (mandible)	38.9 36.7
Conventional radiography		
Periapical ^c	5	0.14
Panoramic ^d	6.3	0.2
Cosmic radiation on board an aircraft flying a round trip between Paris-Tokyo ^e	150	4.2

^aArai *et al.* (2001).^bLudlow *et al.* 2006.^cNgan *et al.* (2003).^dLudlow *et al.* (2003).^eBottollier-Depois *et al.* (2003)

CT, computer tomography.

block and a human mandible. These authors found that accurate linear and volumetric measurements of the simulated defects could be acquired using CBCT software to automatically measure the volume of the defect.

Limitations of CBCT

At present the images produced with CBCT technology do not have the resolution of conventional radiographs. The spatial resolution of conventional direct-action packet film and digital sensors is in the order of 15–20 line pairs mm^{-1} (Farman & Farman 2005). CBCT images only have a spatial resolution of 2 line pairs mm^{-1} (Yamamoto *et al.* 2003). However, as CBCT technology improves at a rapid rate, so may the resolution of the reconstructed scans.

One significant problem, which can affect the image quality and diagnostic accuracy of CBCT images is the scatter and beam hardening (Fig. 6) caused by high density neighbouring structures, such as enamel, metal posts and restorations (Mora *et al.* 2007, Soğur *et al.* 2007). If this scattering and beam hardening is associated close to or with the tooth being assessed,

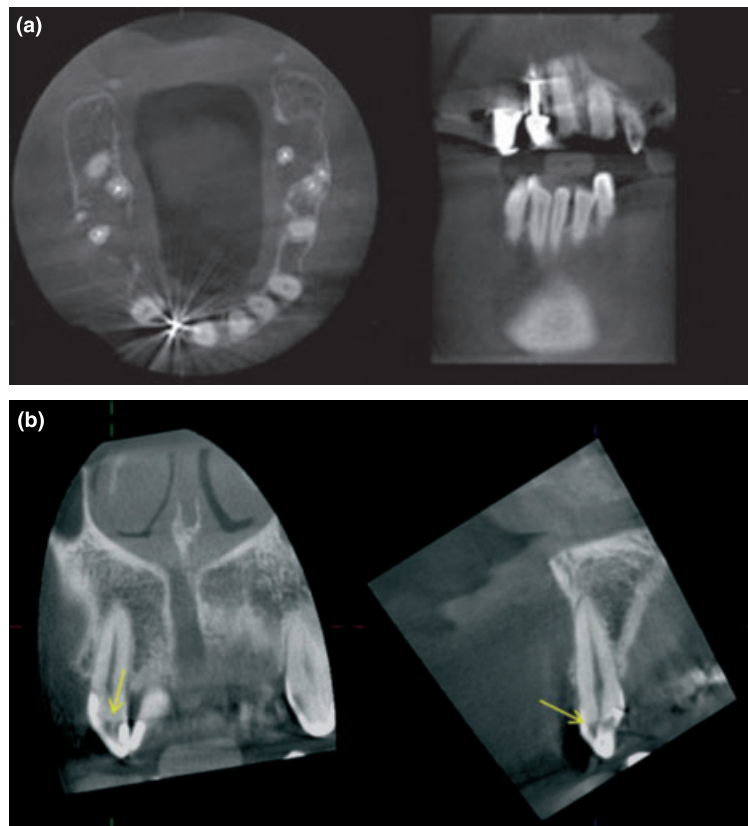


Figure 6 (a) Scatter and beam hardening around metallic restorations (maxillary right second incisor) may result in a reduction in the quality of reconstructed cone beam computed tomography images (only axial and sagittal scans shown). (b) These reconstructed coronal and sagittal images of another case appear to show radiolucencies in the maxillary right second incisor, which may be mistaken for caries (yellow arrows) – this is actually scatter caused by overlying enamel and direct plastic restorations in the tooth.

the resulting CBCT images may be of minimal diagnostic value (Lofthag-Hansen *et al.* 2007, Estrela *et al.* 2008). Finally, scan times are lengthy at 15–20 s and require the patient to stay absolutely still.

The use of CBCT in the management of endodontic problems

Cone beam computed tomography overcomes several limitations of conventional radiography. Slices can be selected to avoid adjacent anatomical noise. For example, the roots of maxillary posterior teeth and their periapical tissues can be visualized separately and in all three orthogonal planes without superimposition of the overlying zygomatic buttress, alveolar bone and adjacent roots. The spatial relationship of the roots of multi-rooted teeth can be visualized in three-dimensions (Soğur *et al.* 2007) and the true size and three-dimensional nature of periapical lesions can also be assessed (Cotton *et al.* 2007, Patel *et al.* 2007).

Detection of apical periodontitis

Cone beam computed tomography enables radiolucent endodontic lesions to be detected before they would be apparent on conventional radiographs (Fig. 7). Lofthag-Hansen *et al.* (2007) compared the periapical status of 46 posterior mandibular and maxillary teeth using CBCT scans and two angled periapical radiographs. Thirty-two teeth were diagnosed with periapical lesions using conventional radiographs and a further 10 (24%) with CBCT. When the periapical

status of the individual roots of these teeth was assessed, CBCT allowed 38% more periapical lesions to be detected than with conventional radiographs. This was especially apparent in the mandibular and maxillary second molar region and was probably because of a combination of selecting relevant CBCT data without adjacent anatomical noise and the geometric accuracy of the CBCT scanner. Similar findings have been reported recently by Low *et al.* (2008). Estrela *et al.* (2008) compared the diagnostic accuracy of panoramic and periapical radiographs with CBCT for the detection of apical periodontitis. Their results confirmed the increased sensitivity of CBCT for detecting apical periodontitis compared with periapical and panoramic radiography. The sensitivity of periapical and panoramic radiography was 0.55 and 0.28 respectively. These clinical studies appear to presume that the radiological findings from CBCT represent the true status of the periapical tissues, i.e. that CBCT can be used as a 'gold standard' with a sensitivity and specificity of 1.0 to detect the presence or absence of periapical disease. The results of these studies have been validated by Stavropoulos & Wenzel (2007). They compared CBCT, digital periapical sensors and conventional periapical films to detect artificially made periapical lesions of varying sizes in pig mandibles. CBCT was found to be twice as sensitive as digital and conventional radiographic films in detecting periapical lesions. Recently, Patel *et al.* (2008) found CBCT to have a 100% sensitivity (1.0) and specificity (1.0) in the detection of artificially created periapical lesions in dry human mandibles.

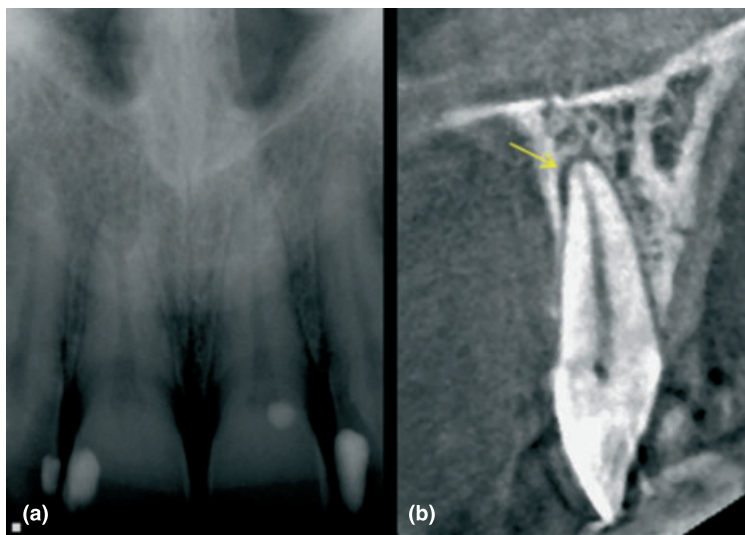


Figure 7 (a) Periapical radiograph of a patient who has been complaining of an intermittent dull ache. Clinical and special investigations are unremarkable. A periapical radiograph of the maxillary central incisor teeth reveal a normal periapical appearance. (b) Cone beam computed tomography scans reveal a periapical radiolucency (yellow arrow) associated with the UL1, this tooth was root treated after and the patient symptoms resolved.

The radiographic outcome of root canal treatment is more successful when teeth are treated before obvious radiographic signs of periapical disease are detected (Friedman 2002). Thus, earlier identification of periradicular radiolucent changes with CBCT may result in earlier diagnosis and more effective management of endodontic disease. In situations where patients have poorly localized symptoms associated with an untreated or previously root treated tooth and clinical and periapical radiographic examination show no evidence of disease, CBCT may reveal the presence of previously undiagnosed pathosis (Nakata *et al.* 2006, Cotton *et al.* 2007, Patel *et al.* 2007).

Simon *et al.* (2006) compared the ability of CBCT gray scale value measurements with histological examination for diagnosing large periapical lesions in 17 teeth. They suggested that with CBCT, they were able to differentiate 'solid from cystic or cavity type lesions', which they claimed would improve decision making when it came to deciding whether or not to carry out surgery. However, all the lesions were not completely intact and no attempt was made to carry out serial sectioning of the biopsy material, which meant that it was not possible to accurately confirm the type of lesion present.

Perhaps the most exciting area in which CBCT may be applied to endodontics is in determining the outcome of treatment. CBCT scans should result in a more objective and accurate determination of the prognosis of endodontic treatment. CBCT images are geometrically accurate (Murmulla *et al.* 2005) and the problems of anatomical noise seen with periapical radiographs can be eliminated. Serial sets of linear and volumetric measurements obtained with CBCT technology could therefore be used to provide a more objective and accurate representation of osseous changes (healing) over time (Pinsky *et al.* 2006a,b, Patel *et al.* 2007).

Future research may show that periapical tissues, which appear to have 'healed' on conventional radiographs may still have signs of periapical disease (for example, widened periodontal ligament space, periapical radiolucency) when imaged using CBCT. This in turn may have implications for decision making and selection criteria when considering (re-) placing coronal restorations on teeth, which have previously been endodontically treated and appear to have successfully healed radiographically (Faculty of General Dental Practitioners (UK) 2004). It appears that conventional radiography results in an under-estimation of the incidence of apical periodontitis (Estrela *et al.* 2008).

Therefore, clinical studies with a primary outcome measure of detecting the presence or absence of apical periodontitis and epidemiological studies assessing the prevalence of apical periodontitis in different populations may have to be re-evaluated.

Pre-surgical assessment

Cone beam computed tomography has been recommended in the for the planning of endodontic surgery (Rigolone *et al.* 2003, Tsurumachi & Honda 2007). Three-dimensional imaging allows the anatomical relationship of the root apices to important neighbouring anatomical structures, such as the inferior dental canal, mental foramen and maxillary sinus, to be clearly identified in any plane the clinician wishes to view (Fig. 8) (Patel *et al.* 2007). Rigolone *et al.* (2003) concluded that CBCT may play an important role in planning for periapical microsurgery on the palatal roots of maxillary first molars. The distance between the cortical plate and the palatal root apex could be measured, and the presence or absence of the maxillary sinus between the roots could be assessed.

By selecting relevant views and slices of data, the thickness of the cortical plate, the cancellous bone pattern, fenestrations, as well as the inclination of the roots of teeth planned for surgery can be accurately determined preoperatively (Nakata *et al.* 2006). Root morphology and bony topography can be visualized in three-dimensions, as can the number of root canals and whether they converge or diverge from each other. Unidentified (and untreated) root canals may be identified using axial slices, which may not be readily identifiable with periapical radiographs (Low *et al.* 2008) The true size, location and extent of the periapical lesion can also be appreciated, whilst the actual root to which the lesion is associated may be confirmed. This information may have a bearing on non-surgical and surgical management (Fig. 8).

Recently, Low *et al.* (2008) compared the radiographic findings of periapical radiographs with CBCT in root treated maxillary posterior teeth, which were being assessed for periapical surgery. In this study, 34% of periapical lesions detected by CBCT were not detected with periapical radiographs. The likelihood of detecting periapical lesions with periapical radiographs was reduced when the root apices were in close proximity to the floor of the maxillary sinus and when there was <1 mm of bone between the periapical lesion and the sinus floor. Therefore, periapical radiographs were less

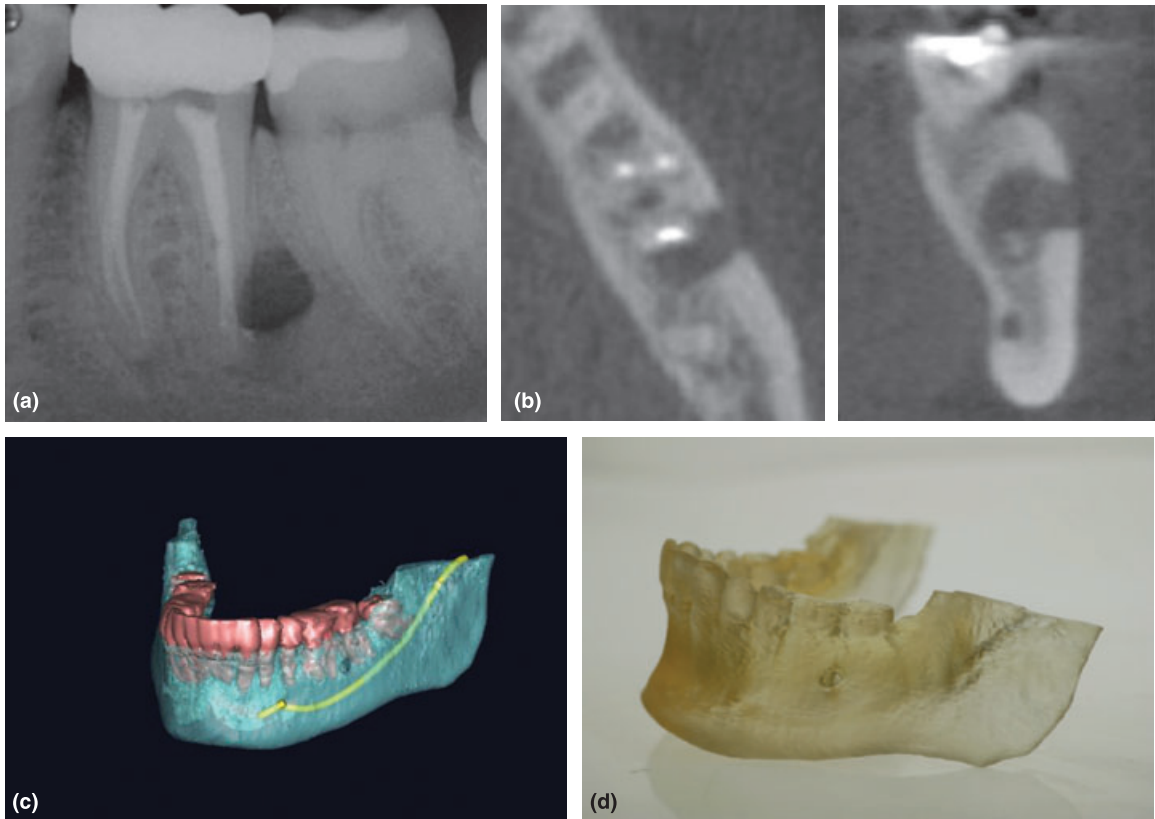


Figure 8 (a) A periapical radiograph of the lower left first molar with a failing root canal treatment and a large periapical radiolucency, periapical microsurgery is planned. (b) A cone beam computed tomography scan is taken, from this data orthogonal images can be reconstructed, (c) volume rendering allows true three-dimensional assessment of the roots, periapical tissues and adjacent inferior dental nerve to be assessed, (d) finally a rapid prototyping anatomical model has been manufactured, which allows the operator to tangibly assess the area to be treated.

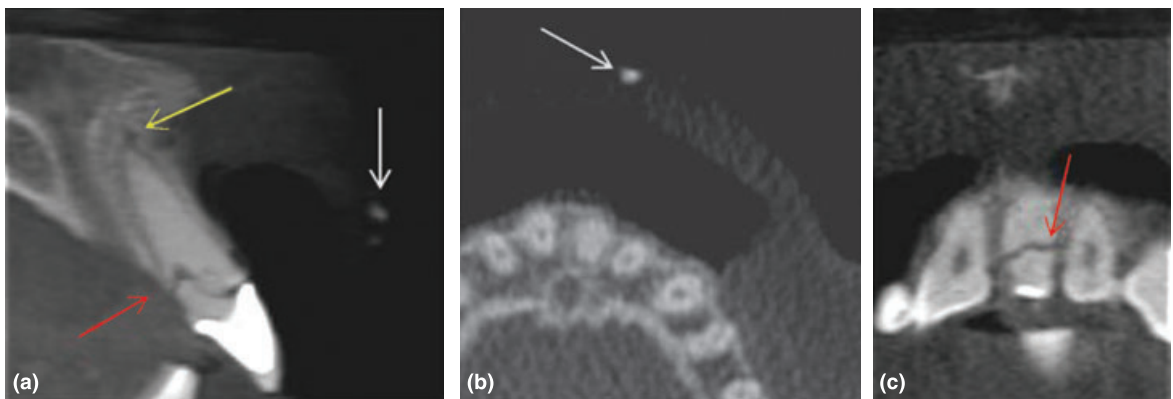


Figure 9 A single cone beam computed tomography scan used in the management of a root fracture and luxation injury. The (a) sagittal and (b) axial views reveal the presence and exact location of the fractured portion of the crown fragment (white arrow) in the upper lip. The scan also reveals an oblique fracture of tooth 21 (red arrow) and widened labial apical-third periodontal space as a result of a lateral luxation injury (yellow arrow).

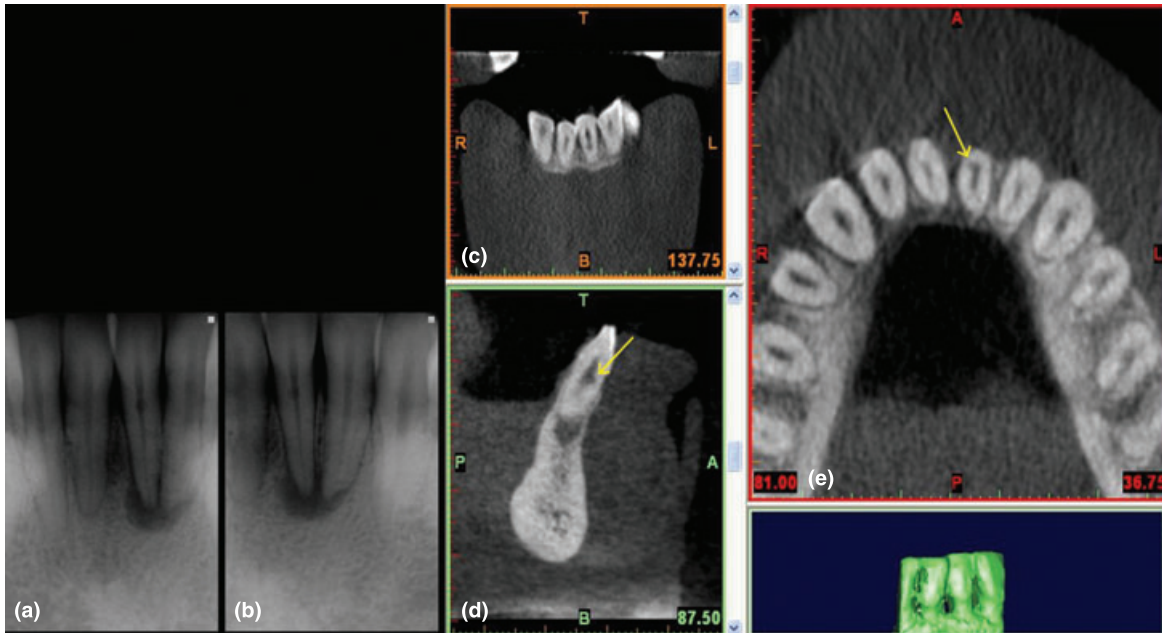


Figure 10 (a–b) Periapical radiographs taken at different views (parallax technique) of the lower left central incisor tooth, note the outline of the root canal is visible through the radiolucent lesion, also the lesion moves in the opposite direction to the X-ray tube in the second radiograph. These signs indicate a diagnosis of external cervical resorption for the radiolucent lesion in the coronal third of the root canal. (c) cone beam computed tomography scans reveal that lesion is actually internal resorption, because of its location on the periphery of the root canal (yellow arrow) it can be easily be mistaken for external cervical resorption with conventional radiographs.

sensitive for detecting periapical lesions associated with maxillary molar teeth.

Cone beam computed tomography data can also be used to produce physical models, a process commonly known as rapid prototyping. True scale models (rapid prototype anatomical models) can be produced of the area of interest using Stereolithography (Fig. 8). The ability to produce three-dimensional rendered images and an exact model using stereolithography of the area of interest from the CBCT data means that the operator can tangibly familiarize themselves with the potential surgical site and confidently plan their surgical approach (Scarfe *et al* 2006).

Assessment of dental trauma

Cone beam computed tomography has also been shown to be useful in diagnosis and management of dento-alveolar trauma (Cohenca *et al.* 2007a, Cotton *et al.* 2007 Patel *et al.* 2007, Tsukiboshi 2008). The exact nature and severity of alveolar and luxation injuries can be assessed from just one scan from which multiplanar views can be selected and assessed with

no geometric distortion or anatomical noise (Fig. 9). It has been reported that CBCT can be used to detect horizontal root fractures (Terakado *et al.* 2000). The same fracture may have needed multiple periapical radiographs taken at several different angles to be detected and even then may not have been visualized. As CBCT is an extra-oral technique it is also far more comfortable for the patient who has recently sustained dental trauma when compared to several intra-oral radiographs taken using a beam aiming device. Cohenca *et al.* (2007a) used CBCT technology to aid their management of three patients who had sustained dental trauma. In addition to detecting the true nature of the injuries sustained by the tooth, the CBCT scans were able to detect cortical bone fractures, which were not diagnosed from the clinical or conventional radiographic examination.

Assessment of root canal anatomy

Because of the two-dimensional nature of radiographs they do not consistently reveal the actual number of canals present in teeth. Matherne *et al.* (2008)

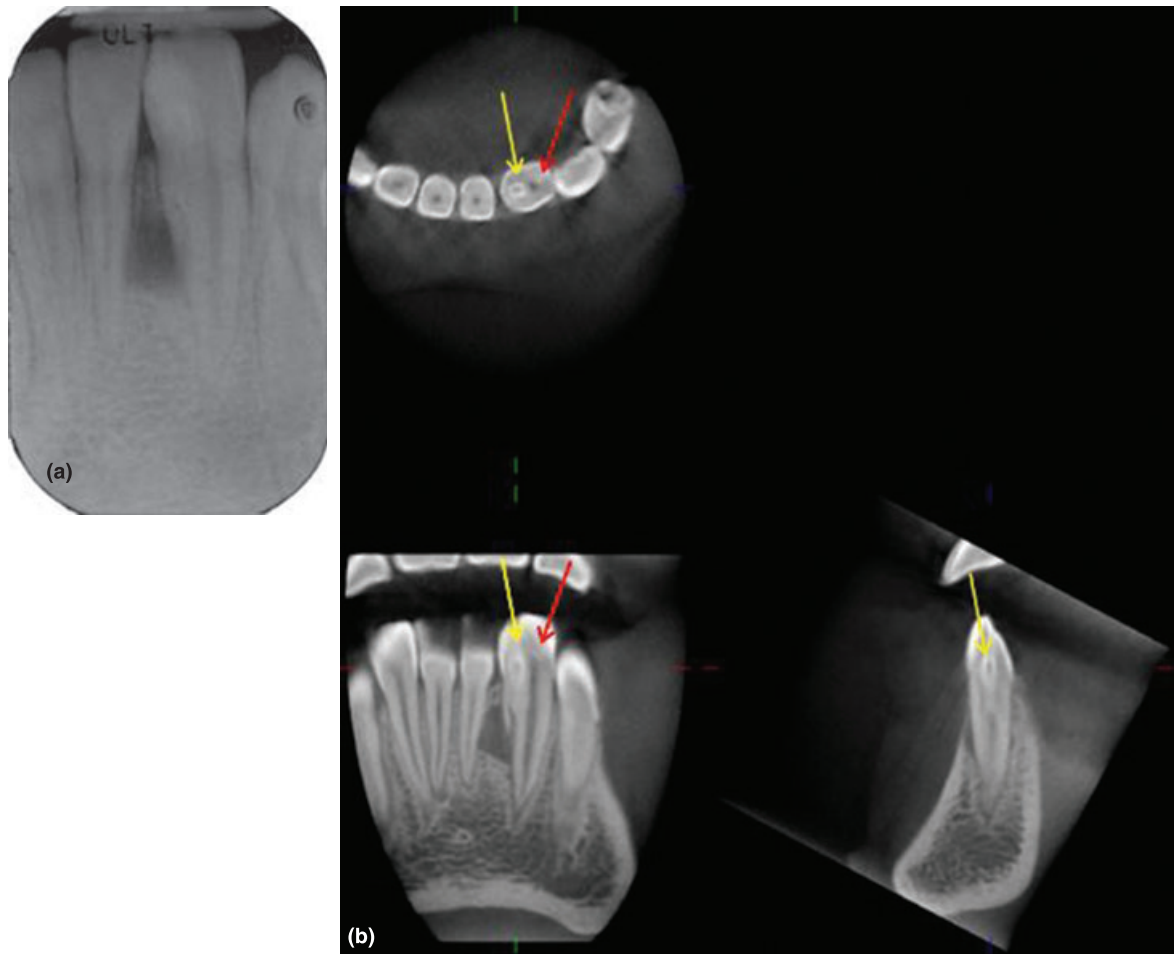


Figure 11 (a) An invaginated lower left second incisor tooth with an associated periapical radiolucency. (b) Only with cone beam computed tomography scans can the relationship of the invagination (yellow arrow) and the root canal (red arrow) be assessed, from this data it is also possible to confirm that the periapical radiolucency is associated with the invagination only.

conducted an *ex vivo* investigation to compare charged-couple device and photostimulable phosphor plate digital radiography systems with CBCT to detect the number of root canals in 72 extracted teeth. They found that with digital radiography, endodontists failed to identify at least one root canal in 40% of teeth despite taking parallax radiographs. Major drawbacks of this study were the fact that a radiologist and endodontists assessed the CBCT scans and the digital radiographs respectively. Finally, the teeth were not sectioned to confirm the true number of root canals compared with the 'gold standard' CBCT data.

Cone beam computed tomography reconstructed images have been successfully used in the diagnosis and management of resorptive lesions (Maini *et al.*

2008). CBCT is able to reveal the true nature and exact location of the lesion, determine the 'portal of entry' of the resorptive lesion and also reveal previously undetected resorptive lesions (Cohenca *et al.* 2007b, Patel & Dawood 2007). With this additional information, decision making on treatment strategies may be more predictable. For example, CBCT slices may reveal if an external cervical resorptive lesion has perforated the root canal or if an internal resorptive lesion has perforated into the adjacent periodontium (Fig. 10).

Cone beam computed tomography reconstructed scans are invaluable for assessing teeth with unusual anatomy, such as teeth with an unusual number of roots, dilacerated teeth and dens in dente (Fig. 11). The exact location and anatomy of the root canal system can be assessed, allowing successful management of

the case (Cotton *et al.* 2007, Patel *et al.* 2007). Previously, even with the aid of magnification, the anatomy of such a tooth may not be truly appreciated, making treatment more unpredictable.

Conclusion

It is essential to remember that CBCT uses ionizing radiation and therefore is not without risk. It is essential that patient radiation exposure is kept as low as reasonably practicable and that evidence-based selection criteria for CBCT use are developed. The benefits of a CBCT investigation must outweigh any potential risks (Farman 2005, Vandenberghe *et al.* 2007), therefore endodontic cases should be judged individually and until further evidence is available CBCT should only be considered in situations where information from conventional imaging systems does not yield an adequate amount of information to allow appropriate management of the endodontic problem.

Cone beam computed tomography technology is improving at a rapid pace, at the same time more companies are introducing CBCT scanners into a steadily increasing and competitive market. This should result in a reduction in cost of CBCT scanners, which in turn will increase its uptake by dentists. Users of CBCT must be adequately trained in CBCT radiology as well as interpretation of these images as they are completely different to conventional radiography systems. CBCT data captures a considerable amount of data and this is especially so with large volume scans, even when the FOV has been reduced. All the data on the scan, not just the area of interest, must be reviewed and any anomalies must be reported and acted upon by the dental surgeon requesting the scan or by a specialist radiologist (Scarfe *et al.* 2006, Nair & Nair 2007).

Cone beam computed tomography overcomes most of the limitations of intra-oral radiography. The increased diagnostic data should result in more accurate diagnosis and monitoring and therefore improved decision making for the management of complex endodontic problems. It is a desirable addition to the endodontist's armamentarium and its use should be incorporated into endodontic postgraduate programmes.

When indicated, three-dimensional CBCT scans may supplement conventional 'two dimensional' radiographic techniques, which at present have higher resolution than CBCT images; in this way, the benefits each system may be harnessed (Vandenberghe *et al.* 2007).

Acknowledgement

Cavendish Imaging, London, UK for producing the rapid prototyping model and invaluable assistance in the preparation of this manuscript.

References

- Arai Y, Honda K, Iwai K, Shinoda K (2001) Practical model '3DX' of limited cone-beam X-ray CT for dental use. *International Congress Series* **2001**, 713–8.
- Arnheiter C, Scarfe WC, Farman AG (2006) Trends in maxillofacial cone-beam computed tomography usage. *Oral Radiology* **22**, 80–5.
- Baba R, Ueda K, Okabe M (2004) Using a flat-panel detector in high resolution cone beam CT for dental imaging. *Dento-maxillofacial Radiology* **33**, 285–90.
- Bottollier-Depois JF, Chau Q, Bouisset P, Kerlau G, Plawinski L, Lebaron-Jacobs L (2003) Assessing exposure to cosmic radiation on board aircraft. *Advanced Space Research* **32**, 59–66.
- Cohenca N, Simon JH, Roges R, Morag Y, Malfaz JM (2007a) Clinical indications for digital imaging in dento-alveolar trauma. Part 1: traumatic injuries. *Dental Traumatology* **23**, 95–104.
- Cohenca N, Simon JH, Marhtur A, Malfaz JM (2007b) Clinical indications for digital imaging in dento-alveolar trauma. Part 2: root resorption. *Dental Traumatology* **23**, 105–13.
- Cotton TP, Geisler TM, Holden DT, Schwartz SA, Schindler WG (2007) Endodontic applications of cone-beam volumetric tomography. *Journal of Endodontics* **9**, 1121–32.
- Estrela C, Bueno MR, Leles CR, Azevedo B, Azevedo JR (2008) Accuracy of cone beam computed tomography and panoramic radiography for the detection of apical periodontitis. *Journal of Endodontics* **34**, 273–9.
- Faculty of General Dental Practitioners (UK) (2004) The Royal College of Surgeons of England. Selection criteria for dental radiography. *FGDP(UK) Good Practice Guidelines*. London, UK: Royal College of Surgeons of England.
- Farman AG (2005) ALARA still applies-Editorial. *Oral Surgery, Oral Medicine, Oral Pathology, Oral Radiology and Endodontology* **100**, 395–7.
- Farman AG, Farman TT (2005) A comparison of 18 different X-ray detectors currently used in dentistry. *Oral Surgery, Oral Medicine, Oral Pathology, Oral Radiology and Endodontology* **99**, 485–9.
- Friedman S (2002) Prognosis of initial endodontic therapy. *Endodontic Topics* **2**, 59–98.
- Iwai K, Arai K, Hashimoto K, Nishizawa K (2001) Estimation of effective dose from limited cone beam X-ray CT examination. *Japanese Dental Radiology* **40**, 251–9.
- Kobayashi K, Shimoda S, Nakagawa Y, Yamamoto A (2004) Accuracy in measurement of distance using cone-beam

- computerized tomography. *International Journal of Oral & Maxillofacial Surgery* **19**, 228–31.
- Lascala CA, Panella J, Marques MM (2004) Analysis of the accuracy of linear measurements obtained by cone beam computed tomography (CBCT-NewTom). *Dentomaxillofacial Radiology* **33**, 291–34.
- Lofthag-Hansen S, Huuonen S, Gröndahl K, Gröndahl H-G (2007) Limited cone-beam CT and intraoral radiography for the diagnosis of periapical pathology. *Oral Surgery, Oral Medicine, Oral Pathology, Oral Radiology and Endodontology* **103**, 114–9.
- Lofthag-Hansen S, Thilander-Klang A, Ekestubbe A, Helmrot E, Gröndahl K (2008) Calculating effective dose on a cone beam computed tomography device: 3D Accutimo and 3D Accutimo FPD. *Dentomaxillofacial Radiology* **37**, 72–9.
- Low MTL, Dula KD, Bürgin W, von Arx T (2008) Comparison of periapical radiography and limited cone-beam tomography in posterior maxillary teeth referred for apical surgery. *Journal of Endodontics* **34**, 557–62.
- Ludlow JB, Davies-Ludlow LE, Brooks SL (2003) Dosimetry of two extraoral direct imaging devices: NewTom cone beam CT and Orthophos Plus DS panoramic unit. *Dentomaxillofacial Radiology* **32**, 229–34.
- Ludlow JB, Davies-Ludlow LE, Brooks SL, Howerton WB (2006) Dosimetry of 3 CBCT devices for oral and maxillofacial radiology: CB Mercuray, NewTom 3G and i-CAT. *Dentomaxillofacial Radiology* **35**, 219–26.
- Ludlow JB, Lester WS, See M, Bailey LJ, Hershey HG (2007) Accuracy of measurements of mandibular anatomy in cone beam computed tomography images. *Oral Surgery, Oral Medicine, Oral Pathology, Oral Radiology and Endodontology* **103**, 534–42.
- Mah J, Danforth RA, Bumann A, Hatcher D (2003) Radiation absorbed in maxillofacial imaging with a new dental computed tomography device. *Oral Surgery, Oral Medicine, Oral Pathology, Oral Radiology and Endodontics* **96**, 508–13.
- Maini A, Durning P, Drage N (2008) Resorption: within or without? The benefit of cone-beam computed tomography when diagnosing a case of an internal/external resorption defect. *British Dental Journal* **204**, 135–7.
- Matherne RP, Angelopoulos C, Kulilid JC, Tira D (2008) Use of cone-beam computed tomography to identify root canal systems *in vitro*. *Journal of Endodontics* **34**, 87–9.
- Mischkowski RA, Pulsfort R, Ritter L *et al.* (2007) Geometric accuracy of a newly developed cone-beam device for maxillofacial imaging. *Oral Surgery, Oral Medicine, Oral Pathology, Oral Radiology and Endodontology* **104**, 551–9.
- Mora MA, Mol A, Tyndall DA, Rivera E (2007) In vitro assessment of local tomography for the detection of longitudinal tooth fractures. *Oral Surgery, Oral Medicine, Oral Pathology, Oral Radiology and Endodontology* **103**, 825–9.
- Mozzo P, Procacci C, Tacconi A, Martini PT, Andreis IA (1998) A new volumetric CT machine for dental imaging based on the cone-beam technique: preliminary results. *European Radiology* **8**, 1558–64.
- Murmulla R, Wörtche R, Mühling J, Hassfeld S (2005) Geometric accuracy of the NewTom 9000 Cone Beam CT. *Dentomaxillofacial Radiology* **34**, 28–31.
- Nair MK, Nair UP (2007) Digital and advanced imaging in endodontics a review. *Journal of Endodontics* **33**, 1–6.
- Nakata K, Naitoh M, Izumi M, Inamoto K, Arijii E, Nakamura H (2006) Effectiveness of dental computed tomography in diagnostic imaging of periradicular lesion of each root of a multiradical tooth: a case report. *Journal of Endodontics* **32**, 583–7.
- Ngan DCS, Kharbanda OP, Geenty JP, Darendeliler MA (2003) Comparison of radiation levels from computed tomography and conventional dental radiographs. *Australian Dental Journal* **19**, 67–75.
- Obenauer S, Dullin C, Houser M (2007) Flat panel detector-based volumetric computed tomography (fpVCT). *Investigative Radiology* **42**, 291–6.
- Patel S, Dawood A (2007) The use of cone beam computed tomography in the management of external cervical resorption lesions. *International Endodontic Journal* **40**, 730–7.
- Patel S, Dawood A, Whaites E, Pitt Ford T (2007) The potential applications of cone beam computed tomography in the management of endodontic problems. *International Endodontic Journal* **40**, 818–30.
- Patel S, Mannocei F, Wilson R, Dawood A, Pitt Ford T (2008) Detection of periapical bone defects in human jaws using cone beam computed tomography and intraoral radiography. *International Endodontic Journal* Accepted for publication.
- Pinsky HM, Dyda A, Pinsky RW, Misch KA, Sarment DP (2006a) Accuracy of three-dimensional measurements using cone-beam CT. *Dentomaxillofacial Surgery* **35**, 410–6.
- Pinsky HM, Dyda S, Pinsky RW, Misch KA, Sarment DP (2006b) Accuracy of three-dimensional measurements using cone-beam CT. *Dentomaxillofacial Radiology* **35**, 410–6.
- Rigolone M, Pasqualini D, Bianchi L, Berutti E, Bianchi SD (2003) Vestibular surgical access to the palatine root of the superior first molar: “low-dose cone-beam” CT analysis of the pathway and its anatomic variations. *Journal of Endodontics* **29**, 773–5.
- Scarfe WC, Farman AG (2008) What is cone-beam CT and how does it work? *Dental Clinics of North America* **52**, 707–30.
- Scarfe WC, Farman AG, Sukovic P (2006) Clinical applications of cone-beam computed tomography in dental practice. *Journal of the Canadian Dental Association* **72**, 75–80.
- Schulze D, Heiland M, Thurmann H, Adam G. (2004) Radiation exposure during midfacial imaging using 4- and 16-slice computed tomography, cone beam computed tomography systems and conventional radiography. *Dentomaxillofacial Radiology* **33**, 83–6.
- Simon JH, Enciso R, Malfaz J-M, Roges R, Bailey-Perry M, Patel A (2006) Differential diagnosis of large periapical lesions

- using cone-beam computed tomography measurements and biopsy. *Journal of Endodontics* **32**, 833–7.
- Soğur E, Baksı BG, Gröndahl H-G (2007) Imaging of root canal fillings: a comparison of subjective image quality between limited conebeam CT, storage phosphor and film radiography. *International Endodontic Journal* **40**, 179–85.
- Stavropoulos A, Wenzel A (2007) Accuracy of cone beam dental CT, intraoral digital and conventional film radiography for the detection of periapical lesions: an ex vivo study in pig jaws. *Clinical Oral Investigations* **11**, 101–6.
- Stratemann SA, Huang JC, Maki K, Miller AJ, Hatcher DC (2008) Comparison of cone beam computed tomography imaging with physical measures. *Dentomaxillofacial Radiology* **37**, 80–93.
- Terakado M, Hashimoto K, Arai Y, Honda M, Sekiwa T, Sato H (2000) Diagnostic imaging with newly developed ortho cubic super-high resolution computed tomography (Ortho-CT). *Oral Surgery, Oral Medicine and Oral Pathology, Oral Radiology and Endodontics* **89**, 509–18.
- Tsukiboshi M (2008) Optimal use of photography, radiology and micro computed tomography scanning in the management of traumatized teeth. *Endodontic Topics* **12**, 4–19.
- Tsurumachi T, Honda K (2007) A new cone beam computerized tomography system for use in endodontic surgery. *International Endodontic Journal* **40**, 224–32.
- Vandenberghe B, Jacobs R, Yang J (2007) Diagnostic validity (or acuity) of 2D CCD versus 3D CBCT-images for assessing periodontal breakdown. *Oral Surgery, Oral Medicine and Oral Pathology, Oral Radiology and Endodontology* **104**, 395–401.
- Yamamoto K, Ueno K, Seo K, Shinohara D (2003) Development of dento-maxillofacial cone beam X-ray computed tomography system. *Orthodontic Craniofacial Research* **6**(Suppl. 1), 160–2.