

# Root Canal Preparation of Maxillary Molars With the Self-adjusting File: A Micro-computed Tomography Study

Ove A. Peters, DMD, MS, PhD,\* and Frank Paqué, Dr med dent<sup>†</sup>

## Abstract

**Introduction:** The aim of this study was to describe the canal shaping properties of a novel nickel-titanium instrument, the self-adjusting file (SAF), in maxillary molars. **Methods:** Twenty maxillary molars were scanned by using micro-computed tomography at 20- $\mu\text{m}$  resolution. Canals were shaped with the SAF, which was operated with continuous irrigation in a handpiece that provided an in-and-out vibrating movement. Changes in canal volumes, surface areas, and cross-sectional geometry were compared with preoperative values. Canal transportation and the fraction of unprepared canal surface area were also determined. Data were normally distributed and compared by analyses of variance. **Results:** Preoperatively, mean canal volumes were  $2.88 \pm 1.32$ ,  $1.50 \pm 0.99$ , and  $4.30 \pm 1.89 \text{ mm}^3$  for mesiobuccal (MB), distobuccal (DB), and palatal (P) canals, respectively; these values were statistically similar to earlier studies with the same protocol. Volumes and surface areas increased significantly in MB, DB, and P canals; mean canal transportation scores in the apical and middle root canal thirds ranged between 31 and 89  $\mu\text{m}$ . Mean unprepared surfaces were  $25.8\% \pm 12.4\%$ ,  $22.1\% \pm 12.0\%$ , and  $25.2\% \pm 11.3\%$  in MB, DB, and P canals, respectively ( $P > .05$ ) when assessed at high resolution. **Conclusions:** By using SAF instruments *in vitro*, canals in maxillary molars were homogeneously and circumferentially prepared with little canal transportation. (*J Endod* 2010; ■:1–5)

## Key Words

Micro-computed tomography, nickel-titanium instruments, root canal preparation, self-adjusting file

From the \*Department of Endodontics, Arthur A. Dugoni School of Dentistry, University of the Pacific, San Francisco, California; and <sup>†</sup>Division of Endodontology, University of Zurich Dental School, Zurich, Switzerland.

Address requests for reprints to Dr Ove Peters, University of the Pacific, Arthur A. Dugoni School of Dentistry, 2155 Webster St, San Francisco, CA 94115. E-mail address: [opeters@pacific.edu](mailto:opeters@pacific.edu).

0099-2399/\$ - see front matter

Copyright © 2010 American Association of Endodontists.

doi:10.1016/j.joen.2010.08.047

Cleaning and shaping of root canals successfully require the presence of irrigation solutions that can only be applied to the apical root canal third after enlargement with instruments (1–4). Nickel-titanium (NiTi) rotary instruments have become an important adjunct for root canal shaping, and outcomes with these instruments are fairly predictable (5). However, rotary instruments perform comparably poorly in long-oval canals such as distal canals in lower molars, specifically because they do not mechanically prepare 60% or more canal surface under these conditions (6).

Very recently a new concept, the so-called self-adjusting file (SAF), has emerged that might allow uniform dentin removal along the perimeter of oval canals. Root canal preparation with this file has been quantitatively described only in anterior teeth (7) but not in molar root canals.

The effects of root canal shaping were assessed, besides other approaches, from double-exposure radiographs (8), from cross sections by using the Bramante technique (9), and more recently by using micro-computed tomography (MCT) data (10). The latter technique allows nondestructive quantitative analyses of variables such as volume, surface areas, cross-sectional shape, taper, and the fraction of affected surface (11).

Earlier studies had indicated that differences in canal anatomy between palatal (P), mesiobuccal (MB), and distobuccal (DB) canals would play a significant role for shaping outcomes (12). More ribbon-shaped or flat canals such as the MB canal would have more unprepared canal area; moreover, on average, smaller more curved MB canals would have greater canal transportation than P canals.

On the basis of the fact that the SAF is capable of addressing non-round canal cross sections, we hypothesized that various canals in maxillary molars can be prepared to similar outcomes with respect to canal transportation and amount of prepared surface.

Studies based on MCT done in our laboratory during the last decade provided data on preparation effects for hand and rotary instruments in maxillary molars (10, 12–14). Therefore, the aim of this study was to describe the canal shaping properties of the SAF in maxillary molars.

## Materials and Methods

### Selection of Teeth

From teeth that had been extracted for reasons unrelated to the current study, 20 human maxillary molars were collected and stored in 0.1% thymol solution at 4°C until further use. Teeth had mature apices and were free of fractures and artificial alterations. They were mounted on scanning electron microscopy stubs and then scanned in a desktop MCT unit at an isotropic resolution of 20  $\mu\text{m}$  ( $\mu\text{CT}$  40; Scanco Medical, Brütisellen, Switzerland) by using previously established methods (10, 15). Care was taken to specifically select teeth that did not have a distinct fourth canal orifice so as to include a buccolingually flat mesiobuccal canal, as judged from a preoperative MCT scan in low resolution. Teeth were then accessed by using high-speed diamond burs, and patency of the coronal canal was confirmed. Coronal flaring was accomplished with #2 Gates Glidden burs (Dentsply Maillefer, Ballaigues, Switzerland) placed to 2–3 mm below the cemento-enamel junction. Subsequently, canal lengths and patency were determined with size 10 K-files (Dentsply Maillefer) and radiographs; working lengths (WLs) were set 1 mm shorter than the radiographic apex. Each canal was then probed with #20 K-file. If it reached the WL, no further preparation was done. If the canal was narrower than that, it was prepared until #20 K-file could freely reach the WL to provide a glide path.

## Basic Research—Technology

### Root Canal Instrumentation with the SAF

The SAF was operated by using a trans-line (in-and-out) vibrating handpiece (GENTLEpower; KaVo, Biberach a. d. Riß, Germany, combined with a RDT3 head, ReDent Nova, Ra'anana, Israel) (16) at a frequency of 83.3 Hz (5000 movements per minute) and an amplitude of 0.4 mm. This movement combined with intimate contact along the entire circumference and length of the canal and the slightly rough surface of the file removed a layer of dentin with a filing motion. The hollow design allowed for continuous irrigation throughout the procedure. A special irrigation device (VATEA; ReDent Nova) was connected to the irrigation hub on the file and provided flow of the irrigant (3% NaOCl) at a flow rate of 5 mL/min.

An SAF of 1.5 mm was inserted into each canal while vibrating and delicately advanced apically with an intermittent in-and-out hand movement of 5-mm amplitude until it reached the predetermined WL. Each SAF was operated for 4 minutes per canal with continuous irrigation (16); all preparations were done by a single general practitioner who had been specifically trained with the SAF instrument. Each maxillary molar was prepared with a new SAF, and canals were instrumented in a random sequence, ie, an equal number of MB, DB, and P canals was instrumented as the first canal with a new file.

The clinician was not allowed to see the virtual models of reconstructed teeth before preparing the root canals and during the course of the treatment. This was done to avoid bias by an attempt to manually direct the preparation instrument into any potentially uninstrumented area.

### Evaluation

Virtual root canal models were reconstructed on the basis of MCT scans and superimposed with a precision of better than 1 voxel. Precise repositioning of pre-preparation and various post-preparation images was ensured by a combination of a custom-made mounting device and a software-controlled iterative superimposition algorithm (11, 15, 17); the resulting color-coded root canal models (green indicates preoperative, red postoperative canal surfaces) enabled qualitative comparison of the matched root canals before and after shaping.

Original data sets with 20- $\mu$ m resolution were reformatted with a resolution of 34  $\mu$ m to facilitate direct comparison with earlier studies by using the same experimental setup (10, 12), resulting in a total of 80 MCT data sets with 2 different resolutions (20  $\mu$ m and 34  $\mu$ m). For individual canals, evaluation was done for the full canal length up to the level of the cemento-enamel junction as well as in the apical 4 mm by using custom-made software (IPL; Scanco Medical) as described previously (15). The cross-sectional appearance, round or more ribbon-shaped, was expressed as the structure model index (SMI). This stereological index varies from 1 (parallel plates) to 4 (perfect ball) and was described earlier in detail (11).

Increases in volumes and surface areas were calculated by subtracting the scores for the treated canals from those recorded for the untreated counterparts. Matched images of the surface areas of the canals, before and after preparation, were examined to quantify the amount of uninstrumented area. This parameter was expressed as a percentage of the number of static surface voxels to the total number of surface voxels. As detailed earlier (11), canal transportation was assessed from “centers of gravity” that were calculated for each slice and connected along the z-axis with a fitted line. Mean transportation scores were then calculated by comparing the centers of gravity before and after treatment for the apical, mid, and coronal thirds of the canals.

### Statistical Analysis

Normality assumptions were verified, and therefore data are reported as mean  $\pm$  standard deviation. Original voxel volume in this

data set was  $8 \times 10^{-6}$  mm<sup>3</sup>; volume data are rounded to the nearest 1/100 mm<sup>3</sup>, area data are reported to the nearest 1/100 mm<sup>2</sup>, data for prepared canal surface area are presented as percentages relative to preoperative canal surface areas, and canal transportation is reported to the nearest in 1/mm distance.

Because normality assumptions could be verified, means were compared by using one-way and two-way analyses of variance (ANOVAs) with Bonferroni/Dunn tests for post hoc comparison; the level of statistical significance was set at  $\alpha = 0.05$ .

## Results

Preoperatively, mean canal volumes ranged from 1.50–4.30 mm<sup>3</sup> in maxillary molar canals (Table 1). Reformating the data set to a resolution of 34  $\mu$ m resulted in, on average,  $0.07 \pm 0.04$  mm<sup>3</sup> smaller volumes. Mean initial canal volumes in the apical 4 mm were 0.69, 0.31, and 0.91 mm<sup>3</sup> in MB, DB, and P canals, respectively ( $P < .01$ ). Canal cross sections were rounder in DB and P canals compared with MB canals ( $P < .01$ , Table 1). Both preoperative volumes and SMI scores were statistically similar compared with samples of maxillary molars used in earlier studies (10, 12–14).

Preoperatively, maxillary molar root canals presented with various curves and accessory canals. Most accessory canals remained visible in postoperative canal models (Fig. 1A). Canal cross sections, as assessed by the SMI, varied as well, with significantly flatter canals mesiobuccally (Table 1). Overall, canal preparation of root canals in maxillary molars with the SAF resulted in adequate canal shapes with no major shaping errors. In particular, no SAF fractured during the course of the study. On the basis of superimposed red-green coded surface areas (Fig. 1A), overall shapes were satisfactory, with similar amounts of dentin removed around the perimeter in most cross sections (Fig. 1A) and overall fully prepared canal surface areas.

Preparing with the SAF for 4 minutes resulted in mean dentin removal ranging from 2.00–2.87 mm<sup>3</sup>; this represented significant volume changes compared with preoperative data ( $P < .01$ ). Differences in volume increase were small but significantly different when comparing the 3 canal types investigated (Table 1). Increases in SMI were only significant for MB canals; 8 of 60 canals had SMI increases of 1 or more, all of which were MB canals. Slice-by-slice observation indicated that rounding of MB canals occurred mostly in the coronal third.

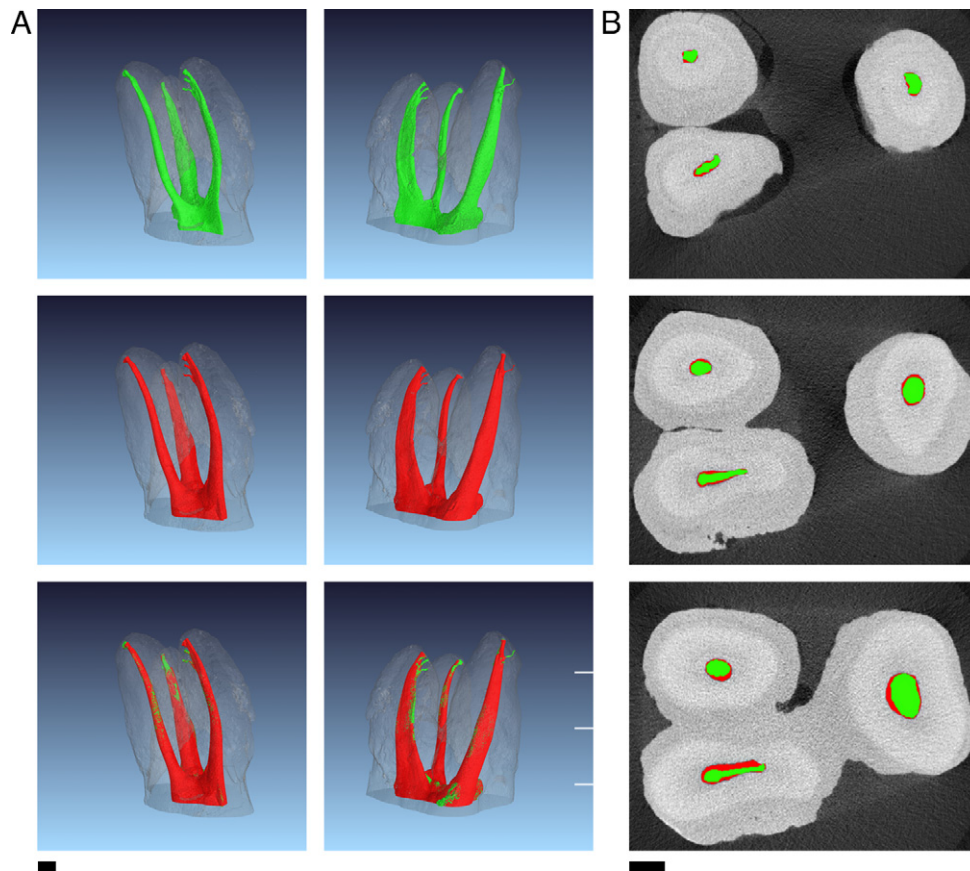
Mechanically untreated canal areas, calculated by using superimposed MCT data sets (Fig. 1), were  $25.8\% \pm 12.4\%$ ,  $22.1\% \pm 12.0\%$ ,

**TABLE 1.** Morphometric Data (mean  $\pm$  standard deviation, n = 20 each) and Their Changes for Root Canals in Maxillary Molars and Changes after Preparation with SAF

	Mesiobuccal	Distobuccal	Palatal
Volume (mm <sup>3</sup> )	2.88 $\pm$ 1.32 <sup>ab</sup>	1.50 $\pm$ 0.99 <sup>ac</sup>	4.30 $\pm$ 1.89 <sup>bc</sup>
$\Delta$ Volume (mm <sup>3</sup> )	2.87 $\pm$ 1.14 <sup>de</sup>	2.00 $\pm$ 0.53 <sup>d</sup>	2.20 $\pm$ 0.71 <sup>e</sup>
Area (mm <sup>2</sup> )	25.54 $\pm$ 8.42 <sup>f</sup>	13.26 $\pm$ 4.77 <sup>fg</sup>	23.30 $\pm$ 5.20 <sup>g</sup>
$\Delta$ Area (mm <sup>2</sup> )	4.89 $\pm$ 1.82 <sup>h</sup>	7.13 $\pm$ 2.41 <sup>hi</sup>	5.31 $\pm$ 2.00 <sup>i</sup>
SMI (units)	2.11 $\pm$ 0.47 <sup>jk</sup>	3.14 $\pm$ 0.23 <sup>j</sup>	3.29 $\pm$ 0.18 <sup>k</sup>
$\Delta$ SMI (units)	0.85 $\pm$ 0.31 <sup>lm</sup>	0.19 $\pm$ 0.18 <sup>l</sup>	0.11 $\pm$ 0.11 <sup>m</sup>

SAF, self-adjusting file; SMI, structure model index.

Significantly different results among root types are indicated by the same superscripted letter ( $P < .05$ ).



**Figure 1.** Representative example of MCT data of maxillary molar root canals prepared with SAF. Preparation time was 4 minutes; black length bars are 1 mm. Note accessory canals that are visible in postoperative images. (A) Preoperative, postoperative, and superimposed reconstructions (from top to bottom) and in clinical and angled views (left and right columns). (B) Cross sections in the apical, middle, and coronal root canal thirds showing the amount of removed dentin in the canal periphery. Green and red areas are preoperative and postoperative cross sections; white lines in (A) indicate section levels.

and  $25.2 \pm 11.3\%$  for MB, DB, and P canals, respectively (Table 2); untreated canal areas were not statistically different when comparing the 3 canal types ( $P > .05$ ). When restricted to the apical 4 mm, uninstrumented canal areas ranged from 28.8% in DB canals to 47.4% in P canals. When canal models were reformatted to 34- $\mu\text{m}$  resolution, overall uninstrumented areas were 38.5% (Table 2).

Mean canal transportation ranged from 31–149  $\mu\text{m}$  and was larger in the coronal third compared with the apical and middle canal thirds ( $P < .01$ , Table 3). Canal transportation was lowest in the palatal canal. Differences between all canal types with respect to canal transportation at the middle and apical levels were significant; however, the individual canal transportation values exceeded 100  $\mu\text{m}$  only in 15 of 120 cases at those 2 levels. No differences were registered when surface areas or canal transportation were recalculated on the basis of 34  $\mu\text{m}$  compared with 20  $\mu\text{m}$ .

## Discussion

This study is the second part of a comprehensive, MCT-based evaluation of the shaping potential of a novel root canal preparation instru-

ment, the SAF. Design (16) and various mechanical parameters (18) of this new system have been described in detail previously. The first MCT study of the current series detailed shaping in anterior teeth and dentin removal over time (7). The current report focuses on preparation of maxillary molars with curved canals and various cross sections, for example, round DB canals and ribbon-shaped or flat MB canals.

Teeth selected for this study were statistically similar to teeth used in earlier studies (10, 12–14) on maxillary molars with respect to morphologic parameters such as preoperative canal volume, SMI, and canal curvature.

Dentin removal with the SAF is most effective during the first 2 minutes of use (18). However, additional time might be needed to ensure a full canal wall preparation in some cases; for example, 4 and possibly 5 minutes of activation were required in anterior teeth (7). Preparation with the SAF did not result in obvious preparation errors such as perforation and ledging, with canal transportation values typically below 100  $\mu\text{m}$  for the middle and apical canal sections. The slightly larger canal transportation in the coronal section, particularly in MB canals, could have been possibly caused by Gates Glidden drills in an attempt to facilitate straight-line access. Overall, canal

**TABLE 2.** Root Canal Surface Area (%) Not Affected by Preparation with SAF (mean  $\pm$  standard deviation,  $n = 20$  each) for Root Canals in Maxillary Molars

	Mesiobuccal	Distobuccal	Palatal
Unprepared area (20- $\mu\text{m}$ resolution)	$25.8 \pm 12.4$	$22.1 \pm 12.0$	$25.2 \pm 11.3$
Unprepared area (34- $\mu\text{m}$ resolution)	$37.8 \pm 13.0$	$35.6 \pm 13.6$	$42.1 \pm 12.3$

There were no significantly different results among root types.



## Basic Research—Technology

**TABLE 3.** Mean ( $\pm$  standard deviation,  $n = 20$  each) Canal Transportation (mm) and Range Determined for Coronal, Middle, and Apical Root Canal Thirds after Preparation with SAF

	Mesiobuccal	Distobuccal	Palatal
Coronal 1/3	113 $\pm$ 37 (60–189) <sup>ab</sup>	149 $\pm$ 58 (63–295) <sup>bc</sup>	65 $\pm$ 24 (31–113) <sup>ac</sup>
Middle 1/3	59 $\pm$ 27 (20–138) <sup>de</sup>	89 $\pm$ 45 (29–174) <sup>ef</sup>	31 $\pm$ 15 (10–62) <sup>df</sup>
Apical 1/3	78 $\pm$ 30 (33–146) <sup>g</sup>	81 $\pm$ 34 (22–18) <sup>h</sup>	47 $\pm$ 21 (22–92) <sup>gh</sup>

<sup>abcdelgh</sup>Significantly different results within levels are indicated by ( $P < .05$ ).

transportation is likely a cumulated effect of coronal flaring, glide path preparation, and the action of the SAF. Similarly, adding instruments for further apical enlargement tends to increase canal transportation, as shown in an MCT-based pilot study with sequential scanning (19).

An earlier study with the same experimental setup had shown overall canal transportation scores of 123.7, 89.8, and 97.7  $\mu$ m for the coronal, middle, and apical thirds, respectively, after preparation with NiTi rotary instruments or K-files (10). These scores and also those described for MB, DB, and P canals shaped with ProTaper (12) and FlexMaster (13) indicate larger canal transportation for rotary instruments than for the SAF in maxillary molar canals.

The present study used MCT to evaluate canal preparation with the SAF. MCT evaluation was introduced to experimental endodontics more than a decade ago (11); it has been used to assess, in a quantitative and three-dimensional approach, the performance of various canal instrumentation techniques (10, 15, 20–22). The cited studies vary with regard to the type of the MCT systems used and their spatial resolution as well as in the software used for evaluation. However, a direct comparison between existing MCT data regarding NiTi rotary instruments generated by the authors (10, 12–14) and the present study was made possible with the recalculation of the data in a 34- $\mu$ m resolution, which had been used earlier. The reformatting did not result in significant changes for canal volume, surface area, or canal transportation data.

A potential limitation of this study as in the majority of MCT-based studies is the relatively small sample size of 60 canals in total. It is, however, larger compared with earlier (10, 12, 21) and similar to more recent (22) MCT-based studies.

An obvious strength of the present nondestructive approach was that it permitted repeated evaluation before and after canal preparation. Moreover, quantitative data for morphologic parameters and canal transportation were obtained.

As in the previous study on the use of the SAF in maxillary incisors (7), cases with accessory canals were present in this study sample, and larger accessory canals might contribute relevantly to the amount of unprepared surface. Therefore, manual editing was used to eliminate such accessory canals from the evaluation.

A major question addressed with MCT studies is the amount of unprepared surface. The software used in the present study, described in more detail earlier (11, 17), counts a surface voxel as belonging to any given structure when the full voxel belongs to it. Therefore, to be counted as “treated,” at least one full voxel has to be registered as removed from the preoperative canal model after superimposition. In other words, it might very well be the case that a sub-voxel amount of dentin is being shaved off canal wall (the walls were “touched”), and no canal wall preparation is registered. In fact, our earlier study on the effect of SAF preparation on maxillary incisors (7) indicated that 5 minutes of shaping with the 2.0-mm SAF resulted in 91.4% treated surface, but only 56.6% surface had more than 100  $\mu$ m dentin shaved off.

The present study, on the basis of 20- $\mu$ m resolution, demonstrates overall unaffected canal area of 25.2%. However, a recalculation to 34- $\mu$ m resolution results in overall 38.5% unaffected area. One earlier

study on canals prepared to apical sizes #40 (MB, DB) and #45 (P) (10) indicated similar amounts of overall unprepared surface as in the present study (38.1%). However, rotary preparation of flat MB canals in maxillary molars in earlier studies (12, 13) resulted in 43.0% and 47.4% mean unaffected areas, respectively, which is higher than the scores in the present study.

Taken together, cross sections from various slices (Fig. 1) and low scores for unaffected canal surface, in particular for flat canals, suggest that canal preparation with the SAF does indeed result in homogenous preparation and circumferential removal of a layer of hard tissue.

In the present study, there were no significant differences in respect to affected canal surface among the canal types. Nevertheless, when the same SAF size is used (eg, 1.5 mm) for multiple canals in the same tooth, it might be prudent to increase preparation time for larger canal diameters. This will compensate for lesser forces of the cutting SAF elements against canal walls (18) in larger canals such as the palatal or the distal canal in molars. Alternatively, it might be advisable to instrument large canals before any smaller canals, on the basis of the tactile feedback during confirmation of the glide path.

Preparation with the SAF resulted in less SMI changes in P and DB canals compared with earlier results (10); slice-by-slice evaluation indicated that the increase in cross-sectional roundness in coronal canal third of MB canals, as opposed to retaining the buccolingual flat shape, could be explained by the use of Gates Glidden burs. A recent study (22) detailed SMI scores after rotary preparation in the apical 1 mm of shaped canal and found scores of 2.63–2.83 for a sample of maxillary and mandibular molars; this is similar to findings in the present study for the apical 4 mm (data not shown) and might indicate that apical canal sections might be prepared round with the SAF.

Rotary NiTi root canal files have been linked to 3%–5% incidence of intracanal breakage (23); although a retained instrument fragment per se might not significantly alter healing outcomes of periapical lesions, it is preferable to have no impediment to disinfection inside canals. In the present study we did not observe any SAF breakage with retained fragments.

Eradication of microorganisms, a critical step for endodontic outcomes (24), is the result of a combination of mechanical preparation (25) and irrigation (26). Irrigation alone is not always effective (27), and mechanical action of instruments on canal walls, including removal of infected dentin, might be needed. In fact, a recent scanning electron microscopic study suggested that preparation with the SAF leaves very clean dentin walls, probably as a result of concurrent irrigation possible with this system (6). Moreover, accessory canals remained visible in postoperative canal models after SAF preparation, suggesting little or no deposition of dentin shavings under the conditions of the current study (17).

The preparation of the most apical canal section remains a challenge. In the present study, mechanical preparation with the SAF resulted in limited prepared surface. Hence, sufficient deposition of disinfecting irrigation solutions remains important. Antibacterial efficacy of canal surface preparation was not directly determined in the present study. Mechanical preparation per se might affect bacterial biofilms (28) rather than only microorganisms in their planktonic state.

With further improvement in hardware and software, it might be possible in the future to directly determine the amount of biofilm removed from canal surfaces on the basis of MCT-based experiments. Furthermore, it is presently unknown whether canal preparation with the SAF and in particular its potential to debride canal walls better will lead to improved clinical outcomes, but clinical studies are underway to address this question. Another important clinical question is how best to obturate canals prepared with the SAF; initial data (29) suggest that lateral compaction resulted in better obturation quality after SAF preparation compared with rotary instrumentation.

In conclusion, by using SAF instruments *in vitro*, canals in maxillary molars were homogenously and circumferentially prepared with little canal transportation or other procedural errors.

## Acknowledgments

*This study was financially supported by ReDent Nova. Helpful discussions with Dipl.-Ing. Christof Reinbart are gratefully acknowledged.*

## References

- Ram Z. Effectiveness of root canal irrigation. *Oral Surg Oral Med Oral Pathol* 1977; 44:306–12.
- Chow TW. Mechanical effectiveness of root canal irrigation. *J Endod* 1983;9:475–9.
- Hsieh YD, Gau CH, Kung Wu SF, Shen EC, Hsu PW, Fy E. Dynamic recording of irrigation fluid distribution in root canals using thermal image analysis. *Int Endod J* 2007;40:11–7.
- Brunson M, Heilborn C, Johnson DJ, Cohenca N. Effect of apical preparation size and preparation taper on irrigant volume delivered by using negative pressure irrigation system. *J Endod* 2010;36:721–4.
- Hülsmann M, Peters OA, Dummer PMH. Mechanical preparation of root canals: shaping goals, techniques and means. *Endod Topics* 2005;10:30–76.
- Metzger Z, Teperovich E, Cohen R, Zary R, Paqué F, Hülsmann M. The self-adjusting file (SAF). Part 3: removal of debris and smear layer—a scanning electron microscope study. *J Endod* 2010;36:697–702.
- Peters OA, Boessler C, Paqué F. Root canal preparation with a novel nickel-titanium instrument evaluated with micro-computed tomography: canal surface preparation over time. *J Endod* 2010;36:1068–72.
- Iqbal MK, Banfield B, Lavorini A, Bachstein B. A comparison of LightSpeed LS1 and LightSpeed LSX root canal instruments in apical transportation and length control in simulated root canals. *J Endod* 2007;33:268–71.
- Bramante CM, Berbert A, Borges RP. A methodology for evaluation of root canal instrumentation. *J Endod* 1987;13:243–5.
- Peters OA, Schönenberger K, Laib A. Effects of four Ni-Ti preparation techniques on root canal geometry assessed by micro computed tomography. *Int Endod J* 2001;34: 221–30.
- Peters OA, Laib A, Rüegsegger P, Barbakow F. Three-dimensional analysis of root canal geometry using high-resolution computed tomography. *J Dent Res* 2000; 79:1405–9.
- Peters OA, Peters CI, Schönenberger K, Barbakow F. ProTaper rotary root canal preparation: effects of canal anatomy on final shape analysed by micro CT. *Int Endod J* 2003;36:86–92.
- Hübscher W, Barbakow F, Peters OA. Root canal preparation with FlexMaster: canal shapes analysed by micro-computed tomography. *Int Endod J* 2003;36:740–7.
- Paqué F, Barbakow F, Peters OA. Root canal preparation with Endo-Eze AET: changes in root canal shape assessed by micro-computed tomography. *Int Endod J* 2005;38:456–64.
- Paqué F, Ganahl D, Peters OA. Effects of root canal preparation on apical geometry assessed by micro-computed tomography. *J Endod* 2009;35:1056–9.
- Metzger Z, Teperovich E, Zary R, Cohen R, Hof R. The self-adjusting file (SAF): part 1—respecting the root canal anatomy: a new concept of endodontic files and its implementation. *J Endod* 2010;36:679–90.
- Paqué F, Laib A, Gautschi H, Zehnder M. Hard-tissue debris accumulation analysis by high-resolution computed tomography scans. *J Endod* 2009;35:1044–7.
- Hof R, Perevalov V, Zary R, Metzger Z. The self-adjusting file: part 2—mechanical analysis. *J Endod* 2010;36:691–6.
- Paqué F, Schneebeli E, Peters OA. Root canal preparation using hybrid-techniques with different rotary instruments: a three-dimensional analysis with micro-computed tomography (abstract). *J Endod* 2007;33:OR65, 345.
- Bergmans L, Van Cleynenbreugel J, Beullens M, Wevers M, Van Meerbeek B, Lambrechts P. Smooth flexible versus active tapered shaft design using NiTi rotary instruments. *Int Endod J* 2002;35:820–8.
- Bergmans L, Van Cleynenbreugel J, Beullens M, Wevers M, Van Meerbeek B, Lambrechts P. Progressive versus constant tapered shaft design using NiTi rotary instruments. *Int Endod J* 2003;36:288–95.
- Moore J, Fitz-Walter P, Parashos P. A micro-computed tomographic evaluation of apical canal preparation using three instrumentation techniques. *Int Endod J* 2009;42:1057–64.
- Spili P, Parashos P, Messer HH. The impact of instrument fracture on outcome of endodontic treatment. *J Endod* 2005;31:845–50.
- Haapasalo M, Endal U, Zandi H, Coil JM. Eradication of endodontic infection by instrumentation and irrigation solutions. *Endod Topics* 2005;10:77–102.
- Byström A, Sundqvist G. Bacteriologic evaluation of the efficacy of mechanical root canal instrumentation in endodontic therapy. *Scan J Dent Res* 1981;89:321–8.
- Estrela C, Blitzkow G, Figuereido JAP, Estrela CRA. Antibacterial efficacy of intracanal medications on bacterial biofilms: a critical review. *J Appl Oral Sci* 2009; 17:1–7.
- Atin T, Buchalla W, Zirkel C, Lussi A. Clinical evaluation of the cleansing properties of the noninstrumental technique for cleaning root canals. *Int Endod J* 2002;35: 929–33.
- Burleson A, Nusstein J, Reader A, Beck M. The in vivo evaluation of hand/rotary/ultrasound instrumentation in necrotic, human mandibular molars. *J Endod* 2007;33:782–7.
- Metzger Z, Zary R, Cohen R, Teperovich E, Paqué F. The quality of root canal preparation and obturation in canals treated with rotary versus files: a three-dimensional micro-computed tomography study. *J Endod* 2010;36:1569–73.