

Question 2

At what point do we decide to rebuild an endodontically treated tooth with a cast post or a preformed post? Adhesive dentistry is so good now, do we still need posts and crowns on posterior teeth? Don't posts weaken teeth?

Clinical and laboratory evidence supports cuspal coverage or extracoronal restoration of endodontically treated posterior teeth to increase their fracture resistance and longevity.^{1,2} In general, the clinical life of endodontically treated molars and bicuspid significantly improves with coronal coverage. The need for a crown is less evident for anterior teeth, and coronal coverage does not necessarily improve clinical longevity.¹ If adequate tooth structure remains, a direct adhesive restoration is often the optimal treatment for anterior teeth. A post is not recommended in these cases. When complete coverage is required for either anterior or posterior teeth, depending on the amount of peripheral crown reduction needed, a core or a post and core should be considered to provide the necessary retention and fracture resistance of the crown/tooth unit.

Molars can be reinforced with a simple direct coronal-radicular amalgam or a bonded composite restoration, without the need for a post. Using the molar pulp chamber volume provides core retention and strength, and has shown clinical success.³ The problem areas are single-rooted teeth or bicuspid with a slender cervical dimension, particularly if the crown is long and shear forces are present. Resistance form against cervical fracture invariably requires a post placement in these single or narrow canals to reinforce the coronal ferrule. Abutments are particularly vulnerable, especially those for removable partial prostheses.⁴ Post placement designed to minimize canal enlargement and maximize preservation of sound tooth structure is currently advocated. This ensures maximum integrity of the tooth and reduces the technical dangers associated with post space preparation.

In all cases where an endodontically treated tooth receives a crown restoration, the prognosis is largely determined by the presence of adequate sound peripheral tooth structure (ferrule) at the crown–root interface. Teeth with little or no cervical ferrule have a very poor prognosis and will require surgical crown lengthening or forced eruption to allow crown placement on adequate peripheral sound tooth structure. For this reason, the intentional provision of endodontic treatment for vital teeth with inadequate ferrule cannot be recommended.

Management of Maxillary Bicuspid

In conjunction with the need for adequate ferrule, post requirements include high strength to prevent cervical fracture, high elastic limit to prevent distortion, and adequate radiopacity to allow future radiographic assessment. Recommendations on the types of posts to use have

changed in recent years. The superiority of a custom-cast post can no longer be claimed over a well-placed prefabricated post, which allows conservative removal of tooth structure. **Figures 1, 2 and 3** show a successfully endodontically treated second maxillary bicuspid before restorative treatment. The tooth has a slender mesiodistal dimension and shows significant loss of tooth structure. In this case, a minimal post space preparation for a prefabricated parallel Para Post (Coltene Whaledent, Konstanz, Germany) was used (**Fig. 4**), concurrent with crown preparation. The passive, parallel, prefabricated post style has shown considerable success in clinical and laboratory studies and is the post by which all others are usually measured.

When there are high clinical strength requirements combined with minimal coronal tooth structure, a metallic post is preferred. A passive *tapered* prefabricated post allows a more conservative removal of tooth structure where there is optimal ferrule and high retention is not required. Safe post space preparation is best achieved with non-end-cutting rotary instruments. The instruments of choice for least-invasive canal preparation are the small head Gates Glidden bur with the Peeso reamer (**Fig. 5**). It is suggested that the smallest size post space be prepared and the post adapted to the canal whenever possible. In the typical figure eight bicuspid canal, the dimensions of the most conveniently accessed “single” canal provide adequate retention and resistance. Sound tooth structure should not be removed to convert the oval shape to a circular outline form, as it will significantly weaken the tooth and may cause root perforation. In the present clinical case, the pulp chamber has also been cleared of all temporary materials. A 1–2 mm preparation into the second canal, involving removal of gutta-percha only, can be added if higher retention and resistance is required.

Clinical studies support superiority of prefabricated posts.^{1–3,5,6} More tooth structure is removed for cast posts,

Post Considerations

- Minimal canal enlargement following endodontic therapy
- Modification of post to fit canal wherever possible
- Length equal to, or exceeding, clinical crown length
- Passive post preferred, to prevent stress concentration
- Minimum 4–5mm gutta-percha remaining

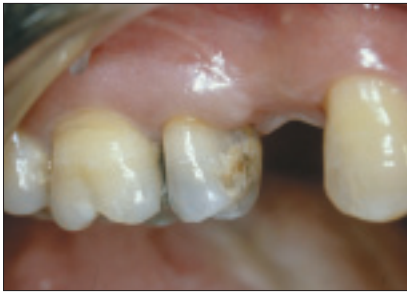

Figure 1: Facial view of a successfully endodontically treated maxillary bicuspid.

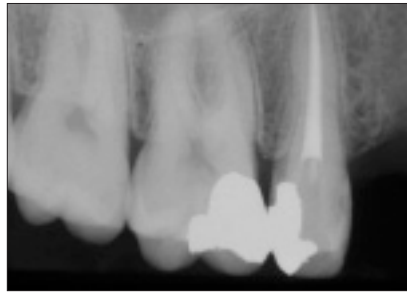


Figure 2: Radiographic view after completion of endodontic treatment.

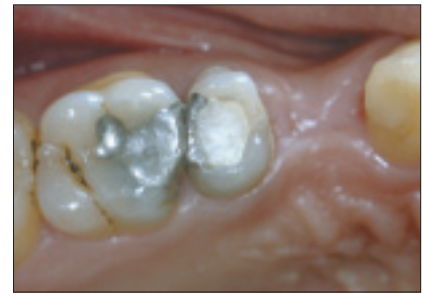

Figure 3: Occlusal view showing extent of occlusal and distal tooth loss.

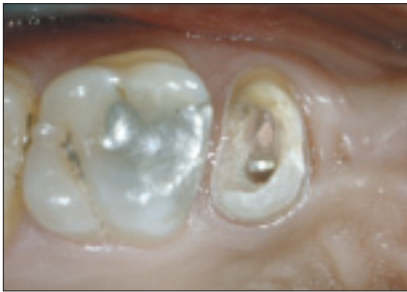

Figure 4: Initial crown preparation with removal of all restorative materials within the crown. Trial placement of prefabricated metal post in palatal canal.




Figure 5: Non-end-cutting rotary instruments for gutta-percha removal and canal preparation. Gates Glidden bur (below) and Peeso reamer (above).

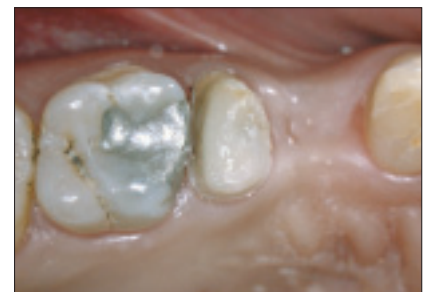

Figure 6: Bonded composite post-core build-up before crown preparation refinement.

2 appointments are necessary, and the cost is high. Even in clinical situations with an important loss of internal dentin — traditionally restored with a custom-cast post and core — there has been more success when the tooth is restored with bonded resin composite reinforced by a smaller central metal post.⁶ Many commercially available prefabricated posts, including esthetic posts, are now available. Different clinical conditions require careful patient-specific treatment planning. **Figure 6** shows the bonded composite core build-up before refinement of the crown preparation. ♦

References

1. Sorensen JA, Martinoff JT. Intracoronal reinforcement and coronal coverage: a study of endodontically treated teeth. *J Prosthet Dent* 1984; 51(6):780-4.
2. Robbins JW. Restoration of endodontically treated teeth. In: Summitt JB, Robbins JW, Schwartz RS, editors. *Fundamentals of operative dentistry — a contemporary approach*. 2nd ed. Quintessence Publishing Co.; 2001. p. 546-66.
3. Robbins JW. Guidelines for the restoration of endodontically treated teeth. *J Am Dent Assoc* 1990; 120(5):558, 560, 562.
4. Sorensen JA, Martinoff JT. Endodontically treated teeth as abutments. *J Prosthet Dent* 1985; 53(5):631-6.
5. Torbjorner A, Karlsson S, Odman PA. Survival rate and failure characteristics for two post designs. *J Prosthet Dent* 1995; 73(5):439-44.
6. Saupé WA, Gluskin AH, Radke RA Jr. A comparative study of fracture resistance between morphologic dowel and cores and a resin-reinforced dowel system in the intraradicular restoration of structurally compromised roots. *Quintessence Int* 1996; 27(7):483-91.



Dr. Dorothy McComb is professor and head of restorative dentistry and director of comprehensive care at the University of Toronto. She has no declared financial interests in any of the products mentioned in this article. E-mail: d.mccomb@utoronto.ca.

Dr. McComb's sessions "Current Operative Dentistry: Part 1. Minimally Invasive Dentistry" and "Part 2. Managing the Heavily Restored Dentition" will be presented Tuesday, June 1 and Wednesday, June 2, respectively.