

# Efficacy of ProTaper Universal rotary retreatment system for gutta-percha removal from root canals

L.-S. Gu, J.-Q. Ling, X. Wei & X.-Y. Huang

Department of Operative Dentistry and Endodontics, Guanghua College of Stomatology, Sun Yat-Sen University, Guangzhou, China

## Abstract

**Gu L-S, Ling J-Q, Wei X, Huang X-Y.** Efficacy of ProTaper Universal rotary retreatment system for gutta-percha removal from root canals. *International Endodontic Journal*, **41**, 288–295, 2008.

**Aim** To evaluate the efficacy of the ProTaper Universal rotary retreatment system for gutta-percha (GP) removal from root canals.

**Methodology** Root canals of 60 extracted human maxillary anterior teeth were prepared and filled with laterally condensed GP and AH Plus sealer. Teeth were divided into three groups: group A – GP removal completed with the ProTaper Universal rotary retreatment system and with further canal reparation accomplished with ProTaper Universal rotary instruments; group B – GP removal was completed using Gates Glidden drills and Hedström files with chloroform as a solvent, followed with further canal reparation with ProTaper Universal rotary instruments; group C – the same as group B for GP removal with further canal preparation with stainless steel K-flex files (Kerr). The

operating time was recorded. Teeth were rendered transparent for the evaluation of the area of remaining GP/sealer in bucco-lingual and mesial–distal directions. Statistical analysis was performed by using repeated measures analysis of variance and ANOVA.

**Results** The ProTaper Universal technique (group A) resulted in a smaller percentage of canal area covered by residual GP/sealer than in groups B and C, with a significant difference between groups A and C ( $P < 0.05$ ). Mean operating time for group A was 6.73 min, which was significantly shorter ( $P < 0.05$ ) than group B (10.86 min) and group C (13.52 min).

**Conclusions** In this laboratory study all test techniques left GP/sealer remnants within the root canal. The ProTaper Universal rotary retreatment system proved to be an efficient method of removing GP and sealer from maxillary anterior teeth.

**Keywords:** endodontic retreatment, gutta-percha, nickel–titanium, ProTaper Universal rotary instruments.

Received 5 December 2006; accepted 25 September 2007

## Introduction

The primary reason for a negative outcome following root canal treatment is the persistence of bacteria within the intricacies of the root canal system (Nair *et al.* 1990, 1999, Sjogren *et al.* 1997, Molander *et al.* 1998, Siqueira 2001). Root canal retreatment aims to eliminate or to substantially reduce the microbial load from the root canal. Thus, nonsurgical

retreatment aims to remove completely the root filling, to enable effective cleaning, shaping and filling of the root canal system (Stabholz & Friedman 1988). Various instruments have been used for gutta-percha (GP) removal, including endodontic hand files, engine-driven rotary files, ultrasonic tips and files, and heat carrying instruments. Chemicals are sometimes used as solvents (Wilcox *et al.* 1987, Lewis & Block 1988, Stabholz & Friedman 1988, Friedman *et al.* 1990, Hulsmann & Stotz 1997). Removal of GP using hand files with or without solvents is time-consuming, especially when the filling materials are well condensed (Sae-Lim *et al.* 2000). Nickel–titanium (NiTi) rotary instruments have been used successfully in root canal cleaning and shaping (Schafer & Lohmann 2002,

Correspondence: Dr Jun-qi Ling, Department of Operative Dentistry and Endodontics, Guanghua College of Stomatology, Sun Yat-Sen University, Guangzhou, China (Tel.: +86 (0)20 83862621; fax: +86 (0)20 83822807; e-mail: lingjq@mail.sysu.edu.cn).

Schafer & Florek 2003, Ayar & Love 2004, Schafer & Vlassis 2004, Guelzow *et al.* 2005, Rangel *et al.* 2005, Schafer *et al.* 2006a,b). Products such as ProFile (Dentsply Tulsa Dental, Tulsa, OK, USA), Quantec (Sybron Dental Specialties, Orange, CA, USA) and FlexMaster (VDW Antreas, Munich, Germany) have been proposed for removal of root filling materials and have been shown to be more efficient and safer than traditional hand files (Imura *et al.* 2000, Sae-Lim *et al.* 2000, Hulsmann & Bluhm 2004, Schirrmeister *et al.* 2006a).

More recently, the ProTaper NiTi rotary system has been upgraded to the ProTaper Universal system, which includes shaping, finishing and retreatment instruments. The three retreatment instruments (D1, D2 and D3) are designed for removing filling materials from root canals. They have various tapers and diameters at the tip, which are size 30, 0.09 taper, size 25, 0.08 taper and size 20, 0.07 taper. The full lengths of these retreatment files are 16 mm for D1, 18 mm for D2 and 22 mm for D3. D1, D2 and D3 are recommended to remove filling materials from the coronal, middle and apical portions of canals respectively. Similar to the shaping and finishing instruments, the retreatment series have a convex cross section, however, D1 has a working tip that facilitates its initial penetration into filling materials. The purpose of the present laboratory study was to evaluate the efficacy of ProTaper Universal retreatment files in removing GP from root canals.

## Materials and methods

### Specimen selection

Extracted human maxillary anterior teeth of similar tooth length were collected. Soft tissue and calculus were mechanically removed from the root surfaces. After preparing access cavities, a size 15 K file (Dentsply Maillefer, Ballaigues, Switzerland) was inserted into the root canal of each tooth until its tip was just visible at the apical foramen. Radiographs were taken to determine the maximum canal curvature as previously reported (Iqbal *et al.* 2003). In brief, each tooth was fixed on a turntable and a series of radiographs were taken whilst incrementally rotating the turntable until the file in the canal appeared straight on the radiograph. Thereafter, the turntable was then rotated 90° to reveal the maximum curvature of the root canal. The degree of canal curvature was then measured (Schneider 1971). Sixty anterior teeth including 42 maxillary incisors and 18 maxillary canines were selected based on the

following criteria: each tooth had a single patent canal; the canal curvature was <10°; the size of the apical foramen was not greater than a size 15 K file.

### Initial root canal treatment

With a size 15 K file inserted in the canal, the end-point of canal preparation and filling was established 1 mm from the foramen. A circumferential 'staging platform' was established near the canal orifice, ensuring a uniform working length (WL) of 15 mm in each tooth.

Cleaning and shaping were performed using a modified step-back flare technique (Walton 1989). The cervical third was flared with sizes 1–3 Gates Glidden drills (Dentsply Maillefer). Canal preparation was carried out by the sequential use of K files up to size 30 at WL, a step-back procedure in 1 mm increments to a file size 50 was then carried out. Upon withdrawal of each instrument, canals were irrigated alternatively with 5.25% NaOCl and 17% ethylenediaminetetraacetic acid (EDTA).

Canals were filled with GP and AH Plus sealer (Dentsply, DeTrey, Konstanz, Germany) using a cold lateral compaction technique. The coronal extension of root fillings was uniformly limited to the level of the staging platform. The access cavities were sealed with Cavit (DeTrey Dentsply). The quality of the root fillings was confirmed using postoperative radiographs in bucco-lingual (B-L) and mesial-distal (M-D) views. The B-L and M-D dimensions of all root canals were measured on the radiographs at the orifice level. The ratio of B-L dimension to M-D dimension was calculated for each specimen. All teeth were stored at 37 °C in a humidifier for 30 days to allow complete setting of the sealer.

### Endodontic retreatment

As canal morphologies were different between incisor and canine teeth, stratified randomization was performed to ensure that these tooth types were allocated equally to each retreatment group. The ratio of incisors and canines in each group was thus 14/6. Removal of GP was performed by using one of the following techniques, and the sequences of instruments used in the present study are given in Table 1.

*Group A: ProTaper Universal retreatment instruments with further canal preparation using ProTaper Universal shaping and finishing instruments*  
Root fillings were removed with ProTaper Universal retreatment instruments following the manufacturers'

**Table 1** Sequences of instruments and working length (WL)

Group A		Group B		Group C	
Instruments	WL (mm)	Instruments	WL (mm)	Instruments	WL (mm)
D1 file (9% taper, size 30)	5	#3 GG drill (tip size 0.09)	2	#3 GG drill (tip size 0.09)	2
D2 file (8% taper, size 25)	10	#2 GG drill (tip size 0.07)	3	#2 GG drill (tip size 0.07)	3
D3 file (7% taper, size 20)	15	#1 GG drill (tip size 0.05)	4	#1 GG drill (tip size 0.05)	4
S1 file (shaping file no.1; taper 2–11%; size 17)	15	ISO size 30 Hedström files	5	ISO size 30 Hedström files	5
S2 file (shaping file no.2; taper 4–11.5%; size 20)	15	ISO size 25 Hedström files	10	ISO size 25 Hedström files	10
F1 file (finishing file no.1; taper 5.5–7%; size 20)	15	ISO size 20 Hedström files	15	ISO size 20 Hedström files	15
F2 file (finishing file no.2; taper 5.5–8%; size 25)	15	ISO size 25 Hedström files	15	ISO size 25 Hedström files	15
F3 file (finishing file no.3; taper 5–9%; size 30)	15	ISO size 30 Hedström files	15	ISO size 30 Hedström files	15
		S1, S2 files	15	ISO size 35 K-flex file	15
		F1, F2, F3 files	15	ISO size 40 K-flex file	14
				ISO size 45 K-flex file	13
				ISO size 50 K-flex file	12

instruction. In brief, D1, D2 and D3 were sequentially used in a crown-down manner to reach the pre-established WL; they were manipulated in a brushing action. The rotational speed was set at 500 rpm as recommended. If the rotary instruments did not advance in the canal prior to reaching the designated depth, stainless steel K files were used to establish a glide path before reintroducing the rotary instruments. Root canal refinement was accomplished with ProTaper Universal rotary shaping (S1 and S2) and finishing (F1, F2 and F3) instruments, which were used in a gentle brushing action at a speed of 300 rpm according to the manufacturers' instruction.

*Group B: Hedström files with further canal preparation using ProTaper Universal shaping and finishing instruments*

Removal of the root filling materials begun with the use of sizes 1–3 Gates Glidden drills in the coronal portion. With chloroform as a solvent, Hedström files (Dentsply Maillefer) sizes 30, 25 and 20 were used in a circumferential quarter-turn push-pull filing motion to remove the root fillings from the middle and apical portions until the original WL had been reached. Once the bulk of root filling had been removed, paper points in conjunction with chloroform were used to remove the GP/sealer remnants from the irregularities of the root canal system. Root canal refining was accomplished with ProTaper Universal rotary shaping (S1 and S2) and finishing (F1, F2 and F3) instruments, which were used as described above.

*Group C: Hedström files, with further canal preparation using K-flex files*

The method for root filling removal was the same as that in group B. Further root canal re-preparation was accomplished with K-flex files (Kerr) with apical enlargement to size 35 and step-back in 1 mm increments to size 50. The files were used with in-and-out movements in a circumferential manner.

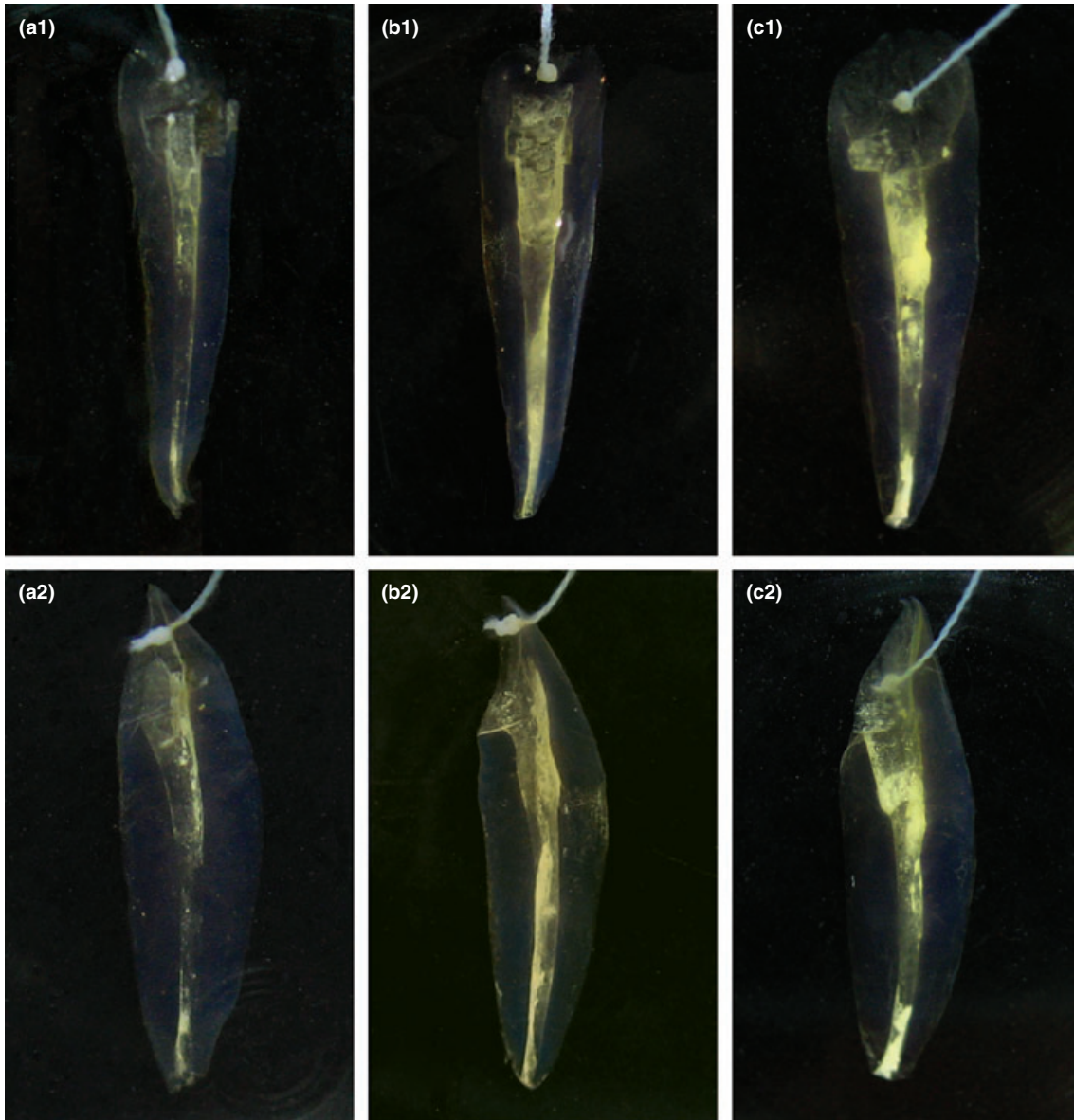
Upon withdrawal of each instrument, adherent debris was removed from the files and canals were irrigated with 5.25% NaOCl and 17% EDTA. Instruments were discarded after being used in five root canals. Retreatment was deemed complete when no debris of GP/sealer was visible on the surface of instruments and canal walls were smooth (Barrieshi-Nusair 2002, Schirrmeister et al. 2006b, Zmener et al. 2006).

## Evaluation

To reduce inter-operator variability, a single operator carried out all endodontic procedures. Evaluation of GP remnants was carried out by a second examiner who was blind to group assignment. The following parameters were evaluated.

*Remaining gutta-percha and sealer*

All specimens were rendered transparent according to the technique described by Schirrmeister et al. (2006b). The GP/sealer remnants on the canal walls were imaged on a black background in B-L and M-D directions using a stereomicroscope at 8× magnifica-



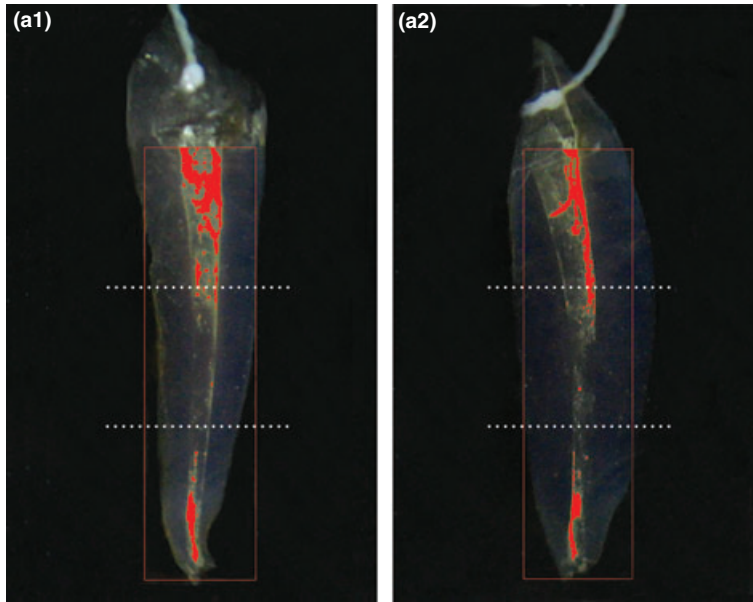
**Figure 1** Stereomicroscopy of transparent specimens in the three retreatment groups (original magnification 8 $\times$ ). The B-L (a1) and M-D (a2) views of a specimen in group A demonstrated a small amount of gutta-percha (GP)/sealer remnants in the coronal and apical portions of the root canal. The B-L (b1) and M-D (b2) views of a specimen in group B demonstrated a moderate amount of GP/sealer remnants in the middle and apical portions of the root canal. A specimen in group C displayed a mass of residual GP/sealer in the coronal and apical portion of the root canal in B-L (c1) and M-D (c2) views.

tion (Fig. 1). Each canal was divided into coronal, middle and apical thirds from the 'staging platform' to the terminus of the apical preparation. The area of GP/sealer remnants as well as the canal wall in each portion was measured in both directions using an image analyser software (Comef 4.0; OEG Messtechnik, Frankfurt, Germany) (Fig. 2). Area fraction of root

canal wall covered by GP/sealer remnants was calculated in percentage terms by dividing the area of GP/sealer remnants with the area of canal wall.

#### *Operating time*

The operating time which elapsed from initial GP removal with the first instrument until reaching the



**Figure 2** Schematic representation of the measurement of area covered by gutta-percha (GP)/sealer remnants. Here a1 and a2 correspond, respectively, to the B-L (a1) and M-D (a2) views of the specimen in group A in Fig. 1. The area covered by GP/sealer remnants was automatically identified by image analyser software and shown in red.

original WL was recorded as T1. The time required to achieve satisfactory GP removal after reaching the WL was recorded as T2. Total time for treatment was the sum of T1 and T2.

#### Procedural errors

Procedural errors including canal perforations, loss of WL, ledging and instrument separation were recorded. When instruments fractured, they were replaced.

#### Statistical analysis

The quantitative data were presented as mean  $\pm$  standard deviation. Analysis of variance (ANOVA) for repeated measures was adopted to analyse the differences in the percentages of GP/sealer remnants covered area amongst the three groups. One-way ANOVA was applied to compare the operating time amongst the three techniques. Bonferroni test was performed as the

*post hoc* multiple comparison method. The difference was considered as being of statistical significance at  $P < 0.05$ . The spss 13.0 software package was used for the statistical analysis.

#### Results

The ratios of B-L dimension to M-D dimension of canals ranged from 1 : 1 to 1.53 : 1. Therefore, no long oval canals were included in the present study according to the criteria proposed by Zmener *et al.* (2006).

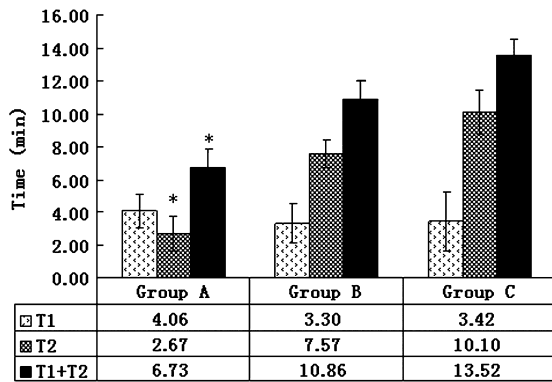
Remaining filling material was observed in all specimens; from direct observation this appeared to be mostly sealer. The area fraction of root canal wall covered by GP/sealer remnants is presented in Table 2. All techniques left 10–17% of the canal area covered by GP/sealer remnants. In the middle and apical portions of root canals, specimens in group A had a smaller percentage of GP/sealer area than those in groups B

**Table 2** Area fraction of root canal wall covered by gutta-percha/sealer remnants after retreatment in B-L and M-D directions

	<i>n</i>	Group A		Group B		Group C	
		B-L	M-D	B-L	M-D	B-L	M-D
Coronal 1/3	20	7.13 $\pm$ 2.07	7.21 $\pm$ 2.99	9.89 $\pm$ 2.75	8.77 $\pm$ 3.52	8.27 $\pm$ 3.93	10.39 $\pm$ 4.17
Middle 1/3	20	9.35 $\pm$ 3.19*	9.63 $\pm$ 3.26*	13.44 $\pm$ 4.87	11.96 $\pm$ 3.89	15.92 $\pm$ 3.27	14.87 $\pm$ 3.84
Apical 1/3	20	13.39 $\pm$ 4.44*	13.91 $\pm$ 4.25*	17.09 $\pm$ 5.07	17.23 $\pm$ 4.98	21.09 $\pm$ 7.57	22.09 $\pm$ 6.38
Total	20	10.12 $\pm$ 3.91*	10.25 $\pm$ 4.73*	12.42 $\pm$ 5.14	12.96 $\pm$ 5.07	17.28 $\pm$ 8.54	17.35 $\pm$ 8.77

\*Significant different against group C ( $P < 0.05$ ).

B-L, bucco-lingual; M-D, mesial-distal.



**Figure 3** Mean time (min) for retreatment. (T1, time for reaching the original WL; T2, time for gutta-percha removal; T1 + T2, total time for retreatment; \*Significant different against groups B and C,  $P < 0.05$ ).

and C. The difference between groups A and C was statistically significant ( $P < 0.05$ ). The same was true when the whole canal was taken into consideration.

The mean operating time is presented in Fig. 3. In terms of the time required to achieve satisfactory GP removal (T2), group A was significantly faster than the other two groups ( $P < 0.05$ ). Overall, GP removal with the ProTaper Universal technique in group A took significantly less time than groups B and C ( $P < 0.05$ ). Instrument fracture, canal perforations, loss of WL or ledging were not observed. One size D3 file in group A and two size 20 Hedström files in group C deformed.

## Discussion

Complete removal of pre-existing filling material from canals is a prerequisite for successful nonsurgical root canal retreatment (Schirrmeister *et al.* 2006c). This procedure can uncover residual necrotic tissues or bacteria that may be responsible for persistent periapical inflammation, and allow further cleaning and refilling of the root canal system (Stabholz & Friedman 1988, Schirrmeister *et al.* 2006d).

Remaining filling debris has been assessed by radiography (Ferreira *et al.* 2001, Schirrmeister *et al.* 2006d), splitting teeth longitudinally (Baratto Filho *et al.* 2002, Zmener *et al.* 2006) or making teeth transparent (Schirrmeister *et al.* 2006a,b,c,d). Amongst them, the transparent teeth method appears to be cost-effective and sensitive enough to identify small area of residual GP/sealer on the canal walls (Schirrmeister *et al.* 2006d). In the present study, teeth were made transparent after treatment to allow measurement of the area covered by root filling remnants.

Chloroform is more effective in dissolving GP compared with eucalyptol, halothane and xylol (Tamse *et al.* 1986, Kaplowitz 1990, Wilcox 1995). In the present study, canal wall cleanliness was less satisfactory in groups B and C, in which chloroform had been used. This result is consistent with previous studies that demonstrated the auxiliary use of chloroform in GP removal resulted in reduced cleanliness compared with hand instrumentation without chloroform (Wilcox 1989, 1993, Hulsmann & Stotz 1997). It is postulated that the softening effect of chloroform on GP results in inadvertent distribution of GP from the canal walls in the form of a film on the canal surface (Sae-Lim *et al.* 2000). The thin film of filling materials thus formed may reduce the action of intracanal antibacterial medicaments, and impair the adaptation of subsequent filling material on the canal walls (Wilcox & Juhlin 1994).

NiTi rotary instruments have been proposed for removing GP from root canals (Baratto Filho *et al.* 2002, Hulsmann & Bluhm 2004, Schirrmeister *et al.* 2006c). To date, there have been few studies investigating the behaviour of ProTaper Universal retreatment instruments in nonsurgical endodontic retreatment. In the present study, the ProTaper Universal rotary instruments left a smaller percentage of area covered by GP/sealer remnants than those treated with other techniques. The better performance of ProTaper Universal retreatment instruments may be attributable to their design. D1, D2 and D3 have three progressive tapers and lengths. These features may enable the retreatment instruments to cut not only GP but also the superficial layer of dentine during root filling removal. Moreover, the specific flute design and rotary motion of the ProTaper Universal retreatment instruments tend to pull GP into the file flutes and direct it towards the orifice. Furthermore, it is possible that the rotary movements of engine-driven files produce a certain degree of frictional heat which might plasticize GP. The plasticized GP would thus present less resistance and be easier to remove (Betti & Bramante 2001).

As has been shown in the literature, it was impossible to remove all traces of GP/sealer from root canals with any retreatment technique, regardless of single or combined action (Wilcox *et al.* 1987, Sae-Lim *et al.* 2000, Barrieshi-Nusair 2002). This was also demonstrated in the present study, as none of the specimens was free of GP/sealer remnant under stereomicroscopic examination. The majority of remnants on the canal walls appeared to be sealer, which is consistent with other studies (Wilcox *et al.* 1987, Barrieshi-Nusair

2002). Generally, sealer adheres well to the canal wall particularly when solvents are used (Wilcox 1989, Sae-Lim *et al.* 2000). Therefore, effective canal re-preparation is of great importance for thorough cleaning after GP removal.

Prior to the introduction of ProTaper Universal retreatment files, ProTaper rotary finishing files had been used for GP removal (Hulsmann & Bluhm 2004, Schirrmeister *et al.* 2006c). This technique yielded a high-fracture incidence of 22.7% (Schirrmeister *et al.* 2006c). Procedural errors including instrument fracture were not noted in the present study, demonstrating the safety of ProTaper Universal retreatment instruments in endodontic retreatment. As a general rule, NiTi rotary instruments should be used with great caution. When ProTaper Universal retreatment files are used to remove GP, slight apical pressure has to be exerted for file penetration. Files should be withdrawn frequently for the removal of the debris from instrument flutes before being reintroduced in the root canal system. If the rotary instruments fail to progress along the canal path, stainless steel hand files may be used to check the resistance and establish the glide path.

## Conclusions

All techniques left GP/sealer remnants on root canal walls. The ProTaper Universal rotary retreatment system removed GP more efficiently compared with other traditional techniques in maxillary anterior teeth.

## Acknowledgement

This study was supported by Key Clinical Program of the Ministry of Health, China.

## References

- Ayar LR, Love RM (2004) Shaping ability of ProFile and K3 rotary Ni-Ti instruments when used in a variable tip sequence in simulated curved root canals. *International Endodontic Journal* **37**, 593–601.
- Baratto Filho F, Ferreira EL, Fariniuk LF (2002) Efficiency of the 0.04 taper ProFile during the re-treatment of gutta-percha-filled root canals. *International Endodontic Journal* **35**, 651–4.
- Barrieshi-Nusair KM (2002) Gutta-percha retreatment: effectiveness of nickel-titanium rotary instruments versus stainless steel hand files. *Journal of Endodontics* **28**, 454–6.
- Betti LV, Bramante CM (2001) Quantec SC rotary instruments versus hand files for gutta-percha removal in root canal retreatment. *International Endodontic Journal* **34**, 514–9.
- Ferreira JJ, Rhodes JS, Pitt Ford TR (2001) The efficacy of gutta-percha removal using ProFiles. *International Endodontic Journal* **34**, 267–74.
- Friedman S, Stabholz A, Tamse A (1990) Endodontic retreatment-case selection and technique. Part 3: retreatment techniques. *Journal of Endodontics* **16**, 543–9.
- Guelzow A, Stamm O, Martus P, Kielbassa AM (2005) Comparative study of six rotary nickel-titanium system and hand instrumentation for root canal preparation. *International Endodontic Journal* **38**, 743–52.
- Hulsmann M, Bluhm V (2004) Efficacy, cleaning ability and safety of different rotary NiTi instruments in root canal retreatment. *International Endodontic Journal* **37**, 468–76.
- Hulsmann M, Stotz S (1997) Efficacy, cleaning ability and safety of different devices for gutta-percha removal in root canal retreatment. *International Endodontic Journal* **30**, 227–33.
- Imura N, Kato AS, Hata GI, Uemura M, Toda T, Weine F (2000) A comparison of the relative efficacies of four hand and rotary instrumentation techniques during endodontic retreatment. *International Endodontic Journal* **33**, 361–6.
- Iqbal MK, Maggiore F, Suh B, Edwards KR, Kang J, Kim S (2003) Comparison of apical transportation in four Ni-Ti rotary instrumentation techniques. *Journal of Endodontics* **29**, 587–91.
- Kaplowitz GJ (1990) Evaluation of gutta-percha solvents. *Journal of Endodontics* **16**, 539–40.
- Lewis R, Block R (1988) Management of endodontic failures. *Oral Surgery, Oral Medicine and Oral Pathology* **66**, 7111–21.
- Molander A, Reit C, Dahlen G, Kvist T (1998) Microbiological status of root-filled teeth with apical periodontitis. *International Endodontic Journal* **31**, 1–7.
- Nair PN, Sjogren U, Figdor D, Sundqvist G (1999) Persistent periapical radiolucencies of root-filled human teeth, failed endodontic treatments, and periapical scars. *Oral Surgery, Oral Medicine, Oral Pathology, Oral Radiology and Endodontics* **87**, 617–27.
- Nair PN, Sjogren U, Kahnberg KE, Krey G, Sundqvist G (1990) Intraradicular bacteria and fungi in root-filled, asymptomatic human teeth with therapy-resistant periapical lesions: a long-term light and electron microscopic follow-up study. *Journal of Endodontics* **16**, 580–8.
- Rangel S, Cremonese R, Bryant S, Dummer P (2005) Shaping ability of RaCe rotary nickel-titanium instruments in simulated root canals. *Journal of Endodontics* **31**, 460–3.
- Sae-Lim V, Rajamanickam I, Lim BK, Lee HL (2000) Effectiveness of ProFile.04 taper rotary instruments in endodontic retreatment. *Journal of Endodontics* **26**, 100–4.
- Schafer E, Erler M, Dammaschke T (2006a) Comparative study on the shaping ability and cleaning efficiency of rotary Mtwo instruments. Part 1. Shaping ability in simulated curved canals. *International Endodontic Journal* **39**, 196–202.
- Schafer E, Erler M, Dammaschke T (2006b) Comparative study on the shaping ability and cleaning efficiency of rotary Mtwo instruments. Part 2. Cleaning effectiveness and

- shaping ability in severely curved root canals of extracted teeth. *International Endodontic Journal* **39**, 203–12.
- Schafer E, Florek H (2003) Efficiency of rotary nickel-titanium K3 instruments compared with stainless steel hand K-Flexofile. Part 1. Shaping ability in simulated curved canals. *International Endodontic Journal* **36**, 199–207.
- Schafer E, Lohmann D (2002) Efficiency of rotary nickel-titanium FlexMaster instruments compared with stainless steel hand K-flexofile—Part 1. Shaping ability in simulated curved canals. *International Endodontic Journal* **35**, 505–13.
- Schafer E, Vlassis M (2004) Comparative investigation of two rotary nickel-titanium instruments: ProTaper versus Race. Part 1. Shaping ability in simulated curved canals. *International Endodontic Journal* **37**, 229–38.
- Schirrmeyer JF, Wrbas KT, Meyer KM, Altenburger MJ, Hellwig E (2006a) Efficacy of different rotary instruments for gutta-percha removal in root canal retreatment. *Journal of Endodontics* **32**, 469–72.
- Schirrmeyer JF, Meyer KM, Hermanns P, Altenburger MJ, Wrbas KT (2006b) Effectiveness of hand and rotary instrumentation for removing a new synthetic polymer-based root canal obturation material (Epiphany) during retreatment. *International Endodontic Journal* **39**, 150–6.
- Schirrmeyer JF, Wrbas KT, Schneider FH, Altenburger MJ, Hellwig E (2006c) Effectiveness of a hand file and three nickel-titanium rotary instruments for removing gutta-percha in curved root canals during retreatment. *Oral Surgery, Oral Medicine, Oral Pathology, Oral Radiology, and Endodontics* **101**, 542–7.
- Schirrmeyer JF, Hermanns P, Meyer KM, Goetz F, Hellwig E (2006d) Detectability of residual Epiphany and gutta-percha after root canal retreatment using a dental operating microscope and radiographs-an ex vivo study. *International Endodontic Journal* **39**, 558–65.
- Schneider SW (1971) A comparison of canal preparations in straight and curved root canals. *Oral Surgery, Oral Medicine, and Oral Pathology* **32**, 271–5.
- Sjogren U, Figdor D, Persson S, Sundqvist G (1997) Influence of infection at the time of root filling on the outcome of endodontic treatment of teeth with apical periodontitis. *International Endodontic Journal* **30**, 297–306.
- Siqueira JF, Jr (2001) Aetiology of root canal treatment failure: why well-treated teeth can fail. *International Endodontic Journal* **34**, 1–10.
- Stabholz A, Friedman S (1988) Endodontic retreatment-case selection and technique. Part 2. Treatment planning for retreatment. *Journal of Endodontics* **14**, 607–14.
- Tamse A, Unger U, Metzger Z, Rosenberg M (1986) Gutta-percha solvents – a comparative study. *Journal of Endodontics* **12**, 337–9.
- Walton R (1989) Cleaning and shaping. In: Walton R, Torabinejad M, eds. *Principles and Practice of Endodontics*, 1st edn. Philadelphia: W.B. Saunders & Company, pp. 195–213.
- Wilcox LR (1989) Endodontic retreatment. Ultrasonics and chloroform as the final step in reinstrumentation. *Journal of Endodontics* **15**, 125–8.
- Wilcox LR (1993) Thermafil retreatment with and without chloroform solvent. *Journal of Endodontics* **19**, 563–6.
- Wilcox LR (1995) Endodontic retreatment with halothane versus chloroform solvent. *Journal of Endodontics* **21**, 305–7.
- Wilcox LR, Juhlin JJ (1994) Endodontic retreatment of thermafil versus laterally condensed gutta-percha. *Journal of Endodontics* **20**, 115–7.
- Wilcox LR, Krell KV, Madison S, Rittman B (1987) Endodontic retreatment: evaluation of gutta-percha and sealer removal and canal reinstrumentation. *Journal of Endodontics* **13**, 453–7.
- Zmener O, Pameijer CH, Banegas G (2006) Retreatment efficacy of hand versus automated instrumentation in oval-shaped root canals: an ex vivo study. *International Endodontic Journal* **39**, 521–6.