

Revascularisation of the necrotic open apex

Author_ Dr Antonis Chaniotis, Greece

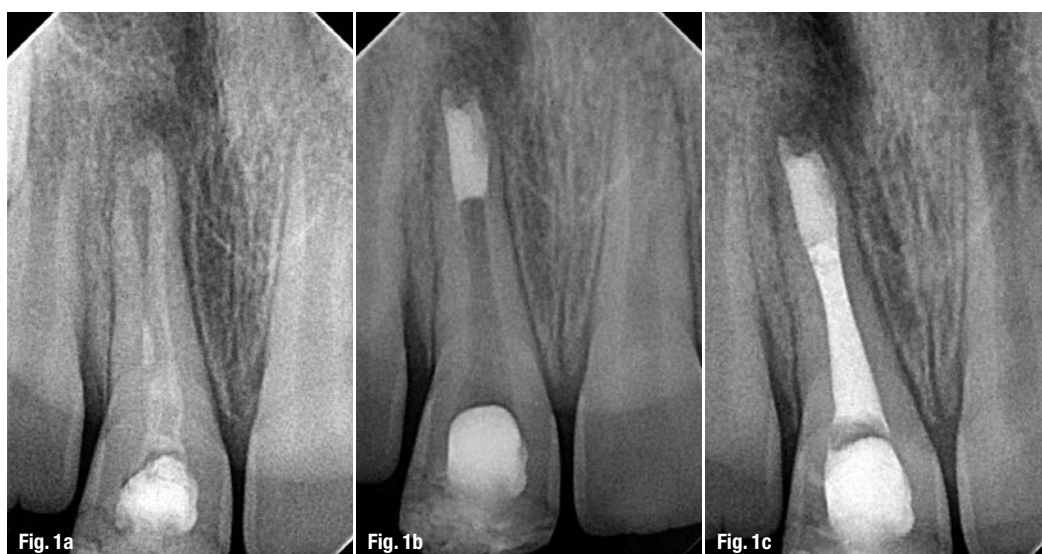

Fig. 1a Pre-op radiograph of tooth #11 with Ca(OH)₂ dressing from the referring doctor.

Fig. 1b Radiographic appearance of properly placed apical MTA plug.

Fig. 1c Post-treatment radiograph with gutta-percha backfilling.

Two years ago, I was struggling to learn how to perform a good apical MTA plug. I used all the existing MTA carriers and absorbable barriers that I could find on the Greek dental market. It took me a while, but I finally ended up performing some proper apical MTA plugs and with practice, I am now able to perform apical MTA plugs even without using absorbable barriers (Figs. 2a–c).

Figs. 2a & b Initial situation.

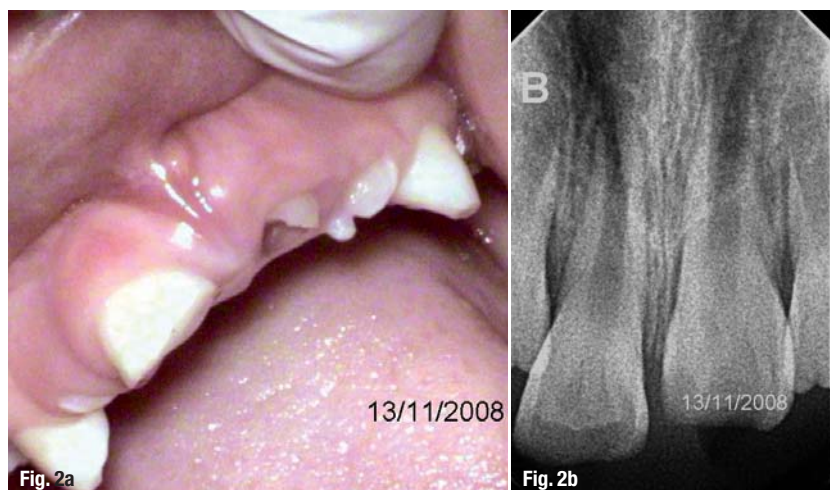


Fig. 2a

Fig. 2b

It was back then, that I started gathering information on revascularisation procedures of the necrotic open apex. A case report by Iwaya *et al.* published in a 2001 issue of *Dental Traumatology* was reproduced by Banchs and Trope in 2004, giving the work of Nygaard-Ostby *et al.* and Skoglund *et al.* from the seventies a whole new meaning. According to Dr Martin Trope, "If the canal is effectively disinfected, a scaffold into which new tissue can grow is provided, and the coronal access is effectively sealed, revascularisation should occur as in an avulsed immature tooth." I believe this is an excellent description of the philosophy behind the revascularisation procedure. Dr Trope's words gave me all the information that I needed for making the attempt myself.

Case report

On a rainy morning, the phone in my private practice rang. The referring doctor was very anxious to obtain an early appointment, as it concerned a trauma case of an eight-year-old child. I saw the little girl the same afternoon. Two days earlier, little Marlene had been hit by a car. Her right maxillary central incisor had suffered an enamel-dentine frac-

ture while her left maxillary central incisor had been displaced into the alveolar bone (intrusion; Figs. 2a & b). Thermal and electrical pulp testing was positive for the right maxillary central incisor. However, it was impossible to perform vitality tests on the intruded incisor.


The treatment plan aimed mainly at protecting the vital pulp tissue of the immature fractured tooth with bonded resin, while the intruded tooth was left for spontaneous repositioning. Instructions for a week long, soft food diet was given and an appointment was scheduled for the following month. Unfortunately, the little girl did not return to my practice until one year later. At that time, there were two sinus tracts associated with the traumatised central incisors, and both thermal and electrical vitality tests were negative for both incisors. Probing depths were within normal limits (Figs. 3a-c). The spontaneous repositioning of the left central maxillary incisor had succeeded, but the pulp tissue had become necrotic.

I then decided to attempt revascularisation of the necrotic immature apices. The treatment plan aimed mainly at the effective disinfection of the wide canals, followed by blood clot induction and MTA placement. Effective disinfection is one of the main issues in endodontics. Articles by Sato *et al.* and Hoshino *et al.* describe an effective disinfection procedure using a triple antibiotic paste. The effectiveness of a metronidazole, ciprofloxacin and minocycline mixture for the disinfection of the immature necrotic open apex was demonstrated by Windley *et al.* However, the minocycline component of the mixture stained the dentine excessively. Therefore, many researchers suggest either a bi-antibiotic paste regimen (without minocycline) or with cefaclor as a substitute.


Back then, I thought it was not safe to place antibiotics inside the wide-open canal of a nine-year-old child. Therefore, I sought to achieve effective disinfection by using only syringe irrigation of a 2% chlorhexidine digluconate solution. After administering infiltration anaesthesia, the incisors were isolated with Hygenic Wedjets (Coltène/Whaledent) and access was achieved. The wide canal was completely necrotic in the right central incisor. In the left central incisor, however, there appeared to be vital pulp tissue in the middle part of the wide-open canal. Both canals were irrigated with a 2% chlorhexidine digluconate solution. The thin dentinal walls were lightly brushed using a #110 Hedstrom file. The final rinse was accomplished using sterile water, and the canals were dried using sterile paper points.

A sterile #60 K-file was used for bleeding induction. Only in the left central maxillary incisor was a

Finally, an assistant that gives you the benefits.



It will make your practice more efficient.



The **Endoring® II** organizer enables the clinician to directly place, store, measure and clean endodontic hand and rotary instruments within the operating field. It reduces the risk of cross-contamination and minimizes the passing of sharps between dentist and staff. Using the Endoring II organizer helps make endodontic procedures safer, faster and reduces patient chair time. **Endoring II, hand-held endodontic assistant**, REF: ERK2-s (Premium Kit), ER2SK-s (Starter Kit), ER2-s (with metal ruler).

FEATURES & BENEFITS

- Endo Docking Station™**
Ideal for use with microscopes
- Laser-Etched Metal Ruler**
Precise 1/2mm markings on high-contrast detachable ruler
- Right/Left-Handed 30mm Scale**
Rapid calibration of instruments, paper points and gutta percha
- and much more...



Manufactured by Jordco, Inc. USA
www.jordco.com • TEL 800-752-2812 • FAX 503-531-3757

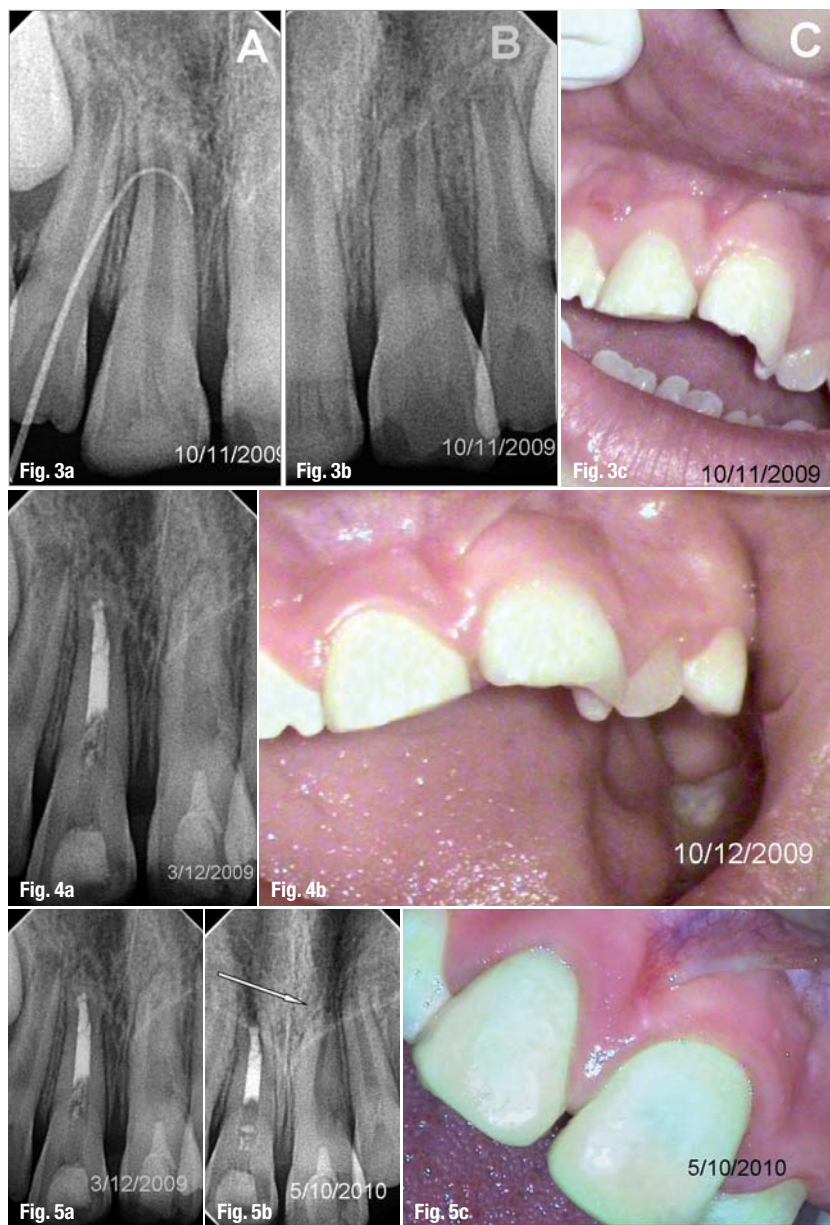
QUALITY DENTAL PRODUCTS MANUFACTURED IN THE U.S.A.

To order, please contact your dental supply dealer.
To find a dealer visit www.jordco.com or call 800-752-2812

NEW foam shape.

Jordco's new **e-Foam™** has been redesigned to securely lock into the Endoring assembly with a simple tug on the end. With three package options to fit your specific needs: combo, all blue and all yellow packs. **Jordco e-Foam**, ERF-s (combo pack); ERFB-s (all blue pack); ERFY-s (all yellow pack); 48 inserts per pack.





Figs. 3a–c_One year after the initial visit.
Figs. 4a & b_Post-treatment.
Fig. 5a_Post-treatment radiograph of tooth #21 after the revascularisation attempt.
Fig. 5b_One-year follow-up radiograph indicating successful revascularisation and dentin wall thickening.
Fig. 5c_Clinical image after the successful revascularisation procedure.

blood clot successfully produced to the level of the cemento–enamel junction, followed by an MTA seal in the cervical area and a bonded resin coronal restoration above it. In the other incisor, bleeding induction was unsuccessful and an apical MTA plug was placed. One week later, the sinus tracts had disappeared and the little girl was referred back to her dentist for appropriate restoration (Figs. 4a & b).

One year later, the patient returned for her scheduled follow-up examination. The radiographic image showed healing, root wall thickening and root lengthening of the left central maxillary incisor, indicating that the root canal had been revascularised with vital tissue (Figs. 5a–c). Unfortunately, the post space of the right central maxillary incisor had been left empty. The patient was referred back to her dentist for retreatment of the restoration.

_Conclusion

Revascularisation research has introduced me to a whole new area of great interest. I have learnt that it is important to distinguish between revascularisation and pulp regeneration.

"When looking for the 'bag of gold coins from the Emperor' we must separate the treatment of immature teeth from stem cell research. Both topics are valid topics for research but with very different objectives and pathways." These are the exact words of Prof Larz Spångberg in his editorial titled *The emperor's new cloth*, which was published in *Oral Surgery, Oral Medicine, Oral Pathology, Oral Radiology and Endodontology* 5/2009. Prof Spångberg goes on to say that "there is much indirect evidence that revascularization of necrotic pulp space content will result in fibrous connective tissue with cellular/acellular apposition on the root canal walls."

A couple of months later, a study on dogs by Wang *et al.* provided direct evidence on the importance of the blood clot as a scaffold for the stimulation of the revascularisation process. Their histological findings found bone ingrowth in the lumen of infected immature dog teeth and cementum on the inner root wall, which was the reason for the thickening of the root.

Further studies are probably underway to find new and more predictable scaffolds for tissue ingrowth. Until a definite predictable revascularisation protocol is proposed, the procedure described in this paper could be safely attempted in most cases. An apical MTA plug can always be performed, if no signs of regeneration are present after three months.

Editorial note: A list of references is available from the author.

_contact	roots
<p>Dr Antonis Chaniotis 140 El. Venizelou Av. Stoa Karantinou, 1st floor 176 76 Kallithea Athens Greece</p> <p>antch@otenet.gr www.endotreatment.gr</p>	