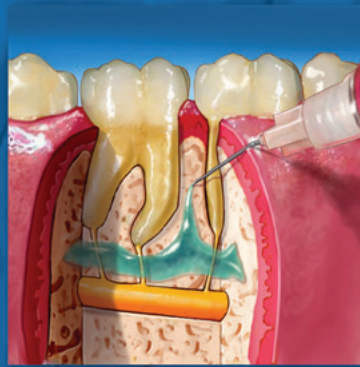

ENDODONTICS



*Colleagues for
Excellence*

Winter 2009

*Taking the Pain out of Restorative Dentistry
and Endodontics: Current Thoughts
and Treatment Options to Help Patients
Achieve Profound Anesthesia*



Published for the Dental Professional Community by the
American Association of Endodontists

This newsletter is intended to help resolve some of the misunderstandings surrounding local anesthesia and outline new methods and ideas for local anesthetic administration from a specialist's perspective. The goal is to help general practitioners achieve successful **pulpal** anesthesia. Discussion will focus on the inferior alveolar nerve block, as most clinical problems occur with this commonly used block.

Just like implants, endodontics and restorative dentistry, the subject of local anesthesia has enjoyed an explosion of knowledge. Proven techniques and evidence-based research offer a sound foundation for helping patients achieve profound pulpal anesthesia. A good deal of the new research on local anesthesia has come from endodontists, published in the highly respected *Journal of Endodontics*, and provides a welcome insight into the problems associated with local anesthesia. Endodontists are the resource of choice for practitioners seeking answers about providing profound local anesthesia because they deal with pulpal anesthesia and pain management on a daily basis.

Use of the Inferior Alveolar Nerve Block

Following are some common misunderstandings associated with the use of this block:

1. Lip numbness indicates pulpal anesthesia.

Not really. We were all taught that if the lip is numb, the teeth are numb. However, a number of studies (1-12) have found lip numbness means the lip is numb, but it does not guarantee pulpal anesthesia! It does mean the block injection was accurate enough to anesthetize the nerve fibers that supply the lip. Failure to achieve lip numbness occurs about 5% of the time with experienced clinicians (11,12).

2. Soft tissue "sticks" indicate pulpal anesthesia.

Unfortunately, like lip numbness, mucosal sticks with a sharp explorer can't be used to indicate pulpal anesthesia (1-3).

3. Lack of an accurate inferior alveolar nerve block injection causes anesthesia failure.

No. Studies using ultrasound (4) and radiographs (13,14) to accurately locate the inferior alveolar neurovascular bundle or mandibular foramen revealed accurate needle location did not guarantee successful pulpal anesthesia. One **important fact** you want to remember is that even though profound lip anesthesia is achieved, patients do **not** always achieve pulpal anesthesia, but it is NOT the fault of the clinician for giving an inaccurate injection!

4. Once lip numbness is obtained, pulpal anesthesia is not far behind.

Not always. The onset of lip numbness occurs usually within 5-9 minutes of injection (1-3) and pulpal anesthesia usually occurs by 15-16 minutes (1-3). However, pulpal anesthesia may be delayed. Slow onset of pulpal anesthesia (after 15 minutes) occurs approximately 19-27% of the time in mandibular teeth (6) and approximately 8% of patients have onset after 30 minutes (1-6,15).

5. Incorrect needle bevel orientation causes failure.

Not really. The orientation of the needle bevel (away or toward the mandibular ramus) for an inferior alveolar nerve block does not affect anesthetic success or failure (7).

6. Failure in molars and incisor teeth is the same.

No. Pulpal anesthesia failure occurs in approximately 17% of first molars, 11% of first premolars and 32% of lateral incisors (1-6). Again, 100% of these patients had profound lip numbness. Therefore, failure of pulpal anesthesia is higher in the incisor teeth than the molars and premolars.

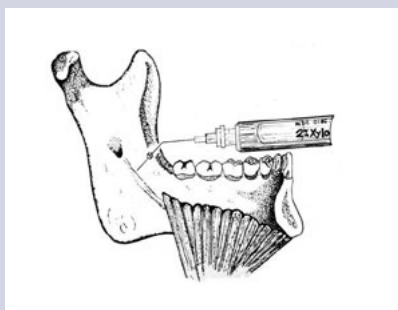


Fig. 1. Injection site for the mylohyoid nerve block.

7. Accessory innervation is the main reason for failure.

No. Judging from clinical and anatomical studies (16,17), the mylohyoid nerve is the accessory nerve most often cited as a cause for failure with mandibular anesthesia. When the inferior alveolar nerve block was compared to a combination injection of the inferior alveolar nerve block plus the mylohyoid nerve block (Figure 1), which was aided by the use of a peripheral nerve stimulator, the mylohyoid injection did not significantly enhance pulpal anesthesia of the inferior alveolar nerve block (Figure 2)(8). Another study employed the use of a lingual infiltration of the first molar after an inferior alveolar nerve block, but it did not significantly increase success in the mandible over the inferior alveolar nerve block alone (9).

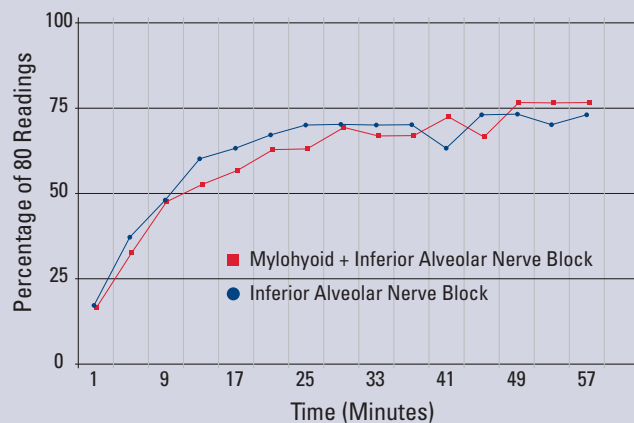


Fig. 2. Pulpal anesthesia [no patient response at the highest reading (an 80 reading) with an electric pulp tester] of the first mandibular molar comparing the combination mylohyoid infiltration plus the inferior alveolar nerve block to the inferior alveolar nerve block alone. No statistical differences were found.

Therefore, the mylohyoid nerve is not a major factor in failure with the inferior alveolar nerve block. Other nerves (buccal, lingual, cervical plexus) have been cited for failure; however, the magnitude of failure with the inferior alveolar nerve block is very difficult to explain by accessory innervation as a major contributor.

8. Cross innervation causes the majority of failures in mandibular incisor teeth.

Not really. Cross innervation does occur in mandibular central and lateral incisors (10,18). However, cross innervation is not the major reason for failure in incisor teeth—it is the failure of the inferior alveolar nerve block to adequately anesthetize these teeth. Administering bilateral inferior alveolar nerve blocks does not anesthetize the central and lateral incisors (10).

9. Giving another inferior alveolar nerve block will help the patient if they feel pain during operative procedures.

Not really. If the patient has **profound lip numbness and experiences pain upon treatment**, repeating the inferior alveolar nerve block **does not help!** Clinicians may think that another injection is helpful because the patient sometimes achieves pulpal anesthesia after the second injection. However, the patient may just be experiencing slow onset of pulpal anesthesia. That is, the second injection does not provide additional anesthesia—the first injection is just “catching up” (6).

10. Two cartridges are better than one.

No. Increasing the volume to two cartridges (Figure 3) of lidocaine (1,6,19) or increasing the epinephrine concentration from 1:100,000 to 1:50,000 (20, 21) will not provide better pulpal anesthesia.

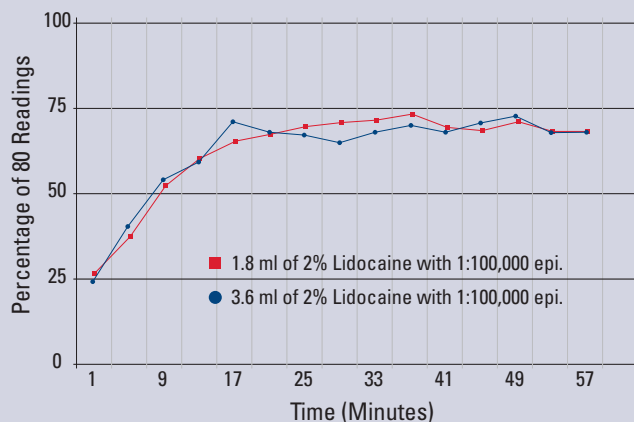


Fig. 3. Pulpal anesthesia [no patient response at the highest reading (an 80 reading) with an electric pulp tester] of the first mandibular molar comparing 3.6 mL and 1.8 mL of 2% lidocaine with 1:100,000 epinephrine. No statistical differences were found.

11. Plain 3% mepivacaine (Carbocaine) and 4% prilocaine (Citanest) solutions won't work for an inferior alveolar nerve block.

A cartridge of either mepivacaine or prilocaine will work the same as 2% lidocaine with epinephrine for pulpal anesthesia of at least 50-55 minutes (2). Clinically, this is an important finding because when medical conditions or drug therapies suggest caution in administering epinephrine-containing solutions, plain solutions can be used as an alternative for the inferior alveolar nerve block.

12. Articaine is better than lidocaine.

Not really. Repeated clinical trials have failed to demonstrate any statistical superiority of articaine over lidocaine for **nerve blocks** (12,22-24).

13. Articaine causes paresthesia and should not be used for nerve blocks.

Questionable. Two retrospective studies found a higher incidence of paresthesia with articaine and prilocaine (25,26). However, it was a clinically rare event (14 cases out of 11 million injections). Pogrel (27) evaluated patients referred with a diagnosis of damage to the inferior alveolar and/or lingual nerve, which could only have resulted from an inferior alveolar nerve block. He found 35% were caused by a lidocaine formulation and 30% were caused by an articaine formulation. He concluded there was not a disproportionate nerve involvement from articaine.

Why Don't Patients Achieve Pulpal Anesthesia With the Inferior Alveolar Nerve Block?

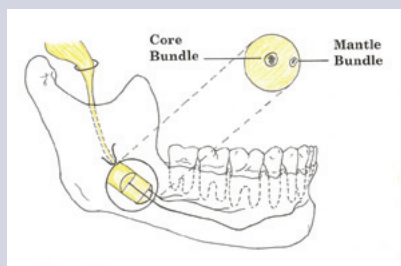


Fig. 4. Central Core Theory. The axons in the mantle bundle supply the molar teeth and those in the core bundle supply the incisor teeth. The local anesthetic solution diffuses from the mantle to the core. (Modified from DeJong RH: *Local Anesthetics*, St. Louis, 1994, Mosby).

The central core theory may be our best explanation (28,29). It states nerves on the outside of the nerve bundle supply molar teeth, and nerves on the inside supply incisor teeth (Figure 4). The anesthetic solution may not diffuse into the nerve trunk to reach all nerves and produce an adequate nerve block. The theory may explain the higher failure rates in incisor teeth with the inferior alveolar nerve block (1-6).

Proven Methods and Ideas to Help With Pulpal Anesthesia in Restorative Dentistry

Evaluate Pulpal Anesthesia Before Starting Treatment

Clinically, following lip numbness, application of a cold refrigerant (Figure 5) or the electric pulp tester can be used to test the tooth under treatment for pulpal anesthesia prior to beginning a clinical procedure (30-32). A cold refrigerant is easier to use than an electric pulp tester. To test the tooth, simply pick up a large cotton pellet with cotton tweezers, spray the pellet with the cold refrigerant and place it on the tooth. If



Fig. 5. A cold refrigerant can be used to test for pulpal anesthesia before the start of a clinical procedure.

the patient responds, we have to consider using supplemental injections to achieve profound pulpal anesthesia. Therefore, following an inferior alveolar nerve block and achieving lip numbness, we can now determine if the patient is numb **before** starting our treatment. Note: If the patient is experiencing **irreversible pulpitis**, no patient response to cold testing may not always indicate pulpal anesthesia (32).

Patients who have had previous difficulty with achieving anesthesia may experience more failures.

Patients who report a history of previous difficulty with anesthesia are more likely to experience unsuccessful anesthesia (33). A good clinical practice is to **ask** the patient if they have had previous difficulty achieving clinical anesthesia. If they have had these experiences, supplemental injections should be considered.

A slow inferior alveolar nerve block injection (60 seconds) results in a higher success rate of pulpal anesthesia than a rapid injection (15 seconds).

Yes, this is true (34). There is also less pain with the slow injection (34).

Use a buccal infiltration of articaine after an inferior alveolar nerve block in mandibular first molars to increase success.

A recent study (35) found giving a buccal infiltration of a cartridge of 4% articaine with 1:100,000 epinephrine after an inferior alveolar nerve block significantly increased success (88%) when compared to a lidocaine formulation (71% success). The buccal infiltration of articaine should be very helpful clinically! Note: In patients with **irreversible pulpitis**, the supplemental buccal infiltration of articaine is only 58% successful (36).

Use an intraosseous injection after an inferior alveolar nerve block to increase success.

The intraosseous injection delivers a local anesthetic solution directly into the cancellous bone adjacent to the tooth to be anesthetized (Figure 6). The addition of the intraosseous injection after an inferior alveolar nerve block, in the first molar, will provide a quick onset and a high incidence of pulpal anesthesia (approximately 90%) for 60 minutes (Figure 7)(37-39). Clinically, the supplemental intraosseous injection works very well.

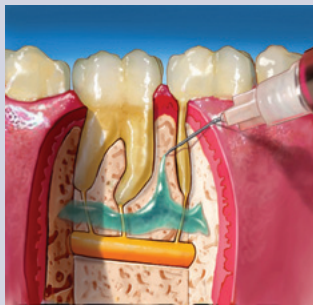

Fig. 6. The intraosseous injection delivers a local anesthetic solution directly into the cancellous bone adjacent to the tooth to be anesthetized.

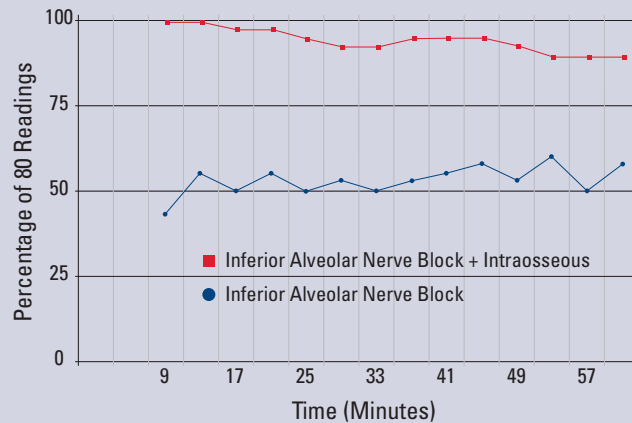


Fig. 7. Pulpal anesthesia [no patient response at the highest reading (an 80 reading) with an electric pulp tester] of the first mandibular molar comparing the combination intraosseous injection of 2% lidocaine with 1:100,000 epinephrine plus the inferior alveolar nerve block to the inferior alveolar nerve block alone. The combination technique was statistically better for all of the postinjection times.

Use an intraligamentary (PDL) injection after an inferior alveolar nerve block in posterior teeth to increase success.

The intraosseous injection is more successful than the intraligamentary injection (37,38,40) due to the greater amount of anesthetic solution delivered with the intraosseous injection. However, the intraligamentary injection may be helpful if the clinician is not familiar with the intraosseous injection.

Success With the Inferior Alveolar Nerve Block in Patients With Irreversible Pulpitis

Clinical studies in endodontics (12,32,41-44) in patients with irreversible pulpitis have found success (mild or no pain upon endodontic access or initial instrumentation) with the inferior alveolar nerve block alone between 19% and 56% of the time. Therefore, these studies would indicate that anesthesia is often difficult to achieve in irreversible pulpitis with only the inferior alveolar nerve block.

Why Don't Patients With Irreversible Pulpitis Achieve Pulpal Anesthesia?

Endodontic patients who are in pain and have pulpal pathosis have additional anesthetic problems. There are a number of explanations for failure:

1. The inferior alveolar nerve block does not always provide profound pulpal anesthesia (1-12).
2. There is a theory that the lowered pH of inflamed tissue reduces the amount of the base form of anesthetic to penetrate the nerve membrane. Consequently, there is less of the ionized form within the nerve to achieve anesthesia. However, this explanation of local influences on the anesthetic solution does not explain the mandibular molar with pulpitis, which is not readily blocked by an inferior alveolar injection administered at some distance from the area of inflammation. Therefore, it is difficult to correlate local pH changes with failure of the inferior alveolar nerve block.
3. Nerves arising from inflamed tissue have altered resting potentials and decreased excitability thresholds (45,46). Therefore, local anesthetic agents do not prevent impulse transmission due to these lowered excitability thresholds.
4. Tetrodotoxin-resistant (TTXr) class of sodium channels that have been shown to be resistant to the action of local anesthetics (47). A related factor is the increased expression of sodium channels in pulps diagnosed with irreversible pulpitis (48).
5. Finally, patients in **pain** are often apprehensive, which lowers their pain threshold.

Proven Methods and Ideas to Help With Pulpal Anesthesia in Endodontics: Supplemental Injections

Use of intraosseous anesthesia after the inferior alveolar nerve block.

Using the Stabident and X-tip intraosseous systems, success rates (none or mild pain upon endodontic access) of 86% to 91% have been reported (32,41,43, 44,49). Onset is immediate and duration is very good for the endodontic treatment appointment. Supplemental intraosseous injections work very well clinically.

Use of intraligamentary anesthesia after the inferior alveolar nerve block.

A supplemental intraligamentary injection is about 75% successful. Re-injection will increase success to approximately 95% (42,50). However, duration is fairly short when compared to the intraosseous injection.

Use of intrapulpal anesthesia after the inferior alveolar nerve block.

In approximately 5-10% of mandibular posterior teeth with irreversible pulpitis, supplemental injections, even when repeated, do not produce profound anesthesia; pain persists when the pulp is entered. This is an indication for an intrapulpal injection. The advantage of the intrapulpal injection is that it works well if given under back-pressure (51,52). Onset will be immediate and no special syringes or needles are required. The disadvantage is that the injection is painful.

Summary

The American Association of Endodontists hopes this issue of *ENDODONTICS: Colleagues for Excellence* resolved some of the misunderstandings concerning the inferior alveolar nerve block and provided some good ideas and methods to achieve profound pulpal anesthesia for your patients.

References

1. Vreeland D, Reader A, Beck M, Meyers W, Weaver J. An evaluation of volumes and concentrations of lidocaine in human inferior alveolar nerve block. *J Endod* 1989;15:6-12.
2. McLean C, Reader A, Beck M, Meyers WJ. An evaluation of 4% prilocaine and 3% mepivacaine compared to 2% lidocaine (1:100,000 epinephrine) for inferior alveolar nerve block. *J Endod* 1993;19:146-50.
3. Hinkley S, Reader A, Beck M, Meyers W. An evaluation of 4% prilocaine with 1:200,000 epinephrine and 2% mepivacaine with levonordefrin compared to 2% lidocaine with 1:100,000 epinephrine for inferior alveolar nerve block. *Anesth Prog* 1991;38:84-89.
4. Hannan L, Reader A, Nist R, Beck M, Meyers WJ. The use of ultrasound for guiding needle placement for inferior alveolar nerve blocks. *Oral Surg Oral Med Oral Pathol Oral Radiol Endod* 1999;87:658-65.
5. Fernandez C, Reader A, Beck M, Nusstein J. A prospective, randomized, double-blind comparison of bupivacaine and lidocaine for inferior alveolar nerve blocks. *J Endod* 2005;31:499-503.
6. Nusstein J, Reader A, Beck M. Anesthetic efficacy of different volumes of lidocaine with epinephrine for inferior alveolar nerve blocks. *Gen Dent* 2002;50:372-5.
7. Steinkruger G, Nusstein J, Reader A, Beck M, Weaver J. The significance of needle bevel orientation in achieving a successful inferior alveolar nerve block. *J Am Dent Assoc* 2006;137:1685-91.

8. Clark S, Reader A, Beck M, Meyers WJ. Anesthetic efficacy of the mylohyoid nerve block and combination inferior alveolar nerve block/mylohyoid nerve block. *Oral Surg Oral Med Oral Pathol Oral Radiol Endod* 1999;87:557-63.
9. Foster W, Drum M, Reader A, Beck M. Anesthetic efficacy of buccal and lingual infiltrations of lidocaine following an inferior alveolar nerve block in mandibular posterior teeth. *Anesth Prog* 2007;54:163-9.
10. Yonchak T, Reader A, Beck M, Meyers WJ. Anesthetic efficacy of unilateral and bilateral inferior alveolar nerve blocks to determine cross innervation in anterior teeth. *Oral Surg Oral Med Oral Pathol Oral Radiol Endod* 2001;92:132-5.
11. Mikesell P, Nusstein J, Reader A, Beck M, Weaver J. A comparison of articaine and lidocaine for inferior alveolar nerve blocks. *J Endod* 2005;31:265-70.
12. Claffey E, Reader A, Nusstein J, Beck M, Weaver J. Anesthetic efficacy of articaine for inferior alveolar nerve blocks in patients with irreversible pulpitis. *J Endod* 2004;30:568-71.
13. Berns JM, Sadove MS. Mandibular block injection: a method of study using an injected radiopaque material. *J Am Dent Assoc* 1962;65:736-745.
14. Galbreath JC. Tracing the course of the mandibular block injection. *Oral Surg Oral Med Oral Pathol* 1970;30:571-82.
15. Ågren E, Danielsson K. Conduction block analgesia in the mandible. *Swed Dent J* 1981;5:81-89.
16. Frommer J, Mele FA, Monroe CW. The possible role of the mylohyoid nerve in mandibular posterior tooth sensation. *J Am Dent Assoc* 1972;85:113-117.
17. Wilson S, Johns P, Fuller PM. The inferior alveolar and mylohyoid nerves: an anatomic study and relationship to local anesthesia of the anterior mandibular teeth. *J Am Dent Assoc* 1984;108:350-352.
18. Rood JP. The nerve supply of the mandibular incisor region. *Brit Dent J* 1977;143:227-30.
19. Yared GM, Dagher FB. Evaluation of lidocaine in human inferior alveolar nerve block. *J Endod* 1997;23:575-8.
20. Wali M, reader A, Beck M, Meyers W. Anesthetic efficacy of lidocaine and epinephrine in human inferior alveolar nerve blocks. *J Endod* 1988;14:193 (abstract).
21. Dagher BF, Yared GM, Machtou P. An evaluation of 2% lidocaine with different concentrations of epinephrine for inferior alveolar nerve blocks. *J Endod* 1997;23:178-80.
22. Malamed, S.F., Gagnon, S., Leblanc, D. Efficacy of articaine: a new amide local anesthetic. *J Am Dent Assoc* 2000;131:635-42.
23. Tofoli GR, Ramacciato JC, de Oliveira PC, Volpato MC, Groppo FC, Ranali J. Comparison of the effectiveness of 4% articaine associated with 1:100,000 or 1:200,000 epinephrine in inferior alveolar nerve block. *Anesth Prog* 2003;50:164-8.
24. Moore PA, Boynes SG, Hersh EV, DeRossi SS, Sollecito TP, Goodson JM, Leonel JS, Floros C, Peterson C, Hutcheson M. Dental anesthesia using 4% articaine 1:200,000 epinephrine: Two clinical trials. *J Am Dent Assoc* 2006;137:1572-81.
25. Haas DA, Lennon D. A 21 year retrospective study of reports of paresthesia following local anesthetic administration. *J Can Dent Assoc* 1995;61:319-20.
26. Miller P, Lennon D. Incidence of local anesthetic-induced neuropathies in Ontario from 1994-1998. *J Dent Res* 2000;Abstract (3869):627.
27. Pogrel MA. Permanent nerve damage from inferior alveolar nerve blocks – an update including articaine. *Calif Dent J* 2007;35:217-3.
28. DeJong RH. *Local Anesthetics* C.V. Mosby, St. Louis, MO, 1994, p 110,111.
29. Strichartz G. Molecular mechanisms of nerve block by local anesthetics, *Anesthesiology* 1976;45:421-44.
30. Dreven L, Reader A, Beck M, Meyers W, Weaver J. An evaluation of the electric pulp tester as a measure of analgesia in human vital teeth. *J Endod* 1987;13:233-8.
31. Certosimo A, Archer R. A clinical evaluation of the electric pulp tester as an indicator of local anesthesia. *Oper Dent* 1996;21:25-30.
32. Nusstein J, Reader A, Nist R, Beck M, Meyers WJ. Anesthetic efficacy of the supplemental intraosseous injection of 2% lidocaine with 1:100,000 epinephrine in irreversible pulpitis. *J Endod* 1998;24:487-91.
33. Kaufman E, Weinstein P, Milgrom P. Difficulties in achieving local anesthesia, *J Am Dent Assoc* 1984;108:205-8.
34. Kanaa MD, Meechan JG, Corbett IP, Whitworth JM. Speed of injection influences efficacy of inferior alveolar nerve blocks: A double-blind randomized controlled trial in volunteers. *J Endod* 2006;32:919-23.
35. Haase A, Reader A, Nusstein J, Beck M, Drum M. Comparing anesthetic efficacy of articaine versus lidocaine as a supplemental buccal infiltration of the mandibular first molar after an inferior alveolar nerve block. *J Am Dent Assoc* 2008;139:1228-35.
36. Matthews R, Drum M, Reader A, Nusstein J, Beck M. Articaine for supplemental, buccal mandibular infiltration anesthesia in patients with irreversible pulpitis. *J Endod* 2009; in press.
37. Dunbar D, Reader A, Nist R, Beck M, Meyers, W. Anesthetic efficacy of the intraosseous injection after an inferior alveolar nerve block. *J Endod* 1996;22:481-6.
38. Guglielmo A, Reader A, Nist R, Beck M, Weaver J. Anesthetic efficacy and heart rate effects of the supplemental intraosseous injection of 2% mepivacaine with 1:20,000 levonordefrin. *Oral Surg Oral Med Oral Pathol Oral Radiol Endod* 1999;87:284-93.
39. Stabile P, Reader A, Gallatin E, Beck M, Weaver J. Anesthetic efficacy and heart rate effects of the intraosseous injection of 1.5% etidocaine (1:200,000 epinephrine) after an inferior alveolar nerve block. *Oral Surg Oral Med Oral Pathol Oral Radiol Endod* 2000;89:407-11.
40. Childers M, Reader A, Nist R, Beck M, Meyers W. Anesthetic efficacy of the periodontal ligament injection after an inferior alveolar nerve block. *J Endod* 1996;22:317-20.
41. Reisman D, Reader A, Nist R, Beck M, Weaver J. Anesthetic efficacy of the supplemental intraosseous injection of 3% mepivacaine in irreversible pulpitis. *Oral Surg Oral Med Oral Pathol Oral Radiol Endod* 1997;84:676-82.

42. Cohen HP, Cha BY, Spangberg LSW. Endodontic anesthesia in mandibular molars: a clinical study. *J Endod* 1993;19:370-3.
43. Nusstein J, Kennedy S, Reader A, Beck M, Weaver J. Anesthetic efficacy of the supplemental X-tip intraosseous injection in patients with irreversible pulpitis. *J Endod* 2003;29:724-8.
44. Bigby J, Reader A, Nusstein J, Beck M, Weaver J. Articaine for supplemental intraosseous anesthesia in patients with irreversible pulpitis. *J Endod* 2006;32:1044-7.
45. Wallace J, Michanowicz A, Mundell R, Wilson E. A pilot study of the clinical problem of regionally anesthetizing the pulp of an acutely inflamed mandibular molar. *Oral Surg Oral Med Oral Pathol* 1985;59:517-21.
46. Byers M, Taylor P, Khayat B, Kimberly C. Effects of injury and inflammation on pulpal and periapical nerves. *J Endod* 1990;16:78-84.
47. Roy M, Nakanishi T. Differential properties of tetrodotoxin-sensitive and tetrodotoxin-resistant sodium channels in rat dorsal root ganglion neurons. *J Neurosci* 1992;12:2104-11.
48. Sorenson H, Skidmore L, Rzasar R, Kleier S, Levinson S, Hendry M. Comparison of pulpal sodium channel density in normal teeth to diseased teeth with severe spontaneous pain. *J Endod* 2004;30:287 (abstract).
49. Parente, SA, Anderson RW, Herman WW, Kimbrough WF, Weller RN. Anesthetic efficacy of the supplemental intraosseous injection for teeth with irreversible pulpitis. *J Endod* 1998;24:826-8.
50. Walton R, Abbott B. Periodontal ligament injection: a clinical evaluation. *J Am Dent Assoc* 1981;103:571-5.
51. Birchfield J, Rosenberg P. Role of the anesthetic solution in intrapulpal anesthesia. *J Endod* 1975;1:26-7.
52. VanGheluwe J, Walton R. Intrapulpal injection—factors related to effectiveness. *Oral Surg Oral Med Oral Pathol Oral Radiol Endod* 1997;19:38-40.

AAE COLLEAGUES ONLINE

Exclusive Bonus Materials

This issue of the *ENDODONTICS: Colleagues for Excellence* newsletter is available online at www.aae.org/colleagues with the following **exclusive bonus materials** prepared by the author:

- A. Important Clinical Factors Related to Local Anesthesia
- B. Alternate Anesthetic Solutions for the Inferior Alveolar Nerve Block
- C. Alternate Injection Locations
- D. Studies Evaluating Mechanisms of Failure With the Inferior Alveolar Nerve Block
- E. Supplemental Injections
- F. Intraosseous Anesthesia
- G. Intrapulpal Injection
- H. Bonus Material References
- I. "Ask the Author" Discussion Board for all of your questions and comments

This issue, as well as **all back issues** of this newsletter, are available for your ongoing reference.

The AAE wishes to thank Dr. Al Reader for authoring this issue of the newsletter, as well as the following article reviewers: Drs. James A. Abbott, Louis E. Rossman, Clara Spatafore and Susan L. Wolcott.

Do you have questions for the author? Visit the Dental Professionals section of the AAE Web site at www.aae.org/colleagues and click on the link for this issue of *ENDODONTICS: Colleagues for Excellence*. Questions and comments for the author can be posted to a special discussion board dedicated to this topic.

The information in this newsletter is designed to aid dentists. Practitioners must use their best professional judgment, taking into account the needs of each individual patient when making diagnosis/treatment plans. The AAE neither expressly nor implicitly warrants against any negative results associated with the application of this information. If you would like more information, consult your endodontic colleague or contact the AAE.

Did you enjoy this issue of *ENDODONTICS*? Are there topics you would like *ENDODONTICS* to cover in the future? We want to hear from you! Send your comments and questions to the American Association of Endodontists at the address below.

Endodontists
the root canal specialists

American Association of Endodontists
211 E. Chicago Ave., Suite 1100
Chicago, IL 60611-2691
info@aae.org • www.aae.org