

# Root and canal morphology of permanent mandibular molars in a Sudanese population

H. A. Ahmed, N. H. Abu-bakr, N. A. Yahia & Y. E. Ibrahim

Conservative Dentistry Division, Department of Oral Rehabilitation, Faculty of Dentistry, University of Khartoum, Khartoum, Sudan

## Abstract

**Ahmed HA, Abu-bakr NH, Yahia NA, Ibrahim YE.**

Root and canal morphology of permanent mandibular molars in a Sudanese population. *International Endodontic Journal*, 40, 766–771, 2007.

**Aim** To investigate variations in the root canal systems of first and second permanent mandibular molar teeth in a Sudanese population using a clearing technique.

**Methodology** Two hundred extracted first and second permanent mandibular molars from three cities in the state of Khartoum were studied. Access cavities were prepared and pulp tissue was removed by immersion in 5% sodium hypochlorite under ultrasonication; Indian ink was then injected into the root canal systems assisted by a vacuum applied apically. The teeth were rendered clear by demineralization and immersion in methyl salicylate before evaluation. The following observations were made (i) number of

roots and their morphology; (ii) number of root canals per tooth; (iii) number of root canals per root and (iv) root canal configuration.

**Results** Overall 59% of mandibular first molars had four canals with 3% having a third distolingual root. Seventy-eight per cent of second mandibular molars had two separate flat roots, whilst 10% were C-shaped. The most common canal system configurations were type IV (73%) and type II (14%). Inter-canal communications were more common in the mesial roots. The prevalence of inter-canal communications was 65% in first molars and 49% in second molars.

**Conclusions** In this sample of Sudanese teeth, 59% of the mandibular first permanent molars had four root canals whilst 10% of the mandibular second molars had C-shaped roots/canals.

**Keywords:** C-shape canal, canal morphology, clearing technique, mandibular molars.

Received 25 June 2006; accepted 9 March 2007

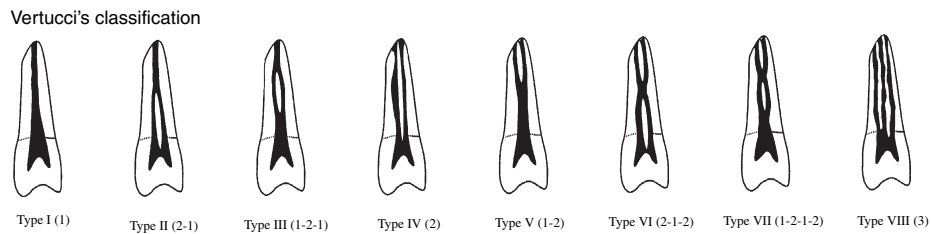
## Introduction

The study of root and canal anatomy has endodontic significance (Vertucci 1984). Moreover, the morphology of pulp systems varies greatly in different races and in different individuals within the same race. It is important to be familiar with variations in tooth anatomy and characteristic features in various racial groups as this knowledge can aid location, negotiation and management of canals during root canal treatment. A number of studies have shown

trends in the shape and number of canals amongst different races (Somogyi-Csimazia & Simmons 1971, Curzon 1974, Reichart & Metah 1981, Walker 1988a, Weine *et al.* 1988, Weine 1998, Sperber & Moreau 1998). Textbooks of endodontics state that C-shaped canals in mandibular second molars are common (Walton & Torabinejad 1996). There is a significant ethnic variation in the incidence of C-shaped molars, that ranges between 10% and 32.7% (Kotoku 1985, Yang *et al.* 1988, Gaby *et al.* 1999, Al-Fouzan 2002, Gulabivala *et al.* 2002, Seo & Park 2004).

Many investigations have examined the configurations of root canal system using techniques, such as radiographs, decalcification, sectioning, replication and computerized-aided techniques (Mayo *et al.* 1986, Baurmann 1994, Blaskovic-Subat *et al.* 1995, Omer

Correspondence: Dr Neamat Hassan Abu-bakr, Head of Conservative Dentistry Division, Department of Oral Rehabilitation, Faculty of Dentistry, University of Khartoum, PO Box 102, Khartoum 11111, Sudan (Tel.: +249912297332; fax: +249183780088; e-mail: neamat@yahoo.com).



**Figure 1** The Vertucci's classification.

*et al.* 2004). The technique of clearing teeth has considerable value in studying the anatomy of the root canal system because unlike radiographic images, it provides a three-dimensional view of the pulp cavity in relation to the exterior of the teeth and allows a comprehensive examination of the pulp chamber and root canal system (Vertucci 1978, Saunders & Saunders 1992).

No data are available on the incidence of canal configurations in the Sudanese population. The purpose of this study was to evaluate root and canal morphology of permanent mandibular molar teeth in a Sudanese population.

## Material and methods

Two hundred extracted mandibular molar teeth were collected from various dental hospitals and departments in Khartoum. The gender of the patients was unknown but the age range was 15–45 years. The teeth included 100 first molars and 100 second molars based on crown morphology. All attached soft tissue and calculus were removed using an ultrasonic scaler and the teeth were soaked in 5% sodium hypochlorite. Access cavities were prepared and the coronal pulp tissue was removed; the teeth were then immersed in 3% sodium hypochlorite overnight before placement in an ultrasonic bath. The teeth were then rinsed under running tap water for 2 h and dried overnight. An endodontic irrigating syringe with gauge 27 needle (Sherwood Medical Company, St Louis, MO, USA) was used to inject Indian ink (Calder Colours Ltd; Ashby-de-la-Zouch, Leicester, UK) into the root canal systems. Ink penetration was assisted by a vacuum applied apically. The teeth were dried by an oil-free air supply and immersed in 10% nitric acid (MJ Patterson, Dunstable, UK) to decalcify for 5–14 days. The acid solution was changed on a daily basis. The teeth were washed under running tap water, dried and dehydrated using

ascending concentrations of ethanol (70%, 95% and 100%) for 3 days. Finally, the teeth were rendered transparent by immersion in methyl salicylate (Merck Ltd, Poole, UK) for 2 days. The cleared teeth were examined under a dissecting microscope; root canal morphology was examined and compared with the classification of Vertucci (1984) (Fig. 1). The following observations were made: (i) morphology and number of roots; (ii) number of root canals per root and tooth and (iii) root canal morphology (lateral canals, inter-canal communications).

The data were analysed using the Statistical Package for the Social Sciences (SPSS) at confidence level of 95% and significant level of 5%. *P*-value  $\leq 0.05$  was considered as significant.

## Results

The results of the observations were as follows:

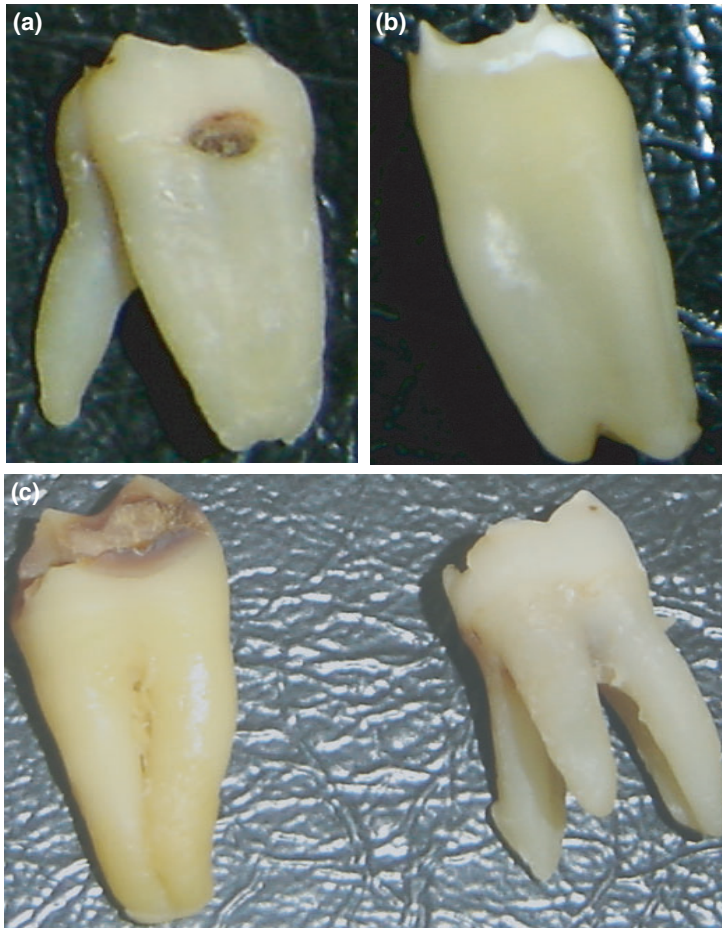
### Morphology and number of roots

Evaluation of the number of roots and their morphology revealed that 3% of mandibular first molars were three-rooted with the extra distal root on the lingual aspect (Fig. 2a,c). Twenty-six per cent had two separate roots, the mesial being flat and the distal conical in shape; only 3% had single conical shaped roots (Table 1, Fig. 2b).

Seventy-eight per cent of second molar teeth had two separate flat roots, whilst 10% were C-shaped (Fig. 3) and the rest (8%) either had two fused roots or a single conical root (4%).

### Number of root canals per root and tooth

The data for number and type of canal system are shown in Tables 1 and 2. Both mandibular molars demonstrated a wide variation of canal configurations. Most of the mesial roots of the first mandibular molars



**Figure 2** Clinical photographs showing variations in number of root and morphology in first permanent mandibular molar. (a) The extra distal root, (b) flat mesial root and (c) the three roots of the three rooted tooth.

**Table 1** Classification of Sudanese permanent mandibular molars by root number and morphology

Root shape and no.	First molar (%)	Second molar (%)
Three roots: all separate	3	0
Two roots: separate both M and D both flat	68	78
Two separate root M flat and D conical	26	0
Two roots: fused	0	8
One root: conical	3	4
One root: C-shaped	0	10

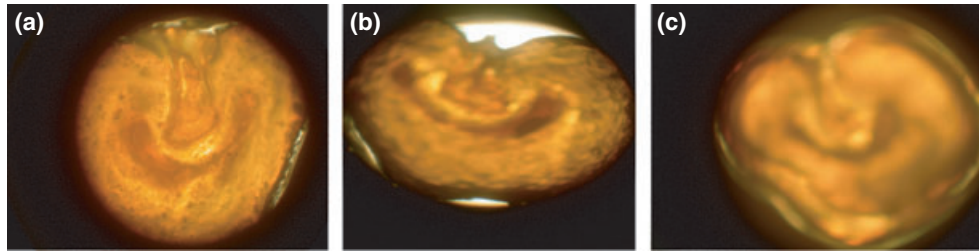
M, mesial; D, distal.

had two canals (86%) whilst 59% of the distal roots had two canals (Table 1). In the mandibular first molar the most common types were IV (73%) and II (14%) whilst type IX occurred in 5% of specimens (Table 2; Fig. 4).

Most of the distal roots of second mandibular molars (69%) had one canal. Most mesial roots (83%) had two canals, of which type IV (63%) and type II (18%) canal configurations were most prevalent (Table 2). The second mandibular molar had fused roots in 8% of cases (Table 1). Seventy-eight per cent of the second mandibular molar teeth had two flat separate roots (Table 1). The canal configuration of distal roots were type I (65%), type II (11%) and type IV (10%), whilst 10% had C-shaped canals (Table 2, Fig. 3).

**Root canal morphology (lateral canals, inter-canal communications)**

Inter-canal communications were more common in the mesial roots. In the mesial roots of two- or three-rooted mandibular molars they occurred 62% of the time in first molars and 49% in second molars. The prevalence of inter-canal communications was lower in the



**Figure 3** Histomicrograph of a permanent mandibular molar showing the C-shaped canal along the (a) cervical, (b) middle and (c) apical one-third of the root.

**Table 2** The different anatomical features of Sudanese permanent mandibular molars


Features	First molar		Second molar	
	M (%)	D (%)	M (%)	D (%)
<b>No. of canals</b>				
One	8	38	7	69
Two	86	59	83	21
Three	4	3	10	10
Others	2	0	0	0
<b>Type of canal</b>				
Type I	3	38	5	65
Type II	14	28	18	11
Type III	1	0	0	0
Type IV	73	22	63	10
Type V	1	1	0	1
Type VI	0	6	3	2
Type VII	1	0	1	1
Type VIII	2	3	0	0
C-shape	0	0	10	10
Type IX	5	2	0	0
<b>No. of apical foramina</b>				
One	17	65	20	73
Two	71	31	61	21
Three	11	4	18	4
Other	1	0	1	1
<b>Lateral canals in</b>				
Cervical third	11		5	
Middle third	13		9	
Apical third	28		20	
Horizontal interconnection	62	8	49	27
<b>Apical foramen location</b>				
Centrally in the apex	21		1	
Laterally	79		99	
<b>Apical constriction</b>				
Yes	3		4	
<b>Curvature</b>				
Straight	60	97	64	76
Curved – C-shape	0	0	10	10
Curved – Distally	38	3	21	11
Curved – Mesially	1	0	2	1

corresponding distal roots, 8% for the first molar and 27% for the second molar. The apical foramen was located laterally to the apex in 79% of the first

mandibular molars and 99% in the second mandibular molars (Table 2).

## Discussion

Although various techniques have been used in studies evaluating canal morphology, it has been reported that the most detailed information can be obtained by demineralization and staining (Vertucci 1984, Neaverth *et al.* 1987, Sieraski *et al.* 1989). This is regarded as an excellent method for three-dimensional evaluation of root canal morphology. It was anticipated that examination of the fine details (inter-canal communications, lateral canals) would require adequate ink penetration; however, it was found that the quality of clearing was sufficient to visualize such details without staining. In most studies, the classification of Vertucci (1984) was taken as a reference. In the present study, additional root canal configurations (Kartal & Yamkoglu 1992a,b) along with the classification of Vertucci (1984) were taken into consideration. The prevalence of three roots in mandibular first molars (3%) of the Khartoum population were in agreement with the findings of Sperber & Moreau (1998), who reported that 3% of their specimens had three roots. It is also similar to the finding of Curzon (1973) in the UK in a sample of 377 teeth where 3.4% had three roots and Curzon (1974) where teeth from a Baffin Eskimo population had a prevalence of 21.7%. The additional root was found on the lingual aspect of the main distal root and has been regarded as a genetic trait rather than a developmental anomaly (Walker 1988a). The nature of this additional root is variable, ranging from a short conical extension to a full-length root, with pulp extending into the root even when it is short (Reichart & Metah 1981). The presence of C-shaped canals was first documented in the endodontic literature by Cooke & Cox (1979) in three case reports. Subsequent studies of the root canal anatomy of mandibular second molars



**Figure 4** Clinical photographs showing the first permanent mandibular arrow indicate (a) type VI, (b) mesial aspect revealed type II, (c) and (d) type II.

from Japanese, Chinese and Hong Kong Chinese populations found a high incidence of C-shaped roots and canals (14–52%). In the present study, the prevalence of C-shaped canals was 10% in Sudanese mandibular second molars and this falls within the lower end of the range for a Mongoloid group (Walker 1988b, Yang *et al.* 1988, Manning 1990a,b).

### Conclusion

Four root canals (59%) in mandibular first permanent molar teeth of a population in Khartoum was a common occurrence. Three roots in mandibular first molars (3%) and C-shaped canals in the second permanent mandibular molars (10%) were recorded.

### References

- Al-Fouzan KS (2002) C-shaped root canals in mandibular second molars in a Saudi Arabian population. *International Endodontic Journal* **35**, 499–504.
- Baurmann M (1994) A new approach to demonstration of root canal anatomy. *Journal of Dental Education* **28**, 704–8.
- Blaskovic-Subat V, Smojver I, Maricic D, Sutaalo J (1995) A computerized method for the evaluation of root canal morphology. *International Endodontic Journal* **28**, 290–6.
- Cooke HG, Cox F (1979) C-shaped canal configurations in mandibular molars. *Journal of American Dental Association* **90**, 836–9.
- Curzon MEJ (1973) Three-rooted mandibular molars in English Caucasians. *Journal of Dental Research* **52**, 181.

- Curzon MEJ (1974) Miscegenation and the prevalence of three-rooted mandibular first molars in the Baffin Eskimo. *Community Dentistry and Oral Epidemiology* **2**, 130–1.
- Gaby YH, Walid BN, Hani FO (1999) Diagnosis, classification, and frequency of C-shaped canals in mandibular second molars in the Lebanese population. *Journal of Endodontics* **25**, 268–71.
- Gulabivala K, Opananon A, Ng YL, Alavia A (2002) Root and canal morphology of Thai mandibular molars. *International Endodontic Journal* **35**, 56–62.
- Kartal N, Yamkoclu F (1992a) The incidence of mandibular premolars with more than one root canal in a Turkish population. *The Journal of the Marmara Faculty of Istanbul* **1**, 203–10.
- Kartal N, Yamkoclu F (1992b) Root canal morphology of mandibular incisors. *Journal of Endodontics* **18**, 562–4.
- Kotoku K (1985) Morphological studies on the roots of the Japanese mandibular second molars. *Shikwa Gakuho* **85**, 43–64.
- Manning SA (1990a) Root canal anatomy of mandibular second molars. Part I. *International Endodontic Journal* **23**, 34–9.
- Manning SA (1990b) Root canal anatomy of mandibular second molars. Part II. *International Endodontic Journal* **23**, 40–5.
- Mayo C, Montgomery S, Rio C (1986) A computerized method for evaluating root canal morphology. *Journal of Endodontic* **12**, 2–7.
- Neaverth EJ, Kotler ML, Kaltenbach RF (1987) Clinical investigation (in vivo) of endodontically treated maxillary first molars. *Journal of Endodontics* **13**, 506–12.
- Omer OE, Ai Shalabi RM, Jennings M, Glennon J, Claffey NM (2004) A comparison between clearing and radiographic techniques in the study of the root-canal anatomy of maxillary first and second molars. *International Endodontic Journal* **37**, 291–7.
- Reichart PA, Metah D (1981) Three rooted permanent mandibular first molars in the Thai. *Community Dentistry and Oral Epidemiology* **9**, 191–2.
- Saunders WP, Saunders EM (1992) Effect of non-cutting tipped instruments on the quality of root canal preparation using a modified double-flared technique. *Journal of Endodontics* **18**, 32–6.
- Seo MS, Park DS (2004) C-shaped root canals of mandibular second molars in a Korean population: clinical observation and in vitro analysis. *International Endodontic Journal* **37**, 139–44.
- Sieraski SM, Taylor GN, Khon RA (1989) Identification and endodontic management of three-canal maxillary premolars. *Journal of Endodontics* **15**, 29–32.
- Somogyi-Csimazia W, Simmons AJ (1971) Three-rooted mandibular first molars in Alberta Indian children. *Canadian Dental Association Journal* **37**, 105–6.
- Sperber GH, Moreau JL (1998) Study of the number of roots and canals in Senegalese first permanent mandibular molar. *International Endodontic Journal* **31**, 117–22.
- Vertucci FJ (1978) Root canal morphology of mandibular premolars. *Journal of the American Dental Association* **97**, 47–50.
- Vertucci FJ (1984) Root canal anatomy of the human permanent teeth. *Oral Surgery Oral medicine and Oral Pathology* **58**, 589–99.
- Walker RT (1988a) Root form and canal anatomy of mandibular first molars in a Southern Chinese population. *Endodontics and Dental Traumatology* **4**, 19–21.
- Walker RT (1988b) Root form and canal anatomy of mandibular second molars in a Southern Chinese population. *Journal of Endodontics* **14**, 325–9.
- Walton R, Torabinejad M (1996) *Principles and Practice of Endodontics*, 2nd edn. Philadelphia, USA: W.B. Saunders Co, pp. 177–8.
- Weine FS (1998) The C-shaped mandibular second molar: incidence and other considerations. *Journal of Endodontics* **24**, 372–5.
- Weine FS, Pasiewicz RA, Rice RT (1988) Canal configuration of the mandibular second molar using a clinically oriented in vitro method. *Journal of Endodontics* **14**, 207–13.
- Yang ZP, Yang SF, Lin YC, Shay JC, Chi CY (1988) C-shaped root canals in mandibular second molars in a Chinese population. *Endodontics and Dental Traumatology* **3**, 160–3.