STEREOMICROSCOPIC STUDY OF 700 ROOT APICES OF MAXILLARY AND MANDIBULAR POSTERIOR TEETH

David Green, D.D.S., Brooklyn, N. Y.*

THIS study is a supplement to my previous article entitled "A Stereomicroscopic Study of the Root apices of 400 Maxillary and Mandibular Anterior Teeth."[1] I have thus completed the analysis of posterior as well as anterior teeth.[2]

The purpose of this article is to establish with greater precision than has heretofore been attained the morphology of the canal at the root apex, the major apical foramina, and accessory apical foramina.

In examining past and current literature, I noted that in previous investigations of pulp canal morphology the techniques employed in the preparation of the teeth for study may have distorted the specimens. Therefore, any descriptions, evaluations, or conclusions drawn from such studies may have been inaccurate.

The use of the stereomicroscope has given a view of these areas in depth and has provided a better opportunity to observe, analyze, and compare anatomic areas.

In this study, the basic principle was to use specimens which had been carefully treated and prepared so as not to mar the natural detail. The specimen apices were cut at a 7 mm. distance from the apex and cemented, flat end down, on glass microscope slides. The apices were then studied under the three-dimensional microscope, which had a micron measuring device on the lens. The measurements of the foraminal openings, as noted in Tables I and II, were tabulated to two decimals.

Considerable judgment had to be used in classifying round, oval, irregular, and funnel-shaped openings, as many of these shapes were of the borderline variety. Some orifices which appeared to be foramina, such as indented cementum, seemed to enter the main canal, but gradations of hard to soft cementum and dentine made classification difficult.

In order to determine accurately the percentage of accessory foramina present, it was also necessary to explore, penetrate, and study the cut ends of

This study was exhibited at the International Centennial of the American Dental Association in New York, New York, Sept. 14-18, 1959; the meeting of the American Association of Endodontists in Chicago, Illinois, February, 1958; and the midwinter meeting of the Chicago Dental Society, February, 1959, and February, 1960.

*Chief, Department of Endodontics, Unity Hospital, Brooklyn, New York.

TABLE I. DESCRIPTION OF MAJOR APICAL FORAMINA OF MAXILLARY AND MANDIBULAR POSTERIOR TEETH

TEETH	NUMBER OF ROOTS EXAMINED	AVERAGE DIAMETER OF MAJOR APICAL FORAMINA EXAMINED (MM.)	AVERAGE DISTANCE FROM APEX (MM.)	MAJOR FORAMINA (PER CENT)					
				DIRECTLY ON APEX	ROUND CONTOUR	OVAL CONTOUR	ASYMMETRICAL CONTOUR	SERRATED PERIPHERY	PRONOUNCED FUNNEL
*Maxillary molars**									
Lingual root	100	0.4	0.5	31	53	29	18	21	15
Distobuccal root	100	0.4	0.45	27	46	39	15	3	34
Mesiobuccal root	100	0.35	0.4	40	55	29	16	9	27
Mandibular molars									
Mesial root	100	0.5	0.45	34	52	35	13	24	14
Distal root	100	0.65	0.45	47	42	47	11	21	19
Maxillary									
First premolars	50	0.3	0.3	47	71	18	11	7	34
Second premolars	50	0.3	0.4	46	58	19	23	9	27
Mandibular									
First premolars	50	0.35	0.5	36	66	22	11	6	40
Second premolars	50	0.3	0.45	60	55	24	20	13	20

*All molar calculations include first and second molars.

all roots. A Kerr No. 1 file was used to explore the cut end, as well as the apex, for major and accessory foramina. This instrument measured about 1 micron (0.001 mm.) at its tip and flared to a thickness of 125 microns at a point 1 mm. from the tip. Canal orifices at the cut end were from approximately 0 to 1 mm. or more in diameter.

In entering a canal from either the cut end or the apical end, negotiation was simple, effective, and successful in about 90 per cent of the cases. In the

TABLE II. DESCRIPTION OF ACCESSORY APICAL FORAMINA OF MAXILLARY AND MANDIBULAR POSTERIOR TEETH

TEETH	NUMBER OF TEETH EXAMINED	AVERAGE DIAMETER (MM.)	AVERAGE DISTANCE FROM APEX (MM.)	ACCESSORY FORAMINA (PER CENT)			
				TOTAL WITH ACCESSORY FORAMINA	ONE FORAMEN	TWO FORAMINA	THREE OR MORE FORAMINA
*Maxillary molars**							
Lingual root	100	0.25	1.0	13	11	2	None
Distobuccal root	100	0.2	0.85	17	12	4	1
Mesiobuccal root	100	0.2	1.0	32	20	10	2
Mandibular molars							
Mesial root	100	0.2	0.8	18	10	3	5
Distal root	100	0.3	0.8	35	23	5	7
Maxillary							
First premolars	50	0.15	1.0	34	29	3	2
Second premolars	50	0.15	1.0	32	15	10	7
Mandibular							
First premolars	50	0.2	1.0	45	19	15	11
Second premolars	50	0.15	1.0	47	25	17	5

*All molar calculations include first and second molars.

Fig. 1.

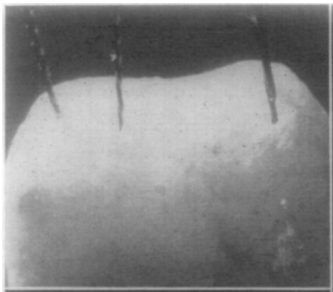

Fig. 2.

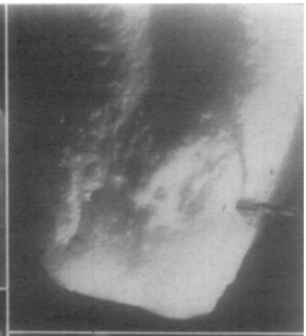

Fig. 3.

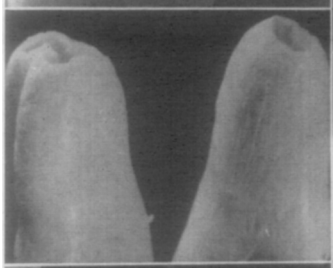

Fig. 4.

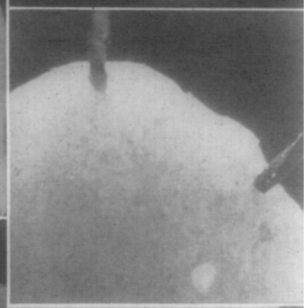

Fig. 5.

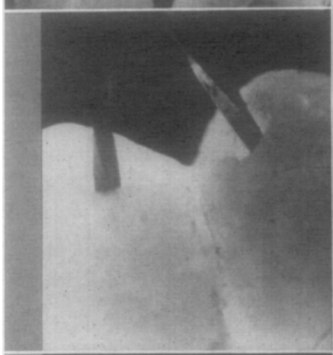

Fig. 6.

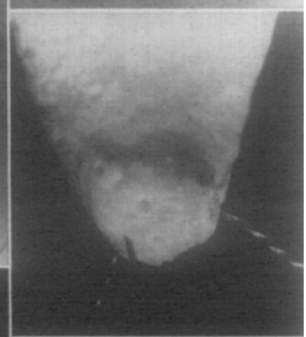

Fig. 7.

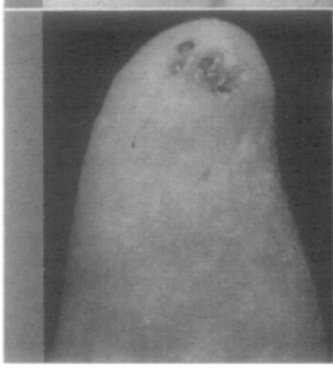

Fig. 8.

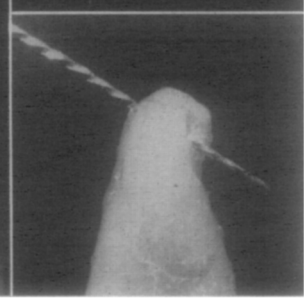

Figs. 1 to 9.—Photomicrographs showing unusual variations in morphology of apical foramina. A Kerr No. 1 file was used for exploration.

Fig. 1.—Maxillary molar, mesiobuccal root. The lingual canal foramen is on the right. On the left are two foramina, possibly a major and accessory or else the result of a bifurcated major canal.

Fig. 2.—Mandibular first premolar. A No. 1 file is inserted through a lateral canal which follows a course at a right angle to the major canal.

Fig. 3.—Roots of a maxillary first premolar. Note incompletely developed apical foramina.

Fig. 4.—Apex of a maxillary second premolar. Note major apical foramen at 45 degree angle to axis of root and 2 mm. short of apex. An accessory foramen appears below.

Fig. 5.—Maxillary first premolar. Canals are exiting in unparallel manner.

Fig. 6.—Mandibular first premolar with multiple foramina.

Fig. 7.—Palatal root of maxillary second molar with one major foramen and two accessory foramina.

Fig. 8.—Maxillary first premolar. A canal follows a horizontal course 2 mm. below the apex. The major canal meets the horizontal canal.

remaining 10 per cent the following difficulties were encountered: (1) Varying degrees of calcified material in the canal prevented successful negotiation of or even entrance into the canal from either end. (2) In a marked curve in a canal a thin, flexible instrument would follow through. In some cases a broader, more rigid instrument would not follow the curve but instead would cause a ledge, after which negotiation of the apex, even with the finer instrument, was not possible. (3) A bent instrument had no propelling power.

To supplement the data of this study, I am now preparing a paper entitled "A Study of Double Canals in Single Roots," the results of which will alter somewhat the percentages of major and accessory foramina. Since it was not expedient to cut the 7 mm. root apices used in this study for sagittal examination, a new set of 1,100 teeth was classified. In cutting roots sagittally, I found that many had two canals at the 7 mm. level which coalesced to form a single canal between this point and the apex. In other cases a major canal bifurcated to two canals about 2 to 3 mm. short of the apex. In rare cases these, in turn, bifurcated again, making four or five multiple foramina.

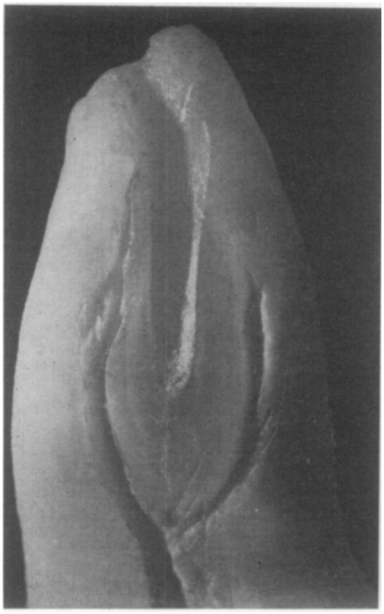

Fig. 9.—Maxillary second premolar. Note dens in dente.

The mesiobuccal roots of the upper molars presented a noteworthy aspect. In twenty-eight cases of apparent double canals at the cut end, the analysis was as follows:

1. Twelve had two major canals at the cut end as well as at the apex. One specimen had two roots (similar to a premolar).
2. In sixteen cases one of the two major canals was calcified and impenetrable. Of these, thirteen had impenetrable lingual canals, and three had impenetrable buccal canals.

Impenetrable canals were found less often in other roots having double canals.

In classifying single roots with possibilities of double canals, I found that some had one major canal and that some had two. This group included premolars, mesiobuccal roots of upper molars, and mesial roots of lower molars. Where there was only one major canal, it was untenable to classify it as a buccal or lingual canal. Descriptive analyses of buccal and lingual canals were found to be quite similar. Because of these findings, buccal, lingual, and single canals were averaged under one heading.

In Tables I and II it is to be noted that two-rooted premolars were included in the averages, but in order to avoid confusion they were not stated in the tables.

In Table I, total percentages add up to more than 100, since foramina had more than one classification. Accessory foramina were, for the most part, round in shape and classification was not indicated.

In some cases it was not possible to detect with anatomic accuracy the designation of a first and second molar; hence, their inclusion under one heading.

Approximately 25 per cent of the maxillary first premolars and about 10 per cent of the maxillary second premolars have two fully formed roots. In the mandibular premolars the occurrence of two roots is a rare anomaly.

SUMMARY

1. By comparison with previous methods, studying the specimens in their original and natural conditions and shapes may have resulted in more accurate findings.

2. Average accessory foramina are about one-half the size of major foramina and twice the distance from the apex.

3. Approximately 50 per cent of major foramina open directly on the apex. Those which do not open at the apex range from eccentric position to 2 mm. from the apex.

4. The average funnel in an apical foramen diminishes in diameter to about one-half its size at a point about 0.75 mm. from the surface opening.

5. While Tables I and II are nearly accurate for application in about 90 per cent of cases found in the oral cavity, allowances should be made for variables and imponderables.

6. When there was a curve at the root end, the canal invariably followed the curve rather than a straight line.

7. In multirooted teeth, whether accessory foramina were or were not present, the other roots usually had similar conditions.

CONCLUSION

I have endeavored to add to the present knowledge of apical morphology by organizing my observations into definite statistical form. It is hoped that this analysis will stimulate further investigations in this field of study.

Appreciation is hereby expressed to Dr. Arnold Reisman of the Watson Laboratories of The International Business Machine Company for his assistance in the investigation and calculation of averages, as well as to The International Business Machine Company for permission to use their equipment.

REFERENCES

1. Green, David: A Stereomicroscopic Study of the Root Apices of 400 Maxillary and Mandibular Anterior Teeth, ORAL SURG., ORAL MED. & ORAL PATH. **9**: 1224-1232, 1956.
2. Green, David: Morphology of the Pulp Cavity of the Permanent Teeth, ORAL SURG., ORAL MED. & ORAL PATH. **8**: 743-759, 1955.