

**Critical review of endodontic topic(s) related to my submitted clinical case**

***The applications of small field of view cone beam computerised tomography in endodontics.***

Submitted in partial fulfilment of the requirements for the

Postgraduate Certificate in Endodontology  
in the Faculty of Health & Social Care

*2010-2011*

**E19182**

At the University of Chester

**Word count 2799.**

# **The applications of small field of view cone beam computerised tomography in endodontics**

*The purpose of this essay is to discuss the use of Cone Beam Computerised Tomography (CBCT) in the field of endodontics. This subject was chosen as radiographs taken at differing angles of the periradicular areas related to the teeth treated in the clinical case are inconsistent in shape and density. The use of CBCT would hopefully have provided an image of greater diagnostic value.*

## **Definition of CBCT**

*A technique that enables three-dimensional reconstruction, but using a cone beam to decrease the dose to the patient when compared to conventional computerized tomography. (A Dictionary of Dentistry in Medicine)*

**Table 1. A brief history of the development of CBCT.**

*1895 Wilhelm Roentgen discovered X rays, Germany.  
1896 First intra oral radiograph C. Edmond Kells. New Orleans.  
1967 Godfrey Hounsfield developed first CT scanner was in 1967.  
1971 CT scanning was introduced into medical scanning.  
1990 Tachibana and Matsumoto first reported use of CT in endodontics.  
1997 Quantative Radiology produced the first CBCT, the New Tom 9000, for dental use after the pioneering work of both Arai in Japan and Mozzo in Italy.  
2001 First CBCT licensed for use in USA*

*For nearly a century dentists have been studying a 2D representation of a 3D structure, the patient. This simplification of information produces inherent disadvantages. Anatomical structures in the plane of roots and apices of teeth studied obscure their detail, typically occurring in the upper molar area where the zygomatic arch or sinus may complicate the detail of posterior teeth root anatomy (Tamse et al 1980). In practice this means that radiolucent areas may not be identified, there maybe difficulty in relating the position of the apices of the teeth to vital structures. Correct identification of root morphology and canal anatomy maybe difficult as is identification of root fractures and root resorption.*

## **How does a CBCT work?**

*A cone beam source of radiation revolves on a gantry between 180° to 360° around a fixed fulcrum, the region of interest (ROI). The radiation, after it has passed thought the ROI it is received by a detector directly opposite of the rotating source. This rotation produces between 150-600 sliced images of the area around the ROI, the field of view (FOV). This 2D data is then converted via cone beam algorithms (based on the original by Feldkamp et al in 1984) into a 3D volume of data by a PC. Information can then be viewed on a PC in*

either of the 3 dimensional planes or as a composite 3D image. This can be manipulated by the PC software to provide more detail of specific areas of interest. Figures 1,2,3.

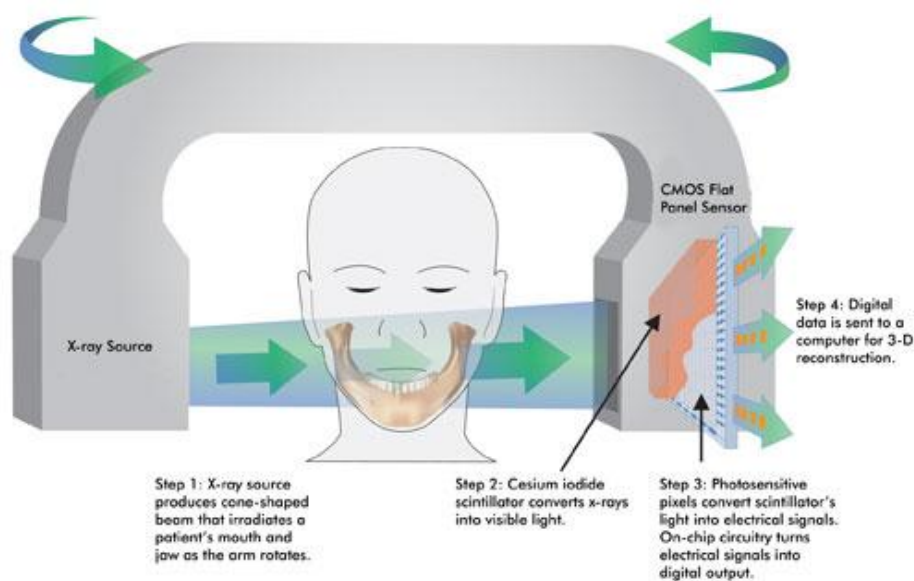


Figure 1.

### Essential aspects of CBCT relating to endodontics.

The most important concepts in the use of CBCT in endodontics is the field of view and the spatial resolution of the machine. Figures 2,3.

#### Field of view (FOV) Figures 2,3.

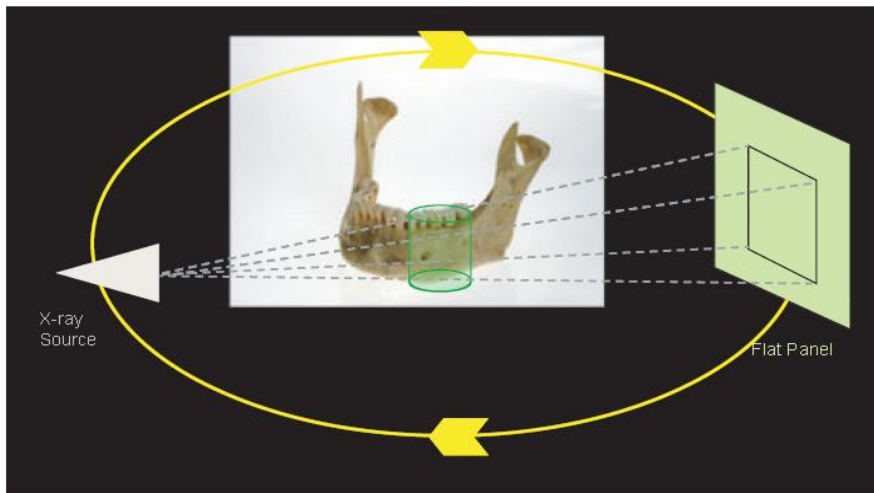
This is essentially the scan volume, and is usually either spherical or rectangular in nature. Because endodontic treatment usually involves one or maybe two teeth on an arch the FOV can afford to be small, or “localised”, usually 5cm by 5cms or less. This reduction of the FOV reduces the amount of effective radiation dose. Other advantages of a small FOV are a higher spatial resolution and improved diagnostic potential, ability to avoid metallic structures which may cause interference, reduced time to process and read and the image, and a smaller area of responsibility medico legally. (Simonton et al 2008.)

Most small FOV CBCT machines produce an effective radiation dose in the same order of magnitude as a panoramic x ray or a set of full mouth periapical radiographs. (Pauwels R, et al. 2011).

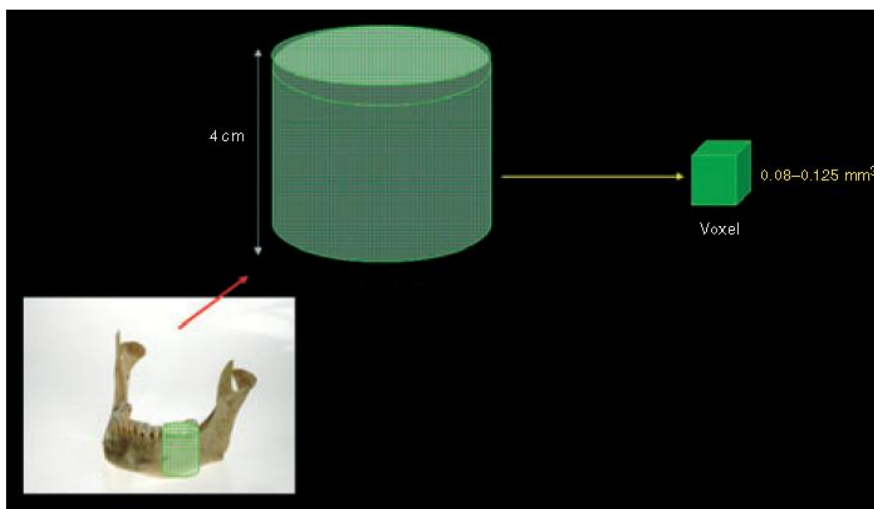
#### Spatial resolution. Figures 2,3.

The degree of spatial resolution is determined by the voxel size, it is desirable that the resolution of a CBCT machine used for endodontics should not exceed 200µm, the average width of the periodontal space. Otherwise pathological changes will not be identified.

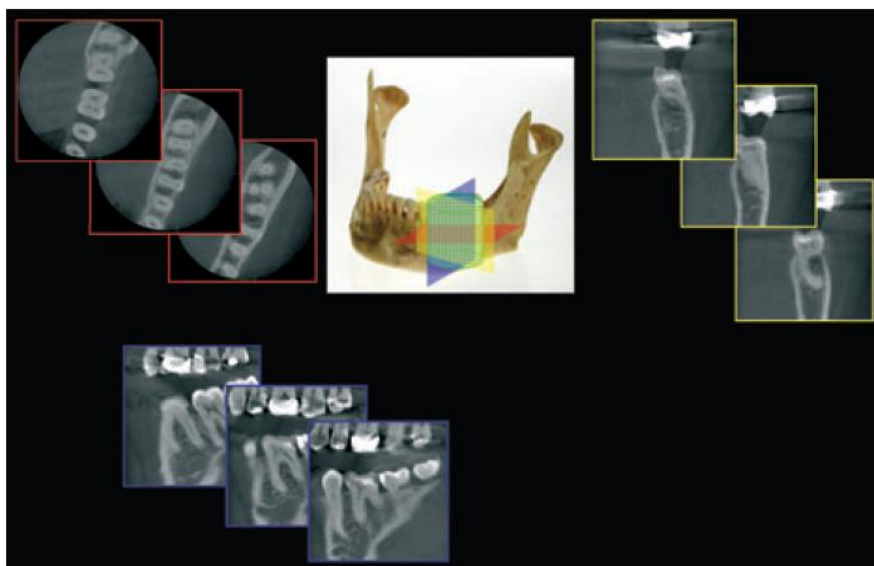
Advantages and limitations of CBCT can be seen in table 2. Technical aspects of CBCT machines can be viewed tables 3-6.



*A cone-shaped X-ray beam and the detector rotate once around the patient and captures a cylindrical volume of data (FOV).*

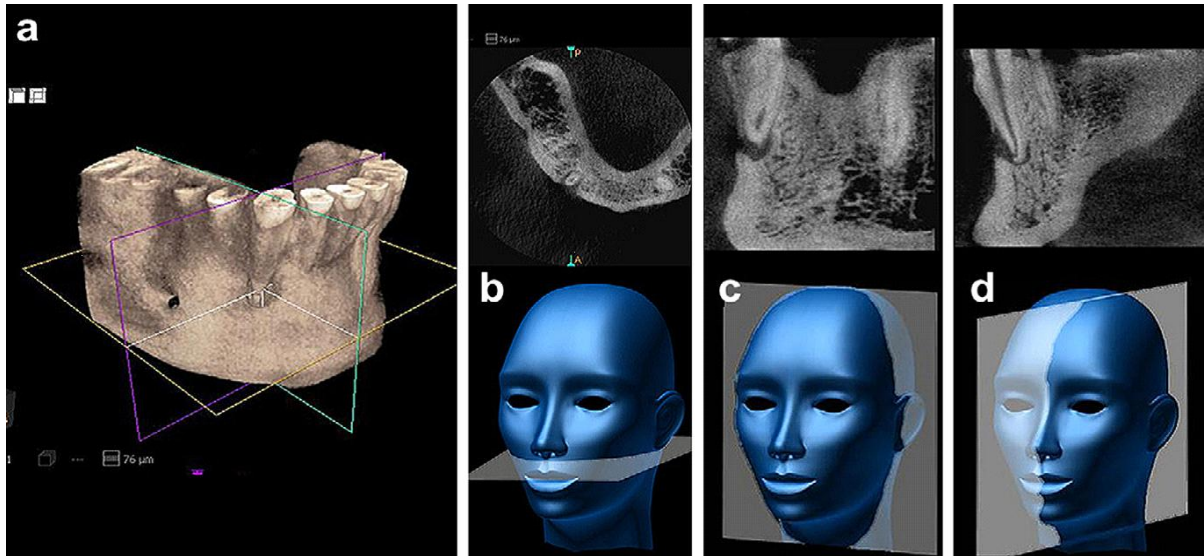


*The collected data within the FOV is collated as voxels, therefore a typical FOV consists of millions of voxels. Software then reconstructs images for this dataset.*

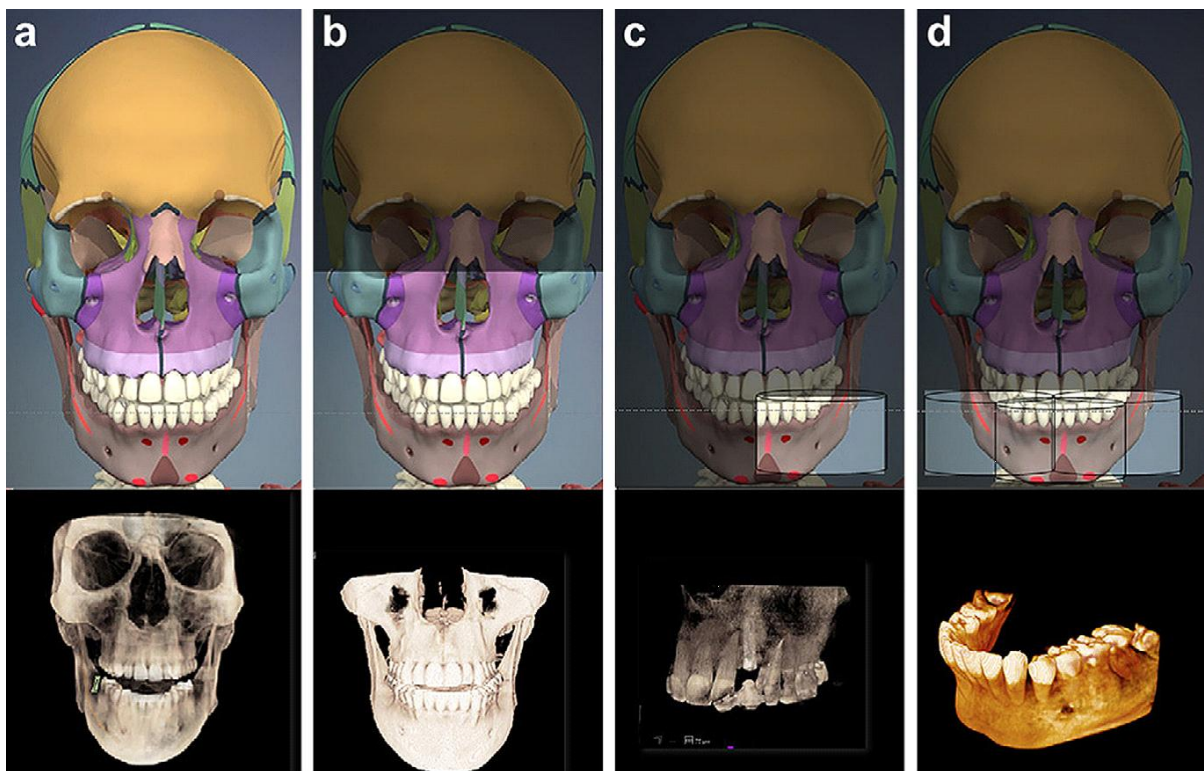


*Typically cross-sectional images in three orthogonal views are generated from the CBCT scan. The clinician selects the position and thickness of the slice selected from within the volume of data. The three views can be assessed simultaneously, traversing through one plane simultaneously alters the other two planes.*

*Figure 2.*



After reconstruction of the basis images, visualization software displays the volumetric data as, A, a three-dimensional rendering, B, axial, C, coronal, and D, sagittal orthogonal images.



CBCT units can be classified according to the FOV incorporated from the scan. A, Large FOV scans provide images of the entire craniofacial skeleton, B, Medium FOV scans image either the maxilla mandible. C, Focused FOV scans provide high-resolution images of limited regions. D, Stitched scans from the multiple focused FOV scans provide larger regions of interest to be imaged from the superimposition of multiple scans.

**Figure 3**

## **Uses of focused FOV CBCT in endodontics.**

### **Definitive diagnosis of periradicular areas.**

*Endodontics is the treatment or prevention of periradicular pathology of endodontic origin. Radiographic investigation is essential in the definitive diagnosis of periradicular pathosis. 50 years ago Bender et al demonstrated that bone lesions could not be consistently diagnosed radiographically unless cortical bone was perforated. In 1972 Goldman et al showed that there was considerable disagreement amongst operators in diagnosing periapical areas with radiographs. The reasons for these inconsistencies are the 2D nature of the radiographic image, anatomical noise and geometric distortion combining to mislead the operator.*

*Anatomical noise can be due to a number of factors, overlying anatomy, thickness of cancellous bone and of the cortical plate or the relationship of the apices to the cortical plate. Anatomical noise tends also to reduce the size of the lesion.*

*Geometric distortion occurs due to sub optimal irradiation geometry e.g. due to low palatal vault in maxillary molar area. 2D radiographs can also magnify the image by up to 5%.*

*Lesion shape may also determine the size on a 2D x ray, if its shape is oblong and its largest dimension is parallel to the direction of the x-ray beam it will appear smaller.*

*Increasing the number of radiographs, taken at differing angles improves accuracy of diagnosis. As described by Brynolf in 1970. However use of 2D radiography still has serious limitations.*

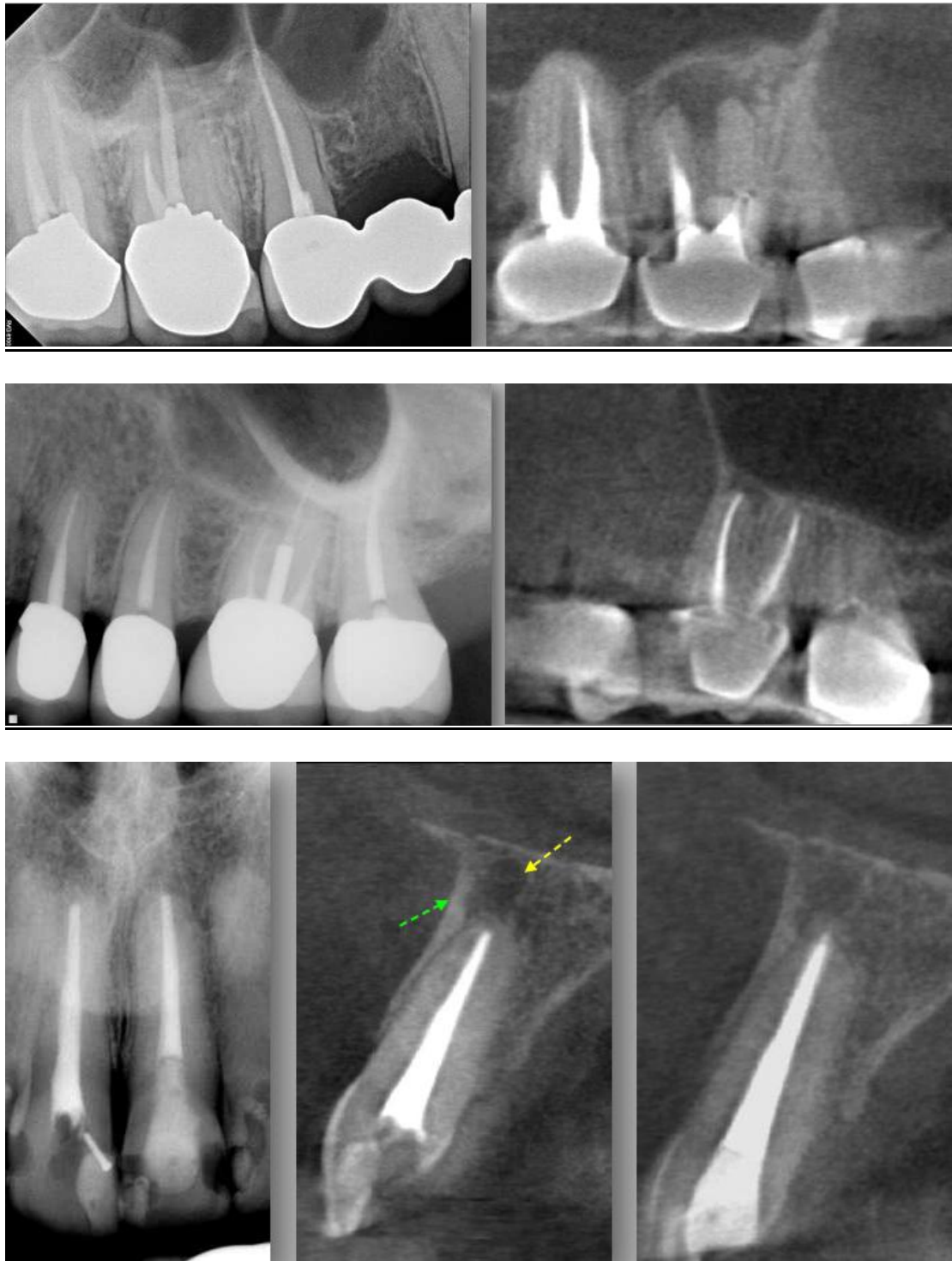
*Studies by Estrela et al 2008 evaluated apical periodontitis (AP) in 1508 teeth by three different methods, panoramic, periapical radiographs (PR) and CBCT. He concluded that accuracy of diagnosis was significantly higher with periapical radiographs (54.5%) over panoramic radiographs (27.5%) using CBCT as a standard reference, apical periodontitis was correctly identified with conventional radiography only when advanced. Estrela concluded that the diagnosis of AP should be done with great care due to the great possibility of false negative diagnosis. Lofthag Hansen (2007) compared the periapical status of 46 mandibular and maxillary molar teeth with two angled periapical radiographs and CBCT scans. CBCT detected 38% more periapical lesions. Low et al 2008 reported similar findings.*

*An in vivo study by Garcia de Paula-Silva in 2009 examined the periapex of 83 dogs teeth with PR and CBCT using histological examination as a gold standard. Conclusions were that CBCT diagnosed a healthy periapex more accurately than PR and was more sensitive in detecting PR. AP was detected in 71% of roots with PR, 84% with CBCT and 93% with histology.*

*I can find no literature regarding the diagnosis of periapical scarring with CBCT.*

*Radiographs (left) and sagittal CBCT scan (right) showing improved diagnostic ability of periradicular areas with CBCT. Picture 1.*

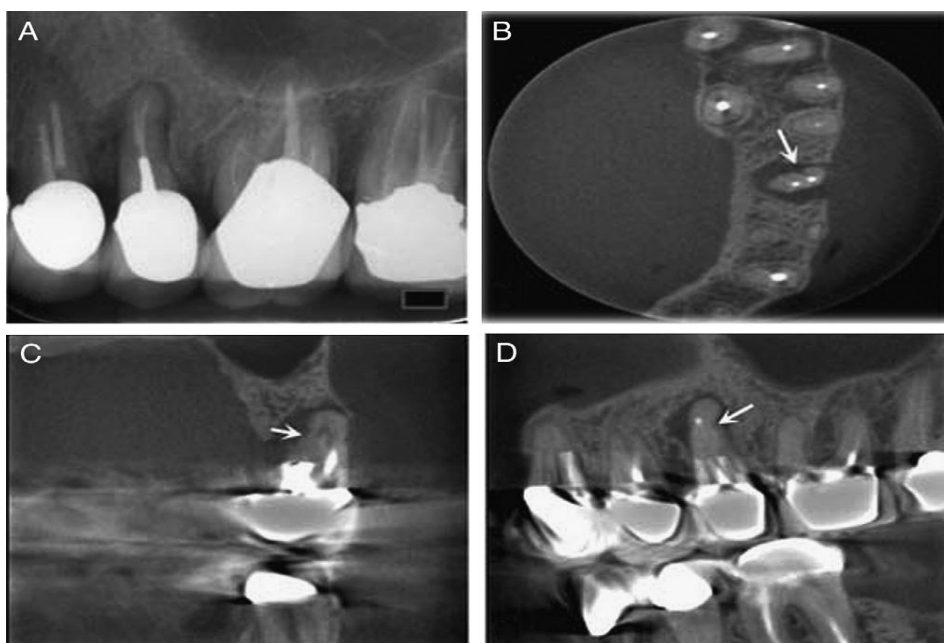
Picture 1.



Visualisation of root fractures.

Vertical root fractures (VRF) are fractures that extend along the long axis of the tooth. If left undiagnosed progressive destruction of the periodontal ligament and alveolar bone occurs influencing the prognosis of adjacent teeth and future restorations. VRFs may not produce any signs or symptoms. It is therefore important that VRFs are diagnosed promptly. Prevalence of VRFs in various populations is said to be between 2-5% and in extracted root filled teeth varies between 3-30% dependent on the studies read. The highest incidence occurs in the age 40-60 years (Tamse et al 1999). The most common teeth to present with a VRF are lower molar and upper premolars (Cohen et al 2006).

One third of VRFs are detectable radiographically, usually when the x ray beam is perpendicular to the fracture line or granulation tissue separates the splinters (Hannig et al 2005). Mesiodistal fractures are almost impossible to detect with normal radiography because the x ray beam must be within 4 degrees of the fracture plane to allow detection (Rud Omnell et al 1970). The gold standard for in vivo diagnosis of a VRF is surgical exposure of the fracture, and visual inspection under magnification with the aid of staining. There are few in vivo studies comparing visual examination to CBCT investigation of VRFs, because of the ethical implications. However a study by Edlund et al 2011 examined 32 teeth in 29 patients, who gave symptoms of a VRF, with CBCT and subsequent surgical exploration. Results showed a high correlation between diagnosis via CBCT and direct visualisation. This confirms numerous in vitro studies supporting the validity of CBCT diagnosing VRFs. Picture 2 shows diagnostic ability of VRF with CBCT using alternative axial planes.



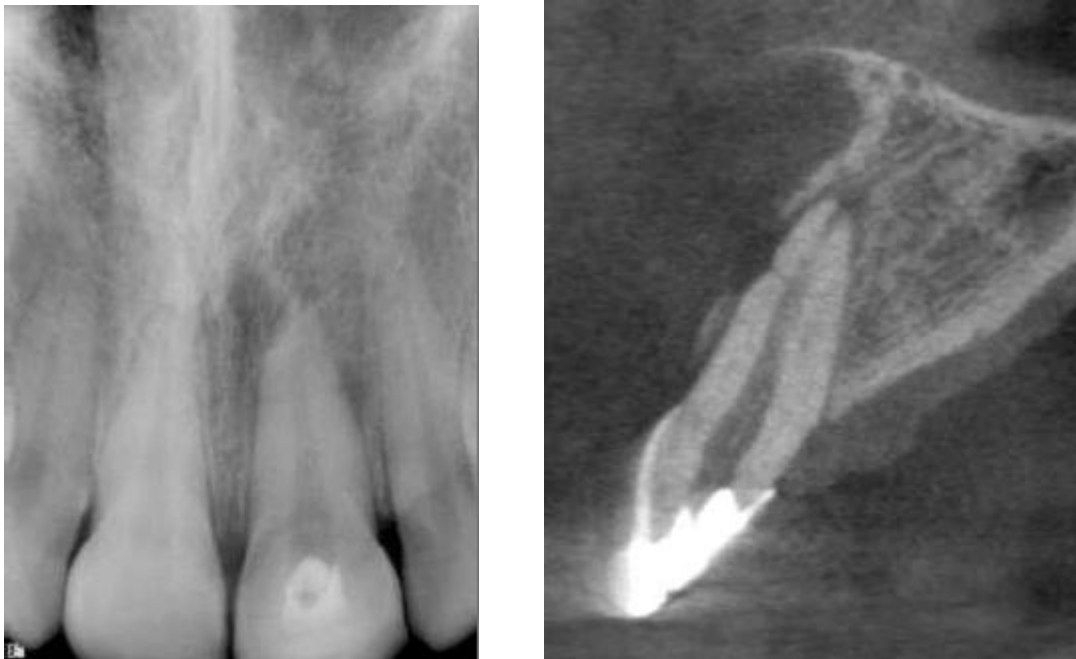Picture 2.

PA of suspected VRF. (B) Axial CBCT showing fracture line mesiodistally. (C) Coronal (D) Sagittal view.

### Diagnosis and management of dento alveola trauma.

Most maxillofacial traumatic injuries involve only the dentition (50%) or the dentition and the adjacent soft tissue (36%). Injuries involving alveolus account for the remaining 13.6%. Gassner et al 1999. Unfortunately film based intra oral radiography has poor sensitivity for the diagnosis of minimal tooth displacements, or root and alveolar fractures. CBCT has the advantage that it is more comfortable for the traumatised patient, one extra oral scan producing a multidimensional image avoiding the need for multiple intra oral radiographs. Bernardes et al retrospectively compared conventional periapical radiographs and CBCT images for 20 patients with suspected root fractures. They found that CBCT was able to detect fractures in 90% of patients whereas PAs could only detect fractures in 30% to 40% of cases. They indicated that CBCT was an excellent supplement to conventional radiography in the diagnosis of root fractures. Picture 3 shows more defined radiolucent areas and fracture lines with CBCT at apex of traumatised upper central.

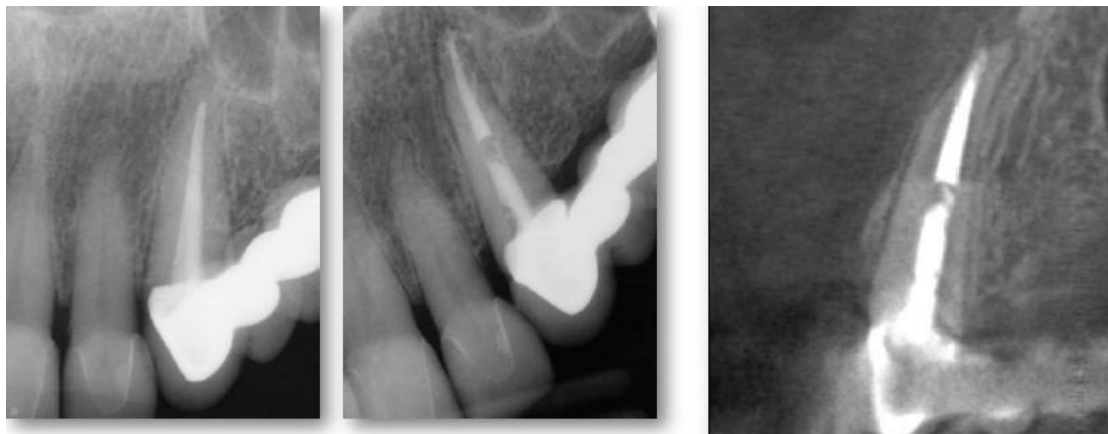Picture 3.



### Identification of apices of teeth in relation to vital structures.

Conventional radiographs cannot always assess the spatial relationship of the roots to their surrounding anatomical structures (Cotti et al 1999). This is important in the context of surgical planning and treatment (Velvart et al 2001, Low et al 2008). The radiological identification of the position of roots and their apices to vital structures such as maxillary sinus or mandibular canal is essential for presurgical assessment for endodontic microsurgery and the avoidance of iatrogenic damage due to overfill during orthograde root canal

therapy. In 2001 Velvart et al studied 55 patients with 44 mandibular molars and 6 mandibular premolars, who had been referred for apical surgery due to persistent periapical areas. Both a CT scan and a periapical radiograph were taken of all the teeth to be treated. CT identified all 78 lesions identified during surgery; normal radiographs identified 21% fewer lesions. The mandibular canal could be identified in 31 cases with normal radiography but could be identified in all cases with CT. CT was also able to measure the distance from the lesion/ root apex to the mandibular canal, this could not be identified in 49 cases with normal radiography. CT was also able to quantify the amount of cortical and cancellous bone and the 3 dimensional extent of the lesion. Rigolone et al in 2003 studied 43 upper first molars using CBCT for possible microsurgical treatment of the palatal root. They concluded that that mean distance from the buccal cortex and the buccal side of the palatal root was 9.73 mm and that presence of the maxillary sinus between the roots was 25%. They postulated that this could provide enough information for a minimally invasive microsurgical technique via the buccal rather than palatal approach. Low et al 2008 assessed 37 premolars and 37 molars in the maxilla, referred for apical surgery. They verified that CBCT was able to identify 34% more lesions than periapical radiography, and that detection was influenced by the apices proximity to the sinus floor, and was more difficult in upper second molars. CBCT was also able to identify sinus membrane thickening, expansion of the lesion into the maxillary sinus, and apicomarginal communications which PA radiographs were not. These are important presurgical markers which may indicate possible surgical complications, oral antral fistula and vertical root fracture. Picture 4 demonstrates how CBCT can more effectively relate the apex to a vital structure, in this case the sinus.



Picture 4.

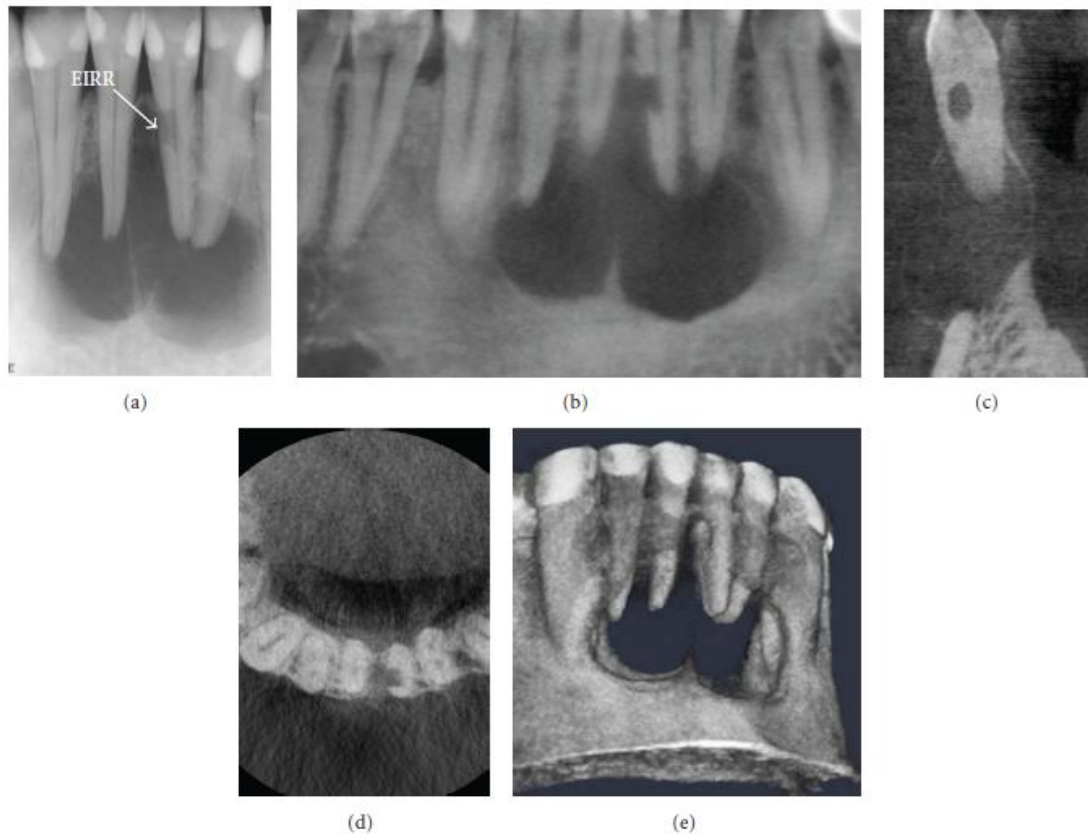
#### Identification of root resorption.

Root resorption is the loss of cementum or dentine as the result odontoclastic cell action. Classifications of resorption are external cervical resorption, internal resorption and external resorption. It can be challenging to diagnose and classify. Accurate identification is essential to ensure correct treatment as management differs dependant on the type of resorption. Gartner et al 1976 described guidelines for clinicians to differentiate the types of resorption . The

use of parallax 2D radiographic techniques is advocated for differentiating internal from external resorption. However conventional radiography does not fully represent the lesion, being unable to identify its true size, location and portal of entry.

The diagnostic advantages of CBCT lies in the ability of its software to access the most favourable orthogonal views related to the specific site of interest, and the ability to reproduce an accurate reproducible 3D image of the lesion in relation to the root anatomy. Recent studies by Cohenca et al 2007 stated that CBCT was extremely useful in diagnosing the extent of resorption, dictating the treatment.

A recent report by Cochrane institute, Ahangari et al suggested that “clinicians decide on the most appropriate means of managing this condition according to their clinical experience with regard to patient related factors”. CBCT is an ideal imaging tool to assess and diagnose such conditions and their sequelae, as can be seen by the images below.



Picture 5.

### Diagnosis of cystic lesions, and non-endodontic pathosis.

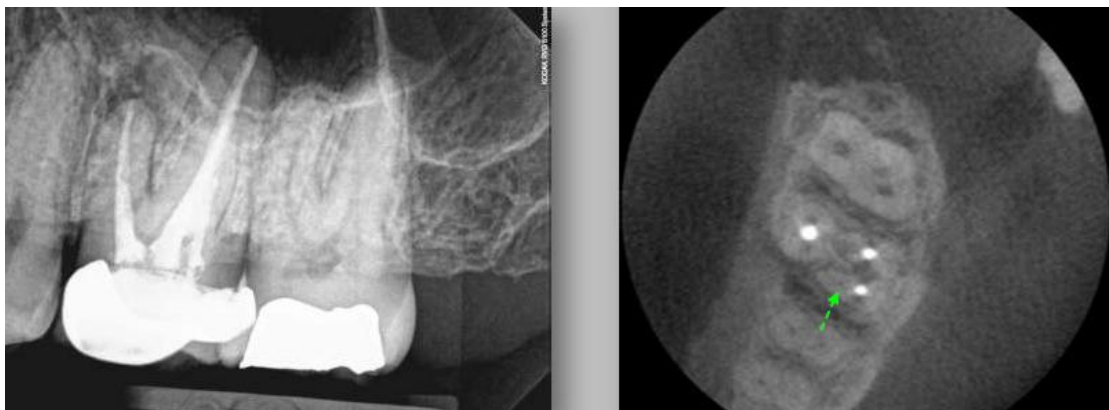
*Diagnosis of cystic lesions is important as there is controversy whether these lesions heal without surgical treatment. Cysts can only be diagnosed histologically which involves surgery! Different studies have tried to differentiate between granuloma and cysts by means of imaging, relying on the different densities of the cavity contents. Simon et al in 2006 using CBCT found that diagnosis coincided with histological examination in 13 of 17 cases studied inferring some correlation. However a more recent study by Rosenberg et al in 2010 using a larger sample of 45 cases concluded that diagnosis could not be confirmed with CBCT. Further studies need to be undertaken to determine the diagnostic ability of CBCT in these cases.*

### Identification of tooth morphology

*The success endodontic therapy is dependant on the correct identification of all root canals, this enables shaping, cleaning and obturation. Failure to identify anatomy is a major cause of endodontic failure.*

*Matherne et al compared the ability of three board certified endodontists to detect the number of root canals on intraoral digital (both CCD and PSP) images with CBCT in 72 extracted teeth in 3 equal groups of maxillary molars, mandibular premolars, and mandibular incisors. Observers failed to detect at least one root canal in 40% of teeth using 2D imaging.*

*Picture 6 shows clear presence of MB2 canal on CBCT axial section, not visible on 2D radiograph.*



Picture 6.

### Conclusion.

*The relatively modern technology of CBCT has added another dimension to dental radiography and is quickly becoming the gold standard for radiographic imaging in dentistry. At present it cannot replace film or digital radiography for the reasons of cost and degree of effective radiation. However, as with all new technologies, techniques will improve to reduce the dose of radiation and costs will lower. Presently CBCT has a place in referral endodontics, where the increased number of complex cases warrants the use of the technology and the benefits to the patient outweigh the risks.*

*The limited number of high quality research papers in the field prevents the publishing of evidence-based guidelines and at present there are only best practice guidelines – SEDENTEXCT 2009.*

*One of the most valuable areas of use of CBCT in endodontics is the assessment of healing of pathology after treatment. Due to its ability to image in 3 dimensions and accurately quantify volume and linear measurements, it can more precisely gauge changes in pathosis than 2D radiographs. This may change the standards by which further clinical endodontic papers are written and judged. It may also graphically show the science of endodontics that success rates are far lower than previously thought.*

*Table 2. Major benefits and limitations of CBCT imaging in the OMF region.*

Benefits

- 3D dataset
- real-size data
- potential for generating all 2D images (e.g. orthopantomogram, lateral cephalogram, TMJ)
- potential for vertical scanning in a natural seated position
- isotropic voxel size
- high resolution (e.g. bone trabeculae, Periodontal ligament (PDL), root formation)
- lower radiation dose than MSCT
- less disturbance from metal artifacts
- reduced costs compared with MSCT
- easy accessibility
- in-office imaging
- easy handling
- small footprint
- Digital Imaging and Communications in Medicine (DICOM) compatible
- user-friendly post-processing and viewing software
- energy saving compared with MSCT

Limitations

- low contrast range (dependent on the type of X-ray detector)
- limited detector size causes limited field of view and limited scanned volume
- limited inner soft tissue information
- increased noise from scatter radiation and concomitant loss of contrast resolution
- movement artefacts affecting the whole dataset
- truncation artifacts (caused by the fact that projections acquired with region of interest selection do not contain the entire object)
- cannot be used for estimation of Hounsfield units (HU)

**Table 3**

*Reported Comparative Radiation Effective Dose ( $E_{2007}$ ) for Limited, "Focused" or Small FOV CBCT Systems. Int. J. Dent. 2009; 2009: 634567.*

CBCT unit	Technique	Dose <sup>a</sup>		
		Absolute Effective dose <sup>a</sup> ( $\mu$ Sv)	Comparative Digital panoramic equivalent <sup>b</sup>	No. of days of annual per capita background <sup>c</sup>
Kodak 9000 3D	Mx Post/Mx Ant/Mn Post/Mn Ant	9.8/5.3/38.3/21.7	.7/1.4/2.7/1.6	1.2/.6/4.7/2.6
PreXion 3D	Standard/High Res	189/388	13.5/27.7	23/47
ProMax 3D	Small/Large	488/652	35/47	59/79
3D Accuitomo	Ant (4 x 4 cm/6 x 6 cm)	20/43	1.4/3.1	2.5/5.2
	Min (Mn PM)—Max (Mn 3rd Mol)	11–77	.8–5.5	2.5–5.2
	Mx (Ant/PM/Mol)	29/44/29	2/3.2/2	3.5/5.3/3.5
	Mn (Ant/PM/Mol)	13/22/29	.9/1.6/2	1.6/2.7/3.5
	II/FPD Large/FPD Small	30/102/50	2.1/7.3/3.6	3.6/12.4/6
Veraview	Ant (4 x 4 cm/8 x 4 cm/pan + 4 x 4 cm)	31/40/30	2.2/2.9/2.1	3.8/4.9/3.6
	4 x 4 cm	2.9	.2	.06

<sup>a</sup>Using 2007 ICRP calculations.

<sup>b</sup>Median of published effective dose for digital dental panoramic radiography = 14  $\mu$ Sv.

<sup>c</sup>Annual per capita = 3.0 mSv (3,000  $\mu$ Sv) per annum.

**Table 4**

Technical parameters of CBCT devices.

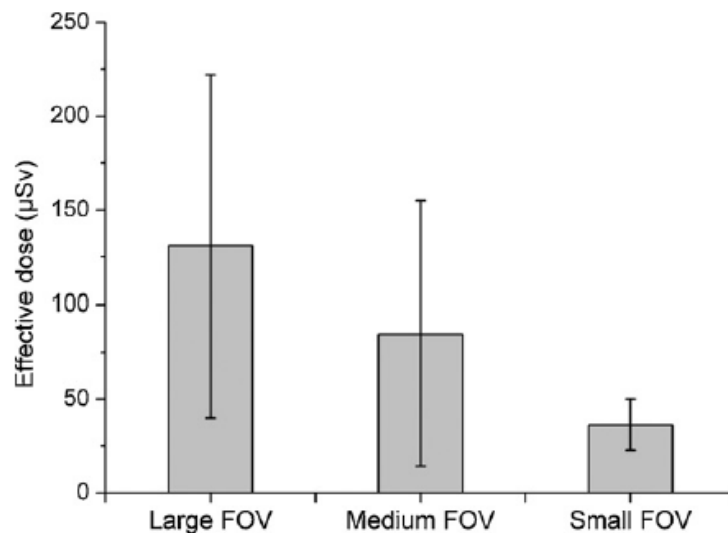
CBCT	Manufacturer	Protocol	FOV (cm)	Voltage (kV)	mAs
3D Accuitomo 170	J. Morita, Kyoto, Japan	Maxilla	10 × 5	90	87.5
		Lower jaw molar region	4 × 4	90	87.5
Galileos Comfort	Sirona Dental Systems, Bensheim, Germany	Maxillofacial	15 × 15	85	28
		i-CAT Next Generation	Imaging Sciences International, Hatfield, PA, USA	Maxillofacial	16 × 13
Iluma Elite	Imtec (3M), Ardmore, OK, USA	Mandible	16 × 6	120	18.5
		Maxillofacial	21 × 14	120	76
Kodak 9000 3D	Kodak Dental Systems, Carestream Health, Rochester, NY, USA	Upper jaw front region	5 × 3.7	70	107
		Lower jaw molar region	5 × 3.7	70	107
Kodak 9500	Kodak Dental Systems, Carestream Health, Rochester, NY, USA	Maxillofacial	20 × 18	90	108
		Dentoalveolar	15 × 8	90	108
NewTom VG	Quantitative Radiology, Verona, Italy	Maxillofacial	23 × 23	110	10.4
		NewTom VGi	Quantitative Radiology, Verona, Italy	Maxillofacial	15 × 15
PaX-Uni3D	VATECH, Yongin, Republic of Korea	Dentoalveolar	12 × 8	110	43
		Upper jaw front region	5 × 5	85	120
Picasso Trio	VATECH, Yongin, Republic of Korea	Dentoalveolar - standard dose	12 × 7	85	127
		Dentoalveolar - low dose	12 × 7	85	91
Promax3D	Planmeca Oy, Helsinki, Finland	Dentoalveolar - standard dose	8 × 8	84	169
		Dentoalveolar - low dose	8 × 8	84	19.9
Scanora 3D	Soredex, Tuusula, Finland	Dentoalveolar	10 × 7.5	85	30
		Mandible	10 × 7.5	85	30
SkyView	MyRay, Cefla Dental Group, Imola, Italy	Maxilla	10 × 7.5	85	30
		Maxillofacial	14.5 × 13.5	85	48
Veraviewepocs 3D	J. Morita, Kyoto, Japan	Maxillofacial	17 × 17	90	51.5
		Dentoalveolar	8 × 8	70	51

**Table 5**

Absorbed organ dose and effective dose for small FOV (localised) protocols.

	3D Accuitomo 170	Kodak 9000 3D	Kodak 9000 3D	Pax-Uni3D
FOV positioning	Lower jaw, molar region	Upper jaw, front region	Lower jaw, molar region	Upper jaw, front region
Red bone marrow	37	21	78	47
Thyroid	195	30	251	209
Skin	32	25	24	55
Bone surface	37	27	35	49
Salivary glands	2120	523	709	1073
Brain	37	18	290	28
Remainder	70	74	86	146
Effective dose	43	19	40	44

**Table 6**



The average effective dose of CBCT divided into subgroups dependant on the size of FOV. Standard deviations are shown for each group.

References. (In the order they appear).

Tamse A, Kaffe I, Fishel D. 1980 Zygomatic arch interference with correct radiographic diagnosis in maxillary molar endodontics. *Oral Surg*;50:563-5.

L. A. Feldkamp, L. C. Davis, and J.W. Kress, 1984 Practical cone beam algorithm, *J. Opt. Soc. Am. A*, vol. 1, pp. 612–619.

Simonton JD, Trevino E, Azevedo: 2008- Small v Large Volume CBCT in Endodontics, *Table Clinic, AAE, Vancouver.*

Pauwels.,R, Beinsbergera J, Collaert. B,Theodorakou C, Rogerse. J, Walker. A, Cockmartin, Bosmans. H, Reinhilde J, Bogaerts. R, Horner. L, The SEDENTEXCT Project Consortium 2010.- Effective dose range for dental cone beam computed tomography scanners. *Eur J Radiol* (2011), doi:10.1016/j.ejrad.2010.11.028

Bender IB, Seltzer S. 1961- Roentgenographic and direct observation of experimental lesions in bone. Part I. *J Am Dent Assoc*;62:152-60.

Bender IB, Seltzer S. 1961- Roentgenographic and direct observation of experimental lesions in bone. Part II. *J Am Dent Assoc*;62:708-16.

Goldman M, Pearson AH, Darzenta N. 1972 Endodontic success - Who's reading the radiograph. *Oral Surg*;33:432-7.

Brynolf I. Roentgenologic periapical diagnosis. IV 1970- When is one roentgenogram not sufficient. *Swed Dent J* ;63:415-23.

Lofthag-Hansen.S, Huumonen, S. Gröndahl, K. Gröndahl. H. 2007- Limited cone-beam CT and intraoral radiography for the diagnosis of periapical pathology. *Oral Surg Oral Med Oral Pathol Oral Radiol Endod*;103:114-9

Garcia de Paula-Silva. F, Hassan. B, Bezarra da Silva. L, Leonardo. M, Wu. M 2009- Outcome of Root Canal Treatment in Dogs Determined by Periapical Radiography and Cone-Beam Computed Tomography Scans. *JOE*. Vol. 35. 5. p723-726.

Tamse A, Fuss Z, Lustig J, Kaplavi J. 1999-An evaluation of endodontically treated vertically fractured teeth. *J Endod*;25:506–8.

Cohen S, Berman LH, Blanco L, Bakland L, Kim JS 2006- A demographic analysis of vertical root fractures. *J Endod*;32:1160–3

Hannig. C, Dullin. C. Hülsmann M, Heidrich. G 2005- Three-dimensional, non-destructive visualization of vertical root fractures using flat panel volume detector computer tomography: an ex vivo in vitro case report.

*Int Endo J. Vol.38 I. 12 p904-913*

*Rud. J, Omnell. K. 1970- Root fractures due to corrosion. Diagnostic aspects. Journal of European Sciences. Vol 78. I 1-4. p397-403*

*Edlund. M, Nair. M, Nair. U, 2011- Detection of Vertical Root Fractures by Using Cone-beam Computed Tomography: A Clinical Study. JOE Vol 78.I 1-4. p768-772*

*Gassner. R, Bosch.R, Emshoff.R 1999- Prevalence of dental trauma in 6000 patients with facial injuries: Implications for prevention. Oral Surg Oral Med Oral Pathol Oral Radiol Vol 87:27-33.*

*Bernardes RA, de Moraes IG, Duarte MA, Azevedo BC, de Azevedo JR, Bramante CM. 2009 Use of cone-beam volumetric tomography in the diagnosis of root fractures. Oral Surg Oral Med Oral Pathol Oral Radiol Endod.*

*Cotti E, Vargiu P, Dettori C, Mallarini G 1999- Computerized tomography in the management and follow-up of extensive periapical lesion. Endodontics and Dental Traumatology 15, 186-9.*

*Velvart P, Hecker H, Tillinger G 2001- Detection of the apical lesion and the mandibular canal in conventional radiography and computed tomography. Oral Surgery, Oral Medicine, Oral Pathology and Endodontology 92, 682–8.*

*Low K, Dula K, Bürgin W, von Arx T 2008-Comparison of Periapical Radiography and Limited Cone-Beam Tomography in Posterior Maxillary Teeth Referred for Apical Surgery Identification of root morphology and canal anatomy. JOE Vol 34. 5. p557-562.*

*Rigolone M, Pasqualini D, Bianchi L, Berutti E, Bianchi SD 2003- Vestibular surgical access to the palatine root of the superior first molar: “low-does cone-beam” CT analysis of the pathway and its anatomic variations. JOE 29, 773–5.*

*Gartner AH, Mack T, Somerlott RG, Walsh LC. 1976- Differential diagnosis of internal and external root resorption. J Endodon;2:329-34.*

*Cohenca N, Simon JH, Roges R, Morag Y, Malfaz JM (2007a) Clinical indications for digital imaging in dento-alveolar trauma. Part 1: traumatic injuries. Dental Traumatology 23, 95–104.*

*Cohenca N, Simon JH, Marhtur A, Malfaz JM (2007b) Clinical indications for digital imaging in dento-alveolar trauma. Part 2: root resorption. Dental Traumatology 23, 105–13.*

*Ahangari Z, Nasser M, Mahdian M, Fedorowicz Z, Marchesan M. 2010- Interventions for the management of external root resorption. Cochrane Database Syst Rev. 2010 Jun 16;(6):CD008003.*

*Simon JH, Enciso R, Malfaz J-M, Roges R, Bailey-Perry M, Patel A 2006- Differential diagnosis of large periapical lesions using cone-beam computed tomography measurements and biopsy. Journal of Endodontics 32, 833–7.*

*Rosenberg PA, Frisbie J, Lee J, Lee K, Frommer H, Kottal S, Phelan J, Lin L, Fisch G. 2010 Journal of Endodontics. 36(3):423-8.*

*Matherne RP, Angelopoulos C, Kulild JC, Tira D. 2008- Use of CBCT to identify root canal systems in vitro. J Endod;34:87-89.*