

Three cases of subpontic osseous hyperplasia of the mandible: A report

Mohammed N. Islam, BDS¹/Donald M. Cohen, DMD, MS, MBA²/
Matthew T. Waite, DDS, MS²/Indraneel Bhattacharyya, DDS, MSD²

Subpontic osseous hyperplasia is a relatively uncommon benign submucosal mass of normal bone found beneath a pontic. Three cases of mandibular subpontic osseous hyperplasia are described, adding to the 40 existing cases in the English-language literature. Subpontic osseous hyperplasia may represent a unique reactive osseous metaplasia in the subpontic region, with chronic stimuli and functional or occlusal stress as possible etiologies. This article aims to address the clinical significance, treatment considerations, and radiographic correlation of subpontic osseous hyperplasia. (*Quintessence Int* 2010;41:299–302)

Key words: bone, fixed prosthesis, metaplasia, subpontic osseous hyperplasia

Subpontic osseous hyperplasia (SOH) is a relatively uncommon proliferation of normal bone seen under a pontic, typically in the mandible. The etiology is not clearly understood. Clinicians should be aware of the unique clinical presentation of this condition, which does not usually necessitate a biopsy or further treatment.

CASE 1

A 65-year-old woman presented with a bony lesion under the pontic on the left mandibular ridge, in the area of the first molar. Clinical

examination revealed a firm mass in the subpontic space. A periapical radiograph revealed a mottled radiopaque and mixed radiolucent sclerotic mass under a hygienic pontic (Fig 1a). A thin radiolucent line separated the mass from the underlying bone. An alveolar ridge osteoplasty re-established a hygienic pontic. Histopathology was consistent with SOH and revealed fragments of dense lamellar normal bone with osteocytes within lacunae and fibrofatty marrow (Figs 1b to 1d).

CASE 2

A 78-year-old man complained of heaviness, tightness, and fullness in the area of the mandibular right first molar. A marginally reduced self-cleansing area under the pontic was noted. A radiograph revealed a dense radiopaque, osseous, exostosislike growth under the pontic between the mandibular right second premolar and second molar (similar to that in Fig 1a). A clinical diagnosis of SOH was made, and the patient was placed on a 6-month recall.

¹Department of Oral Pathology, Medicine, and Radiology, Indiana University, School of Dentistry, Indianapolis, Indiana, USA.

²Department of Oral and Maxillofacial Surgery and Diagnostic Sciences, University of Florida, College of Dentistry, Gainesville, Florida, USA.

Correspondence: Dr I. Bhattacharyya, Department of Oral and Maxillofacial Surgery and Diagnostic Sciences, College of Dentistry, University of Florida, PO Box 100414, Gainesville, FL 32610. Fax: 352-392-2507. Email: ibhattacharyya@dental.ufl.edu

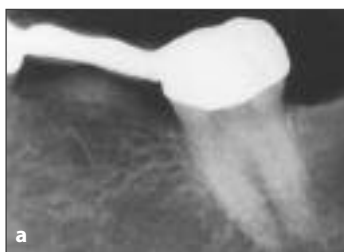

Fig 1a Case 1. Periapical radiograph exhibiting a mixed mottled radiopaque and radiolucent sclerotic mass under a hygienic pontic in the area of the mandibular left first molar, with a thin radiolucent line separating the mass from the alveolar crestal bone.

Figs 1b to 1d Case 1. Photomicrographs showing fragments of dense lamellar normal bone exhibiting osteocytes within lacunae and fibrofatty marrow, consistent with SOH (hematoxylin and eosin stain; original magnification $\times 2.5$, $\times 5$, and $\times 10$, respectively).

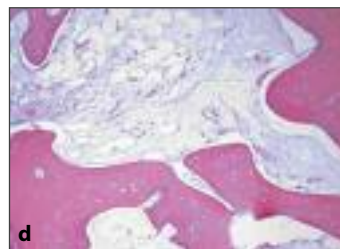
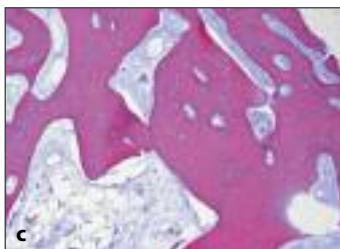
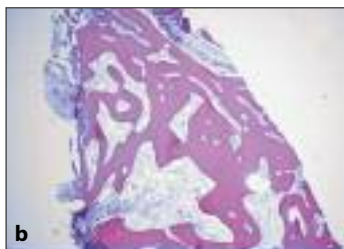Fig 2 Case 3. Intraoral clinical photographs of the prosthesis in the area of the mandibular left second premolar to second molar.

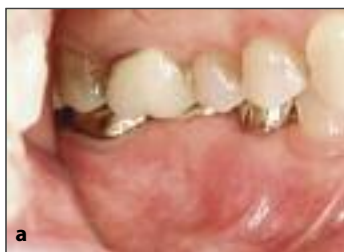

Fig 2a Buccal view with teeth in occlusion and closure of the subpontic space.

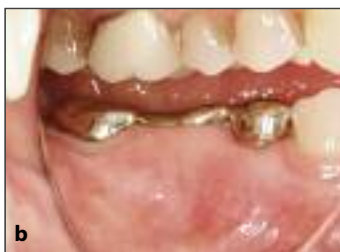

Fig 2b Buccal view with partially open jaw.

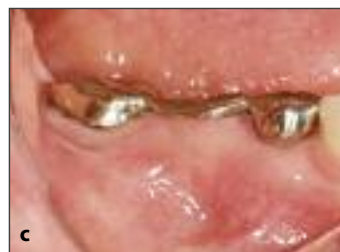

Fig 2c Buccal view with fully open jaw and soft tissue completely filling the hygiene area in the area of the first molar.

CASE 3

An 80-year-old woman presented for clinical crown lengthening for the mandibular left second molar. She had a 15-year history of alendronate sodium usage for prevention of osteoporosis. She had difficulty flossing in the area of a fixed partial denture (FPD) (Fig 2). Being a patient of record since 1993, serial radiographs were available from 1993 to 2004 (Fig 3), in addition to those taken before crown lengthening in 2006 and for follow-up in 2007. Radiographs revealed a bony

expansion or protuberance beneath the pontic. A clinical diagnosis of SOH was determined. It was decided to follow the patient to monitor the area of the mandibular left second molar for osteonecrosis after crown lengthening surgery.

The patient has since discontinued alendronate sodium permanently upon advice from her physician and remains healthy. Neither a change in the size of the subpontic hyperplasia nor evidence of osteochemonecrosis in the surgical area have been noted on follow-up visits to date.

Fig 3 Case 3. Intraoral periapical radiographs.

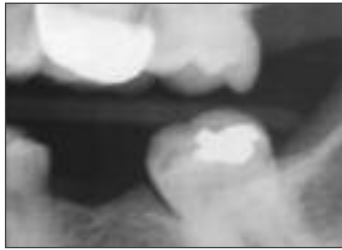


Fig 3a Partially edentulous area of the mandibular left first molar exhibiting a disto-occlusal restoration on the second premolar (1994).

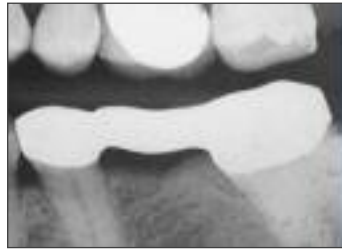

Fig 3b No evidence of bony deformity (1996).

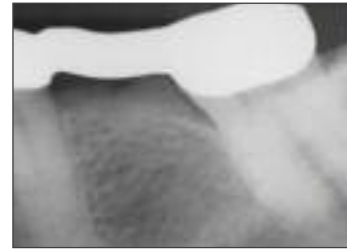

Fig 3c Slight evidence of elevated subpontic mixed radiodensity (1997).

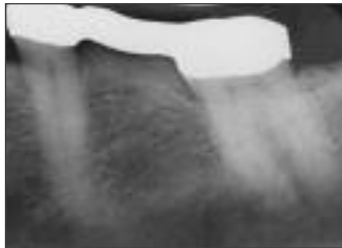


Fig 3d Well-delineated subpontic osseous elevation (2002).

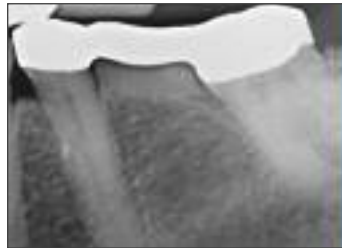


Fig 3e Markedly radiopaque osseous elevation (2004).

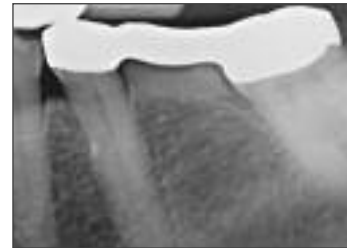


Fig 3f Markedly radiopaque osseous elevation with a definitive linear boundary between the opacity and the underlying alveolar bone (2006).

DISCUSSION

Subpontic osseous hyperplasia was first reported by Calman et al as an unusual anomaly in 1971.¹ It commonly presents as a nodular, elevated growth or protuberance of crestal bone beneath the pontic of an FPD.² SOH is similar histopathologically to other exostoses such as tori and consists of mature dense lamellar osseous tissue continuous with the underlying normal bone. The clinicoradiographic and histomorphologic presentation of SOH in these patients is consistent with 40 (39 mandibular and 1 maxillary) previously reported cases found in the English-language literature.² The only notable exception was case 3, with a history of long-term bisphosphonate use.

The exact etiology of SOH remains unknown. SOH may be genetic in origin as in other exostoses, or it may have a multifactorial etiology.² It may be related to chronic gingival irritation leading to subpontic bone proliferation.² SOH is usually uniquely unilateral, even when patients have bilateral pontics.³ The placement of an FPD may distribute the stress or functional load to the abutment and the surrounding bony tissue, thereby stimulating osseous proliferation and subsequent bone formation.⁴ This theory is also supported by evidence of spontaneous remission of SOH after loss of an FPD, thus underscoring the above point, and is well-documented.⁴ SOH may compromise subpontic hygiene and lead to subsequent prosthesis failure. It also has the potential to recur, thus requiring a radiographic follow-up.⁴

For case 1, no recurrence was noted. Cases 2 and 3 have been placed on routine radiographic follow-up. In case 3, the patient was on oral bisphosphonates, and the implication of this medication on osseous surgery has been documented in the literature.⁵ The possible role bisphosphonate plays in enlargement of SOH is speculative at best, and this should be considered when patients are evaluated for treatment.

The recognition of SOH by general dentists or other dental professionals during clinical and/or radiographic evaluation is important, and SOH should be included in the differential diagnosis of bony proliferations in relation to a prosthesis. Clinicians should be aware that SOHs do not usually require treatment, and unnecessary biopsy and related expenses should be avoided.

REFERENCES

1. Calman HI, Eisenberg M, Grodjesk JE, Szerlip L. Shades of white: Interpretations of radiopacities. *Dent Radiogr Photogr* 1971;44:3–10.
2. Frazier KB, Baker PS, Abdelsayed R. A case report of subpontic osseous hyperplasia in the maxillary arch. *Oral Surg Oral Med Oral Pathol Oral Radiol Endod* 2000;89:73–76.
3. Daniels WC. Subpontic osseous hyperplasia: A five-patient report. *J Prosthodont* 1997;6:137–143.
4. Sutherland JK, Holland GA, Sluder TB, White JT. A photoelastic analysis of the stress distribution in bone supporting fixed partial dentures of rigid and nonrigid design. *J Prosthet Dent* 1980;4:616–623.
5. Sanna G, Preda L, Bruschini R, et al. The role of surgery in jaw bone necrosis associated with long-term use of bisphosphonates. *Acta Oncol* 2007; 25:1–3.

Copyright of Quintessence International is the property of Quintessence Publishing Company Inc. and its content may not be copied or emailed to multiple sites or posted to a listserv without the copyright holder's express written permission. However, users may print, download, or email articles for individual use.