

THE SUCCESS OF ENDODONTIC THERAPY — HEALING AND FUNCTIONALITY

Shimon Friedman, DMD; and Chaim Mor, DMD

ABSTRACT

Current, relevant knowledge on the outcome of endodontic therapy is key to clinical decision making, particularly when endodontic treatment is weighed against tooth extraction and replacement. Inherent to reviewing the outcome is a definition of "success" in relation to the goals of therapy. As the specific goal set out by the individual patient may either be healing/prevention of disease (apical periodontitis) or just functional retention of the tooth, the potential for both healing and functionality is reviewed. Based on selected follow-up studies that offer the best evidence, the chance of teeth without apical periodontitis to remain free of disease after initial treatment or orthograde retreatment is 92 percent to 98 percent. The chance of teeth with apical periodontitis to completely heal after initial treatment or retreatment is 74 percent to 86 per-

cent, and their chance to be functional over time is 91 percent to 97 percent. Thus there does not appear to be a systematic difference in outcome between initial treatment and orthograde retreatment. The outcome of apical surgery is less consistent than that of the non-surgical treatment. The chance of teeth with apical periodontitis to completely heal after apical surgery is 37 percent to 85 percent, with a weighted average of approximately 70 percent. However, even with the lower chance of complete healing, the chance for the teeth to be functional over time is 86 percent to 92 percent. Considering the favorable outcome, conservative endodontic therapy, both nonsurgical and surgical,



Authors / Shimon Friedman, DMD, is professor and head of Discipline of Endodontics and director of MSc program in Endodontics at the University of Toronto Faculty of Dentistry, Canada.

Chaim Mor, DMD, is a lecturer in the Department of Endodontics at Hebrew University — Hadassah Faculty of Dental Medicine in Jerusalem, Israel.

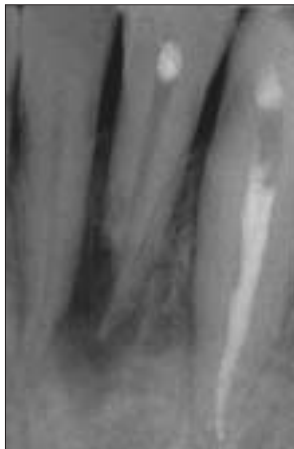

Figure 1a. Outcome classified as “healed.” Pre-operative radiograph of a mandibular lateral incisor with apical periodontitis and associated apical external resorption.

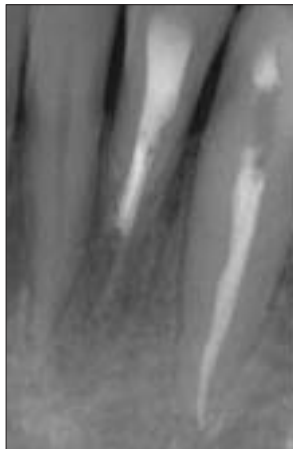
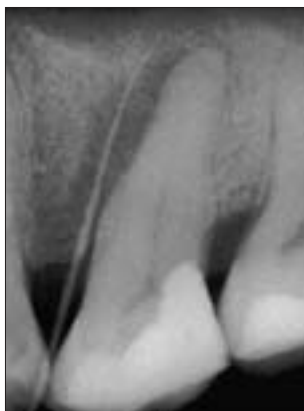
Figure 1b. Follow-up radiograph at one year; the radiolucency has completely resolved and the tooth is asymptomatic, indicating it has healed.

(Reprinted with permission from Friedman S. Prognosis of initial endodontic therapy. Endodontic Topics 2:59-88, 2002)



2a. Outcome classified as “healed.” Pre-operative radiograph of a maxillary second molar with apical periodontitis extending along the mesial root surface, and associated sinus tract (traced with a gutta-percha cone).

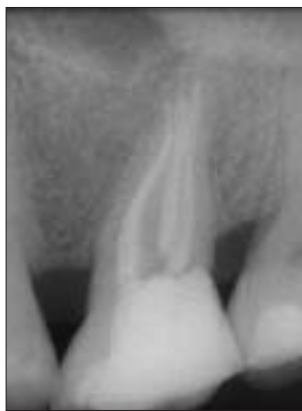

Figure 2b. Follow-up radiograph at one year; the radiolucency has completely resolved and the tooth is asymptomatic, indicating it has healed.

(Reprinted with permission from Friedman S. Prognosis of initial endodontic therapy. Endodontic Topics 2:59-88, 2002.)

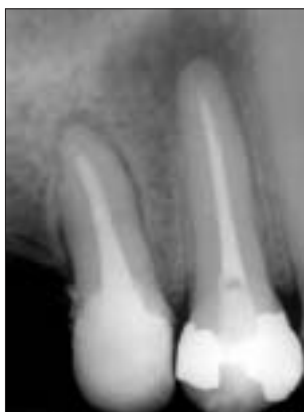

Figure 3a. Outcome classification as “healed” vs. “healing.” Immediate post-operative radiograph of maxillary first and second premolars with apical periodontitis.

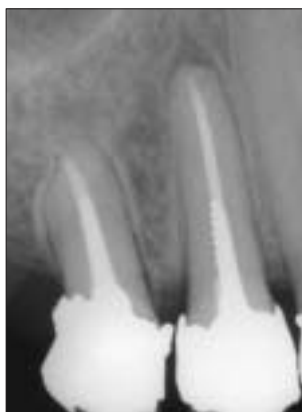

Figure 3b. Follow-up radiograph at one year; both teeth are asymptomatic. While the second premolar is classified as healed (see **Figures 1 and 2**), the reduction of the radiolucency in the first premolar is indicative of heal-

ing in progress (see also **Figures 4 and 5**). Regrettably, both the restorations are inadequate.

(Reprinted with permission from Friedman S. Prognosis of initial endodontic therapy. Endodontic Topics 2:59-88, 2002.)

Imagine the following scenario. Mrs. L. K. suffered a complicated fracture of her left wrist. After receiving emergency care, she consulted with an orthopedic surgeon who offered her two treatment options, each with its specific benefits and risks. The first option was to treat the broken wrist, with an 80 percent chance of “success” (complete healing of the fracture) but with the possibility of sporadic discomfort and some movement restriction, and the risk of re-fracture upon another impact. The second was to amputate the hand and replace it with a state-of-the-art prosthesis, with 97 percent chance of “success” (complete integration and functionality of the prosthesis) without discomfort or movement restriction. Although impressed by the prosthetic device’s functionality and hand-like appearance, Mrs. L. K. selected the first treatment option without any hesitation.

The analogy of this scenario applies to recent articles¹⁻³ debating endodontic therapy of teeth versus implant-supported single tooth replacement, and comparing the “success” rates of both procedures. The main argument in that debate is the “success” rate of endodontic therapy — initial treatment, orthograde retreatment, and apical surgery. Often the quoted “success” rates are irrelevant to the debate, because they are outdated or derived from articles providing a low level of evidence. Importantly, the debate itself is often irrelevant, comparing a functional organ with an artificial prosthetic device, however perfect. While the latter problem concerns the balancing of ethics against pragmatism, the former is a matter of possessing the relevant knowledge regarding endodontic therapy and single-tooth implants, based on current information.

The objective of this article is to provide current, relevant review of the “success” of endodontic treatment pro-

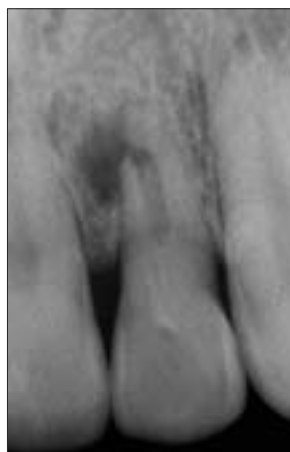

Figure 4a. Outcome classified as "disease." Pre-operative radiograph of a maxillary lateral incisor with apical periodontitis.

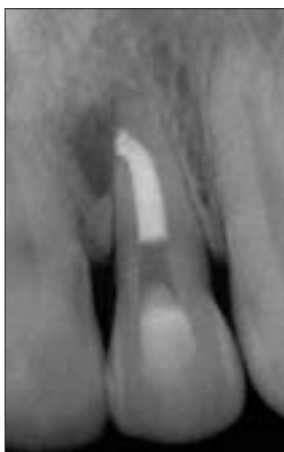

Figure 4b. Immediate post-operative radiograph.

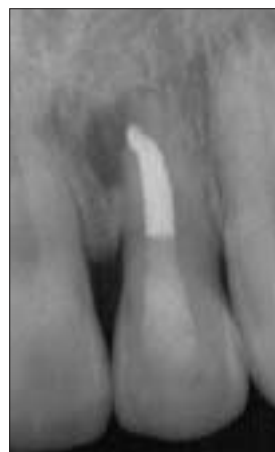

Figure 4c. Follow-up radiograph at one year; the tooth is asymptomatic but the radiolucency has not been reduced, indicating persistence of the disease.

(Reprinted with permission from Friedman S. Prognosis of initial endodontic therapy. *Endodontic Topics* 2:59-88, 2002.)

cedures, and thus the knowledge basis for case selection regarding options of endodontic therapy.

What is "Success"?

The non-specific term "success" is ambiguous — it has a different meaning when referring to different dental treatment procedures, such as endodontic therapy, periodontal therapy or implants.⁴ Undiscerning use of the term "success" confuses communication within the profession and it may misguide patients contemplating alternative treatments, particularly endodontic therapy versus extraction and tooth replacement. The definition of "success" and the related rates differ considerably for the various procedures in dentistry. The uninformed patient weighing one "success" rate against the other, may erroneously assume their definitions are comparable and select the treatment alternative that offers the "higher number" and thus appears to suggest a better chance of "success."⁴

Even for endodontic therapy, the definition of "success" has been ambiguous, with requirements ranging from stringent (radiographic and clinical normalcy) to lenient (only clinical

normalcy).^{4,5} Clearly, the more lenient definition increases the "success" rate in comparison with the more stringent one. For example, in a follow-up study after endodontic initial treatment and retreatment, Friedman et al,⁶ report 78 percent complete healing (radiographic and clinical normalcy) and 16 percent incomplete healing (clinical normalcy combined with reduced radiolucency). Their success rate can be interpreted as 78 percent using the stringent definition, or 94 percent using the more lenient definition.

To resolve this long-lasting dilemma, one should remember that "success" is invariably defined by the goal(s) established to be achieved. To use another analogy, one can reflect on two athletes preparing for the Olympic games — the first's goal is to attend the games, while the second's goal is to win. For the first athlete, just participating in the Olympics is a "success," irrespective of placement on the scoreboard. For the second athlete, only winning the gold medal is a "success" — winning a silver medal may feel like a failure. Just like in this analogy, the confusion resulting from the ambiguity of the term "success" with regard to endodontic therapy can be easily avoid-

ed by defining the specific goals and expected outcomes of treatment.⁴

The usual goal of endodontic therapy is to prevent or heal disease, apical periodontitis.⁷ Accordingly, endodontic treatment outcomes should be defined in reference to healing and disease^{5,8,9} as follows:

n *Healed*: Both the clinical and radiographic presentations are normal (**Figures 1 and 2**).

n *Healing*: Because healing is a dynamic process, reduced radiolucency combined with normal clinical presentation can be interpreted as healing in progress (**Figure 3**).

n *Disease*: Radiolucency has emerged or persisted without change, even when the clinical presentation is normal (**Figure 4**), or clinical signs or symptoms are present, even if the radiographic presentation is normal.

Although curing of disease is the ultimate goal of therapy, patients are autonomous to set less demanding goals for therapy, such as prevention or elimination of symptoms, or retention of the tooth. The latter is particularly applicable when the patient is motivated to attempt therapy even though the projected prognosis is unfavorable because of complicating factors.

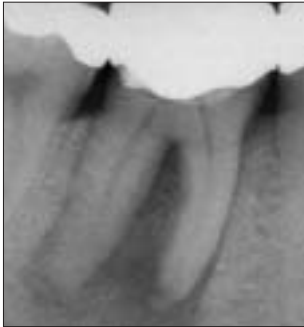

Figure 5a. Outcome classified as “functional.” Pre-operative radiograph of a mandibular first molar with extensive apical periodontitis.

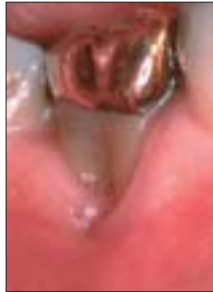

Figure 5b. Clinical view of the gingival recession on the buccal aspect of the tooth, coupled with probing depth apical to the root tips, suggests total loss of the buccal bone plate. The projected prognosis is poor.

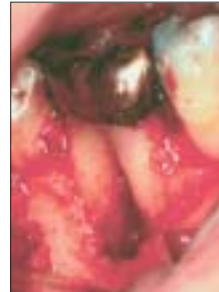

Figure 5c. Clinical view after reflection of a full-thickness flap reveals the extent of bone loss on the buccal aspect of the tooth. Advised of the poor prognosis, the patient decided to proceed with treatment in an attempt to retain the tooth in function as long as possible.

Accordingly, the endodontic treatment outcome can be defined as tooth retention,⁴ as follows:

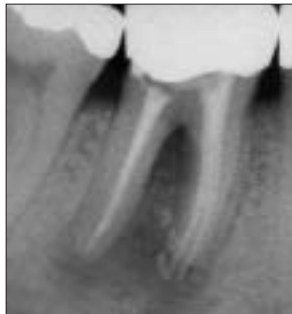n **Functional retention:** The clinical presentation is normal, while radiolucency may be absent or present — newly emerged or persisting (**Figures 5 and 6**).

Considering the above, the outcome of endodontic therapy, or its “success,” is usually defined as the healing of disease unless it is specifically defined as tooth retention in asymptomatic function.⁴

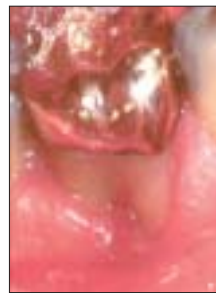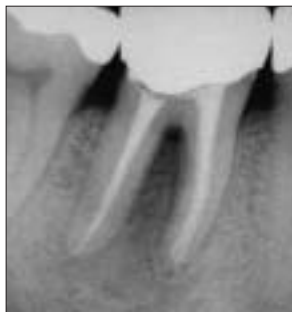Relevant Information on Endodontic Treatment Outcomes

The potential for healing and functional retention of endodontically treated teeth can be gleaned from numerous follow-up studies of selected populations, exposed to initial treatment (**Figure 7**), orthograde retreatment (**Figure 8**) and apical surgery (**Figure 9**). Cumulatively, those studies include data from thousands of treated cases. Comprehensive reviews of those studies^{4,5} reveal inconsistencies and large variability in the reported outcomes,^{4,5} resulting from diversity in material composition, treatment procedures, and methodology.^{4,5} Because of that diversity, not all published studies are equally valuable as a source of valid and clinically relevant information. As suggested by one review,⁴ “undiscerning review of all the existing studies can be ineffective and even misleading.”

The fact that clinical studies vary with regard to the level of evidence they



Figures 5d and e. Immediate post-operative radiograph after root canal therapy (root filling with vertical compaction of warm gutta-percha), followed by placement of a resorbable guided tissue regeneration membrane.



Figures 5f and g. Follow-up radiograph and clinical view at six months; the radiolucency is considerably reduced and the gingival tissue appears to be healed. Although the prognosis remains poor, the tooth being functional achieves the goals of therapy as set by the patient, and should be considered as success.

(Reprinted with permission from Friedman S. Prognosis of initial endodontic therapy. Endodontic Topics 2:59-88, 2002.)

provide is well recognized in the current concept of evidence-based health care.¹⁰ Reviewed studies, therefore, must be appraised according to well-defined criteria to differentiate them according to the level of evidence.¹¹ Such appraisal criteria can also be applied to select those endodontic outcome studies that provide the best evidence.

In a review article on the prognosis of initial treatment of apical periodontitis, Friedman⁴ used the accepted guidelines for appraisal of studies.¹² The appraisal criteria were grouped into four general

parameters, comprising the following: cohort at inception and end-point of study, exposure (treatment), outcome assessment, and analysis/reporting of data. Studies conforming to three out of the four parameters were selected for review, while others were excluded. A similar approach was subsequently used to review studies on orthograde retreatment¹³ and apical surgery.¹⁴

Tables 1-3 list the studies selected in the reviews as described above, for initial treatment,^{8,9,15-27} orthograde retreatment^{13,15,16,20,28,29} and apical

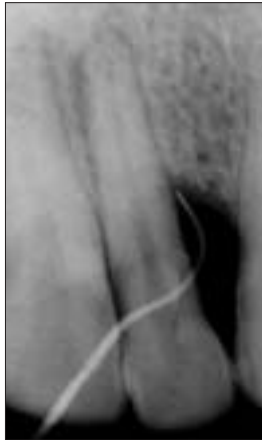


Figure 6a. Outcome classified as "functional." Pre-operative radiograph of a mandibular lateral incisor with apical periodontitis and a palatal developmental groove associated with an extensive bone loss. Prognosis of this condition is recognized as hopeless; however, the patient decided to proceed with treatment in an attempt to retain the tooth in function as long as possible.

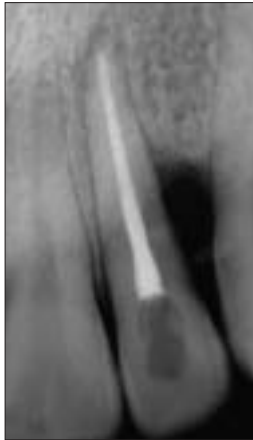
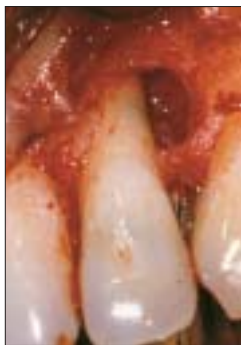
Figure 6b. Immediate post-operative radiograph after root canal therapy.



Figures 6c and d. Clinical view after reflection of buccal and palatal full-thickness flaps, revealing the extent of bone loss and the developmental groove.

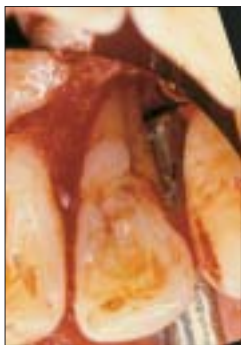
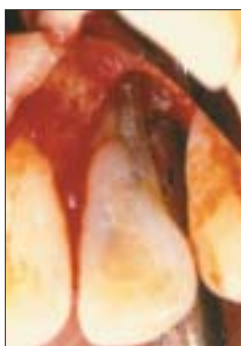
Figure 6d.



Figures 6e and f. Immediate post-operative clinical view and radiograph after filling of the groove with varnish and amalgam.

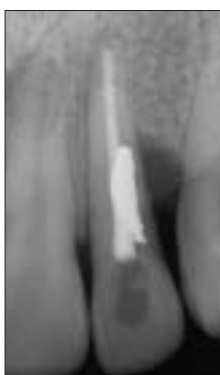

Figure 6f.

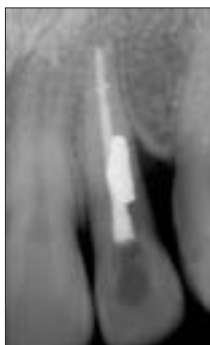

Figure 6g. Follow-up radiograph at four years; the apical periodontitis has healed, and the crestal bone margin has stabilized. Although the prognosis remains questionable, the tooth being functional achieves the goals of therapy as set by the patient.

(Reprinted with permission from Friedman S, Goultshin J. The radicular palatal groove — a therapeutic modality. Endod Dent Traumatol 4:282-6, 1988.)

surgery,^{14,29-33} respectively. The outcomes in the tables are interpreted from those reported by the original authors, as follows: (i) combined clinical and radiographic normalcy is classified as "healed"; (ii) reduced radiolucency combined with clinical normalcy is classified as "healing"; and (iii) the rate of teeth with no signs and symptoms is classified as "functional" — for several studies this is simply the sum of "healed" and "healing" (when both are available), while for others it also includes teeth where the radiolucency remained unchanged.

Treatment Outcome in Teeth Presenting Without Apical Periodontitis

Teeth that present without apical periodontitis may have irreversible pulpitis, pulp necrosis, or a dubious root filling.⁴ Accordingly, they undergo initial treatment or orthograde retreatment with the goal of preventing emergence of apical periodontitis. The outcomes of initial treatment and retreatment are presented separately in **Tables 1 and 2**, respectively. Consistently high percentages of teeth that remained healed after follow-up of up to 10 years can be seen in both tables. Excluding studies that appear to be outliers for initial treatment,^{16,25} it can be concluded that the chance of teeth without apical periodontitis to remain free of disease is 92 percent to 98 percent, both after initial treatment and orthograde retreatment. The rate of functional teeth is not indicated in these studies; however, it is likely to be even higher than the healed rate. Considering the generally asymptomatic nature of apical periodontitis,^{13,14,26,27} it can be assumed that only a few of the teeth with emerged disease are symptomatic.

Treatment Outcome in Teeth Presenting With Apical Periodontitis

Teeth that present with apical periodontitis may have a primary infection

Table 1

SELECTED FOLLOW-UP STUDIES ON THE OUTCOME OF ENDODONTIC INITIAL TREATMENT

Study	Follow-up (years)	Cases observed	Teeth without	Teeth with		Functional ^a (%)
			Apical Periodontitis	Healed (%)	Apical Periodontitis	
Strindberg 1956	0.5-10	258	Healed (%)	80	—	—
Engström et al 1964	4-5	221	88	73	—	—
Kerekes & Tronstad 1979	3-5	491	97	90	—	—
Byström et al 1987	2-5	79	—	85	9	94
Ørstavik et al 1987	1-4	543	95	—	—	—
Eriksen et al 1988	3	121	—	82	9	91
Sjögren et al 1990	8-10	471	96	86	—	—
Ørstavik 1996	4	599	94	75	13	88
Sjögren et al 1997	<5	53	—	83	—	—
Trope et al 1999	1	76	—	80	—	—
Weiger et al 2000	1-5	67	—	78	16	94
Hoskinson et al 2002	4-5	200	88	74	—	97
Peters & Wesselink 2002	1-4.5	38	—	76	21	97
Friedman et al 2003	4-6	120	92	74	18	97
Farzaneh et al 2004	4-6	242	94	79	—	95

^a Proportion of all teeth, with and without apical periodontitis

of the root canal system, or a residual or subsequent infection after endodontic treatment. Accordingly, they undergo initial treatment, orthograde retreatment, or apical surgery with the goal of healing of apical periodontitis. The outcomes of those treatment procedures are presented separately in **Tables 1, 2** and **3**, respectively.

Even among the selected studies on the outcome of initial treatment (**Table 1**) and orthograde retreatment (**Table 2**), there is some variability in the reported results. The “healed” rates up to 10 years after therapy, range from 73 percent¹⁶ to 90 percent¹⁷ for initial treatment, and from 74 percent²⁸ to 86 percent¹³ for orthograde retreatment. This disparity is considerably smaller

than that observed across all studies for initial treatment (46 percent to 91 percent, **Figure 7**) and retreatment (43 percent to 86 percent, **Figure 8**). Because the selected studies are rather uniform in outcome assessment, this variability may be related to differences in case selection, in requiring a negative bacterial culture before root filling, and in restoration after treatment.⁴ Excluding studies that appear to be outliers, on initial treatment¹⁷ and on orthograde retreatment,^{20,29} as well as teeth with perforations before retreatment,¹³ it can be concluded that the chance of teeth with apical periodontitis to completely heal is 74 percent to 86 percent, after both initial treatment and orthograde retreatment. The fact that apical peri-

odontitis has a similar potential to heal after initial treatment and orthograde retreatment challenges the historic perception, of the latter having a poorer prognosis than the former.

Seven of the studies on initial treatment (**Table 1**) and one study on retreatment (**Table 2**) reveal that over 88 percent of the teeth are “functional,” with the disease mostly healed or healing. It can be assumed that in additional teeth disease persists without symptoms, as in 5 percent of the teeth included in the study by Friedman et al;²⁶ thus the rate of functional teeth probably approaches or even exceeds 95 percent.^{24,26,27} Excluding one study on initial treatment that appears to be an out-

Continued on Page 500

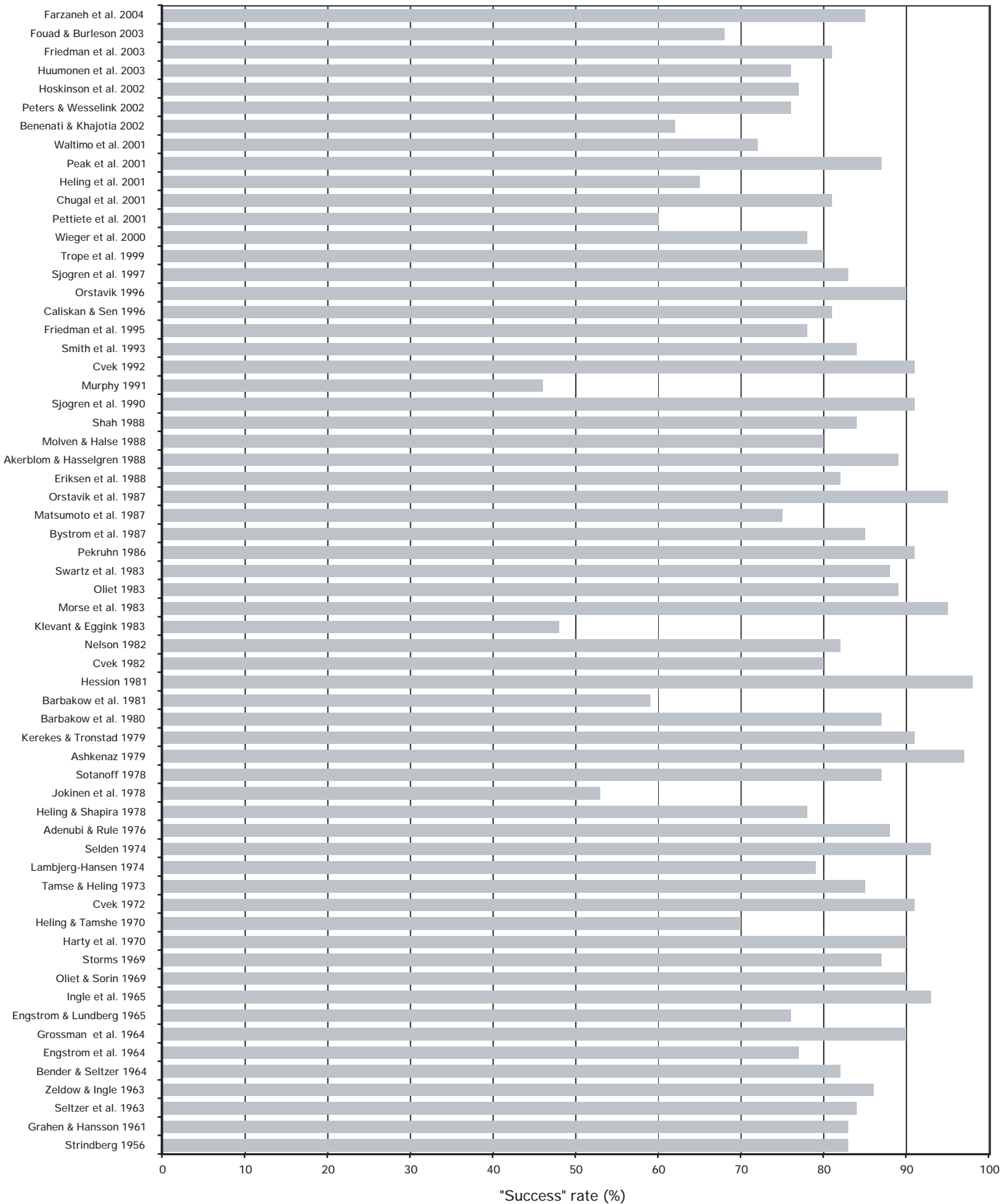


Figure 7. Graphic representation of the reported success rates in follow-up studies after endodontic initial treatment, from 1956 till 2004.

Continued from Page 498

lier,⁹ it can be concluded that the chance of teeth with apical periodontitis to remain in asymptomatic function is 91 percent to 97 percent, after both initial treatment and orthograde retreatment. These figures are certainly at par

with the "success" rate reported for single-tooth implant-supported replacement.³⁴ Clearly, then, in teeth with apical periodontitis, a good restorative and periodontal prognosis and no pre-operative perforation, conservative endodontic therapy is definitely justified

and should be attempted; tooth extraction and replacement should not be considered unless the patient is not motivated to retain the tooth.

Among the selected studies on the outcome of apical surgery (Table 3) the variability in the reported results

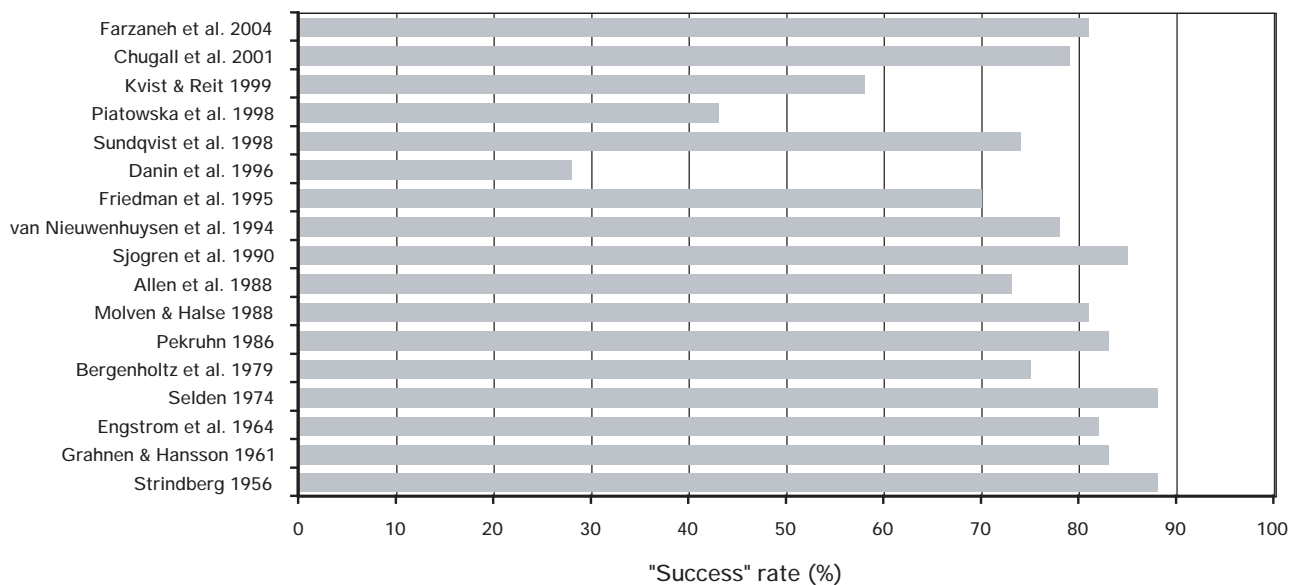


Figure 8. Graphic representation of the reported success rates in follow-up studies after endodontic orthograde retreatment, from 1956 till 2004.

Table 2

SELECTED FOLLOW-UP STUDIES ON THE OUTCOME OF ENDODONTIC ORTHOGRADE RETREATMENT

Study	Follow-up (years)	Cases observed	Teeth without Apical Periodontitis		Teeth with Apical Periodontitis		Functional ^a (%)
			Healed (%)	Healed (%)	Healing (%)		
Strindberg 1956	0.5-10	187	95	84	—	—	
Engström et al 1964	4-5	153	93	74	—	—	
Sjögren et al 1990	8-10	266	98	62	—	—	
Sundqvist et al 1998	4	54	—	74	—	—	
Kvist & Reit 1999	4	47	—	58	—	—	
Farzaneh et al 2004	4	103	97	86 ^b	6	93	

^aProportion of all teeth, with and without apical periodontitis
^bExcluding teeth with pre-operative perforations (78 percent healed with perforated teeth included)

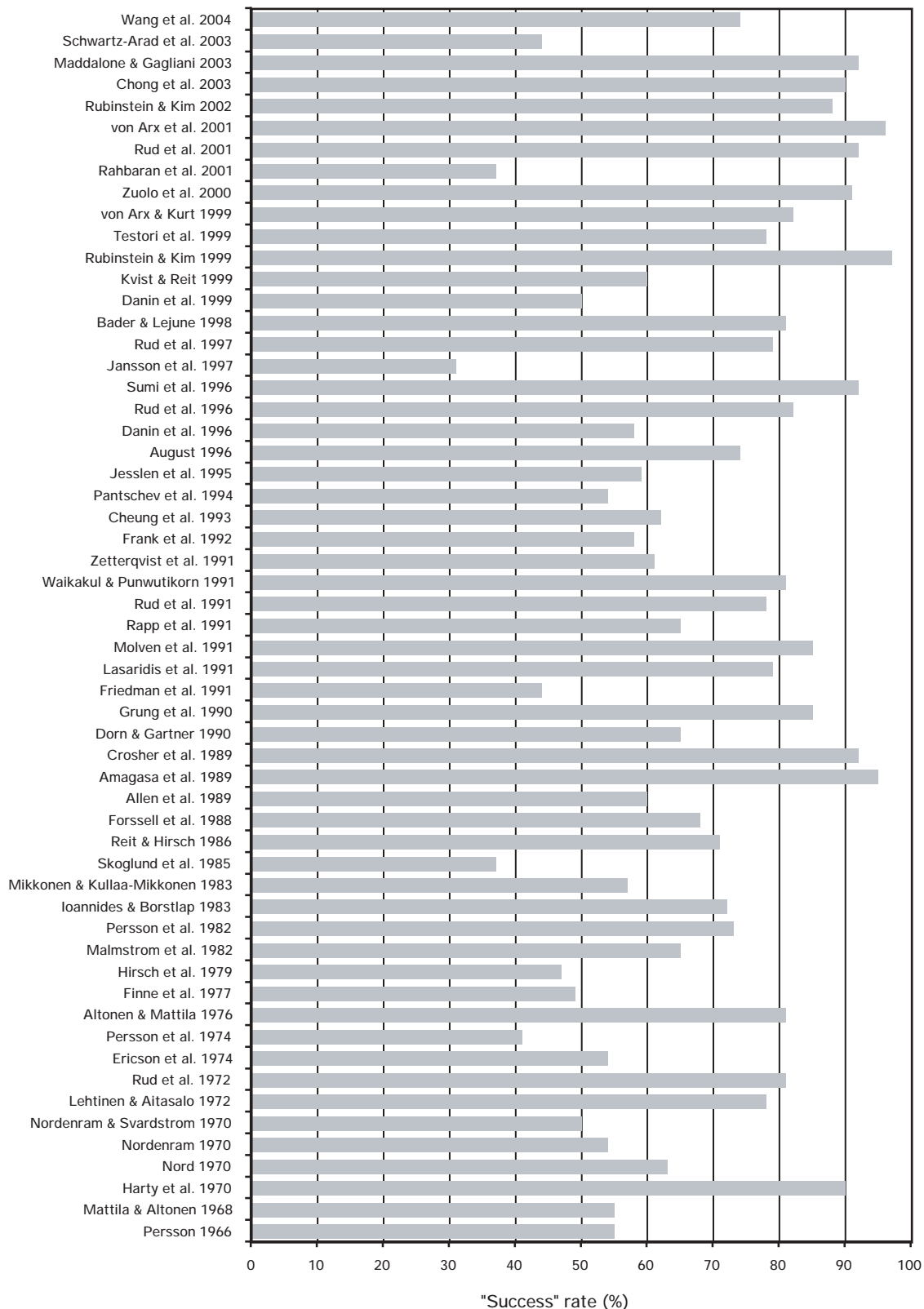


Figure 9. Graphic representation of the reported success rates in follow-up studies after apical surgery, from 1966 till 2004.

Table 3

SELECTED FOLLOW-UP STUDIES ON THE OUTCOME OF APICAL SURGERY

Study	Follow-up (years)	Cases observed	Healed (%)	Healing (%)	Functional (%)
Molven et al 1991	1-8	222	85	17	92
Jansson et al 1997	1-1.3	62	31	55	86
Kvist & Reit 1999	4	45	60	—	—
Zuolo et al 2000	1-4	102	91	—	—
Rahbaran et al 2001	≥4	129	37	33	70
Wang et al 2004	4-8	94	74	—	91

remains large. The “healed” rates, up to eight years after surgery, range from 31 percent³¹ to 91 percent.³² This disparity is comparable to that observed across all studies for apical surgery (31 percent to 97 percent, **Figure 9**). In regard to apical surgery, this variability may be related to differences in case selection, in percentage of teeth undergoing repeat surgery,³⁵ in type (initial or retreatment) and quality of the previous endodontic treatment,^{5,14} and possibly, also in root-end preparation and filling techniques. Excluding two studies that appear to be outliers,^{31,32} the chance of teeth with apical periodontitis to completely heal after apical surgery appears to be 37 percent to 85 percent. To overcome this wide range and draw more definitive conclusions from the selected studies, a weighted average can be calculated.³⁶ Including the outlier studies^{31,32} the average is 66 percent, and excluding these studies, the average is 69 percent. It can be concluded, therefore, that the surgical treatment is less predictable than the nonsurgical treatment, with an approximate 70 percent chance for teeth to heal.

Three of the studies reveal that 70 percent to 92 percent of the teeth show the disease to be healed or healing (**Table 3**). Because in additional

teeth disease most likely persists without symptoms, the rate of “functional” teeth after apical surgery approximates 90 percent (**Table 3**). Excluding one study that appears to be an outlier,³³ it can be concluded that the chance of teeth with apical periodontitis to remain in asymptomatic function after apical surgery is 86 percent³¹ to 92 percent.³⁰ These figures may be considered lower than those for nonsurgical endodontic therapy. Nevertheless, they suggest that, for teeth with apical periodontitis and a good periodontal prognosis, even apical surgery is justified and should be attempted rather than contemplating tooth extraction and replacement, unless the patient is not motivated to retain the tooth.

Case Selection

Selection of cases for endodontic therapy takes into consideration the prognosis of the endodontic, restorative and periodontal procedures, but also health and socio-economic factors. Contraindications to treatment include non-restorable and periodontally hopeless teeth, patients with extensive dental problems and restricted resources (that have to be utilized so as to benefit as many teeth as possible), and medically compromised patients at high-risk for infection.

Criteria used for case selection can influence the outcome of endodontic therapy. It can be generalized, however, that in teeth presenting without apical periodontitis, the chance to prevent disease in the long-term is excellent. Even in teeth presenting with apical periodontitis, the prognosis is good whether they are exposed to initial treatment, orthograde retreatment or apical surgery — the chance of complete healing is reasonably high, and the chance for the tooth remaining asymptomatic and functional over time is truly excellent, provided that the tooth is promptly and well restored. An asymptomatic functional state, although not a measure of healing, allows the tooth to be retained without necessitating extraction. *This clear, even if not optimal benefit should be routinely communicated to patients when endodontic therapy is weighed against tooth extraction and replacement with a prosthetic device.*

Summary

In summary, the concerns regarding the success of endodontic therapy are unsupported and misguided. The success of endodontic therapy, in terms of healing and functionality, is very good for both teeth without and with apical periodontitis. Therefore,

the most appropriate form of endodontic therapy should be attempted whenever feasible, and generally preferred over tooth extraction and replacement. **CDA**

References / 1. Curtis DA, Lacy A, Chu R, Richards D, Plesh O, Kasrovi P, Kao R, Treatment planning in the 21st century: What's new? *J Cal Dent Assoc* 30:503-10, 2002.

2. Matosian GS, Treatment planning for the future: Endodontics, posts and core, and periodontal surgery - or an implant? *J Cal Dent Assoc* 31:323-5, 2003.

3. Somborac M, Implant treatment versus endodontic retreatment: A contemporary dilemma. *Oral Health* Oct: 8-15, 2003.

4. Friedman S, Prognosis of initial endodontic therapy. *Endodontic Topics* 2:59-88, 2002.

5. Friedman S, Treatment outcome and prognosis of endodontic therapy. *Essential Endodontology: Prevention and Treatment of Apical Periodontitis. Oxford: Blackwell Science, 1998.*

6. Friedman S, Löst C, Zarrabian M, Trope M, Evaluation of success and failure after endodontic therapy using glass ionomer cement sealer. *J Endodon* 21:384-90, 1995.

7. Ørstavik D, Pitt Ford TR, Apical periodontitis: Microbial infection and host responses. *Essential Endodontology: Prevention and Treatment of Apical Periodontitis. Oxford: Blackwell Science 1998.*

8. Byström A, Happonen RP, Sjögren U, Sundqvist G, Healing of periapical lesions of pulpless teeth after endodontic treatment with controlled asepsis. *Endod Dent Traumatol* 3:58-3, 1987.

9. Ørstavik D, Time-course and risk analyses of the development and healing of chronic apical periodontitis in man. *Int Endod J* 29:150-5, 1996.

10. Sackett DL, Richardson W, Rosenberg W, Haynes R, Evidence-based medicine: how to practice and teach EBM. *London: Churchill Livingstone 1997.*

11. Anderson JD, Need for evidence-based practice in prosthodontics. *J Pros Dent* 83:58-5, 2000.

12. Department of Clinical Epidemiology and Biostatistics, McMaster University Health Science Centre. How to read clinical journals. III. To learn the clinical course and prognosis of disease. *Can Med Assoc J* 124:869-2, 1981.

13. Farzaneh M, Abitbol S, Friedman S, Treatment outcome in Endodontics: The Toronto Study. Phases I and II: Orthograde Retreatment. *J Endodon* 2004, in press.

14. Wang NC, Knight K, Dao TT, Friedman S, Treatment outcome in Endodontics: The Toronto Study. Phases I and II: Apical Surgery. *J Endodon* 2004, submitted.

15. Strindberg LZ, The dependence of the results of pulp therapy on certain factors. An analytic study based on radiographic and clinical follow-up examination. *Acta Odontol Scand* 14:suppl. 21, 1956.

16. Engström B, Hard AF, Segerstad L, Ramstrom G, Frostell G, Correlation of positive cultures with the prognosis for root canal treatment. *Odontol Rev* 15, 257-70, 1964.

17. Kerekes K, Tronstad L, Long-term results of endodontic treatment performed with a standardized technique. *J Endodon* 5:83-90, 1979.

18. Ørstavik D, Kerekes K, Eriksen HM, Clinical performance of three endodontic sealers. *Endod Dent Traumatol* 3:178-6, 1987.

19. Eriksen HM, Ørstavik D, Kerekes K, Healing of apical periodontitis after endodontic treatment using three different root canal sealers. *Endod Dent Traumatol* 4:114-7, 1988.

20. Sjögren U, Hägglund B, Sundqvist G, Wing K, Factors affecting the long-term results of endodontic treatment. *J Endodon* 16:498-4, 1990.

21. Sjögren U, Figdor D, Persson S, Sundqvist G, Influence of infection at the time of root filling on the outcome of endodontic treatment of teeth with apical periodontitis. *Int Endod J* 30:297-6, 1997.

22. Trope M, Delano O, Ørstavik D, Endodontic treatment of teeth with apical periodontitis: Single vs. multivisit treatment. *J Endodon* 25:345-50, 1999.

23. Weiger R, Rosendahl R, Löst C, Influence of calcium hydroxide intracanal dressings on the prognosis of teeth with endodontically induced periapical lesions. *Int Endod J* 33:219-6, 2000.

24. Peters LB, Wesselink PR, Periapical healing of endodontically treated teeth in one and two visits obturated in the presence or absence of detectable microorganisms. *Int Endod J* 35:660-7, 2002.

25. Hoskinson SE, Ng YL, Hoskinson AE, Moles DR, Gulabivala K, A retrospective comparison of outcome of root canal treatment using two different protocols. *Oral Surg Oral Med Oral Pathol Oral Radiol Endod* 93:705-15, 2002.

26. Friedman S, Abitbol S, Lawrence HP, Treatment outcome in endodontics: The Toronto Study. Phase I: Initial Treatment. *J Endodon* 29:787-93, 2003.

27. Farzaneh S, Abitbol S, Lawrence HP, Friedman S, Treatment outcome in endodontics: The Toronto Study. Phase II: Initial Treatment. *J Endodon* 2004, in press.

28. Sundqvist G, Figdor D, Persson S, Sjögren U, Microbiologic analysis of teeth with failed endodontic treatment and the outcome of conservative retreatment. *Oral Surg Oral Med Oral Pathol Oral Radiol Endod* 85:86-3, 1998.

29. Kvist T, Reit C, Results of endodontic retreatment: A randomized clinical study comparing surgical and nonsurgical procedures. *J Endodon* 25:814-7, 1999.

30. Molven O, Halse A, Grung B, Surgical management of endodontic failures: indications and treatment results. *Int Dent J* 41:33-2, 1991.

31. Jansson L, Sandstedt P, Läftman AC, Skoglund A, Relationship between apical and marginal healing in periradicular surgery. *Oral Surg Oral Med Oral Pathol Oral Radiol Endod* 83:596-1, 1997.

32. Zuolo ML, Ferreira MOF, Gutmann JL, Prognosis in periradicular surgery: a clinical prospective study. *Int Endod J* 33:91-8, 2000.

33. Rahbaran S, Gilthorpe MS, Harrison SD, Gulabivala K, Comparison of clinical outcome of periapical surgery in endodontic and oral surgery units of a teaching dental hospital: A retrospective study. *Oral Surg Oral Med Oral Pathol Oral Radiol Endod* 91:700-9, 2001.

34. Creugers NHJ, Kreulen CM, Snoek PA, de Kanter RJAM, A systematic review of single-tooth restorations supported by implants. *J Dent* 28:209-7, 2000.

35. Peterson J, Gutmann JL, The outcome of endodontic resurgery: a systematic review. *Int Endod J* 34:169-5, 2001.

36. Hepworth MJ, Friedman S, Treatment outcome of surgical and nonsurgical management of

endodontic failures. *J Can Dent Assoc* 63:364-1, 1997.

To request a printed copy of this article, please contact / Shimon Friedman, DMD, Endodontics, University of Toronto Faculty of Dentistry, 124 Edward St., Toronto, Ontario, M5G 1G6, Canada.