

Hi folks: nothing revolutionary here, but its been a long time since I posted a case.

This gentleman had the endo done many years ago as a teenager (he is in mid 30s now) and a SSC placed overtop. The SSC came off over time and the tooth didnt hurt so he left it.

What prompted him to come in was the color of the tooth, so we discussed the need to have the endo redone despite the fact that no periapical pathology was seen but because it was open for so long. I suspect that they had IRM in the access, but the cotton pellet was still in the tooth.

I removed the coronal Gutta Percha with a TUF1 #1 tip. For those of you that have ultrasonics you might want to try these tips out. They are very durable and the coatings last forever. I do some work for them so I am biased but I honestly mean this, these tips are very very good. Manufacturer is San Diego Swiss Machining and here is their website. They also make a great instrument retrieval system that is there star product.

In any event the Ultrasonic with the #1 tip is useful for taking the Gutta percha out without water. ITs safe (compared to Gates Gliddens) and I could get 12mm of the GP out before I had to use rotaries. The US with water also helps flush out the canal of GP.

I widened it to 04 tape 60 tip and it was interesting to see that as I got to my master apical files how the GP came out with darkness on the pieces (as seen under the scope) showing bacteria either from before or more likely due to coronal leakage.

No 2nd canal found, and we obturated with GP and placed flowable over the top and a pellet with Sodium Perborate to help bleach the tooth.

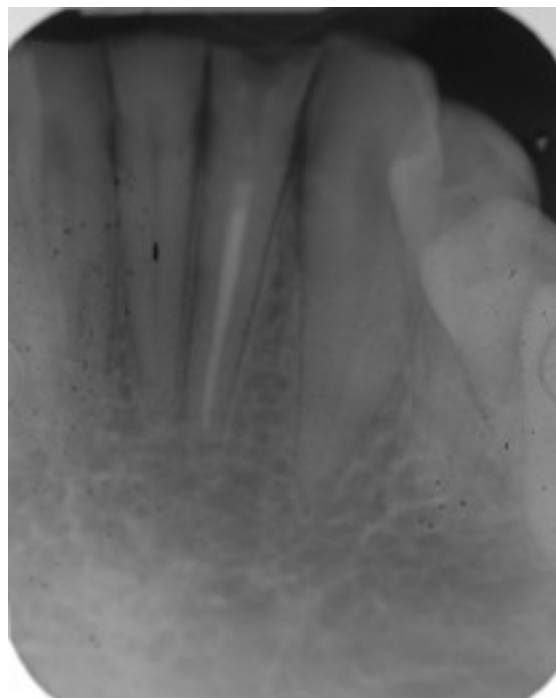
Length control was ok not perhaps perfect but I think the end result for an easy case was decent.

Hope it is of interest....photos shot through the scope to give you a chance to see what makes microscope endo so fascinating.

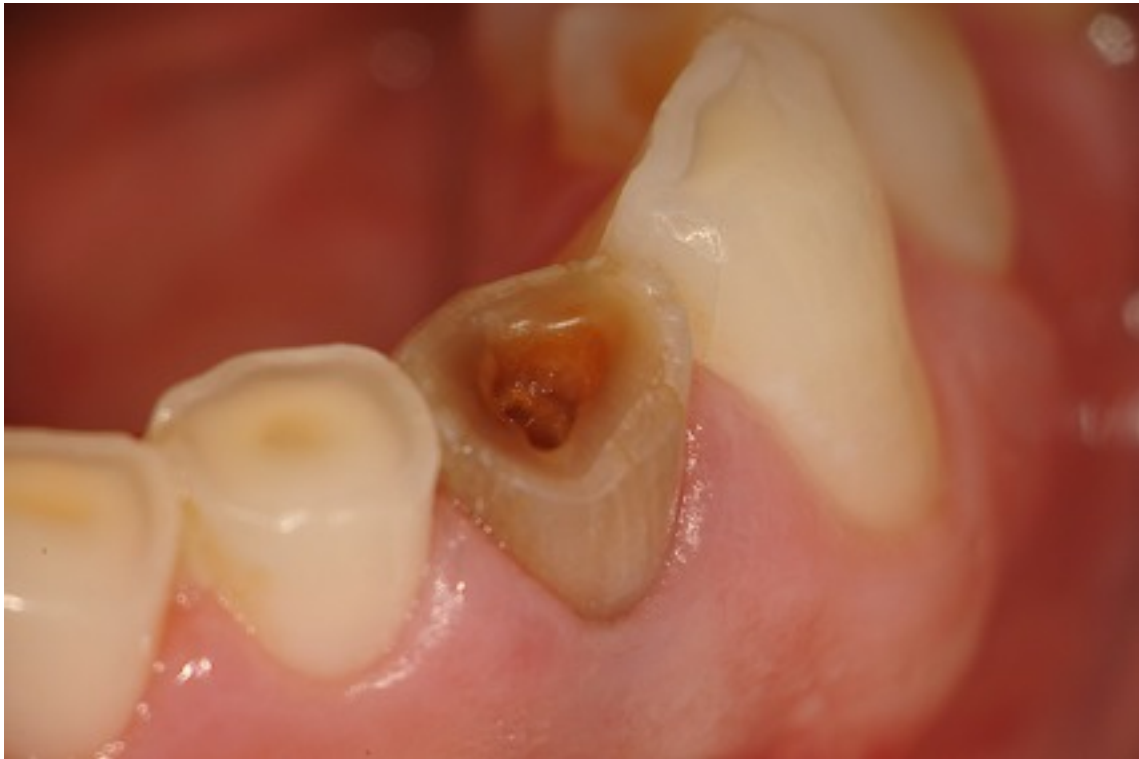Cheers,

Glenn

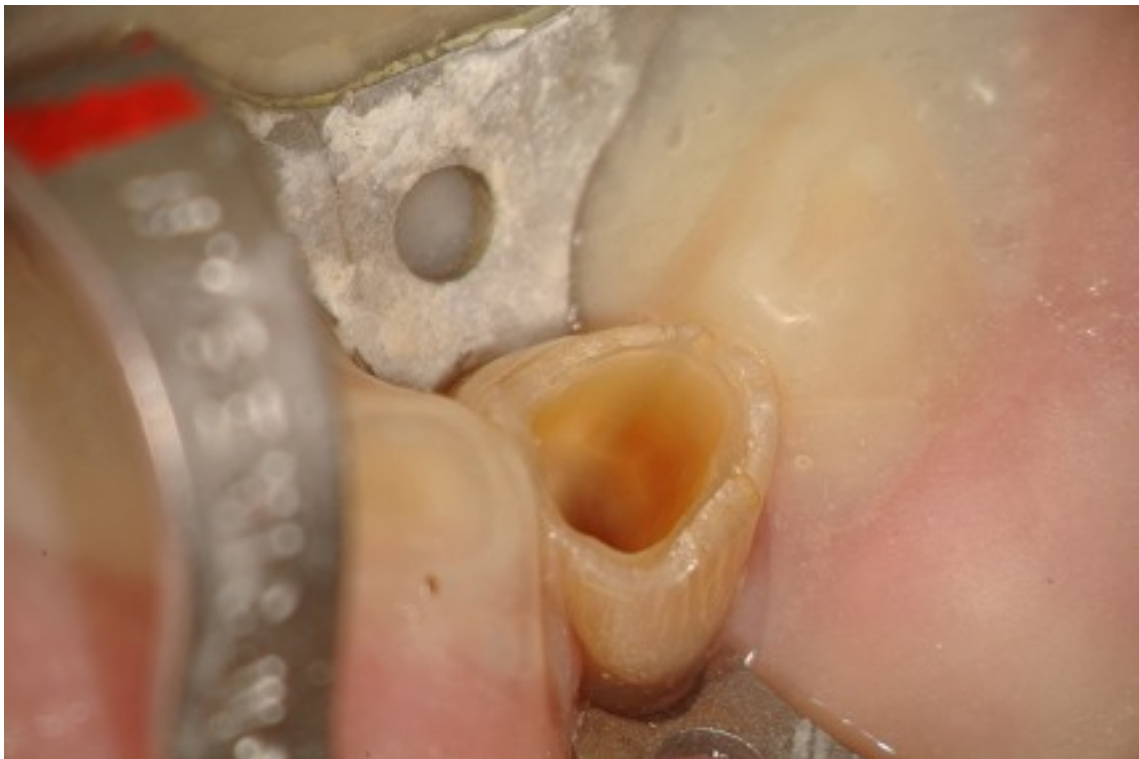original PA before retreatment



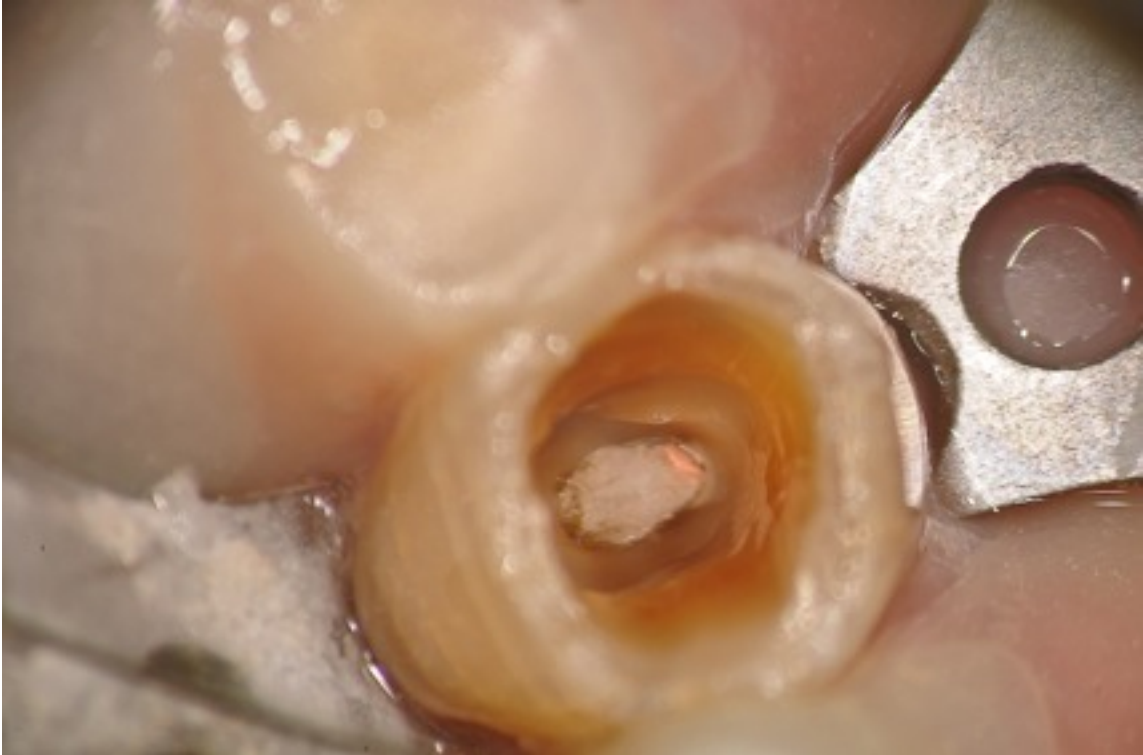Preop photograph of tooth.



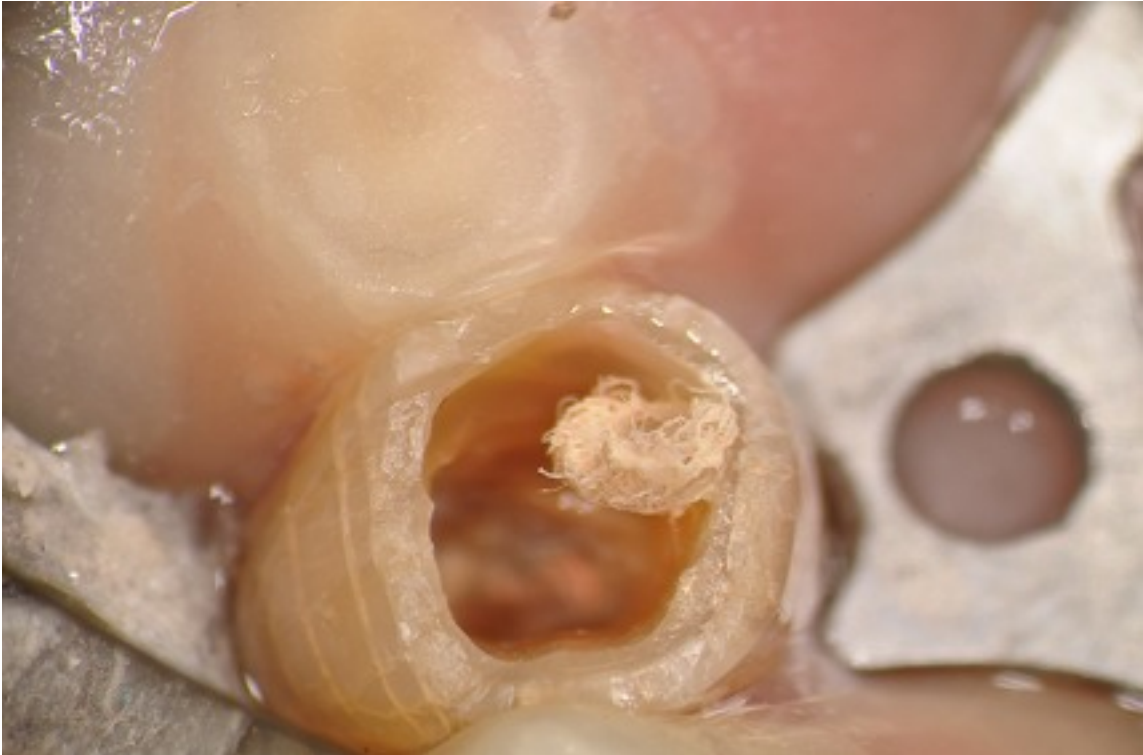Rubber dam placed and caries removal.



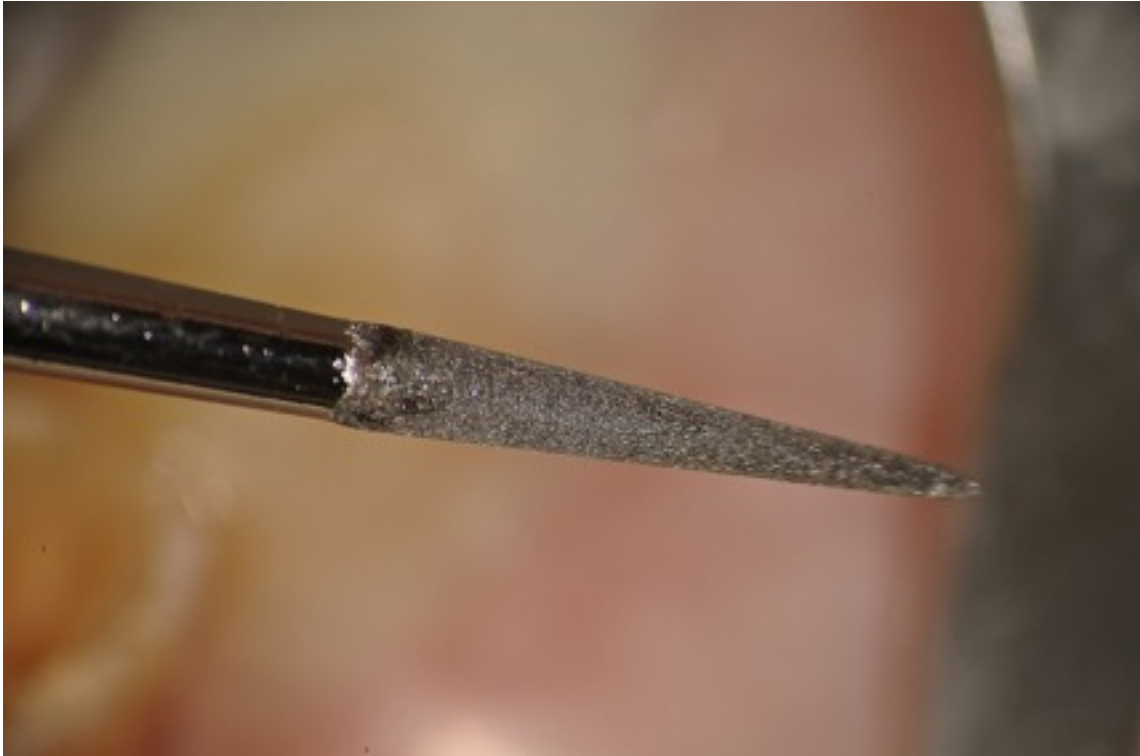
Cotton pellet on top of Gutta Percha



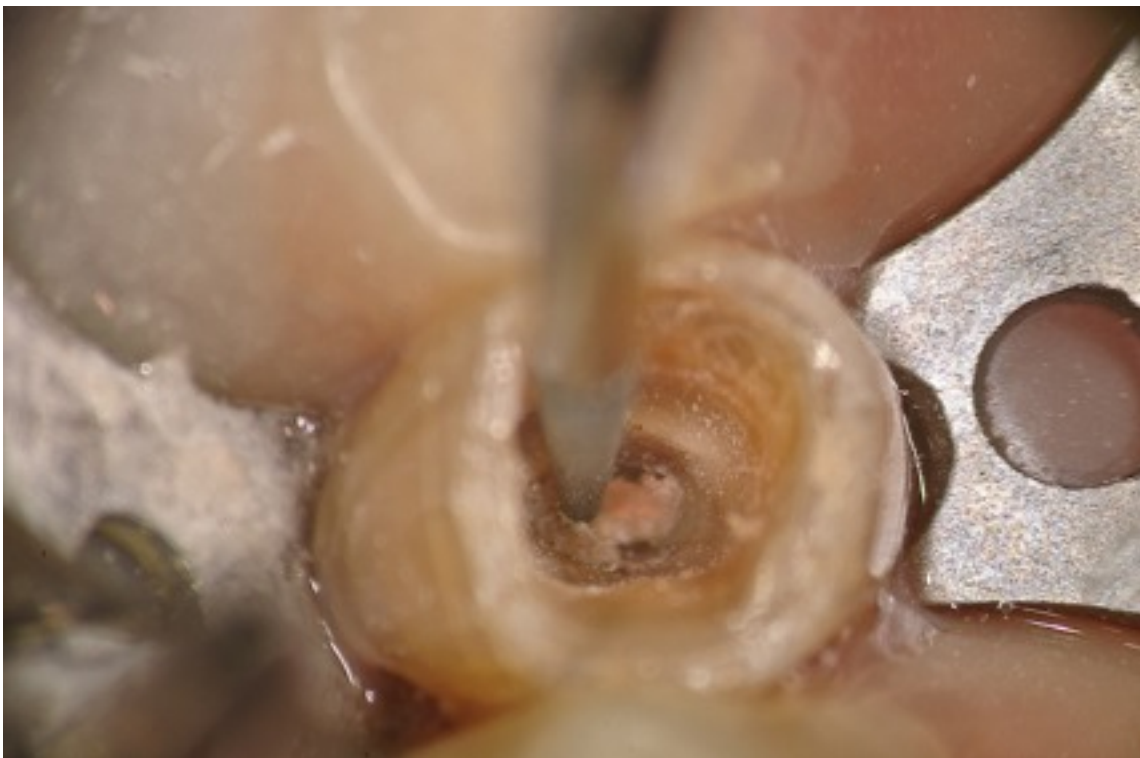Close up view.



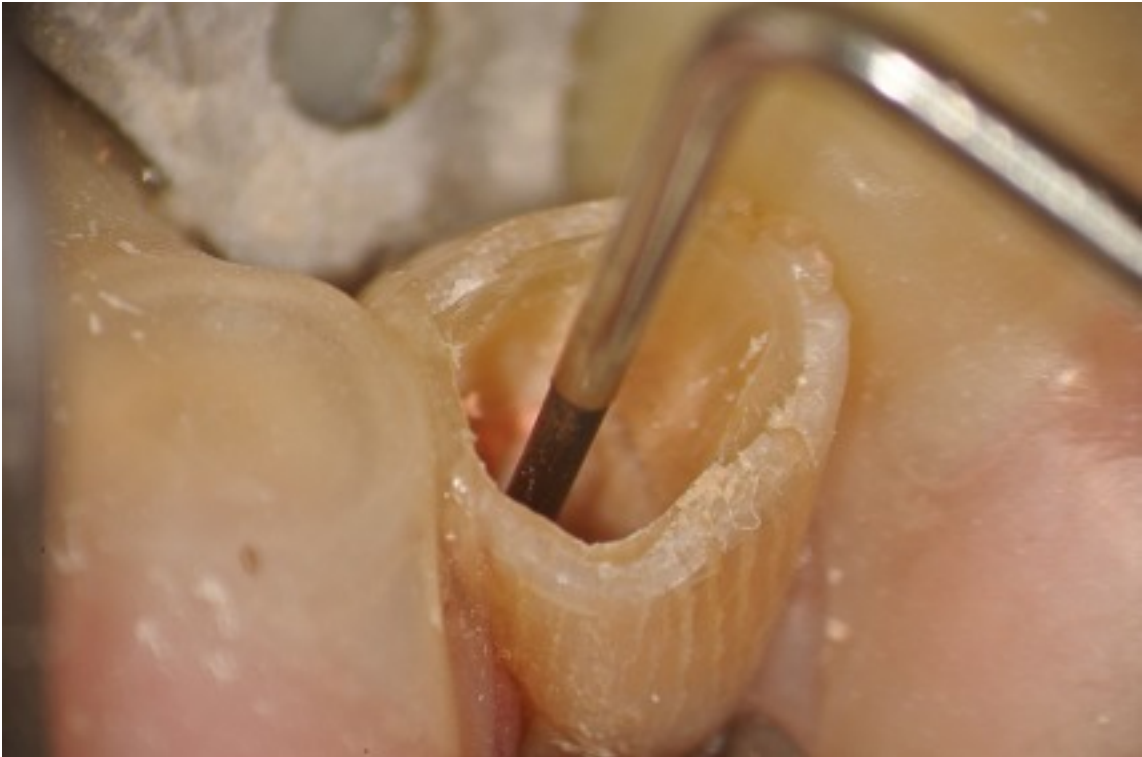TUFI #1 Ultrasonic tip (San Diego Swiss Dental Machining).



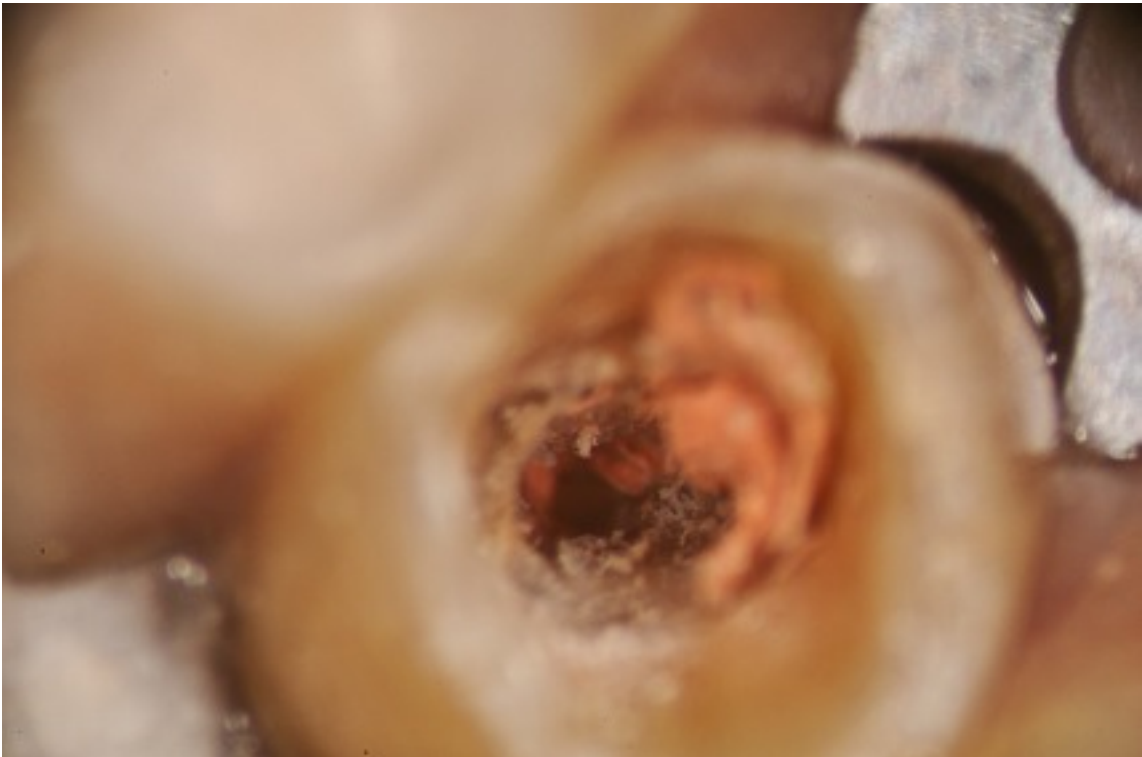Tip placed on GP dry to remove coronal portion of GP easily.



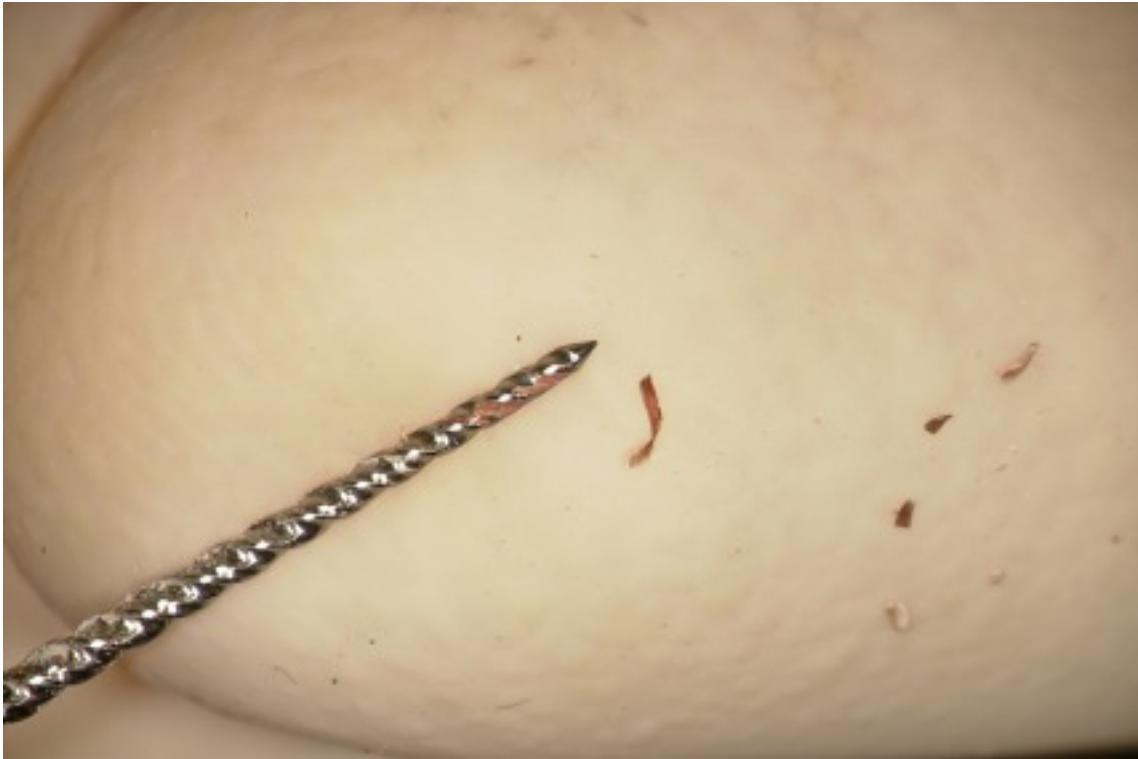Gutta Purcha removed to 12mm with Ultrasonic.



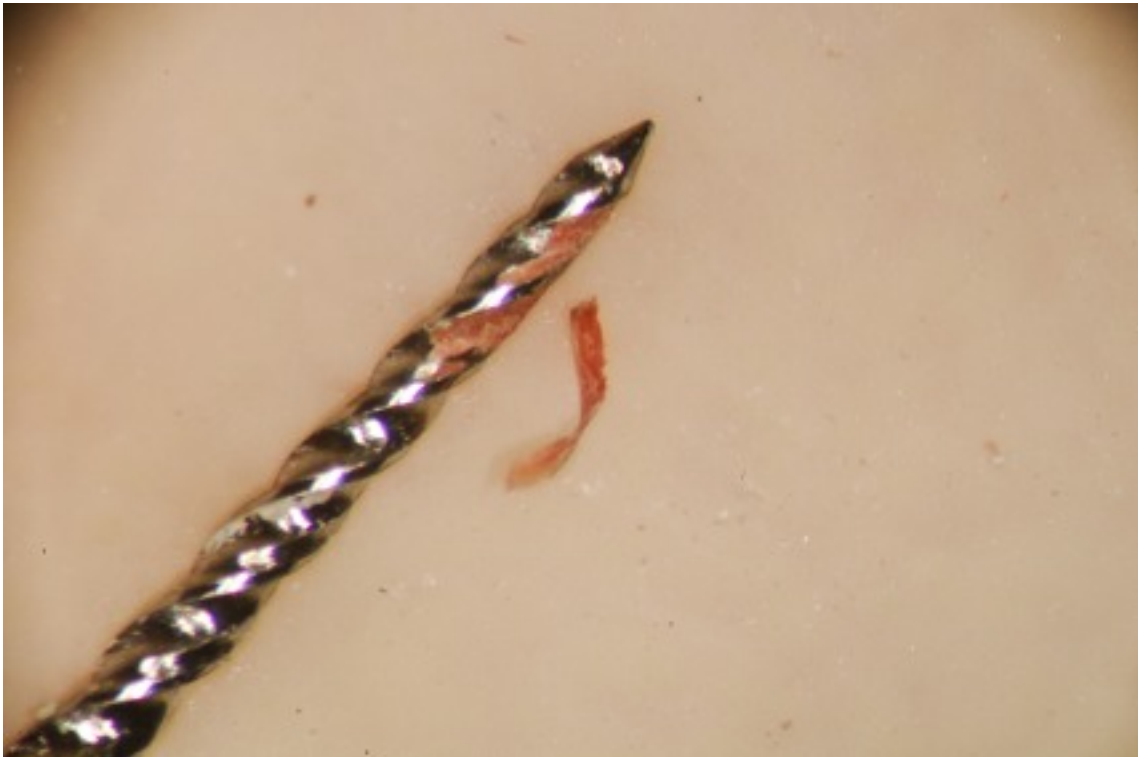Closeup view.



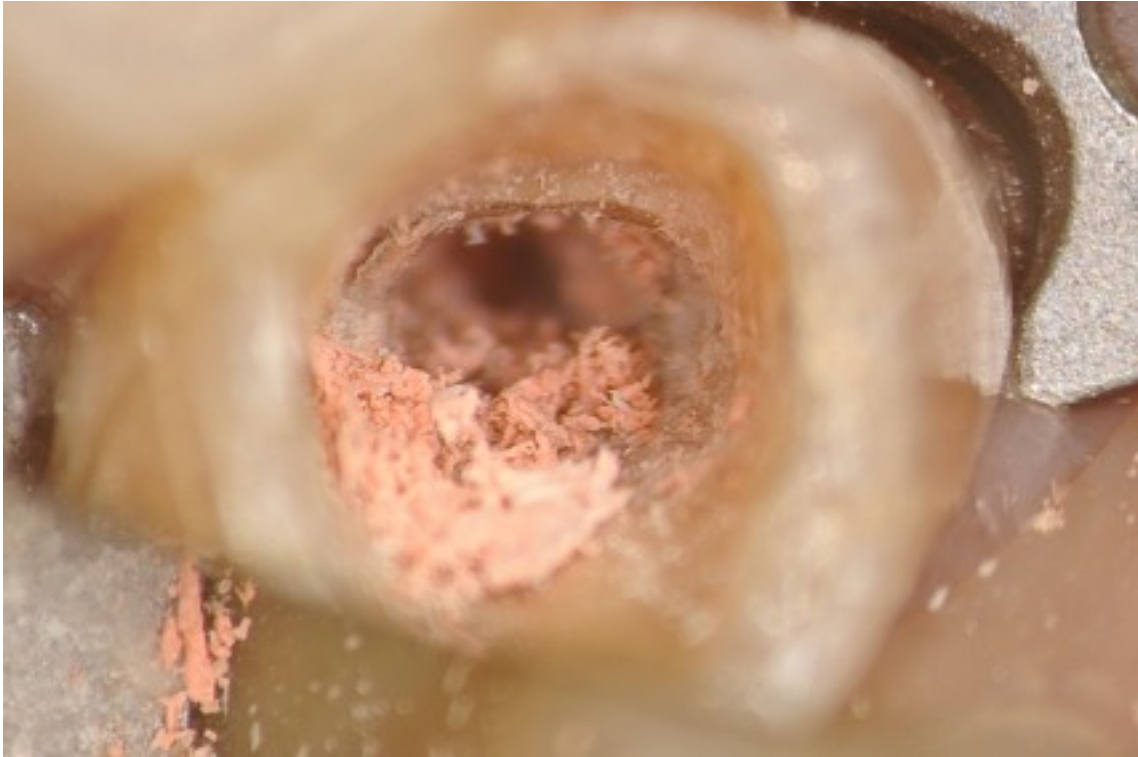
Rotary at end of root, note GP in file and bacteria on GP.



Closeup view of GP and rotary file.



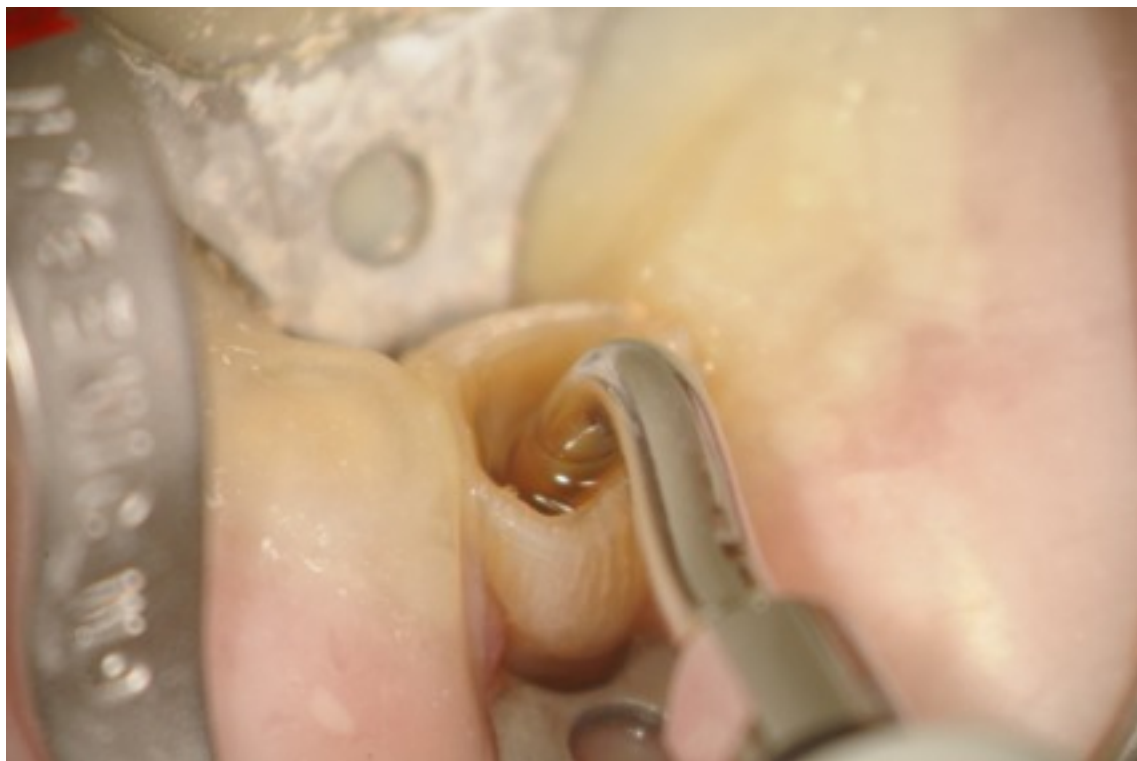GP fragments in canal at high mag.



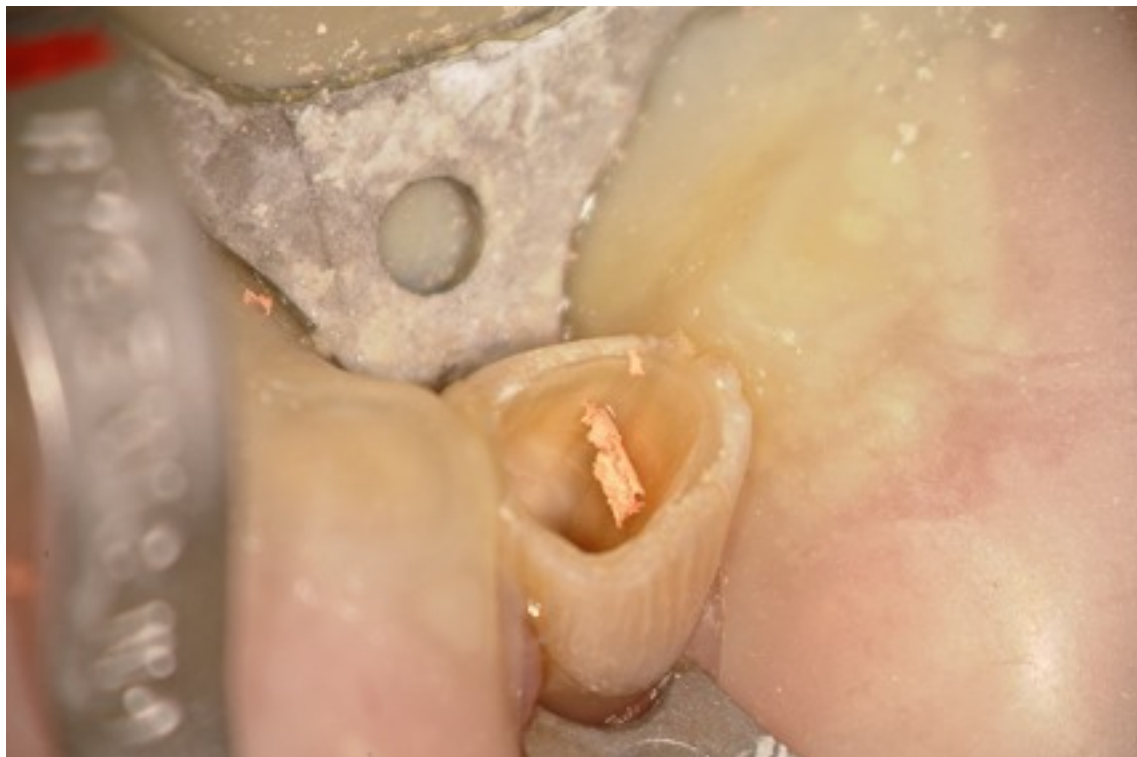Note small amount of GP in canal under scope.



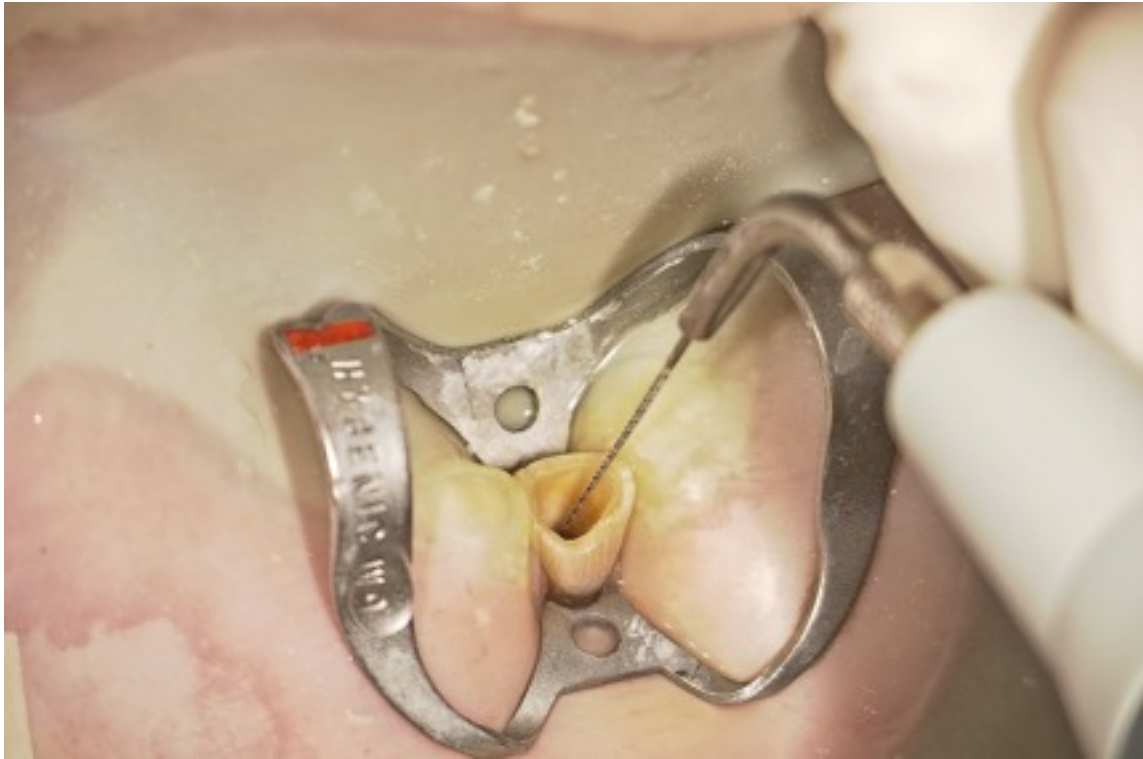Using Ultrasonic TUFI tip with water to flush out last bit of GP in canal



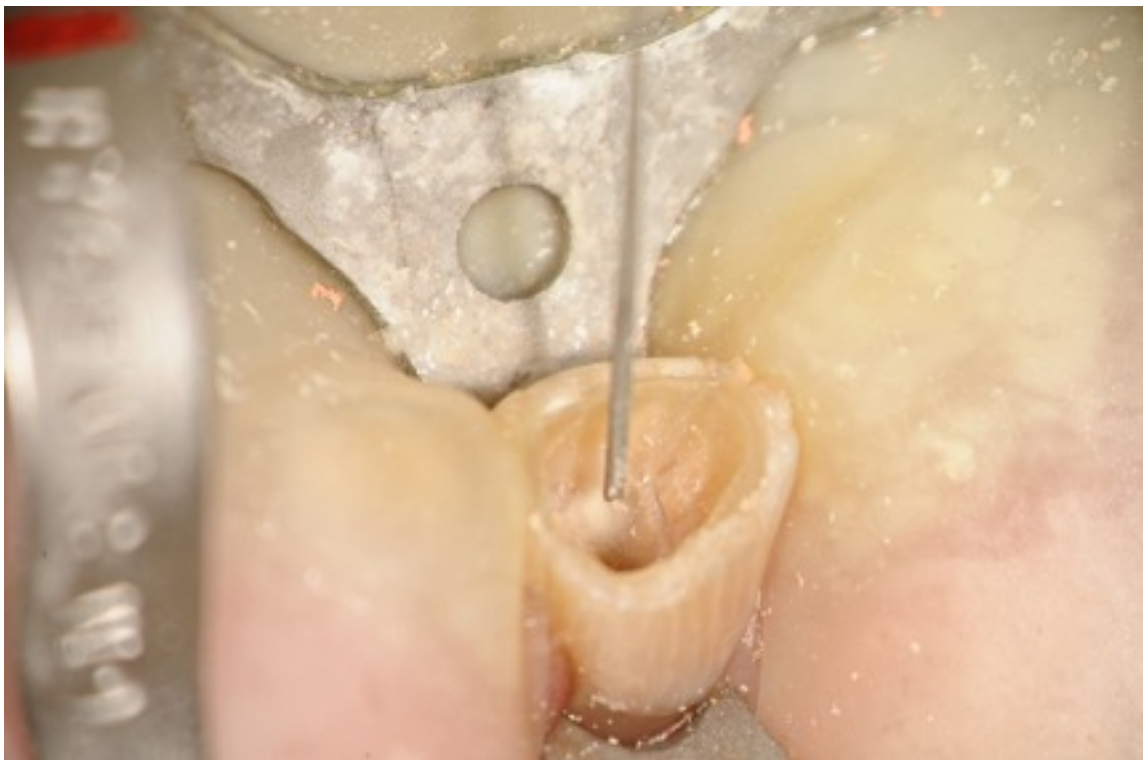Last bit removed with Ultrasonics



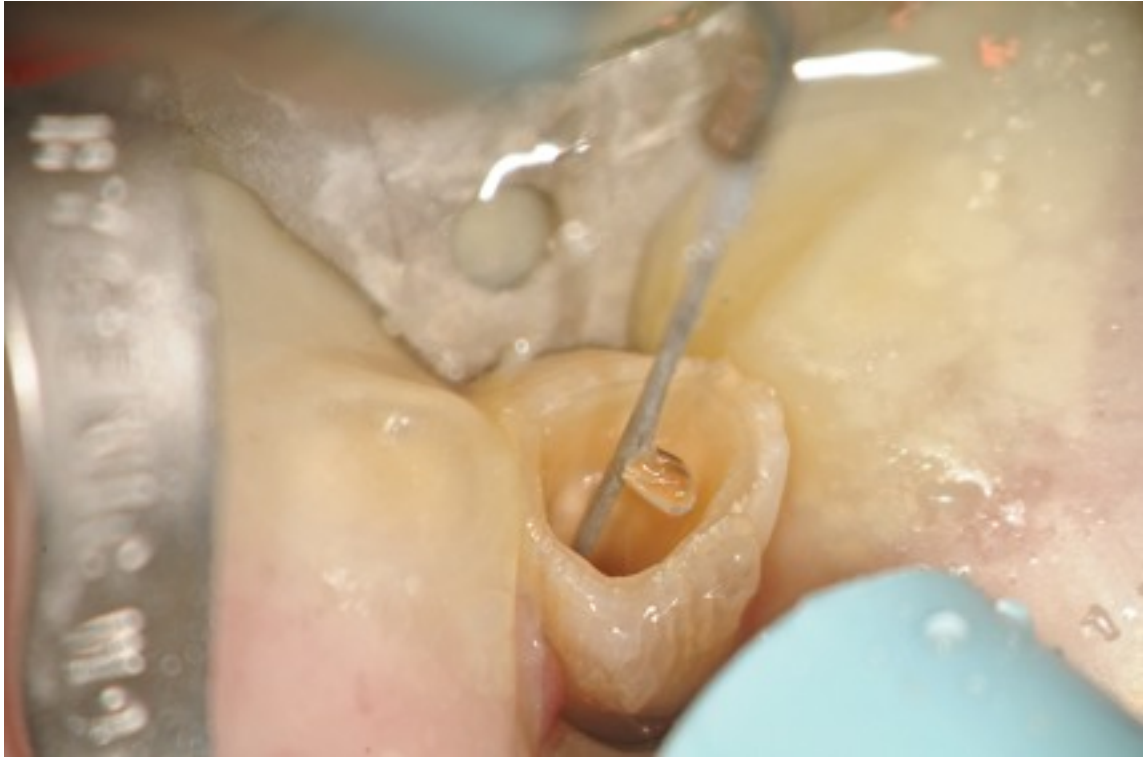Ultrasonic File (Satelec) to help with irrigation.



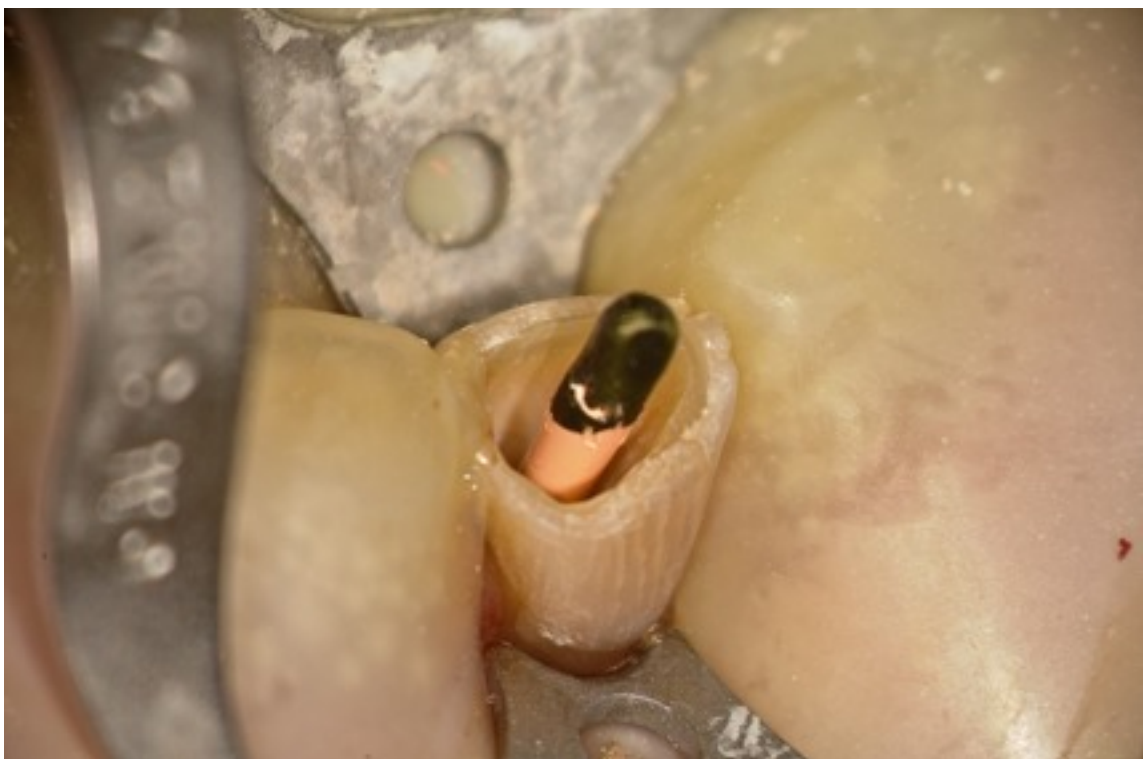
Erbium YAG laser to help disinfect dentin,



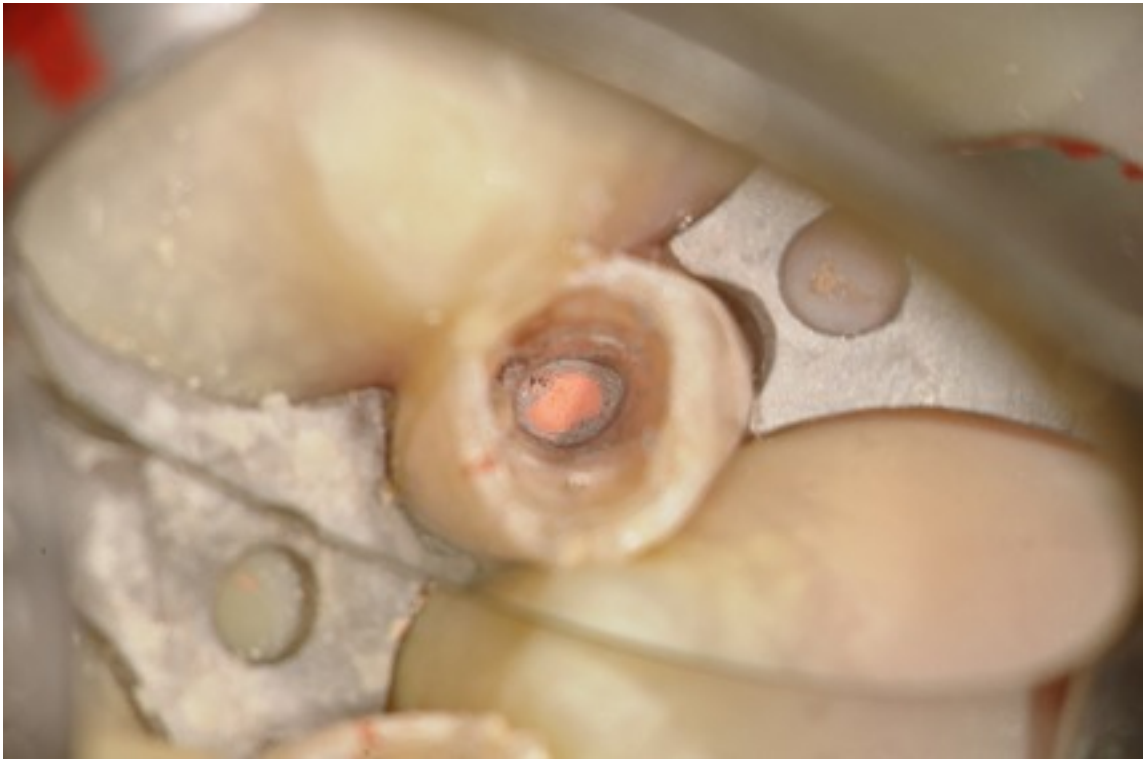
Another view of Laser at work to remove smear layer and to disinfect canal prior to obturation.



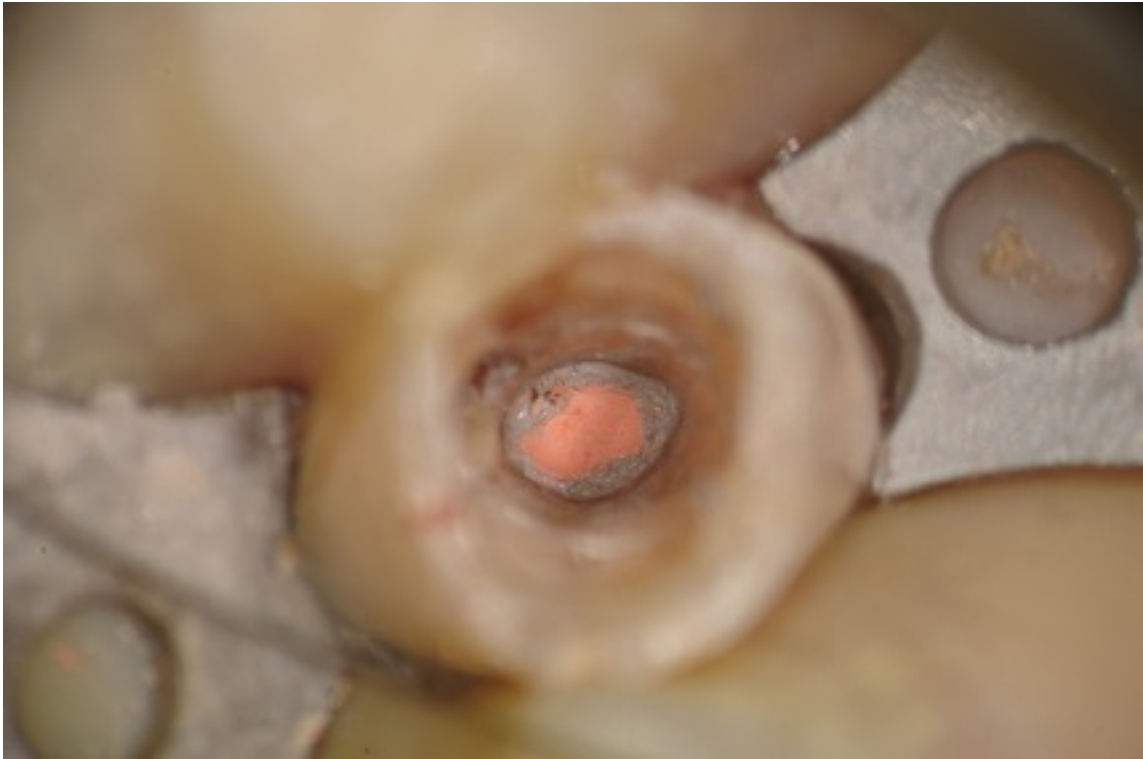Trial Cone in place.



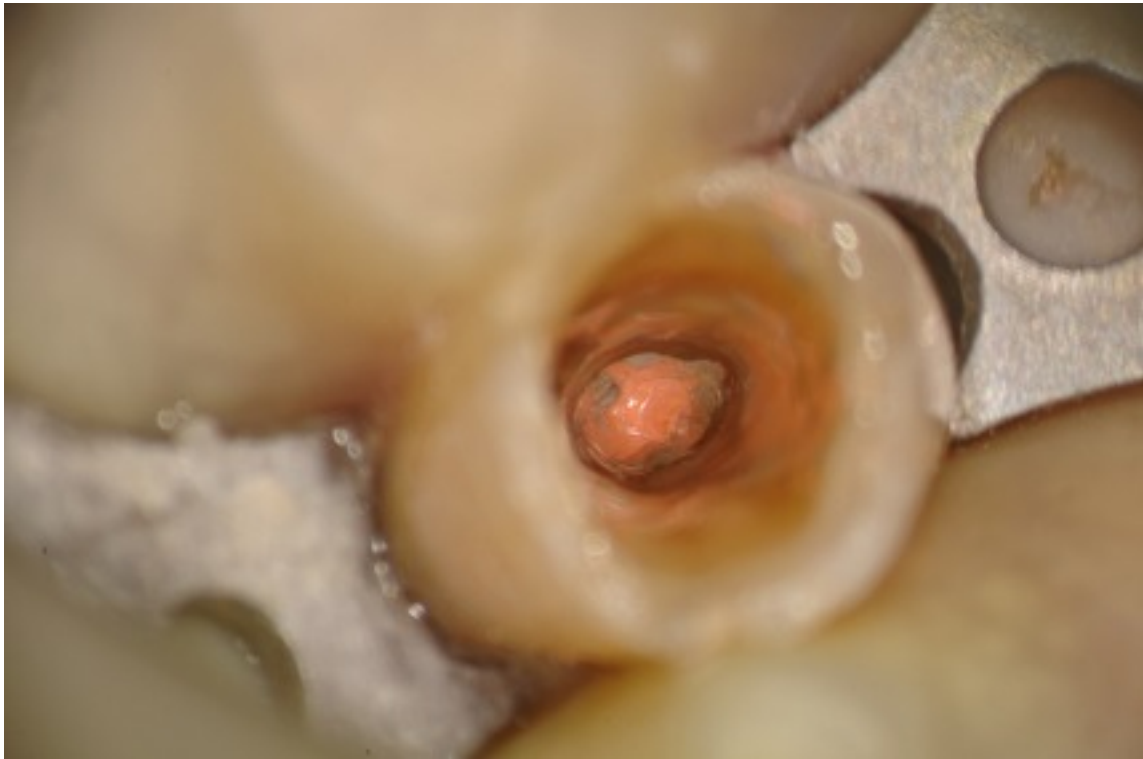
Obtured canal



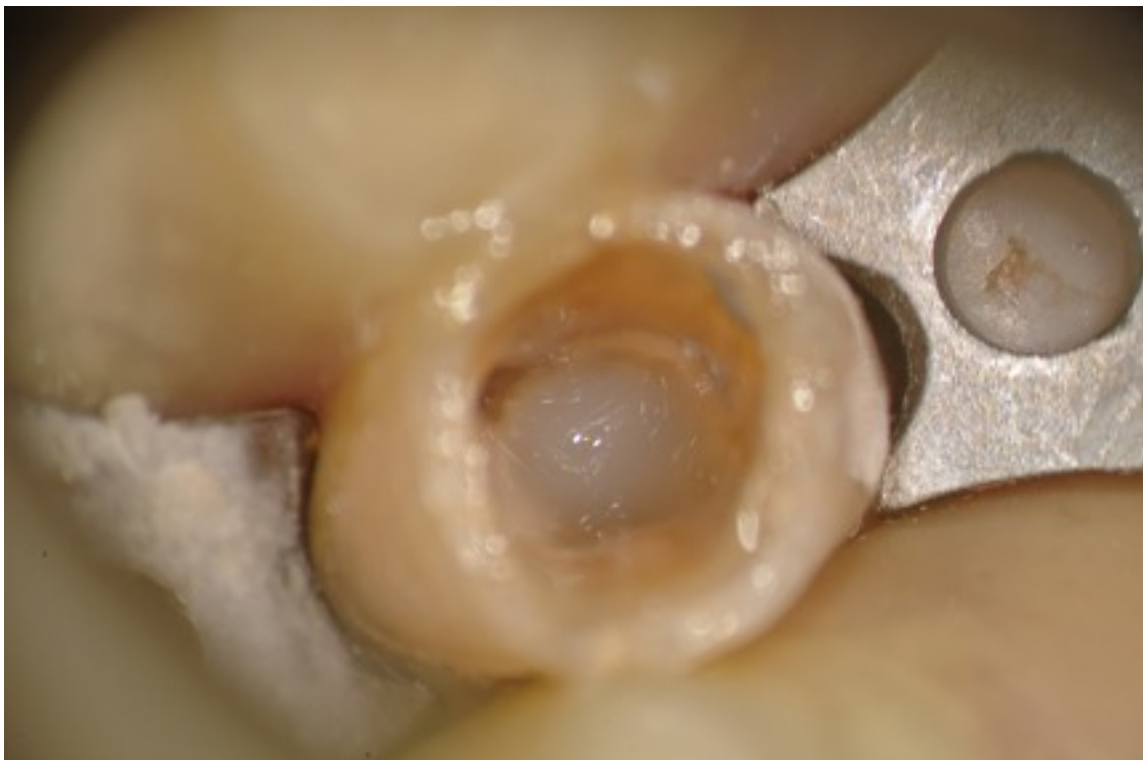Higher mag view of obturation.



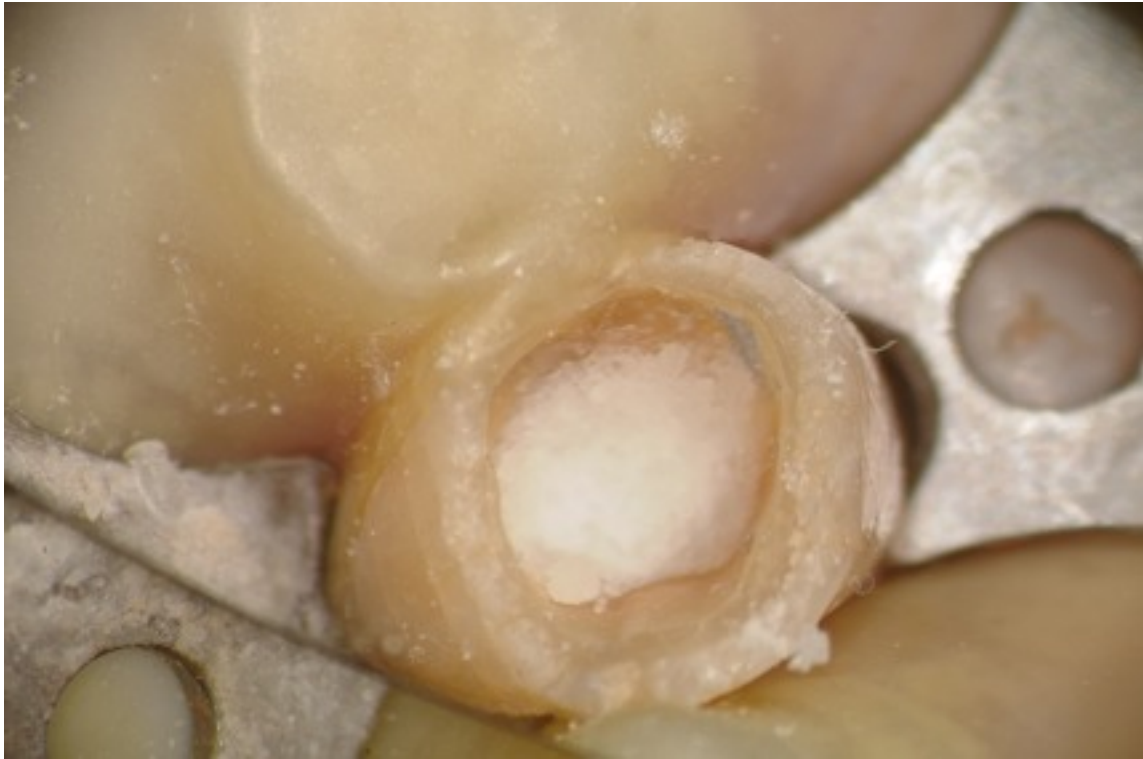Cleaned up floor of pulp chamber with bond in place.



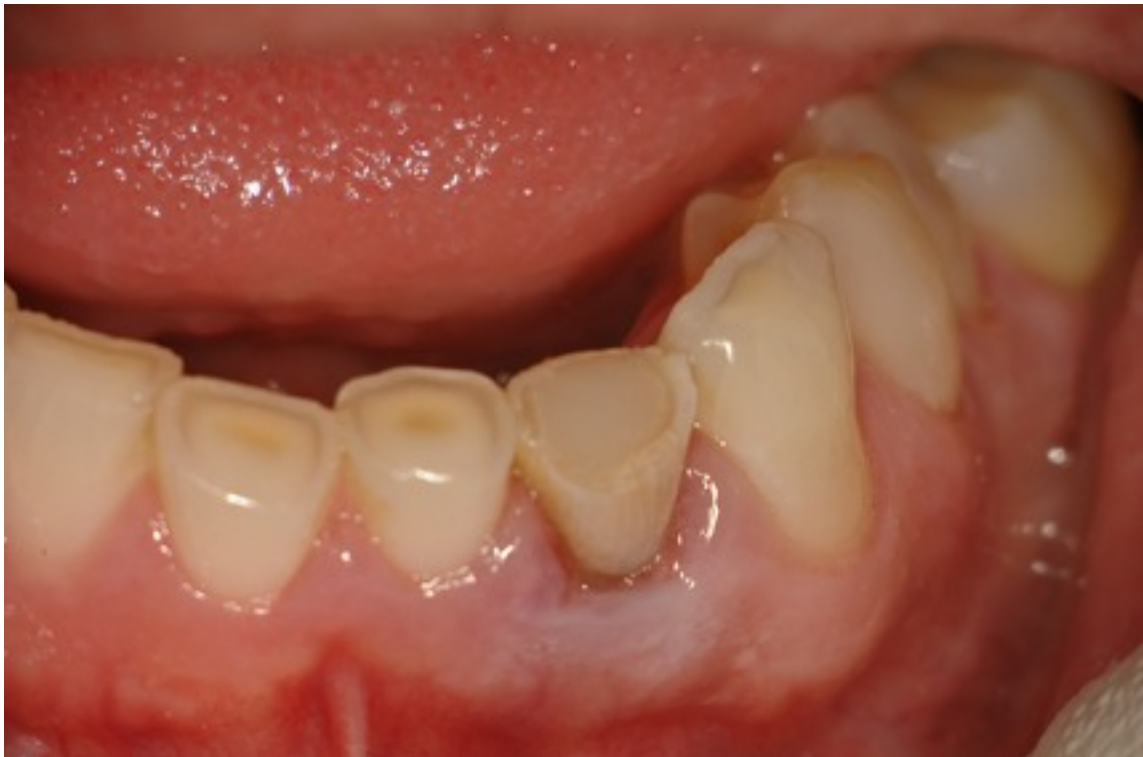Flowable over GP



Pellet of Sodium Perborate for bleaching in tooth.



Temporary restoration in place



Final Postoperative radiograph.

