

Quantitation of Mandibular Ramus Volume as a Source of Bone Grafting

Fernando Verdugo, DDS;* Krikor Simonian, DDS;† Roberto Smith McDonald, MS;‡ Hessam Nowzari, DDS, PhD§

ABSTRACT

Background: When alveolar atrophy impairs dental implant placement, ridge augmentation using mandibular ramus graft may be considered. In live patients, however, an accurate calculation of the amount of bone that can be safely harvested from the ramus has not been reported. The use of a software program to perform these calculations can aid in preventing surgical complications.

Purpose: The aim of the present study was to intra-surgically quantify the volume of the ramus bone graft that can be safely harvested in live patients, and compare it to presurgical computerized tomographic calculations.

Materials and Methods: The AutoCAD® software program quantified ramus bone graft in 40 consecutive patients from computerized tomographies. Direct intra-surgical measurements were recorded thereafter and compared to software data ($n = 10$). In these 10 patients, the bone volume was also measured at the recipient sites 6 months post-sinus augmentation.

Results: The mandibular second and third molar areas provided the thickest cortical graft averaging 2.8 ± 0.6 mm. The thinnest bone was immediately posterior to the third molar (1.9 ± 0.3 mm). The volume of ramus bone graft measured by AutoCAD averaged 0.8 mL (standard deviation [SD] 0.2 mL, range: 0.4–1.2 mL). The volume of bone graft measured intra-surgically averaged 2.5 mL (SD 0.4 mL, range: 1.8–3.0 mL). The difference between the two measurement methods was significant ($p < 0.001$). The bone volume measured 6 months post-sinus augmentation averaged 2.2 mL (SD 0.4 mL, range: 1.6–2.8 mL) with a mean loss of 0.3 mL in volume.

Conclusion: The mandibular second molar area provided the thickest cortical graft. A cortical plate of 2.8 mm in average at combined second and third molar areas provided 2.5 mL particulated volume. The use of a design software program can improve surgical treatment planning prior to ramus bone grafting. The AutoCAD software program did not overestimate the volume of bone that can be safely harvested from the mandibular ramus.

KEY WORDS: AutoCAD, bone graft, ramus

*Private practice, Huntington Beach, CA, USA, consultant periodontist, VA Hospital, Greater Los Angeles Healthcare System, Los Angeles, CA, USA, formerly assistant professor, clinical dentistry, advanced periodontics, University of Southern California, Los Angeles, CA, USA; †assistant professor, advanced periodontics, University of Southern California School of Dentistry, Los Angeles, CA, USA; ‡architect, CAD specialist, Los Angeles, CA, USA; §professor of clinical dentistry and director, advanced periodontics, University of Southern California School of Dentistry, Los Angeles, CA, USA

Reprint requests: Dr. Fernando Verdugo, 18800 Main Street, Suite 201, Huntington Beach, CA 92648, USA; e-mail: fverdugo@perio.org

Advanced Periodontics Research Fund, The University of Southern California, supported this study.

None of the authors has any conflict of interest in this study.

© 2009, Copyright the Authors
Journal Compilation © 2009, Wiley Periodicals, Inc.

DOI 10.1111/j.1708-8208.2009.00172.x

The placement of endosseous dental implants requires bone quantity and quality at a proper prosthetic position. When alveolar atrophy impairs such implant placement, ridge augmentation including maxillary sinus graft may be considered.^{1–7} The mandibular cortical graft can be taken from the ramus that provides primarily a dense cortical bone and high concentration of promoter proteins (eg, bone morphogenetic proteins).^{1,2}

Güngörmüş and colleagues^{8,9} examined 16 adult cadaver dry skulls and measured a ramus volume of 2.4 mL. The landmarks for the ramus block reached as cephalad as the sigmoid notch and coronoid process. The volume was calculated by displacement volumetry ($37.6 \times 33.2 \times 22.5 \times 9.1 = 2.4$ mL). However, the volume of ramus bone that can be harvested in live patients has not been reported. The aim of the present

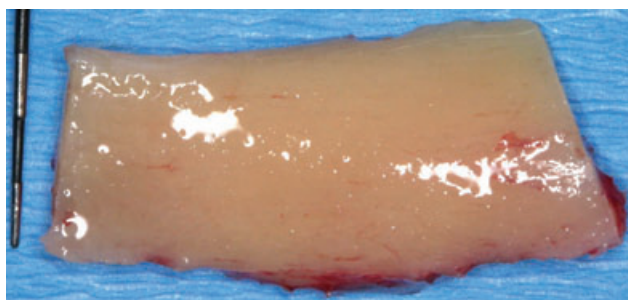


Figure 1 Mandibular ramus block graft (buccal view).

study was to intra-surgically quantify the volume of the ramus bone graft that can be safely harvested in live patients and compare it to presurgical computerized tomographic calculations.

MATERIALS AND METHODS

The University of Southern California Institutional Review Board approved the present research project (IRB #04-06-201).

Intra-Surgical Measurement of the Bone Volume

The mandibular ramus block grafts (Figures 1–3) were harvested and particulated (Figure 4) in 10 consecutive patients, from the mid-buccal of mandibular first molar to mid-distance between the third molar and mandibular foramen. The volume of the particulated grafts was measured using a graduated cylinder with 0.5 mL markings. After inserting the particles inside the cylinder, a compacting pressure of 100 g was applied and saline solution (1 mL) added to fill the voids. From the final measured volume, 1 mL was subtracted to account for the previous saline addition.

Tomographic Measurement of the Bone Volume

The AutoCAD® software program was used to presurgically measure the tomographic bone volume at the man-

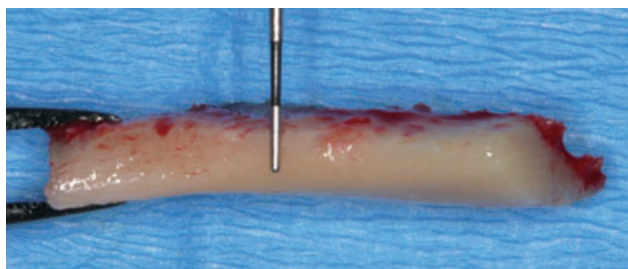


Figure 2 Mandibular ramus block graft (thickness).

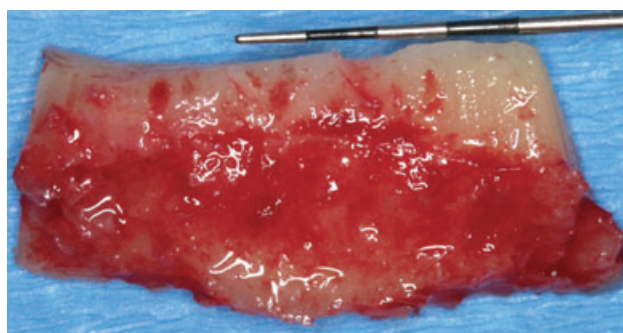


Figure 3 Mandibular ramus block graft (lingual view).

dibular ramus of 40 consecutive patients including the 10 patients who received the intra-surgical measurements and sinus augmentation (Figure 5).

The AutoCAD is a computer-aided design software application used in the architecture, construction, and manufacturing (version 16.0, Autodesk, Inc., San Rafael, CA, USA). The method has been described previously.¹⁰ Briefly, cross-sectional images were imported into the software program, and each 1 mm cut was mapped by a polyline. The surface area measured from each mapped polyline was used to calculate the volume by adding the consecutive cuts from the mid-buccal of mandibular first molar to mid-distance between the third molar and mandibular foramen. These measurements extended apically 3 mm above the inferior alveolar canal. Morphometric references were made at first (M_1), second (M_2), third molar areas (M_3), and anterior to the mandibular foramen (dM_3) to calculate the buccal cortical thickness (Table 1).

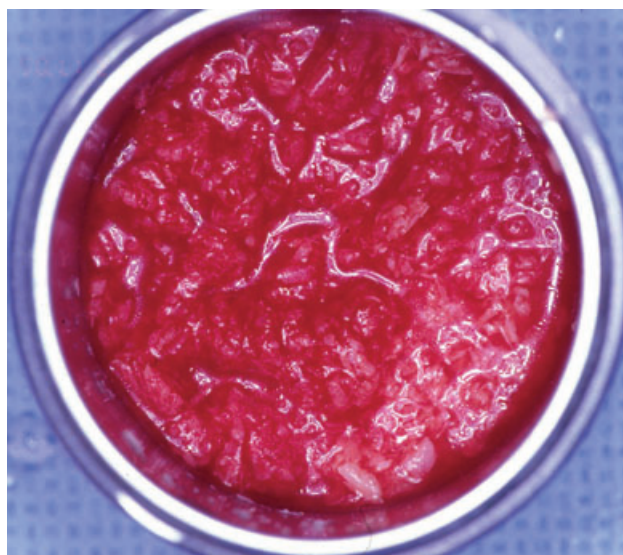


Figure 4 Particulated ramus graft.

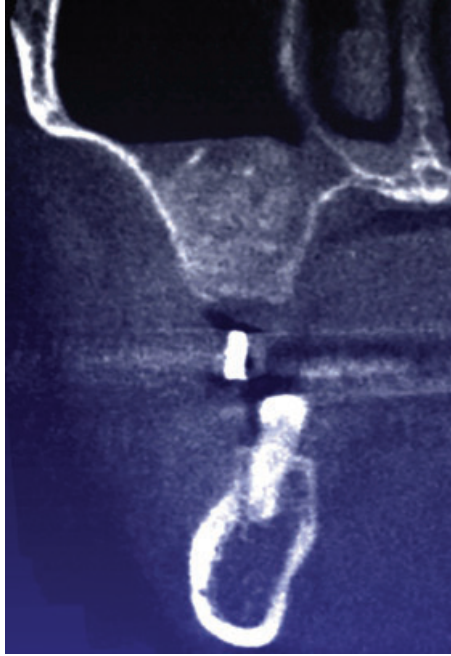

Figure 5 Grafted sinus at 6 months.

Data Analysis

Descriptive analysis of data included mean \pm standard deviation (SD). The SPSS® software program (version 14.0, SPSS Inc., Chicago, IL, USA) analyzed the different variables. The *t*-test was used for paired observations to compare mean cortical thickness, volumes of particulated graft harvested, and volume change post-sinus augmentation. Statistical significance was set at $p < 0.05$.

RESULTS

The study patients comprised 22 women and 18 men (mean age 48 years; range: 28–75). In the

computerized measurement group, the following were calculated:

1. First molars (M_1): 2.2 ± 0.5 mm buccal cortical thickness at the crestal area (range: 1.1–2.9 mm) and 1.9 ± 0.3 mm at the most apical part of the corticotomy (range: 1.5–2.5 mm);
2. Second molars (M_2): 2.8 ± 0.7 mm buccal cortical thickness at the crestal area (range: 2.0–4.2 mm) and $2.4 \text{ mm} \pm 0.6$ mm at the most apical part of the corticotomy (range: 1.7–4.8 mm);
3. Third molars (M_3): $2.7 \text{ mm} \pm 0.5$ mm buccal cortical thickness at the crestal area (range: 1.8–3.6 mm) and $2.1 \text{ mm} \pm 0.4$ mm at the most apical part of the corticotomy (range: 1.3–3.0 mm); and
4. Between mandibular foramen and third molar (dM_3): $1.9 \text{ mm} \pm 0.3$ mm buccal cortical thickness at the crestal area (range: 1.4–2.3 mm) and $1.6 \text{ mm} \pm 0.3$ mm at the most apical part of the corticotomy (range: 1.1–2.3 mm) (see Table 1).

The crestal cortical thickness was significantly greater for M_2 versus M_1 ($p < 0.0001$), and M_3 versus M_1 ($p = 0.002$). The difference between M_1 versus dM_3 , and M_2 versus M_3 did not reach significance ($p = 0.07$ and $p = 0.6$, respectively). At all sites (M_1 , M_2 , M_3 , dM_3), the thickness of the crestal cortical plate was significantly greater than the apical cortical plate ($p < 0.05$). M_2 presented the thickest crestal and apical cortical plates, and dM_3 the thinnest (see Table 1; Figure 6).

The tomographic bone volume averaged 0.8 mL (SD 0.2 mL; range: 0.4–1.2 mL). Intra-surgically, the mean volume of harvested graft was 2.5 mL (SD 0.4 mL;

TABLE 1 Comparison of Cortical Thickness from First Molar Area to Mid-Distance Between the Third Molar and Mandibular Foramen (Mean \pm SD)

| Thickness mm \pm SD | M_1 | M_2 | M_3 | DM_3 | p Value |
|-----------------------|---------------|---------------|---------------|---------------|-----------|
| Crestal | 2.2 ± 0.5 | 2.8 ± 0.7 | 2.7 ± 0.5 | 1.9 ± 0.3 | → <0.05 |
| Apical | 1.9 ± 0.3 | 2.4 ± 0.6 | 2.1 ± 0.4 | 1.6 ± 0.3 | |
| M_1 versus M_2 | → | | | | <0.05 |
| M_1 versus M_3 | → | | | | <0.05 |
| M_1 versus dM_3 | → | | | | NS |
| M_2 versus M_3 | → | | | | NS |
| M_2 versus dM_3 | → | | | | <0.05 |
| M_3 versus dM_3 | → | | | | <0.05 |

NS = not statistically significant; M_1 = mandibular first molar; M_2 = mandibular second molar; M_3 = mandibular third molar; dM_3 = distal of mandibular third molar.

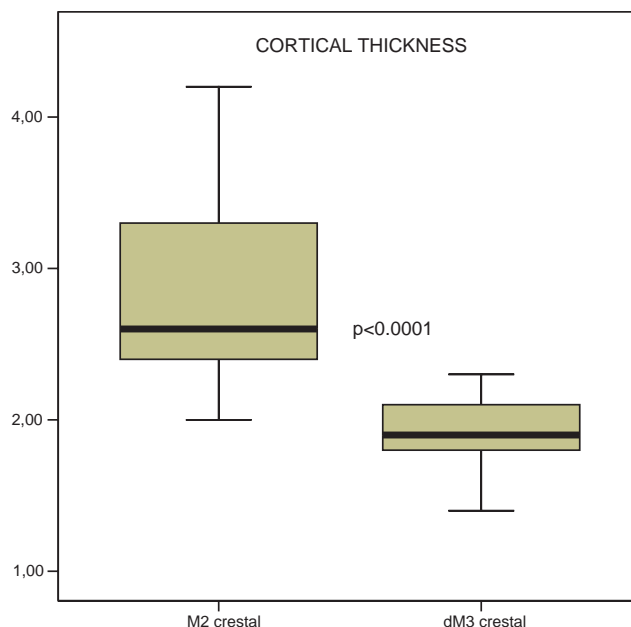


Figure 6 Tomographic measurement of crestal cortical thickness.

range: 1.8–3.0 mL). The difference between the two measurement methods was statistically significant ($p < 0.0001$) (Figure 7).

The AutoCAD program measured sinus augmentation of 2.2 mL (SD 0.4 mL; range: 1.6–2.8) which compared to the initial harvested volume (2.5 mL \pm 0.4) yielded a decrease of 0.3 mL.

DISCUSSION

Computerized tomography is a nondestructive procedure to quantify the osseous volume prior to transplantation.^{10,11} In an animal study, Buchman and colleagues¹² concluded that microcomputed tomography can measure changes in bone stereology, volume, and micro-architecture, while others have questioned the accuracy and reproducibility of caliper or cephalometric measurements because of bone irregularities and human error.^{12–15} The clinical applications of computerized tomography are increasing and include diagnosis, surgical treatment planning prior to implant placement, and the outcome assessment of regenerative therapies.^{10,15–17} The AutoCAD software program used in the present project did not overestimate the volume of bone that can be safely harvested from the mandibular ramus.

The thickest buccal cortical plate measured in the present study was at the second molar area

(2.8 \pm 0.7 mm), and the thinnest one immediately posterior to the third molar (1.9 \pm 0.3 mm). Rajchel and colleagues¹⁸ examined cross-sections of 45 intact adult cadaver mandibles and measured similar apical cortical thickness (M₂: 2.3 \pm 0.7 mm and dM₃: 1.5 \pm 0.4 mm). The crestal cortical thickness was not reported in the Rajchel study. When combined M₂–M₃ areas, an average

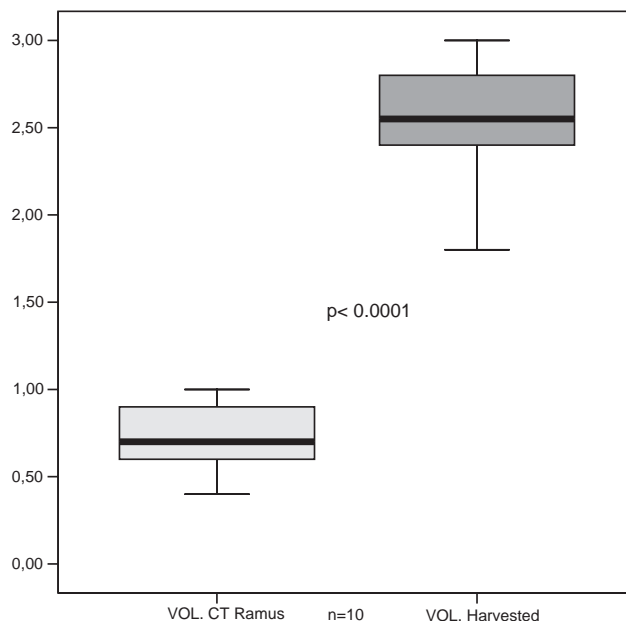


Figure 7 Intra-surgical versus tomographic measurements of ramus volume.

cortical plate of 2.8 mm provided 2.5 mL of particulated volume (see Figure 2). When compared to the mandibular symphysis graft, a slightly higher cortical thickness was obtained from the mandibular ramus (2.4 vs 2.2 mm).¹⁰

Donor site morbidity is a factor to consider when selecting mandibular ramus as a source of bone grafting, although the reported postoperative complications are not frequent. Stiffness and limited mobilization of the vestibule along with altered and decreased sensibility in the adjacent innervated areas can be prevented when proper surgical execution is performed. Recovery is influenced by the patient's age and direct surgical injuries.¹⁹ Myelinic and amyelinic small-diameter fibers such as those conducting thermal and nociceptive sensation seem to recover much faster than myelinic larger diameter fibers (conducting discriminative and epicritic sensation).^{20–22} In the present study, the incidence of temporary altered sensation in the form of hypoesthesia was 10% and lasted no more than 3 months. The most frequent disturbance was impaired sensibility in the soft tissues of the posterior vestibule. No apical pathology around the mandibular teeth was detected. Clavero and Lundgren²³ compared the donor site morbidity and complications between the mandibular ramus and symphysis. Altered sensation was diagnosed in 16 of the 53 patients at 18 months. Fifteen belonged to the symphysis group (impaired nerve function was related to the mental nerve branches), and only one to the ramus group (impaired nerve function was related to the buccal nerve injury).

The repair of the donor site has not been reported in the literature. In the present study, the healing of the donor site was not evaluated. In a long-term retrospective examination post-symphysis graft, Weibull and colleagues²⁴ reported that the rate of subjective symptoms was higher than the clinical findings. The cephalometric examination in 45 patients showed good remineralization in 42 (93.3%). However, bone healing after symphysis graft did not show regeneration to the preoperative level, and a radiologic concavity was detected in the majority of cases. Investigations are granted to evaluate the osseous repair at the mandibular ramus donor site.

CONCLUSIONS

The mandibular second molar area provided the thickest cortical graft averaging 2.8 ± 0.7 mm (range 2.0–

4.2 mm). A cortical plate of 2.8 mm in average at combined M₂–M₃ area provided a minimum of 2.5 mL particulated volume. The use of the design software program can improve surgical treatment planning prior to autogenous bone grafting. The AutoCAD software program did not overestimate the volume of bone that can be safely harvested from the mandibular ramus.

ACKNOWLEDGMENTS

We would like to thank Dr. Alon Frydman and Dr. Jose Maria Malfaz for their assistance with the clinical figures.

REFERENCES

1. Canalis E. Effect of growth factors on bone cell replication and differentiation. *Clin Orthop Relat Res* 1985; 193:246–263.
2. Reddi AH, Wientroub S, Muthukumaran N. Biologic principles of bone induction. *Orthop Clin North Am* 1987; 18:207–212.
3. Zins JE, Whitaker LA. Membranous vs endochondral bone autografts: implications for craniofacial reconstruction. *Plast Reconstr Surg* 1983; 72:778–785.
4. Ozaki W, Buchman SR. Volume maintenance of onlay bone grafts in the craniofacial skeleton: micro-architecture versus embryologic origin. *Plast Reconstr Surg* 1998; 102:291–299.
5. Jensen J, Sindet-Pedersen S. Autogenous mandibular bone grafts and osseointegrated implants for reconstruction of the severely atrophied maxilla. A preliminary report. *J Oral Maxillofac Surg* 1991; 49:1277–1287.
6. Williamson RA. Rehabilitation of the resorbed maxilla and mandible using autogenous bone grafts and osseointegrated implants. *Int J Oral Maxillofac Implants* 1996; 11:476–488.
7. Albrektsson T. Repair of bone grafts. A vital microscopic and histologic investigation in the rabbit. *Scand J Plast Reconstr Surg* 1980; 14:1–12.
8. Güngörmüs M, Yilmaz AB, Ertas U, Akgul HM, Yavuz MS, Harorli A. Evaluation of the mandible as an alternative autogenous bone source for oral and maxillofacial reconstruction. *J Int Med Res* 2002; 30:260–264.
9. Güngörmüs M, Yavuz MS. The ascending ramus of the mandible as a donor site in maxillofacial bone grafting. *J Oral Maxillofac Surg* 2002; 60:1316–1318.
10. Verdugo F, Simonian K, Smith McDonald R, Nowzari H. Quantification of mandibular symphysis volume as a source of bone grafting. *Clin Implant Dent Relat Res* 2009; DOI 10.1111/j.1708-8208.2008.00140.x. [Epub ahead of print]
11. Lu M, Rabie AB. Quantitative assessment of early healing of intramembranous and endochondral autogenous bone grafts using micro-computed tomography and Q-win image analyzer. *Int J Oral Maxillofac Surg* 2004; 33:369–376.

12. Buchman SR, Sherick DG, Goulet RW, Goldstein SA. Use of microcomputed tomography scanning as a new technique for the evaluation of membranous bone. *J Craniofac Surg* 1998; 9:48–54.
13. Feldcamp LA, Goldstein SA, Parfitt AM, Jesion G, Kleerekoper M. The direct examination of three-dimensional bone architecture in vitro by computed tomography. *J Bone Miner Res* 1989; 4:3–11.
14. Kuhn JL, Goldstein SA, Feldkamp LA, Goulet RW, Jesion G. Evaluation of a microcomputed tomography system to study trabecular bone structure. *J Orthop Res* 1990; 8:833–842.
15. Peker I, Alkurt MT, Mihcioglu T. The use of 3 different imaging methods for the localization of the mandibular canal in dental implant planning. *Int J Oral Maxillofac Implants* 2008; 23:463–470.
16. Ito K, Yoshinuma N, Goke E, Arai Y, Shinoda K. Clinical application of a new compact computed tomography system for evaluating the outcome of regenerative therapy: a case report. *J Periodontol* 2001; 72:696–702.
17. Bhatavadekar NB, Paquette DW. Long-term follow-up and tomographic assessment of an intrabony defect treated with enamel matrix derivative. *J Periodontol* 2008; 79:1802–1808.
18. Rajchel J, Ellis E, Fonseca RJ. The anatomical location of the mandibular canal: its relationship to the sagittal ramus osteotomy. *Int J Adult Orthodon Orthognath Surg* 1986; 1:37–47.
19. Nishioka GJ, Zysset MK, Van Sickels JE. Neurosensory disturbance with rigid fixation of the bilateral sagittal split osteotomy. *J Oral Maxillofac Surg* 1987; 45:20–26.
20. Rosenberg A, Sailer HF. A prospective study on changes in the sensibility of oral mucosa and the mucosa of the upper lip after Le Fort I osteotomy. *J Craniomaxillofac Surg* 1994; 22:286–290.
21. Jacks SC, Zuniga JR, Turvey TA, Schalit C. A retrospective analysis of lingual nerve sensory changes after mandibular bilateral sagittal split osteotomy. *J Oral Maxillofac Surg* 1998; 56:700–704.
22. Cunningham LL, Tiner BD, Clarck GM, Bays RA, Keeling SD, Rugh JD. A comparison of questionnaire versus monofilament assessment of neurosensory deficit. *J Oral Maxillofac Surg* 1996; 54:454–460.
23. Clavero J, Lundgren S. Ramus or chin grafts for maxillary sinus inlay and local onlay augmentation: comparison of donor site morbidity and complications. *Clin Implant Dent Relat Res* 2003; 5:154–160.
24. Weibull L, Widmark G, Ivanoff CJ, Borg E, Rasmusson L. Morbidity after chin bone harvesting – retrospective a long-term follow-up study. *Clin Implant Dent Relat Res* 2009; DOI: 10.1111/j.1708-8208.2008.00102.x. [Epub ahead of print]