

# Metastasis of Hepatocellular Carcinoma into the Mandible with Radiographic Findings Mimicking a Radicular Cyst: A Case Report

Hisako Fujihara, DDS, PhD,<sup>\*†</sup> Daichi Chikazu, DDS, PhD,<sup>†</sup> Hideto Saijo, DDS, PhD,<sup>†</sup> Hideyuki Suenaga, DDS, PhD,<sup>†</sup> Yoshiyuki Mori, DDS, PhD,<sup>†</sup> Mitsuyoshi Iino, DDS, PhD,<sup>†</sup> Yoshiki Hamada, DDS, PhD,<sup>\*</sup> and Tsuyoshi Takato, MD, PhD<sup>†</sup>

## Abstract

**Introduction:** Hepatocellular carcinoma (HCC) is a common neoplasm worldwide, with more than half of the tumors associated with regional metastasis. Extrahepatic metastasis is also common, and the most frequently affected sites are the lungs, abdominal lymph nodes, diaphragm, and bone. However, HCC metastasis to the mandible is rare, with approximately 50 cases reported in the literature. **Methods:** In this report, we describe a case of HCC metastasis to the mandible at the apex of #18 root in a 62-year-old man. This patient had already been diagnosed with metastasis to pancreatic caput lymph node. The radiographic features of the mandible resembled radicular cyst and did not show typical findings of malignancy. **Results:** Under the first diagnosis of radicular cyst, root canal treatment was initially performed, and then surgical treatment of the removal of the cystic lesion and #18 extraction were performed. Finally, the lesion was diagnosed as HCC metastasis from pathological examination. Consequently, he received constitutional chemotherapy in the hepatitis unit and is now in remission. **Conclusion:** This case shows the importance of considering the differential diagnosis of malignancy. (*J Endod* 2010; **■**:1–4)

## Key words

Carcinoma, diagnosis, hepatocellular carcinoma, metastasis to mandible, radicular cyst

From the \*Department of Oral and Maxillofacial Surgery, School of Dental Medicine, Tsurumi University, Kanagawa, Japan; and †Department of Oral-maxillofacial Surgery, Dentistry and Orthodontics, The University of Tokyo Hospital, Tokyo, Japan.

Address requests for reprints to Dr Hisako Fujihara, Department of Oral and Maxillofacial Surgery, School of Dental Medicine, Tsurumi University, 2-1-3, Tsurumi, Tsurumi-ku, Yokohama, Kanagawa 230-8501, Japan. E-mail address: fujihara-h@tsurumi-u.ac.jp.

0099-2399/\$0 - see front matter

Copyright © 2010 American Association of Endodontists.  
doi:10.1016/j.joen.2010.05.009

Hepatocellular carcinoma (HCC) is the fifth most common cancer. It is estimated that 8,500 to 11,500 new cases of HCC occur annually in the United States, with a relatively higher frequency reported in Southeast Asia including Japan (1, 2). Among all HCC patients, more than 25% of patients are reported to have extrahepatic metastasis, with 10.1% of patients showing bone metastasis (3). The preferred site is the vertebrae, followed by the ribs, sternum, and pelvis in decreasing order. The mandible is an uncommon site of extrahepatic metastasis of HCC. Here, we report a rare case of HCC metastasis to the mandible with characteristic radiographic findings mimicking radicular cyst at the apex of the molar root.

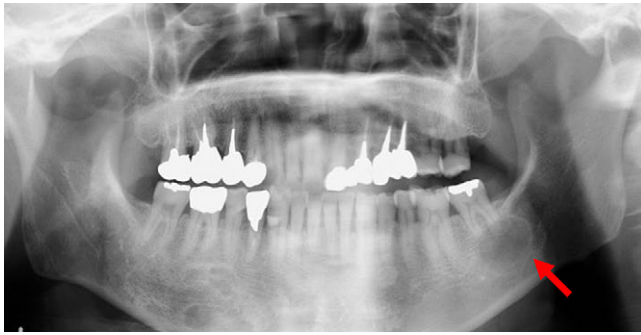## Case Report

A 62-year-old Japanese man was referred to the Department of Oral-maxillofacial Surgery, Dentistry and Orthodontics, the University of Tokyo Hospital, with a chief complaint of slight swelling and discomfort of the left mandible. The symptoms were noticed 1 month previously. He did not suffer from any paralysis, pain, or dyskinesia. He had a history of HCC caused by hepatitis C infection from a transfusion of coagulation factor VIII blood product for hemophilia A. For the treatment of HCC, he had undergone transcatheter arterial embolization and radiofrequency ablation when he was 57 years old. He later underwent resection of the S8 liver area when he was 61 years old.

The clinical examination showed a soft, painless slight swelling in the left mandibular angle region, with no trismus or neurologic problems such as mental nerve paresthesia or facial nerve paralysis. Intraorally, he had healthy dentition with good oral hygiene and a normal mucous membrane. There was slight swelling of the buccal side of the #18 gingiva. An old composite resin restoration was noted on the occlusal aspect of #18. The tooth responded negatively to electric pulp vitality test, and no discomfort or pain was noted on percussion. On the mesiobuccal aspect of the tooth, the probing depth measured 4 mm, whereas the mobility of the tooth was within normal limits. On panoramic x-ray examination, a radiolucent, well-defined lesion about 20 mm in diameter consistent with the appearance of a radicular cyst was observed at the apex of #18 (Fig. 1). Root absorption of #18 was unclear. On computed tomographic (CT) images, a smooth circular lesion was also observed in the same region. A slight resorption of the buccal cortical bone was observed on horizontal slices (Fig. 2A and B). The correlation between the apex of #18 and the circular lesion was not clear even on the CT images, and, unfortunately, dental x-ray examination was impossible because of his vomiting reflex. There were also small circular radiolucent lesions in the right mandibular body in the #29 and #30 regions. On CT images, these several small circular lesions were also observed on the relatively lingual side of the mandible.

Laboratory data revealed slight anemia (hemoglobin = 11.2 g/dL) and a decreased platelet count ( $8.9 \times 10^4$  /mm<sup>3</sup>), but other blood cell counts were within normal limits. Coagulation factors were also within normal limits, and his coagulability was as follows: prothrombin time = 12.5 seconds and 71.7%, international normalized ratio = 1.42, activated partial thromboplastin time = 54.7 seconds, and fibrinogen = 239 units. Hepatic-related factors were as follows: lactate dehydrogenase = 264 IU/L, glutamic

## Case Report/Clinical Techniques



**Figure 1.** Radiologic findings: pantomography at the first referral. The red arrows indicate a radiolucent circular lesion at the apex of #18. There were also radiolucent lesions in the body of the right mandible below teeth #29 and #30.

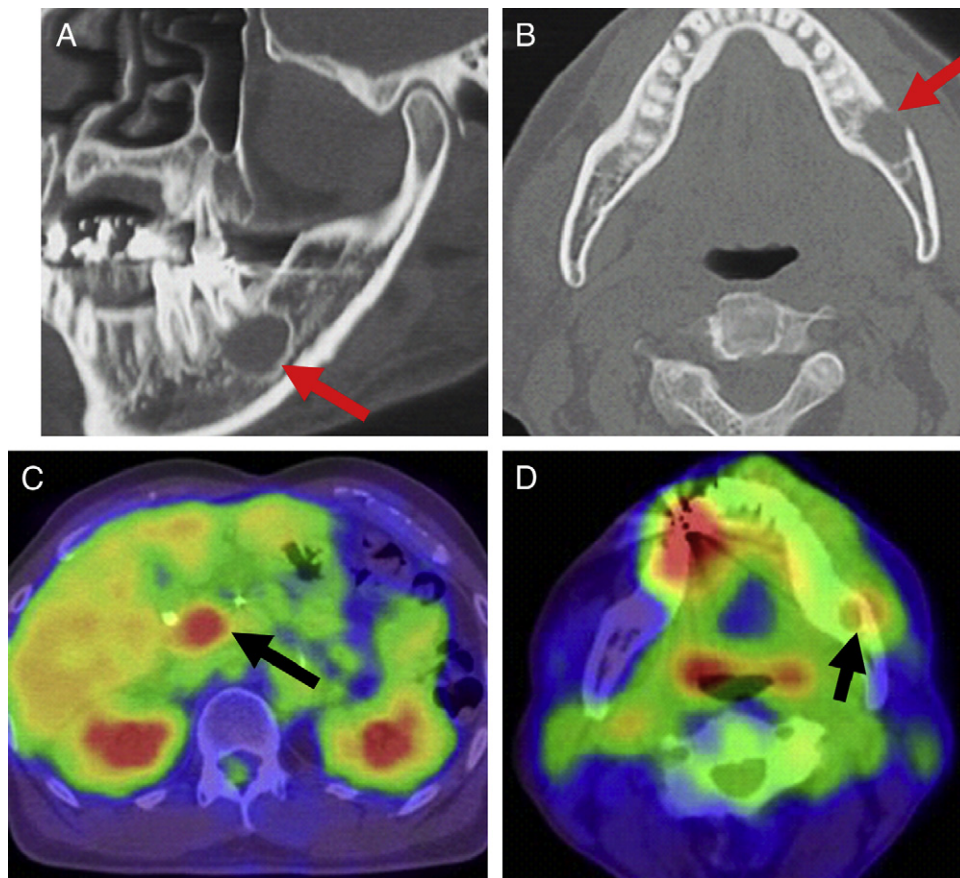
oxaloacetic transaminase = 87 IU/L, glutamic pyruvic transaminase = 74 IU/L, gamma-glutamyl transpeptidase = 66 IU/L, and alpha-fetoprotein (AFP) = 346 IU/L. Tumor markers showed relatively high AFP and AFP-L3 (lectin 3) levels of 158.5 ng/mL and 41.1%, respectively.

At his first visit to our department, HCC metastasis to a caput pancreatic lymph node had already been diagnosed based on positron emission tomography-CT images (Fig. 2C), which was consistent with the high AFP level. On the PET-CT images, high accumulations were

also observed at the mandibular level (Fig. 2D). The apex of #18 showed accumulation, and stronger accumulation was observed in the #28 region. The standard uptake value (SUV) of the apex of #18 was 4.7, and the SUV of the #28 region was 7.9 or 23.7 with artifact.

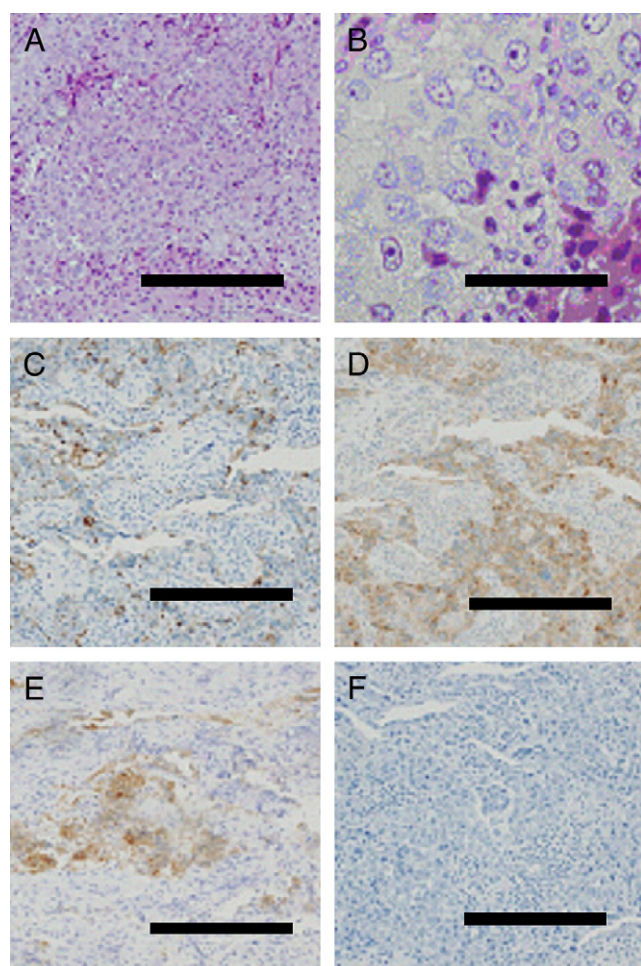
On comparison with pantomography, periodontitis and the metal-cast prosthetic of #28 were considered to be the cause of the accumulation. The SUV of the caput pancreas lymph node was 8.0 and that of the liver was 5.4. These PET-CT images were consistent with other radiologic findings.

On the basis of these findings, this lesion was diagnosed as a #18 radicular cyst with little possibility of malignant tumor or other pathology unrelated to the tooth. Because his systemic condition was poor, planned surgical treatment of #18 was amended to root canal treatment. To start the root canal treatment, a conventional endodontic access opening was made with a rubber dam placement. An access cavity was prepared, and the root canal was instrumented with stainless steel hand files until an apical stop of ISO #40 could be created. Persistent seepage of dark red, muddy exudate through the root canal diminished gradually with instrumentation. The root canal was irrigated frequently with 1.3% sodium hypochlorite followed by a final rinse with 5 mL sterile saline. Subsequently, sterilized cotton with iodine was placed, and the access cavity was temporarily sealed with sterile cotton with Sandarac Vanish (G.C., Tokyo, Japan). At the next visit, the root canal was reentered and irrigated alternately with 1.3% sodium hypochlorite and sterile saline with a crown-down technique.



**Figure 2.** CT and CT-PET images: (A) sagittal CT image. The red arrow indicates a lesion with a clear, smooth margin resembling a radicular cyst of #18. (B) A horizontal CT image. The red arrow indicates slight bone absorption of the outer side of the cortical bone. (C) A PET image of the abdomen. The black arrow indicates pancreatic head lymph node metastasis. This diagnosis had already been made before the first referral. (D) A PET image of the oral region. The red spot in the right premolar region was suggested to be periodontitis of #28 by clinical symptoms. The red arrow points to yellow spot that shows less suggestion of malignancy compared with red spot. This lesion was finally diagnosed as HCC metastasis.

During root canal treatment for 2 months, the swelling of the buccal mucosa of #18 decreased. However, it suddenly became prominent. Therefore, conservative root canal treatment was thought to be ineffective for this cystic lesion, so extraction of #18 was inevitable. At that time, his general condition had improved, and surgical removal of the cystic lesion concomitant with extraction of #18 was performed under general anesthesia with replenishment of coagulation factor VIII (Advate; Baxter, Deerfield, IL). Surprisingly, the cystic lesion was composed of soft solid tissue suspected to be a tumorous lesion. The specimen was pathologically analyzed with hematoxylin-eosin staining, and immunostained for hepatocytes, glypican-3 (GPC-3), alphafetoprotein (AFP), and cytokeratin (CAM 5.2). Hematoxylin-eosin staining showed the lesion to have an alveolar or trabecular pattern. Eosinophilic granules in abundant cytoplasm, mild nuclear pleomorphism, prominent nucleoli, and numerous mitotic figures were observed in the thick-walled lesion (Fig. 3A and B). Additional immunohistochemical study revealed that the tumor cells were positive for hepatocyte-specific antigen (Fig. 3C), GPC-3 (Fig. 3D), and CAM 5.2 (Fig. 3E)



**Figure 3.** Histopathological findings of the specimen. (A) Hematoxylin-eosin staining: the lesion was composed of atypical cells showing an alveolar or fascicular pattern, with eosinophilic granules in the cytoplasm. There are well-developed trabecular patterns and cells with abundant cytoplasm, mild nuclear pleomorphism, prominent nucleoli, and numerous mitotic figures. The bar indicates 50 mm. (B) A higher magnification of the same section. The bar indicates 10 mm. (C-F) Immunohistochemical reaction was positive for (C) hepatocyte, (D) GPC-3, and (E) CAM 5.2 and negative for (F) AFP. Bars from C to F indicate 50 mm.

but negative for AFP (Fig. 3F). Considering these findings, this specimen was diagnosed as HCC metastasis to the oral region.

Immediately after the diagnosis was made, he was transferred to the hepatitis unit and underwent systemic chemotherapy with fluorouracil (5-FU) and irradiation treatment. Since the completion of this treatment, he has been in remission for 6 months.

## Discussion

HCC is the most common malignant tumor of the liver. The number of new HCC patients is approximately 500,000 to 1 million per year and is increasing (2). HCC usually undergoes intrahepatic metastasis in the early stages, and only 25% of HCC patients develop extrahepatic metastasis. The preferred sites are the lungs (34%-70%), regional lymph nodes (16%-45%), and bone (6% in vertebrae, ribs, and long bones) (4-9). However, HCC metastasis to the mandible is very rare. Since Dick et al (10) first reported a case of HCC metastasis to the mandible in 1957, approximately 50 cases have been documented in the literature to our knowledge (11-23). Patients ranged from 25 to 88 years, with a mean age of 63.9 years; 47 were male, and 2 were female. The mandible is the most commonly affected area in the oral and maxillofacial region. This age and sex predilection resembles that of primary HCC, which frequently occurs in men and takes several years to metastasize to the oral and maxillofacial region. Several pathways of HCC metastasis to the oral region have been postulated. One of them is hematogenous pathway; the tumor reaches the circulation through invasion of hepatic arterial and/or portal venous branches. Most oral metastases are associated with lung metastases, and they possibly occur by this route (24). Another possible pathway of metastasis is an anastomotic network of paravertebral veins that bypasses the pulmonary, inferior caval and portal venous circulations (25, 26). This pathway may be responsible for metastasis to the vertebral bodies, which are the preferred site of bony HCC metastasis. This could be the most likely pathway from HCC without pulmonary metastasis, as observed in our patient (27, 28).

On the other hand, the mandibular angle and body have a rich blood supply, and blood flow slows down in this area, allowing deposition of metastatic cells (29). This is the main reason that the mandible is the most commonly involved region. Moreover, it could also be hypothesized that the pulp in tooth #18 became necrotic with a developing periapical lesion. The increased area of inflammation would result in an increased blood flow with more permeable vessel walls, which may allow deposition of metastatic cells. Although the exact pathway of HCC metastasis to the apex of #18 in our patient is still unclear, the previously mentioned pathways would be reasonable because the apex of #18 is positioned near the mandibular angle and body.

Radiographically, all reported cases of HCC metastasis to the mandible showed findings suspicious of tumor, such as tumor mass formation in the bone (10-14, 17-19, 21, 23, 24), osteolytic lesions (14, 16, 20, 22), and ill-defined borders (3, 10, 11, 15). The present case was quite different from these reported patients in that (1) the site of metastasis was the apex of #18 and (2) the margin of the lesion was clearly defined in x-rays. Moreover, the SUV of the PET of the apex of #18 was only 4.7 although that of the pancreatic caput lymph node metastasis was 8.0. This result did not suggest malignancy of the #18 apex lesion because the SUV of malignant lesions ranges from 7.0 to 9.0. Consequently, this patient was not diagnosed as having metastatic HCC to the mandible, and malignancy was excluded initially. The relation between the #18 root and the lesion was still obscure; therefore, the lesion was not clarified as being odontogenic or not. The first period of root canal treatment seemed to be effective because swelling

## Case Report/Clinical Techniques

of the buccal mucosa decreased. Fortunately, his general condition had recovered when the lesion became prominent again, and extraction of #18 and removal of the lesion were performed. Finally, the pathological diagnosis of HCC metastasis to the mandible was made.

There were also several small circular radiolucent lesions in the right mandible body in the #29 and #30 region. On CT images, they were observed on the lingual side in horizontal slices. Moreover, the patient had never had objective or subjective symptoms in the right mandible from the first time of his referral. Before starting the root canal treatment for #18, these lesions were compared with the findings of pantomography performed by his general practitioner 5 years before his treatment. Similar lesions in the right mandible were also observed in the old pantomograph, and their diameters and positions were almost identical; these lesions were diagnosed as static bone cysts or other benign lesions. There was no cystic lesion at the apex of #18. After the cystic lesion of #18 was diagnosed as HCC metastasis, we considered re-diagnosing with a pathological examination of the right mandibular lesions because they might possibly have had the same diagnosis.

However, we dared to postpone the pathological examination for several reasons: (1) the lesions had been there before the cystic lesion of #18 apex occurred; (2) they were deep below the buccal cortical bone, and biopsy would be more invasive and more difficult to coagulate than the removal of #18 cystic lesion and extraction; and (3) in the case that they were malignant, chemotherapy would be effective. Six months after chemoradiotherapy, the lesions of the right mandible had not increased and did not cause any symptoms. In fact, the definitive diagnosis of the right mandibular radiolucent lesions was still unclear.

Patients with HCC have a relatively good survival rate, with a 5-year cumulative survival rate of more than 50% when surgical treatment is performed (30). However, when there is bone metastasis, the survival rate decreases sharply; 1-year survival is 15% to 20%, and 2-year survival is around 4% (31–33). The present patient was still alive and in remission 6 months after the diagnosis of HCC metastasis to the mandible after effective chemotherapy in the hepatitis unit of our hospital.

In conclusion, this report describes the unusual features of a case of oral metastatic HCC in which the lesion was located at the apex of a root with the appearance of a radicular cyst. This case shows that clinicians should consider the possibility of malignancy in the differential diagnosis, even if a malignant lesion is not suggested by the clinical findings, especially in patients with a history of a malignant tumor.

### References

1. Kuhlman JE, Fishman EK, Leichner PK, et al. Skeletal metastases from hepatoma: frequency, distribution, and radiographic features. *Radiology* 1986;160:175–8.
2. Anthony PP. Hepatocellular carcinoma: an overview. *Histopathology* 2001;39:109–18.
3. Yoshimura Y, Matsuda S, Naitoh S. Hepatocellular carcinoma metastatic to the mandibular ramus and condyle: report of a case and review of the literature. *J Oral Maxillofac Surg* 1997;55:297–306.
4. Natsuizaka M, Omura T, Akaike T, et al. Clinical features of hepatocellular carcinoma with extrahepatic metastases. *J Gastroenterol Hepatol* 2005;20:1781–7.
5. Cha C, Fong Y, Jarnagin WR, et al. Predictors and patterns of recurrence after resection of hepatocellular carcinoma. *J Am Coll Surg* 2003;197:753–8.

6. Katal S, Oliver JH, Peterson MS, et al. Extrahepatic metastases of hepatocellular carcinoma. *Radiology* 2000;216:698–703.
7. Tunc B, Filik L, Tezer-Filik I, et al. Brain metastasis of hepatocellular carcinoma: a case report and review of the literature. *World J Gastroenterol* 2004;10:1688–9.
8. Chang JY, Ka WS, Chao TY, et al. Hepatocellular carcinoma with intra-atrial tumor thrombi. A report of three cases responsive to thalidomide treatment and literature review. *Oncology* 2004;67:320–6.
9. Chang L, Chen YL, Kao MC. Intracranial metastasis of hepatocellular carcinoma: review of 45 cases. *Surg Neurol* 2004;62:172–7.
10. Dick A, Mead SG, Mensh M, et al. Primary hepatoma with metastasis to the mandible. *Am J Surg* 1957;94:846–50.
11. Pires FR, Sagarra R, Correa ME, et al. Oral metastasis of a hepatocellular carcinoma. *Oral Surg Oral Med Oral Pathol Oral Radiol Endod* 2004;97:359–68.
12. Ramon Ramirez J, Seoane J, Montero J, et al. Isolated gingival metastasis from hepatocellular carcinoma mimicking a pyogenic granuloma. *J Clin Periodontol* 2003;30:926–9.
13. Arai R, Otsuka T, Mori K, et al. Metastasis of hepatocellular carcinoma to the supra-maxillary gingiva and right ventricle. *Hepatogastroenterology* 2004;51:1159–61.
14. Junquera L, Rodriguez RC, Torre A, et al. Hepatocellular carcinoma metastatic to the mandible: a case involving severe hemorrhage. *Med Oral* 2004;9:345–9.
15. Niedzielska I, Langowska AH, Pajak J, et al. Mandible metastasis of hepatocellular carcinoma. *Wiad Lek* 2004;57:392–4.
16. Chen SY, Cheng PW, Tsai CC. Pathology quiz case: mandibular metastasis of hepatocellular carcinoma. *Arch Otolaryngol Head Neck Surg* 2005;131:735–6.
17. Teshigawara K, Kakizaki S, Sohara N, et al. Solitary mandibular metastasis as an initial manifestation of hepatocellular carcinoma. *Acta Med Okayama* 2006;60:243–7.
18. Han L, Bhan R, Zak I, et al. Metastatic hepatocellular carcinoma to the mandible masquerading as a parotid gland mass: a potential pitfall in the diagnosis by fine needle aspiration biopsy. *Diagn Cytopathol* 2007;35:674–6.
19. Huang SF, Wu RC, Chang JT, et al. Intractable bleeding from solitary mandibular metastasis of hepatocellular carcinoma. *World J Gastroenterol* 2007;13:4526–8.
20. Kamatani T, Tatemoto Y, Tateishi Y, et al. Isolated metastasis from hepatocellular carcinoma to the mandibular condyle with no evidence of any other metastases: a case report. *Br J Oral Maxillofac Surg* 2008;46:499–501.
21. Li R, Walvekar RR, Nalesnik MA, et al. Unresectable hepatocellular carcinoma with a solitary metastasis to the mandible. *Am Surg* 2008;74:346–9.
22. Piot B, Adam P, Sagan C, et al. Mandibular metastasis of hepatocellular carcinoma. Apropos of 3 cases. *Rev Stomatol Chir Maxillofac* 1994;95:431–4.
23. Zanirato S, Porta C, Moroni M, et al. Jaw bone metastasis from hepatocellular carcinoma. *Ital J Gastroenterol Hepatol* 1997;29:478–9.
24. Takinami S, Yahata H, Kanoshima A, et al. Hepatocellular carcinoma metastatic to the mandible. *Oral Surg Oral Med Oral Pathol Oral Radiol Endod* 1995;79:649–54.
25. Batson OV. The vertebral system of veins as a means for cancer dissemination. *Prog Clin Cancer* 1967;3:1–18.
26. Batson OV. The function of the vertebral veins and their role in the spread of metastases. 1940. *Clin Orthop Relat Res* 1995;312:4–9.
27. Hirshberg A, Leibovich P, Buchner A. Metastases to the oral mucosa: analysis of 157 cases. *J Oral Pathol Med* 1993;22:385–90.
28. Hirshberg A, Shnaiderman-Shapiro A, Kaplan I, et al. Metastatic tumours to the oral cavity - pathogenesis and analysis of 673 cases. *Oral Oncol* 2008;44:743–52.
29. Romanas MM, Cherian R, McGregor DH, et al. Hepatocellular carcinoma diagnosed by fine-needle aspiration of the parotid gland. *Diagn Cytopathol* 2004;30:401–5.
30. Schwarz RE, Smith DD. Trends in local therapy for hepatocellular carcinoma and survival outcomes in the US population. *Am J Surg* 2008;195:829–36.
31. Seong J, Koom WS, Park HC. Radiotherapy for painful bone metastases from hepatocellular carcinoma. *Liver Int* 2005;25:261–5.
32. Taki Y, Yamaoka Y, Takayasu T, et al. Bone metastases of hepatocellular carcinoma after liver resection. *J Surg Oncol* 1992;50:12–8.
33. Kaizu T, Karasawa K, Tanaka Y, et al. Radiotherapy for osseous metastases from hepatocellular carcinoma: a retrospective study of 57 patients. *Am J Gastroenterol* 1998;93:2167–71.