

# Dentine removal in the coronal portion of root canals following two preparation techniques

G. Plotino<sup>1</sup>, N. M. Grande<sup>1</sup>, A. Falanga<sup>2</sup>, I. L. Di Giuseppe<sup>3</sup>, V. Lamorgese<sup>3</sup> & F. Somma<sup>1</sup>

<sup>1</sup>Department of Endodontics, Catholic University of the Sacred Heart, Rome, Italy; <sup>2</sup>Private practice, London, UK; and <sup>3</sup>Private practice, Rome, Italy

## Abstract

**Plotino G, Grande NM, Falanga A, Di Giuseppe IL, Lamorgese V, Somma F.** Dentine removal in the coronal portion of root canals following two preparation techniques. *International Endodontic Journal*, **40**, 852–858, 2007.

**Aim** To measure the root canal area and the reduction of the mesial and buccal/lingual wall thickness at the level of the coronal interference in mesial roots of mandibular molars after instrumentation with a crown-down or a simultaneous root canal preparation technique.

**Methodology** Twenty mesial roots of first mandibular molars with a moderate root canal curvature were embedded in resin and sectioned horizontally at the level of the coronal interference, using a modification of the Bramante technique. After scanning and processing, the sections were reassembled. One root canal of each root was prepared using ProTaper instruments, while Mtwo instruments were used in the other root canal of the same mesial root. After scanning and processing, the data obtained were analysed for two

parameters: changes in root canal area after instrumentation ( $\Delta A$ ) and reduction of the mesial and buccal/lingual wall thickness ( $\Delta T$ ). The data were subjected to Student's *t*-tests for statistical analysis at a significance level of  $P < 0.05$ .

**Results** No statistically significant differences were found between the two groups with respect to the changes in the areas ( $\Delta A$ ) at the level considered ( $P = 0.410$ ). No statistically significant differences were noticed between the two groups for dentine thickness ( $\Delta T$ ) of both the mesial wall ( $P = 0.077$ ) and the buccal or lingual wall ( $P = 0.171$ ).

**Conclusions** There was no difference between the ProTaper and Mtwo groups for the amount of dentine removed.

**Keywords:** crown-down technique, dentine thickness, Ni–Ti rotary instruments, root canal instrumentation, simultaneous technique.

Received 19 December 2006; accepted 20 March 2007

## Introduction

In recent years, interest in Ni–Ti rotary instruments has grown, representing a new approach to canal shaping (Thompson 2000). In order to reduce the risk of Ni–Ti instrument fracture, flaring the coronal portion of root canals has been emphasized (Ruddle 2002), thus allowing the removal of all interferences in the coronal and middle thirds of the canal, and, consequently, allowing instruments to reach more easily the critical area of the apical third.

Mtwo endodontic instruments have been introduced recently. Mtwo instruments are used in a simultaneous technique (Plotino *et al.* 2006) without early coronal enlargement. Each instrument being taken to working length without apical pressure. As soon as the clinician experiences a binding sensation, the instrument is withdrawn 1–2 mm, so that it can be worked with a brushing action to selectively remove the interferences and to advance towards the apex. The instruments are used with a lateral pressing movement in order to obtain a circumferential cut and to eliminate at the orifice as much dentine as is needed, to allow the instrument to reach the end-point of preparation, thus producing a selective coronal enlargement.

Correspondence: Dr Gianluca Plotino, Via Eleonora Duse 22, 00197 Rome, Italy (Tel.: +393396910098; fax: +390688644341; e-mail: gplotino@fastwebnet.it).

It is generally accepted that the amount of remaining dentine is directly related to the strength of the tooth (Guzy & Nicholls 1979, Mondelli *et al.* 1980, Morfis 1990, Felton *et al.* 1991, Trope & Ray 1992, Pilo *et al.* 1998, Lertchirakarn *et al.* 2002, Wu *et al.* 2004). The thickness of the dentinal wall at the root circumference is critical, and there is a direct correlation between the root thickness and the ability of the tooth to resist lateral forces and avoid fracture (Rosen & Partida-Rivera 1986, Assif & Gorfil 1994).

The purpose of this study was to use a muffle model to measure root canal area and the reduction of the mesial and buccal or lingual wall thickness at the level of the coronal interference in the mesial roots of mandibular molars after instrumentation with either a crown-down or a simultaneous root canal preparation technique.

## Materials and methods

Twenty human first mandibular molar teeth were selected from a pool of freshly extracted teeth. The teeth were cleaned in 5% NaOCl solution for 24 h, carefully debrided of periodontal tissue and calculus, washed under running water, blot dried and stored in 10% formalin solution. The criteria for selection were the following. Each tooth had to have two separate roots with fully formed apices, no restorations should be present and the crowns had to be intact without defects or caries. Roots with resorption, fractures, open apices or radiographically invisible canals were excluded.

The cusps of all teeth were flattened with a tapered diamond bur in a high-speed hand piece with air/water spray irrigation to establish a flat surface that served as a stable reference position. Occlusal access preparations were completed with a high-speed cylindrical diamond bur (Komet No. 6881; Komet-Brasseler, Lemgo, Germany) using water-cooling. Mesial root canals were initially scouted with hand K-files sizes 08 and 10 without any attempt to enlarge the canal with the instruments. Canal patency was assessed using a size 10 K-Flexofile (Dentsply Maillefer, Ballaigues, Switzerland) to discard any teeth with canal obstructions. To facilitate manipulation of the samples, each mesial root was sectioned entirely and separated from the distal one.

Two preliminary radiographs of each mesial root with a size 10 K-file inserted in each canal were exposed in a bucco-lingual and mesio-distal direction. Exposure time and x-ray processing techniques were standardized. The radiographs were evaluated in

ambient room light, using a viewing box and 3.5× loupes. The radiographs were used to determine if there were canals that merged; such roots were excluded.

Only teeth with a moderate root canal curvature of the mesial root of 10–35° (Schneider 1971), were included. Mesial roots with abrupt apical curvatures (with a radius of curvature  $\leq 2$  mm in the last 3 mm), were excluded.

The working length of the canals was determined by observing the tip of the file protruding through the apical foramen and subtracting 0.5 mm from the recorded length. The apical foramen was identified and coated with Fermit (Ivoclar Vivadent, Schaan, Liechtenstein), an elastic light-curing temporary restorative material. The teeth were then embedded in a stainless steel muffle, as described by Kuttler *et al.* (2001), using an auto-curing acrylic resin (Ortho Jet; Lang Dental MFG, Wheeling, IL, USA). Care was taken to ensure that the long axis of the teeth in the area of interest were positioned perpendicular to the horizontal plane. The level of the coronal interference at the orifice of the root canals was determined using a periodontal probe and the registered depth was marked on the external surface of the tooth. The resin blocks were sectioned at the level of the coronal interference, resulting in two blocks representing subsequently the coronal and apical portion of the tooth. Sections were cut using a water-cooled diamond wavering blade at low speed (Exact BS310; BioOptica, Milan, Italy).

The horizontal tooth sections were then scanned at 4800 dpi resolution on a flat bed scanner (Agfa Snap Scan 1236s; Agfa-Gevaert, Mortsel, Belgium) using a template as a guide, which maintained the same spatial position of the samples on the scanner surface. The scanned images were processed with Adobe Photoshop CS2 and saved in TIFF format. For each root, the section in which the coronal interference was best represented was chosen for the analysis.

Each sample was then re-assembled in the muffle, and the patency was tested once more with a size 10 K-file to check for the presence of ledges due to sectioning. Six specimens were excluded at this time because of damage, the inability to correctly re-assemble the sections in the muffle or the inability to cut the sections precisely at the level of the coronal interference. Root canals of the remaining 14 specimens were allocated subsequently to group A (ProTaper, Dentsply Maillefer) and group B (Mtwo; Sweden & Martina, Padova, Italy), each thus consisting of 14 canals ( $n = 14$ ).

One experienced operator equally trained with both systems performed all instrumentation using 2.5×

magnification. Each mesial root, containing two similar canals, was instrumented by both systems (randomly distributed to the buccal and lingual canals). One root canal of each root was prepared using the ProTaper instruments, while the *Mtwo* procedure technique was carried out for the other root canal of the same mesial root.

The clinical protocols were standardized. The ProTaper system featured six instruments: Sx, S1, S2, F1, F2 and F3. The ProTaper Ni-Ti rotary instruments were used in a crown-down technique. Instrumentation was initiated with the ProTaper S1 instrument to resistance or no more than three-quarters of the estimated canal length in a brushing motion against the canal wall to create the space to insert the ProTaper Sx instrument (Clauder & Baumann 2004). Next, the Sx was used in a brushing motion away from the furcation to remove all the coronal interference and relocate the orifice (Ruddle 2002). Without pressure, and in one or more passes, the ProTaper Shaping instruments were allowed to passively float into the canal, following the glide path and used with a brush-like motion, to laterally cut dentine on the outstroke (Ruddle 2005). Instruments S1, followed by S2 were each taken to the working length with light apical pressure. Shaping was considered complete when the apical root canal was enlarged to ProTaper F2, using Finishing instruments F1 and F2 sequentially in a passive non-brushing manner (Ruddle 2005).

The *Mtwo* system consists of eight instruments varying in size and taper: size 10, 0.04 taper, size 15, 0.05 taper, size 20, 0.06 taper, size 25, 0.06 taper, size 25, 0.07 taper, size 30, 0.05 taper, size 35, 0.04 taper, size 40, 0.04 taper. The *Mtwo* Ni-Ti rotary instruments were used in a simultaneous technique (Plotino *et al.* 2006) without any early coronal enlargement. Instruments were each taken to the working length without apical pressure. As soon as the clinician experienced a binding sensation, the instrument was withdrawn 1–2 mm so that it could be worked passively in a brushing action to selectively remove the interferences and to advance towards the apex. The instruments were used with a lateral pressing movement in order to obtain a circumferential cut, and only allowed to rotate at length for a few seconds. Shaping was considered complete when the apical root canal was enlarged to *Mtwo* size 25, 0.06 taper.

The patency of the apical foramen was checked by passing the tip of a size 08 file through the foramen after each instrument until completion of the root canal shaping. During shaping, canals were irrigated between each successive instrument with 2.5 mL of 5.25% NaOCl

using an endodontic syringe (Navi Tip; Ultradent Products Inc., South Jordan, UT, USA) placed as far into the root canal as possible without binding. A final flush was performed with 5 mL of 17% EDTA solution rinsed out with 5 mL of saline solution. Each instrument was used to shape 10 root canals and was carefully examined under a stereomicroscope at 10× magnification (Global G6, St Louis, MO, USA) between uses for signs of plastic deformation or fracture. Instruments with any sign of failure were discarded and replaced.

Nickel-Titanium rotary instruments were used in a 16 : 1 handpiece (Anthogyr, Sallanches, France) in conjunction with an endodontic electric motor (ATR Teknica, Pistoia, Italy) at 300 rpm.

After mechanical preparation, the sections were removed from the muffle and again scanned, using the above-described technique. The selected apical or coronal section of each root was then measured at a magnification of 24×. Thus, it was possible to evaluate for each specimen, at the level of the coronal interference, two parameters:

**1.** Changes in root canal area ( $\Delta A$ ). The areas ( $A$ ) of the surface of the canal lumen in a horizontal plane, before ( $A_{pre}$ ) and after ( $A_{post}$ ) instrumentation, were calculated and  $\Delta A$  was obtained using the formula  $\Delta A = A_{post} - A_{pre}$ .

**2.** Reduction of the mesial and buccal/lingual wall thickness ( $\Delta T$ ). Pre- and post-instrumentation images were evaluated to determine the minimum thickness ( $T$ ) of the mesial and buccal or lingual dentine wall in a horizontal plane. This was determined by measuring distances from the external aspect of the canal to the external aspect of the root. The shortest distance was selected from these values as the minimum wall thickness present before and after instrumentation.  $\Delta T$  was obtained using the formula  $\Delta T = T_{pre} - T_{post}$ . PC software AutoCad 2000 (Autodesk Inc., San Rafael, CA, USA) was used to calculate these parameters.

Means and standard deviations were calculated for the two parameters and a Student's *t*-test applied to determine if there were statistically significant differences between the two groups with respect to variations of  $\Delta A$  and  $\Delta T$  values at a significance level of  $P < 0.05$ .

## Results

No instrument had intracanal failure during simulated clinical use, while two *Mtwo* and two ProTaper instruments showed visible signs of plastic deformation and were discarded and replaced. Deformations occurred in the apical 4 mm of the instruments.

**Table 1** Area (mean and SD) of root canals ( $\text{mm}^2$ ) at the level of section before (pre) and after (post) instrumentation, the resultant  $\Delta A$  and the difference expressed in percentage for both groups considered

	Group A (ProTaper)				Group B (Mtwo)			
	Pre	Post	$\Delta A$	% Difference	Pre	Post	$\Delta A$	% Difference
Mean	1.4	2.05	0.65	46	1.56	2.08	0.52	33
SD	2.4	3.1	0.26		2.8	3.3	0.42	

Student's *t*-test revealed no statistically significant difference between groups ( $P = 0.410$ ).

**Table 2** Dentine thickness (mean and SD) of the mesial wall (mm) at the level of section before (pre) and after (post) instrumentation, the resultant  $\Delta T$  and the difference expressed in percentage for both group considered

	Group A (ProTaper)				Group B (Mtwo)			
	Pre	Post	$\Delta A$	% Difference	Pre	Post	$\Delta A$	% Difference
Mean	2.78	2.42	0.36	13	2.84	2.6	0.24	9
SD	0.49	0.41	0.20		0.59	0.62	0.14	

Student *t*-test revealed no statistically significant difference between groups ( $P = 0.077$ ).

**Table 3** Dentine thickness (mean and SD) of the buccal/lingual wall (mm) at the level of section before (pre) and after (post) instrumentation, the resultant  $\Delta T$  and the difference expressed in percentage for both group considered

	Group A (ProTaper)				Group B (Mtwo)			
	Pre	Post	$\Delta A$	% Difference	Pre	Post	$\Delta A$	% Difference
Mean	3.06	2.7	0.36	12	3.12	2.88	0.24	8
SD	0.77	0.52	0.27		0.67	0.68	0.17	

Student *t*-test revealed no statistically significant difference between groups ( $P = 0.171$ ).

Table 1 illustrates the measurements of areas and their variations ( $\Delta A$ ) for both groups at the level considered. The percentage of the change in the area values was also reported. Table 2 illustrates the measurements of the thickness of the mesial dentine wall and their variations ( $\Delta T$ ), while Table 3 illustrates the measurements of the buccal or lingual dentine wall thickness with their variations ( $\Delta T$ ). Percentage changes in the wall thickness values are also reported. Figs 1 and 2 are representative of both group A and group B.


No statistically significant differences were found between the two groups with respect to the changes in the areas ( $\Delta A$ ) at the level considered ( $P = 0.410$ ).  $\Delta A$  was greater in group A (ProTaper) than in group B (Mtwo), respectively  $0.65 \pm 0.26 \text{ mm}^2$  and  $0.52 \pm 0.42 \text{ mm}^2$ .

No statistically significant differences were demonstrated between the two groups for dentine thickness ( $\Delta T$ ) of both the mesial wall ( $P = 0.077$ ) and the buccal or lingual wall ( $P = 0.171$ ).

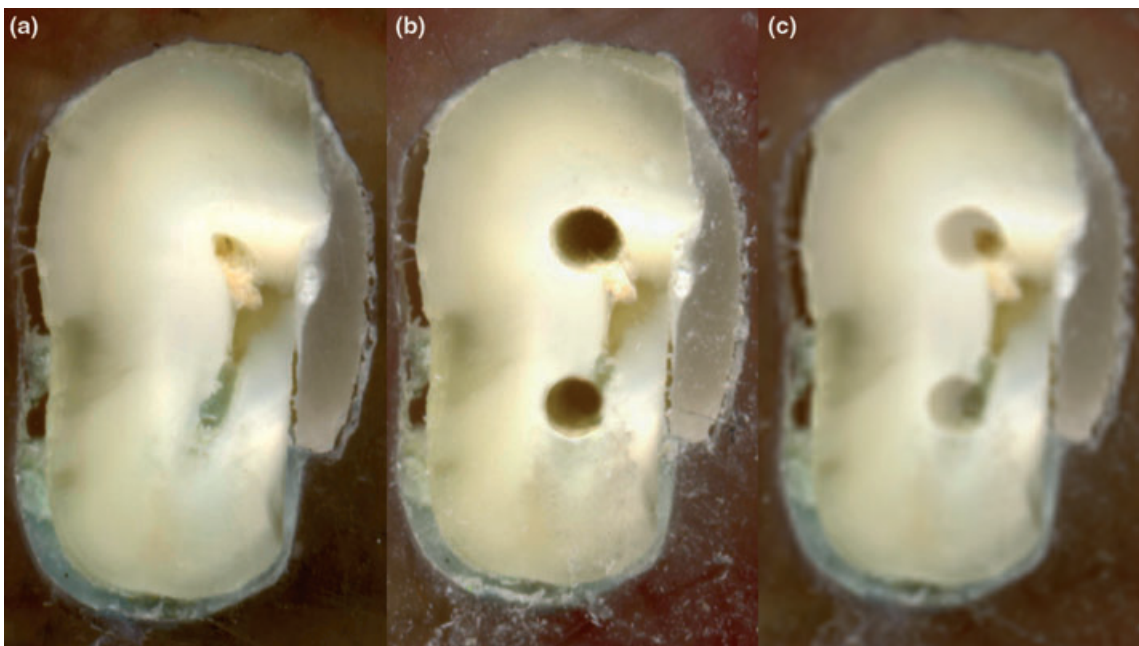
## Discussion

Lateral forces result in high stress concentrations in radicular dentine at the coronal one third of the root

(Guzy & Nicholls 1979, Assif *et al.* 1989). The rotational axis of the tooth is located at the crest of the alveolar bone, and most of the applied force is concentrated around the circumference of the tooth where the crown diameter is the smallest, corresponding to the cervical region of the tooth at the cemento-enamel junction (CEJ) (Guzy & Nicholls 1979, Assif *et al.* 1989), whereas the concentration of the forces is the lowest within the root canal (Assif & Gorfil 1994). The centre of the root canal, representing the central axis of the tooth, is a neutral area with regard to force concentration (Guzy & Nicholls 1979, Assif *et al.* 1989). This force distribution may explain the susceptibility of teeth to fracture at the CEJ area when lateral forces are exerted on the coronal portion of the tooth during occlusal loading (Guzy & Nicholls 1979, Assif *et al.* 1989, Assif & Gorfil 1994). From the point of view of stress concentration, the thickness of the dentinal wall between the root canal and its external circumference assumes great significance. There is a direct correlation between the root thickness and the ability of the tooth to resist lateral forces and avoid fracture (Rosen & Partida-Rivera 1986, Assif & Gorfil 1994). The thickness of the dentine wall is directly proportional to the ability of the tooth to withstand lateral forces (Assif *et al.* 1989). Therefore, treatment that



**Figure 1** Representative samples of a coronal section, in which (a), (b) and (c) are subsequently the pre-instrumentation and post-instrumentation sections and their superimposition. Upper canal was prepared with ProTaper instruments (group A), while the lower one was prepared with Mtwo instruments (group B).



**Figure 2** Representative samples of an apical section, in which (a), (b) and (c) are subsequently the pre-instrumentation and post-instrumentation sections and their superimposition. Upper canal was prepared with ProTaper instruments (group A), while the lower one was prepared with Mtwo instruments (group B).

causes indiscriminate removal of tooth structure from the canal walls during endodontic treatment should be avoided (Assif & Gorfil 1994).

The present study evaluated two active Ni–Ti rotary systems that were used with continuous mechanical rotation without pre-flaring with Gates Glidden burs. Mesial canals of the same roots were used for both techniques to eliminate the variables encountered in root canals in different teeth, such as, curvature, dentine hardness, canal diameter and length. The design of this study was such that an analysis of areas and dentine thickness before and after the root canal preparation would furnish data concerning the quantity of dentine being removed at the cervical level of the tooth. The difference between the groups in the area of root canals at the level considered was 13% (46% for group A and 33% for group B), but statistical analysis did not reveal a significant difference between the ProTaper and Mtwo group for the amount of the dentine removed at the level considered ( $P = 0.410$ ). Furthermore, the reduction of dentine thickness towards the mesial wall reported a difference between the groups that clearly approached statistical significance ( $P = 0.077$ ). The lack of significance between the two groups may be a consequence of an insufficient number of samples, as canal preparation may be dictated more by anatomy than by differences in instrumentation method (Peters et al. 2001b). Although a high degree of similarity between the two groups was confirmed, the variety of root canal anatomy within the groups may have produced a relatively high dispersion of the data.

Nickel–Titanium rotary instruments used in a simultaneous technique aim not to remove indiscriminately coronal root dentine with an early coronal enlargement, but rather to progressively eliminate dentine at the orifice through a selective coronal enlargement. It is a dynamic technique during the entire root canal preparation, that permits each instrument to advance towards the apex while at the same time removing only as much dentine as is needed. This may explain why a comparison between sections revealed a greater enlargement for the samples in group A when analysing the area of root canals and the residual dentine thickness of the mesial and buccal or lingual wall, although no statistically significant differences were demonstrated.

Zandbiglari et al. (2006) have demonstrated that fracture resistance of instrumented roots is significantly lower when canals are prepared with instruments with a greater taper. As a consequence, the authors

recommended that excessive coronal enlargement of the root canal must be avoided to prevent unnecessary weakening of the root. Nevertheless, the final diameter of coronal enlargement may be influenced by the size and taper of the instruments used. Both systems tested in the present study were used in a brushing motion away from the furcation to remove coronal interferences and relocate the orifice (ProTaper) and to selectively remove the interferences in order to advance towards the apex (Mtwo). As a consequence, the final shape of the preparation at the level considered in the present study may be dictated more by the brushing action than by differences in diameter and taper of the instruments used.

The Bramante technique (Bramante et al. 1987) modified by Kuttler et al. (2001) offers a method that is relatively simple and economical besides providing information of the three-dimensional action of an instrument in the canal space. There are certain limitations to this methodology, as six of the 20 specimens had to be discarded due to technical problems. This relatively high number of lost specimens may have affected the results of the present study.

The data that were generated in this study may be obtained with greater accuracy using micro-computed tomography (Bergmans et al. 2001, Peters et al. 2001a,b, ), however, at a much higher expense and more involved procedures, which make it less practical and affordable.

## Conclusions

No differences between the ProTaper and Mtwo groups with respect to the amount of dentine removed at the coronal level were found.

## References

- Assif D, Gorfil C (1994) Biomechanical considerations in restoring endodontically treated teeth. *Journal of Prosthetic Dentistry* **71**, 565–7.
- Assif D, Oren E, Marshak BL, Aviv I (1989) Photoelastic analysis of stress transfer by endodontically treated teeth to the supporting structure using different restorative techniques. *Journal of Prosthetic Dentistry* **61**, 535–43.
- Bergmans L, Van Cleynenbreugel J, Wevers M, Lambrechts P (2001) A methodology for quantitative evaluation of root canal instrumentation using microcomputed tomography. *International Endodontic Journal* **34**, 390–8.
- Bramante CM, Berbert A, Borges RP (1987) A methodology for evaluation of root canal instrumentation. *Journal of Endodontics* **13**, 243–5.

- Clauder T, Baumann MA (2004) ProTaper NT system. *Dental Clinics of North America* **48**, 87–111.
- Felton DA, Webb EL, Kanoy MA, Dugoni J (1991) Threaded endodontic posts: effects of their morphology on the incidence of radicular fractures. *Journal of Prosthetic Dentistry* **65**, 179–84.
- Guzy GE, Nicholls JI (1979) In vitro comparison of intact endodontically treated teeth with and without endo-post reinforcement. *Journal of Prosthetic Dentistry* **42**, 39–42.
- Kuttler S, Garala M, Perez R, Dorn SO (2001) The endodontic cube: a system designed for evaluation of root canal anatomy and canal preparation. *Journal of Endodontics* **27**, 533–6.
- Lertchirakarn V, Timyam A, Messer HH (2002) Effects of root canal sealers on vertical root fracture resistance of endodontically treated teeth. *Journal of Endodontics* **28**, 217–9.
- Mondelli J, Steagal IL, Ishikiriama A, Navarro M, Soares FB (1980) Fracture strength of human teeth with cavity preparation. *Journal of Prosthetic Dentistry* **43**, 419–22.
- Morfis AS (1990) Vertical root fractures. *Oral Surgery, Oral Medicine and Oral Pathology* **69**, 631–5.
- Peters OA, Laib A, Gohring TN, Barbakow F (2001a) Changes in root canal geometry after preparation assessed by high-resolution computed tomography. *Journal of Endodontics* **27**, 1–6.
- Peters OA, Schonenberger K, Laib A (2001b) Effect of four Ni–Ti preparation techniques on root canal geometry assessed by microcomputer tomography. *International Endodontic Journal* **34**, 221–30.
- Pilo R, Corcino G, Tamse A (1998) Residual dentin thickness in mandibular premolars prepared with hand and rotary instruments. *Journal of Endodontics* **24**, 401–4.
- Plotino G, Grande NM, Sorci E, Malagnino VA, Somma F (2006) A comparison of cyclic fatigue between used and new Mtwo NiTi rotary instruments. *International Endodontic Journal* **39**, 716–23.
- Rosen H, Partida-Rivera M (1986) Iatrogenic fracture of roots reinforced with cervical collar. *Operative Dentistry* **11**, 46–50.
- Ruddle CJ (2002) Cleaning and shaping the root canal system. In: Cohen S, Burns RC, eds *Pathways of the Pulp*, 8th edn. St Louis: Mosby, pp. 231–92.
- Ruddle CJ (2005) The ProTaper technique. *Endodontic Topics* **10**, 187–90.
- Schneider SW (1971) A comparison of canal preparations in straight and curved root canals. *Oral Surgery Oral Medicine and Oral Pathology* **32**, 271–5.
- Thompson SA (2000) An overview of nickel–titanium alloys used in dentistry. *International Endodontic Journal* **33**, 297–310.
- Trope M, Ray HL (1992) Resistance to fracture of endodontically treated roots. *Oral Surgery, Oral Medicine and Oral Pathology* **73**, 99–102.
- Wu M-K, van der Sluis LWM, Wesselink PR (2004) Comparison of mandibular premolars and canines with respect to their resistance to vertical root fracture. *Journal of Dentistry* **32**, 265–8.
- Zandbiglari T, Davids H, Schäfer E (2006) Influence of instrument taper on the resistance to fracture of endodontically treated roots. *Oral Surgery, Oral Medicine, Oral Pathology, Oral Radiology and Endodontology* **101**, 126–31.