
REVIEW

Electronic apex locators

M. P. J. Gordon & N. P. Chandler

Department of Oral Rehabilitation, School of Dentistry, University of Otago, Dunedin, New Zealand

Abstract

Gordon MPJ, Chandler NP. Electronic apex locators. *International Endodontic Journal*, **37**, 425–437, 2004.

Prior to root canal treatment at least one undistorted radiograph is required to assess canal morphology. The apical extent of instrumentation and the final root filling have a role in treatment success, and are primarily determined radiographically. Electronic apex locators reduce the number of radiographs required and assist where radiographic methods create difficulty. They may also indicate cases where the apical foramen is some distance from the radiographic apex.

Other roles include the detection of root canal perforation. A review of the literature focussed first on the subject of electronic apex location. A second review used the names of apex location devices. From the combined searches, 113 pertinent articles in English were found. This paper reviews the development, action, use and types of electronic apex locators.

Keywords: apex locators, endodontics, root apex, working length.

Received 11 August 2003; accepted 17 March 2004

Introduction

The removal of all pulp tissue, necrotic material and microorganisms from the root canal is essential for endodontic success. This can only be achieved if the length of the tooth and the root canal is determined with accuracy. The outcome of treatment of roots with necrotic pulps and periapical lesions is influenced significantly by the apical level of the root filling (Sjögren *et al.* 1990). Traditionally, the point of termination for endodontic instrumentation and obturation has been determined by taking radiographs. The development of the electronic apex locator has helped make the assessment of working length more accurate and predictable (Fouad & Reid 2000). The aim of this review is to examine the variety of apex locators available and overview their development. Contemporary endodontic texts were consulted and a database search performed using Medline to identify general

studies on electronic apex locators. This resulted in 70 published articles in English. As apex locators have evolved over more than 60 years a number of older texts were consulted. Data from manufacturers was also studied, especially where identical instruments appeared to be marketed under different names around the world. A list of electronic apex locators was compiled and Medline searches were created for information on current electronic apex locators and accuracy studies for first, second and third generation apex locators based on the units name. This search resulted in a further 43 published articles in English.

Study results were standardized in the comparison tables by using accuracy data for plus or minus 0.5 mm from the apical foramen. Some studies used the apical constriction as a measure of accuracy but also included the apical foramen data.

The importance of working length

Grove (1930) stated that 'the proper point to which root canals should be filled is the junction of the dentin and the cementum and that the pulp should be severed at the point of its union with the periodontal membrane'. The cementodentinal junction (CDJ) is the

Correspondence: Nicholas Chandler, Department of Oral Rehabilitation, School of Dentistry, University of Otago, PO Box 647, Dunedin, New Zealand (Tel.: +64 3 479 7124; fax: +64 3 479 5079; e-mail: nick.chandler@dent.otago.ac.nz).

anatomical and histological landmark where the periodontal ligament begins and the pulp ends. Root canal preparation techniques aim to make use of this potential natural barrier between the contents of the canal and the apical tissues (Schilder 1967). It is generally accepted that the preparation and obturation of the root canal should be at or short of the apical constriction. An *in vivo* histological study found that the most favourable histological conditions were when the instrumentation and obturation remained short of the apical constriction and that extruded gutta-percha and sealer always caused a severe inflammatory reaction despite the absence of pain (Ricucci & Langeland 1998).

The problem clinicians face is how to accurately identify and prepare to this landmark – the ‘working length’ – and achieve maximum success. Epidemiological studies have reported that the best prognosis is when the root filling lies within 2 mm of the radiographic apex (Sjögren *et al.* 1990). The variations in anatomy of tooth apices both by age and tooth type make this task all the more challenging.

Anatomy of the apical foramen

To appreciate fully the concept of working length, an understanding of apical anatomy is required. The anatomy of the apical foramen changes with age. Figure 1a shows a concept of the apex (a), the apex of a younger person (b) and the changing apex due to hard tissue deposition (c). It is generally agreed that there are three distinct aspects of the apex that must be appreciated. Figure 1b shows these as the tooth apex (1), the apical foramen [major foramen (2)] and the apical constriction [minor foramen (3)] which is also described as the CDJ. The apical foramen is not always located at the anatomical apex of the tooth. The foramen of the main root canal may be located to one side of the anatomical apex, sometimes at distances of up to 3 mm in 50–98% of roots (Kuttler 1955, Green 1956, Pineda & Kuttler 1972). Dummer *et al.* (1984) reported the mean apex to foramen distance (Fig. 1b, 4) in anterior teeth to be 0.36 mm. Kuttler (1955) measured the apex to foramen distances as 0.48 mm for a young group and 0.6 mm for an older group. Green (1956, 1960) reported the distance to be 0.3 mm in anterior teeth and 0.43 mm in posterior teeth. The general trend is that the apex to foramen distance is greater in posterior teeth and older teeth than in anterior and younger teeth.

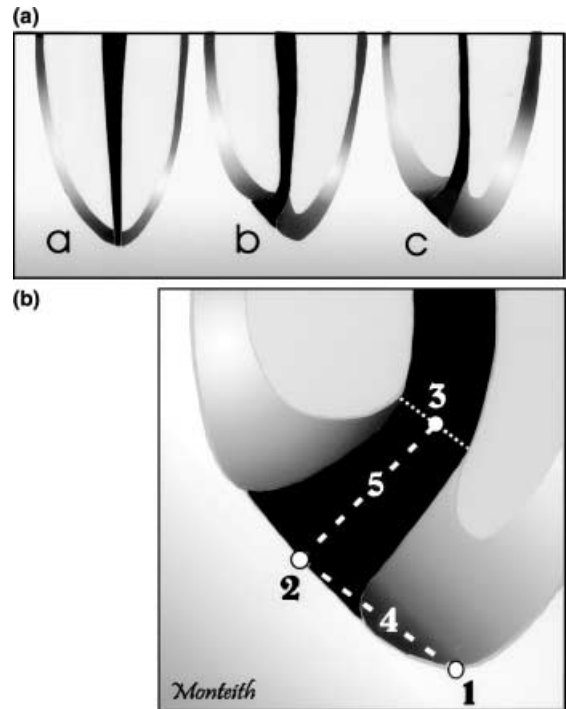


Figure 1 (a) Position of the apical foramen (adapted from Kuttler 1955). (b) Anatomy of the root apex (adapted from Kuttler 1955).

The foramen to apical constriction (Fig 1(b)5) is approximately 0.5 mm in the younger group and 0.8 mm in the older group for all tooth types (Kuttler 1955, Dummer *et al.* 1984, Stein & Corcoran 1990). The discrepancy in measurements from the anatomical studies may be due to the type and age of teeth selected, the presence or absence of apical pathology and the variability of the minor foramen. No studies reported any changes in measurements due to pathological resorption of the apex. Kuttler (1955) used 95% of teeth from cadavers, all without periapical disease, in occlusion, with completely formed apices and of a known age. It was stated that some had superficial caries. Pineda & Kuttler (1972) used extracted teeth because of pulpal alterations or periapical complications. The teeth were also grouped by age. Green (1956) used anterior teeth collected at random and assumed they were from older patients as these teeth were rarely extracted in younger people. Green (1960) in his study of molar apices did not state where the teeth were collected from or their clinical status.

Dummer *et al.* (1984) stated that the teeth used were of unknown age but had completely formed apices. Stein *et al.* (1990) collected extracted teeth which were

nonrestorable from patients of a known age. Of the 111 teeth, 87 were vital and 24 nonvital.

The apical constriction, when present, is the narrowest part of the root canal with the smallest diameter of blood supply and preparation to this point results in a small wound site and optimal healing conditions (Ricucci & Langeland 1998). The location of the apical constriction varies considerably from root to root and its relationship to the CDJ is also variable as the CDJ is highly irregular and can be up to 3 mm higher on one wall of the root compared with the opposite wall (Gutierrez & Aguayo 1995). Radiography can, at best, give an estimate of this histological structure and although clinically desirable, averages used to define the apical constriction from the anatomical or radiographic apex could lead to over or underfilling.

Using the averages from the anatomical studies and using the assumption that the CDJ occurs at the apical constriction has led to the common teaching practice of determining working length to be 1–2 mm short of the anatomic apex as seen on a radiograph.

Dummer *et al.* (1984) classified the apical constriction into four distinct types (Fig. 2) and speculated that using this assumption would lead to under-preparation in type B and over-preparation in type D.

Traditional methods for establishing working length have been (a) the use of anatomical averages and knowledge of anatomy, (b) tactile sensation, (c) moisture on a paper point and (d) radiography.

Limitations of traditional working length assessment

Tactile sensation, although useful in experienced hands, has many limitations. The anatomical varia-

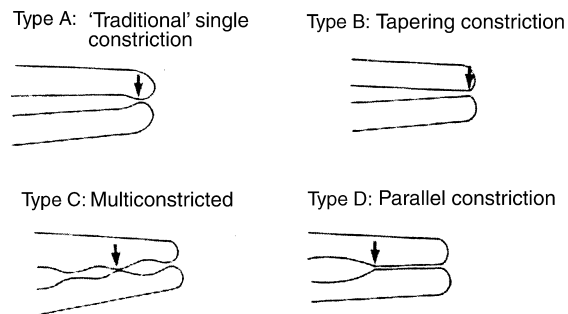


Figure 2 Topography of the apical constriction (from Dummer *et al.* 1984).

tions in apical constriction location, size, tooth type and age make working length assessment unreliable. In some cases the canal is sclerosed or the constriction has been destroyed by inflammatory resorption (Stock 1994). Seidberg *et al.* (1975) found that, even among experienced clinicians, only 60% could locate the apical constriction by using tactile sense. In a simulation study, Chandler & Bloxham (1990) found substantial variation between subjects asked to detect a resistance in a model root canal. Marked intra-subject differences were also a feature of their experiment. In a clinical study in adult patients it was found that preflaring of the canal significantly increased the ability to determine the apical constriction by tactile sensation, and helped to detect the apical constriction 75% of the time (Stabholz *et al.* 1995).

Radiographic determination of working length has been used for many years. The radiographic apex is defined as the anatomical end of the root as seen on the radiograph, while the apical foramen is the region where the canal leaves the root surface next to the periodontal ligament (American Association of Endodontists 1984). When the apical foramen exits to the side of the root or in a buccal or lingual direction it becomes difficult to view on the radiograph. Olson *et al.* (1991) found that when placing files to the foramen in extracted teeth, only 82% appeared to be at the apical foramen. Dense bone and anatomical structures can make the visualization of root canal files impossible by obscuring the apex. The superimposition of the zygomatic arch has been shown to interfere radiographically with 20% of maxillary first molar apices and 42% of second molar apices (Tamse *et al.* 1980). The deposition of secondary dentine and cementum can move the apical constriction further from accepted limits causing preparation errors (Stein & Corcoran 1990, Chong & Pitt Ford 1994).

A radiograph provides a two-dimensional image of a three-dimensional structure and is technique sensitive in both its exposure and interpretation. Cox *et al.* (1991) found that when adjustments were required to working length 68% of examiners agreed when adjustments up to 0.5 mm were needed, but there was only 14% agreement when adjustments greater than 1.0 mm were required.

With concerns over radiation exposure and the increased use of electronically stored patient records, several types of digital radiography machines have been introduced. These use sensors instead of film, and have several advantages over conventional radiographs such as reduced radiation exposure, speed of

image acquisition and the possibility of enhancing or editing the image (Shearer *et al.* 1991). Cederberg *et al.* (1998) found that storage-phosphor digital imaging performed equally as well as Ektaspeed Plus film for working length assessment and had better results with its enhancement features. Friedlander *et al.* (2002), however, found that the clarity of fine endodontic files and periapical lesions was less with phosphor-plate digital images than with conventional film, due in part to the pixel size of 64 μm being larger than the tip of the 06 K-file. Currently, direct digital radiography has not been shown to exceed conventional radiography in quality, even with enhancement and measuring features, but is useful for its speed and lower doses of radiation (Martinez-Lozano *et al.* 2001).

The preoperative radiograph is essential in endodontics to determine the anatomy of the root canal system, the number and curvature of roots, the presence or absence of disease, and to act as an initial guide for working length. The electronic apex locator is an instrument, which used with appropriate radiographs, allows for much greater accuracy of working length control (McDonald 1992, Pratten & McDonald 1996, Segura-Egea *et al.* 2002).

History of electronic apex locators

An electronic method for root length determination was first investigated by Custer (1918). The idea was revisited by Suzuki in 1942 who studied the flow of direct current through the teeth of dogs. He registered consistent values in electrical resistance between an instrument in a root canal and an electrode on the oral mucous membrane and speculated that this would measure the canal length (Suzuki 1942). Sunada took these principles and constructed a simple device that used direct current to measure the canal length. It worked on the principle that the electrical resistance of the mucous membrane and the periodontium registered 6.0 k Ω in any part of the periodontium regardless of the persons age or the shape and type of teeth (Sunada 1962). Using direct current caused instability with measurement, and polarization of the file tip altered the measurement.

Methodology of studies

In vivo studies are more representative of the true accuracy of a given apex locator (Czerw *et al.* 1995). Those studies that use apex locators to find the working length, cement the file in place, extract the tooth and

locate the file under magnification in the root canal emulate what will happen in clinical practice (Shabahang *et al.* 1996). When extraction of the tooth has not been possible, studies have used radiographs to verify the canal length. This method introduces the problems associated with radiographic working length assessment and working in two dimensions with anatomic variation and distortions (Cox *et al.* 1991).

In vitro studies use electroconductive materials to simulate the clinical situation. Researchers have found alginate, gelatine, agar or saline to be media that give predictable results with apex locators when compared with tooth length (Czerw *et al.* 1994, Meares & Steiman 2002). Some of these media can leak through the apical foramen and cause premature readings (Czerw *et al.* 1994). It appears that some *in vitro* experimental models give greater accuracy than can be achieved clinically (Czerw *et al.* 1995).

The first generation

The Root Canal Meter (Onuki Medical Co., Tokyo, Japan) was developed in 1969. It used the resistance method and alternating current as a 150 Hz sine wave. Pain was often felt due to high currents in the original machine, so improvements were made and released as the Endodontic Meter and the Endodontic Meter S II (Onuki Medical Co.) which used a current of less than 5 μA (Kobayashi 1995).

Other devices in the first generation include the Dentometer (Dahlin Electromedicine, Copenhagen, Denmark) and the Endo Radar (Elettronica Liarre, Imola, Italy). These devices were found to be unreliable when compared with radiographs, with many of the readings being significantly longer or shorter than the accepted working length (Tidmarsh *et al.* 1985). Innovative practitioners in the UK designed a home-made resistance type apex locator with simple materials from an electrical supplier and reported comparable results to commercially available machines (Foreman & Howat 1986).

The second generation

Second generation apex locators were of the single-frequency impedance type which used impedance measurements instead of resistance to measure location within the canal. Impedance is comprised of resistance and capacitance and has a sinusoidal amplitude trace. The property is utilized to measure distance in different canal conditions by using different frequencies.

The change in frequency method of measuring was developed by Inoue in 1971 as the Sono-Explorer (Hayashi Dental Supply, Tokyo, Japan) which calibrated at the periodontal pocket of each tooth and measured by the feedback of the oscillator loop (Inoue 1972). The beeping of the device indicated when the apex was reached, so some clinicians erroneously thought that it measured by using sound waves (Inoue 1973). A later model, the Sono-Explorer Mk III uses a meter to indicate distance to apex (Inoue & Skinner 1985).

A high frequency (400 kHz) wave measuring device, the Endocater (Yamaura Seisokushu, Tokyo, Japan) was introduced by Hasegawa *et al.* (1986). With an electrode connected to the dental chair and a sheath over the probe it was able to make measurements in canals even with conductive fluids present. The sheath caused problems because it would not enter narrow canals, could be rubbed off and was affected by autoclaving (Fouad *et al.* 1990, Himel & Schott 1993).

Ushiyama (1983) suggested using a concentric bipolar electrode that measured the current density evoked in a limited area of the canal, the maximum potential of which is obtained when the electrode meets a constriction. The voltage gradient method could measure with conductive fluids present but was limited by the presence, absence and location of a constriction and the electrode would not fit in a narrow canal (Ushiyama *et al.* 1988).

Some reported accuracy studies for the second generation apex locators are detailed in Table 1.

An increasing number of second generation apex locators were designed and marketed but all suffered similar problems of incorrect readings with electrolytes in the canals and also in dry canals.

The Apex Finder and the combined pulp tester and apex locator the Endo Analyzer (Analytic/Endo, Orange, CA, USA) are self-calibrating with a visual indicator but have had variable reports of accuracy. Fouad's group used radiographic length determination and found the accuracy at $67\% \pm 0.5$ mm from the radiographic apex (Fouad *et al.* 1990). Czerw *et al.* (1995) noted that the unit overestimated length by more than 0.5 mm 16.6% of the time in an *in vitro* evaluation. De Moor *et al.* (1999) found in an *in vitro* experiment using gelatine that most measurements resulted in perforation through the apex.

The Digipex I, II and III (Mada Equipment Co., Carlstadt, NJ, USA) also combined a pulp vitality tester with apex locator. Czerw *et al.* (1995) found the Digipex II to be as reliable as the Root ZX in an *in vitro* study.

The Exact-A-Pex (Ellmann International, Hewlett, NY, USA) uses an audio and a light emitting diode (LED) display. It was found that the Exact-A-Pex always duplicated the canal length as determined by visualizing the tip of a file at the foramen of extracted teeth (Czerw *et al.* 1994). Hülsmann & Pieper (1989) found the Exact-A-Pex measured consistently short in immature teeth requiring apexification, but was able to give correct results at the time of obturation, comparing results with radiographs.

Table 1 Accuracy studies for second generation apex locators

Investigator	Accuracy (%)	Device	Compared with
Inoue (1973)	92	Sono-Explorer	Tooth length
O'Neill (1974)	83	Sono-Explorer	Tooth length
Seidberg <i>et al.</i> (1975)	48	Sono-Explorer	RM
	64	Tactile sense	RM
Blank <i>et al.</i> (1975)	89	Sono-Explorer	Tooth length
	85	Endometer	Tooth length
Chunn <i>et al.</i> (1981)	15	Forameter	Tooth length
Berman & Fleischman (1984)	Consistently accurate	Neosono-D	Tooth length
Trope <i>et al.</i> (1985)	90.6	Sono-Explorer Mark III	RM
Inoue & Skinner (1985)	57.7	Sono-Explorer Mark III	RM
Wu <i>et al.</i> (1992)	77.5	Sono-Explorer Mark III	Tooth length
Kaufman <i>et al.</i> (1989)	56	Dentometer	Ingles method
	44	Sono-Explorer Mark II	Ingles method
McDonald & Hovland (1990)	93.4	Endocater	Tooth length
Keller <i>et al.</i> (1991)	67.7	Endocater	Tooth length

RM, radiographic measurement. Tooth length = real or extracted tooth length measurement. Ingles method = radiographic.

The Formatron IV (Parkell Dental, Farmingdale, NY, USA) is a small simple device with an LED display. It uses an AC current and measures impedance to measure the distance of the file tip to the apex. It has also had variable results in terms of accuracy. Himel (1993) found it to be accurate to ± 0.5 mm from the radiographic apex 65% of the time and within 1 mm 83% of the time. The manufacturer stated in the instructions that it would not work with sodium hypochlorite or other conductive irrigants.

The third generation

Third generation apex locators are similar to the second generation except that they use multiple frequencies to determine the distance from the end of the canal. These units have more powerful micro-processors and are able to process the mathematical quotient and algorithm calculations required to give accurate readings.

The Endex/Apiti

The relative values of frequency response method detects the apical constriction by calculating the difference between two direct potentials picked up by filters when a 1 kHz rectilinear wave is applied to the canal. This was described by Saito & Yamashita (1990) and the method was used to develop the Apiti (also marketed as the Endex by Osada Electric Co., Tokyo, Japan), the original third generation apex locator (Frank & Torabinejad 1993). The Apiti is able to measure lengths with electrolytes in the canal but needs to be calibrated in each canal. A number of accuracy studies for the Endex are reported in the literature, which give a combined accuracy of 81% to within ± 0.5 mm of the apical foramen. These are detailed in Table 2.

The Root ZX

The main shortcoming of early apex locators (erroneous readings with electrolytes) was overcome by Kobayashi *et al.* (1991) with the introduction of the ratio method and the subsequent development of the self-calibrating Root ZX (J. Morita, Tokyo, Japan) (Kobayashi & Suda 1994). The ratio method works on the principle that two electric currents with different sine wave frequencies will have measurable impedances that can be measured and compared as a ratio regardless of the type of electrolyte in the canal. The capacitance of a root canal increases significantly at the apical constriction, and the quotient of the impedances reduces rapidly as the apical constriction is reached. Kobayashi & Suda (1994) showed that the ratio of different frequencies have definitive values, and that the ratio rate of change did not change with different electrolytes in the canal. The change in electrical capacitance at the apical constriction is the basis for the operation of the Root ZX and its reported accuracy. Since its introduction the Root ZX has received considerable attention in the literature. It has become the benchmark to which other apex locators are compared, and maintains a 95% world market share for apex locators in use today (Lively 2003, personal communication). The Root ZX has been exhaustively tested for accuracy in many clinical conditions, which are summarized in Table 3. The results give a combined accuracy of 90% to within 0.5 mm of the apical foramen or the CDJ, depending on the reference point used, with many studies reporting 100% accuracy if 1.0 mm is accepted (Pagavino *et al.* 1998).

The Root ZX has also been combined with a handpiece to measure canal length as a rotary file is used (Kobayashi *et al.* 1997). This is marketed as the Tri Auto ZX with integrated handpiece, and more recently as the Dentaport ZX. The Tri Auto ZX has a

Investigator	Accuracy (%)	Test condition	Compared with
Fouad <i>et al.</i> (1993)	73 (± 0.5 mm)	<i>In vitro</i> – NaOCl	Tooth length
Mayeda <i>et al.</i> (1993)	66 (± 0.75 mm)	<i>In vivo</i>	Tooth length
Frank & Torabinejad (1993)	90 (± 0.5 mm)	<i>In vivo</i>	RM
Felippe & Soares (1994)	96.5 (± 0.5 mm)	<i>In vitro</i>	Tooth length
Arora & Gulabivala (1995)	72 (± 0.5 mm)	<i>In vivo</i>	Tooth length
Pratten & McDonald (1996)	82 (± 0.5 mm)	<i>In vitro</i>	RM and tooth length
Lauper <i>et al.</i> (1996)	93 (± 0.5 mm)	<i>In vivo</i>	Tooth length
Ounsi & Haddad (1998)	85 (± 0.5 mm)	<i>In vitro</i>	Tooth length
Weiger <i>et al.</i> (1999)	59 (± 0.5 mm)	<i>In vitro</i> – NaOCl	Tooth length
De Moor <i>et al.</i> (1999)	100 (± 0.5 mm)	<i>In vitro</i>	Tooth length
Martinez-Lozano <i>et al.</i> (2001)	68 (± 0.5 mm)	<i>In vitro</i>	Tooth length

RM, radiographic method.

Table 2 Accuracy studies for the Endex/Apiti apex locator

Table 3 The properties of the Root ZX

Investigator	Variable tested	Accuracy (%)	Compared with	Sample (n)
Clinical accuracy permanent teeth <i>in vitro</i>				
Czerw <i>et al.</i> (1995)	Accuracy <i>in vitro</i>	100 (± 0.5 mm)	Tooth length	30
White <i>et al.</i> (1996)	Accuracy <i>in vitro</i>	84 (± 0.5 mm)	Tooth length	51
Ounsi & Naaman (1999)	Accuracy <i>in vitro</i>	85 (± 0.5 mm)	Tooth length	39
Accuracy in the presence of irrigants				
Shabahang <i>et al.</i> (1996)	Accuracy <i>in vivo</i>	96 (± 0.5 mm)	Extracted tooth length	26
McGinty <i>et al.</i> (1996)	Irrigants and accuracy <i>in vitro</i>	No difference	Tooth length	16
		between irrigants		
Weiger <i>et al.</i> (1999)	Irrigants and accuracy <i>in vitro</i> – NaOCl	85 (± 0.5 mm)	Tooth length	41
Jenkins <i>et al.</i> (2001)	Various irrigants and accuracy <i>in vitro</i>	No difference	Tooth length	30
Mearns & Steiman (2002)	Accuracy with NaOCl <i>in vitro</i>	83 (± 0.5 mm)	Tooth length	40
		No difference		
Clinical accuracy permanent teeth <i>in vivo</i>				
Vajrabhaya & Tepmongkol (1997)	Accuracy <i>in vivo</i>	100 (± 0.5 mm)	Extracted tooth length	20
Pagavino <i>et al.</i> (1998)	Accuracy <i>in vivo</i> – SEM	83 (± 0.5 mm)	Extracted tooth length	29
		100 (± 1.0 mm)		
Dunlap <i>et al.</i> (1998)	Accuracy vital versus necrotic <i>in vivo</i>	82 (± 0.5 mm)	Extracted tooth length	34
McDonald <i>et al.</i> (1999)	Accuracy <i>in vivo</i>	95 (± 0.5 mm)	Extracted tooth length	20
Welk <i>et al.</i> (2003)	Accuracy <i>in vivo</i>	91 (± 0.5 mm)	Extracted tooth length	32
		Minor diameter		
Clinical accuracy in primary teeth				
Katz <i>et al.</i> (1996)	Accuracy in primary teeth – <i>in vitro</i>	100 (± 0.5 mm)	Extracted tooth length	20
Mente <i>et al.</i> (2002)	Accuracy in resorbed primary teeth – <i>in vitro</i>	98 (± 1.0 mm)	Tooth length	24
Kielbassa <i>et al.</i> (2003)	Accuracy in primary teeth – <i>in vivo</i>	64 (± 1.0 mm)	Extracted tooth length	71

reported accuracy similar to the Root ZX of 95% (Grimberg *et al.* 2002) with the addition of some safety features such as auto-reverse when working length is reached (Campbell *et al.* 1998).

The Apex Finder AFA (all fluids allowed)

This machine claims to have five signal frequencies and to read four amplitude ratios (EIE Analytic Endodontics 2002). The unit is self-calibrating and can measure with electrolytes present in the canal.

Pommer *et al.* (2002) found using radiographic methods *in vivo* that 86% of file tips were located 0.5 mm from a point 1 mm from the radiographic apex. The Apex Finder was only able to detect the apical constriction in 76.6% of necrotic canals but was effective for 93.9% of vital canals (Pommer *et al.* 2002). Others reported an accuracy of 95% in locating to within 0.5 mm of the CDJ in patients (McDonald *et al.* 1999). A more recent study found the Endo Analyzer Model 8005 only able to locate the minor diameter (± 0.5 mm) 34.4% of the time using an *in vivo* method and extracting the teeth (Welk *et al.* 2003).

The Neosono Ultima EZ

The Neosono Ultima EZ (Satelec Inc., Mount Laurel, NJ, USA) is known in the Southern Hemisphere as

the DatApex (Dentsply Maillefer, Ballaigues, Switzerland). It is the successor to the Sono Explorer line of apex locators and uses a number of frequencies to sample the canal using the best two for its reading. De Moor *et al.* (1999) found this unit to be 100% accurate in the ± 0.5 mm range in an *in vitro* model with dry and wet canals with sodium hypochlorite. They also found the unit to be the least susceptible to operator influence compared with the Apit and Apex Finder AFA (De Moor *et al.* 1999). Its accuracy with different endodontic file alloys has been reported. It was 94% accurate with nickel-titanium files and 91% with stainless steel files, although this difference was not significant (Nekoofar *et al.* 2002).

There are several other third generation apex locators in use world-wide. These include the Justwo or Justy II (Yoshida Co., Tokyo, Japan), the Mark V Plus (Moyco/Union Broach, Bethpage, NY, USA) and the Endy 5000 (Loser, Leverkusen, Germany). Their market share is very low compared with the Root ZX and there is limited research on their features and accuracy. A recent report found the Justy II to be 82.4% accurate in determining the area between the minor and major foramen and the Endy 5000 to be 81% accurate (Hoer & Attin 2004).

The fourth generation

Bingo 1020/Ray-Pex 4

The Bingo 1020 (Forum Engineering Technologies, Rishon Lezion, Israel) claims to be a fourth generation device and the unit uses two separate frequencies 400 Hz and 8 kHz similar to the current third generation units. The manufacturers claim that the combination of using only one frequency at a time and basing measurements on the root mean square values of the signals increases the measurement accuracy and the reliability of the device (Apex Locator Bingo – '1020' 1999). An *in vitro* study of the Bingo 1020 found it to be as reliable as the Root ZX and also user friendly (Kaufman *et al.* 2002). Tinaz *et al.* (2002a) found the Bingo1020 to be as accurate as the Root ZX in an *in vitro* study and easier for a beginner to use in preflared canals. This unit has subsequently been marketed by Dentsply as the Ray-Pex 4.

Elements Diagnostic Unit and Apex Locator

A new unit to the market in 2003 is the Elements Diagnostic Unit and Apex Locator (SybronEndo, Anaheim, CA, USA). The device does not process the impedance information as a mathematical algorithm, but instead takes the resistance and capacitance measurements and compares them with a database to determine the distance to the apex of the root canal (Lively 2003, personal communication). It uses a composite waveform of two signals, 0.5 and 4 kHz, compared with the Root ZX at 8 and 0.4 kHz. The signals go through a digital-to-analogue converter to be converted into an analogue signal, which then goes through amplification and then to the patient circuit model which is assumed to be a resistor and capacitor in parallel. The feedback signal waveforms are then fed into a noise reduction circuit.

The manufacturer claims that this allows less sampling error per measurement and more consistent readings.

Other uses for apex locators

Innovative uses for apex locators have been reported. All modern apex locators are able to detect root perforations to clinically acceptable limits and are equally able to distinguish both large and small perforations (Fuss *et al.* 1996, Kaufman *et al.* 1997). Azabal *et al.* (2004) found the Justy II was able to detect simulated horizontal fractures but was unreliable when measuring simulated vertical fractures. This aids in decision-making and consideration of treatment

options (Nahmias *et al.* 1983, Kaufman & Keila 1989). Suspected periodontal or pulpal perforation during pinhole preparation can be confirmed by all apex locators, as a patent perforation will cause the instrument to complete a circuit and indicate the instrument is beyond the 'apex' (Ingle *et al.* 2002). Any connection between the root canal and the periodontal membrane such as root fracture, cracks and internal or external resorption will be recognized by the apex locator which serves as an excellent diagnostic tool in these circumstances (Nahmias *et al.* 1983, Chong & Pitt Ford 1994).

Electrically conductive gutta-percha gained favour for a short period in the hope that it would reduce radiographic exposure and reduce underfill or overfill during obturation. The accuracy of apex location measurements with these cones proved to be outside clinically acceptable limits (Rivera & Seraji 1994).

Multiple-function apex locators are becoming more common and several have vitality testing functions. Combination electronic apex locators and electric handpieces are also becoming common and are able to achieve excellent results with the same accuracy as the stand-alone units (Steffen *et al.* 1999). Kobayashi *et al.* (1996) reported the development of a combination ultrasonic unit the SOFY ZX (J. Morita) which uses the Root ZX to monitor file length. Other handpiece combinations are the Dentaport ZX (J. Morita) and the Endy 7000 (Ionyx SA, Blanquefort, France).

Problems associated with the use of apex locators

The majority of present generation apex locators are not affected by irrigants within the root canal (Jenkins *et al.* 2001) and the Root ZX has been found to be more accurate in the presence of sodium hypochlorite (Meares & Steiman 2002).

Huang (1987) refuted the original idea of Sunada (1962) that electrical resistance was a biological property of the tooth and periodontium, and confirmed that physical properties influence root canal measurement. This formed the basis for *in vitro* models to test apex locators using saline, agar, gelatine or alginate (Aurelio *et al.* 1983, Tinaz *et al.* 2002b). Biological phenomena such as inflammation can still have an effect on accuracy (Kovacevic & Tamarut 1998). Intact vital tissue, inflammatory exudate and blood can conduct electric current and cause inaccurate readings so their presence should be minimized before accepting apex readings (Trope *et al.* 1985). Other conductors that can cause short-circuiting are metallic restorations, caries, saliva and instruments in a second canal. Care

must be taken if any of these variables exist. It does not appear that the type of alloy used in the instrument for length assessment affects accuracy, with the same measurements obtained in the same root canal using stainless steel and nickel-titanium instruments (Thomas *et al.* 2003).

Canal shape. Lack of patency, the accumulation of dentine debris and calcifications can affect accurate working length determination with electronic apex locators (Aurelio *et al.* 1983, Morita 1994). It has been suggested that preflaring of root canals as used in modern crown-down preparation techniques would increase the accuracy of readings. This was found to be true for tactile sensation (Stabholz *et al.* 1995) and accuracy with the Root ZX (Ibarrola *et al.* 1999). However, Tinaz *et al.* (2002a) found little difference with preflaring and accuracy other than it was easier for the files to pass beyond the foramen and slightly increased the accuracy of the Root ZX, but decreased the accuracy of the Apex Finder AFA model 7005 and the Bingo 1020. It was found that even in mechanically enlarged canals small or large files gave the same electronic reading (Nguyen *et al.* 1996). Canal patency appears to be more important, as dentine debris may disrupt the electrical resistance between the inside of the canal and the periodontal ligament. Constant recapitulation and irrigation ensures accurate electronic length readings during instrumentation (Rivera & Seraji 1993).

The size of the apical foramen also has an influence on electronic length determination. Huang (1987) found that when the size of the major foramen was less than 0.2 mm measurements were not affected, even in the presence of conductive irrigants, but as it increased above 0.2 mm measured distances from the foramen increased. Stein *et al.* (1990) also concluded that as the width of the major foramen increased the distance between file tip and foramen increased; they also found no significant correlation between the width of the CDJ and the measurement. Immature or 'blunderbuss' apices tend to give short measurements electronically (Berman & Fleischman 1984, Wu *et al.* 1992) due to the instruments not touching the apical dentine walls (Hülsmann & Pieper 1989). Other methods for length determination such as the use of paper points are deemed to be more effective in these cases (Baggett *et al.* 1996).

Cardiac pacemakers. Electromagnetic interference from dental equipment including electronic apex locators

has the potential to interfere with cardiac pacemakers (Woolley *et al.* 1974). The manufacturers of electronic apex locators specifically warn against their use with patients with cardiac pacemakers (Morita 1994). As there are many therapeutic uses and types of pacemakers some may not be influenced by apex locator use (Beach *et al.* 1996). Garofalo *et al.* (2002) conducted a bench top test using five-third generation electronic apex locators and concluded that all except the Bingo 1020 did not cause inhibition or interference with normal pacemaker function, and that electronic apex locators can be used safely in patients with pacemakers. As this study was not clinical it might be prudent to confer with the patients cardiologist prior to treatment.

Clinical acceptance. Use of the electronic apex locator to determine working length has still not gained widespread acceptance worldwide (Table 4). This may in part be due to early devices which suffered from poor accuracy and did not function properly in the presence of common irrigants. Cost of the instruments and exposure to the technology are also factors. A survey in New Zealand found apex locator use favoured by younger practitioners, and users reported a reduced number of radiographs taken during root canal treatment of a maxillary molar (Chandler & Koshy 2002). A Flemish survey (Hommeze *et al.* 2003b) found no relationship between time after graduation and apex locator use, and that about 80% of respondents never used the device. In Japan there is extensive use of apex locators, but large numbers of radiographs are also taken (Yoshikawa *et al.* 2001).

The use of apex locators alone without a preoperative and postoperative radiograph is not a recommended practice due to the large variation in tooth morphology and medico-legal record keeping requirements. ElAyo-uti *et al.* (2001) found that using radiographic working length calculations alone led to instrumentation beyond the apical foramen in 56% of premolars and

Table 4 Electronic apex locator use

Investigator	Country	Use	%
Whitten <i>et al.</i> (1996)	USA	GDPs	10
Saunders <i>et al.</i> (1999)	Scotland	GDPs	7.7
Yoshikawa <i>et al.</i> (2001)	Japan	GDPs	90
Chandler & Koshy (2002)	New Zealand	GDPs	27.5
		Specialists	60
Hommeze <i>et al.</i> (2003a)	Belgium	GDPs	16

GDP, general dental practitioner.

33% of molars. They subsequently found that the use of the Root ZX decreased the overestimation of working length of the premolar group to 21% (ElAyouti *et al.* 2002). Correct use of a calibrated apex locator would prevent the need for further radiographs merely to confirm what the clinician already knows (Clarke 2003, personal communication). A recent case report highlighted the requirement for a preoperative radiograph where an apex locator was initially used. The patient was pregnant and the subsequent failure to detect an anomalous root lead to the failure of treatment (Segura-Egea *et al.* 2002).

Conclusion

No individual technique is truly satisfactory in determining endodontic working length. The CDJ is a practical and anatomic termination point for the preparation and obturation of the root canal and this cannot be determined radiographically. Modern electronic apex locators can determine this position with accuracies of greater than 90% but still have some limitations. Knowledge of apical anatomy, prudent use of radiographs and the correct use of an electronic apex locator will assist practitioners to achieve predictable results.

Acknowledgement

We wish to thank Professor Brian Monteith for drawing Fig. 1.

References

- American Association of Endodontists (1984) *An Annotated Glossary of Terms Used in Endodontics*. Chicago, IL: American Association of Endodontists, pp. 1–3.
- Apex Locator Bingo – ‘1020’ (1999) *User Manual Revised*. Rishon Lezion, Israel: 5–7M Forum Engineering Technologies (96) Ltd.
- Arora RK, Gulabivala K (1995) An in vivo evaluation of the ENDEX and RCM Mark II electronic apex locators in root canals with different contents. *Oral Surgery, Oral Medicine, Oral Pathology, Oral Radiology and Endodontics* **79**, 497–503.
- Aurelio JA, Nahmias Y, Gerstein H (1983) A model for demonstrating an electronic canal length measuring device. *Journal of Endodontics* **9**, 568–9.
- Azabal M, Garcia-Otero D, de la Macorra JC (2004) Accuracy of the Justy II apex locator in determining working length in simulated horizontal and vertical fractures. *International Endodontic Journal* **37**, 174–77.
- Baggett FJ, Mackie IC, Worthington HV (1996) An investigation into the measurement of the working length of immature incisor teeth requiring endodontic treatment in children. *British Dental Journal* **181**, 96–8.
- Beach CW, Bramwell JD, Hutter JW (1996) Use of an electronic apex locator on a cardiac pacemaker patient. *Journal of Endodontics* **22**, 182–4.
- Berman LH, Fleischman SB (1984) Evaluation of the accuracy of the Neosono-D electronic apex locator. *Journal of Endodontics* **10**, 164–7.
- Blank LW, Tenca JI, Pelleu GB Jr (1975) Reliability of electronic measuring devices in endodontic therapy. *Journal of Endodontics* **1**, 141–5.
- Campbell D, Friedman S, Nguyen HQ, Kaufman A, Keila S (1998) Apical extent of rotary canal instrumentation with an apex-locating handpiece in vitro. *Oral Surgery, Oral Medicine, Oral Pathology, Oral Radiology and Endodontics* **85**, 319–24.
- Cederberg RA, Tidwell E, Frederiksen NL, Benson BW (1998) Endodontic working length assessment. Comparison of storage phosphor digital imaging and radiographic film. *Oral Surgery, Oral Medicine, Oral Pathology, Oral Radiology and Endodontics* **85**, 325–8.
- Chandler NP, Bloxham GP (1990) Effect of gloves on tactile discrimination using an endodontic model. *International Endodontic Journal* **23**, 97–9.
- Chandler NP, Koshy S (2002) Radiographic practices of dentists undertaking endodontics in New Zealand. *Dentomaxillofacial Radiology* **31**, 317–21.
- Chong BS, Pitt Ford TR (1994) Apex locators in endodontics: which, when and how? *Dental Update* **21**, 328–30.
- Chunn CB, Zardiackas LD, Menke RA (1981) In vivo root canal length determination using the Foramer. *Journal of Endodontics* **7**, 505–20.
- Clarke M (2003) *Personal Communication*. Dento-Legal Adviser Dental Protection Society, Leeds, UK.
- Cox VS, Brown CE Jr, Bricker SL, Newton CW (1991) Radiographic interpretation of endodontic file length. *Oral Surgery, Oral Medicine, Oral Pathology* **72**, 340–4.
- Custer C (1918) Exact methods for locating the apical foramen. *Journal of the National Dental Association* **5**, 815–9.
- Czerw RJ, Fulkerson MS, Donnelly JC (1994) An in vitro test of a simplified model to demonstrate the operation of electronic root canal measuring devices. *Journal of Endodontics* **20**, 605–6.
- Czerw RJ, Fulkerson MS, Donnelly JC, Walmann JO (1995) In vitro evaluation of the accuracy of several electronic apex locators. *Journal of Endodontics* **21**, 572–5.
- De Moor RJ, Hommez GM, Martens LC, De Boever JG (1999) Accuracy of four electronic apex locators: an in vitro evaluation. *Endodontics and Dental Traumatology* **15**, 77–82.
- Dummer PM, McGinn JH, Rees DG (1984) The position and topography of the apical canal constriction and apical foramen. *International Endodontic Journal* **17**, 192–8.

- Dunlap CA, Remeikis NA, BeGole EA, Rauschenberger CR (1998) An in vivo evaluation of an electronic apex locator that uses the ratio method in vital and necrotic canals. *Journal of Endodontics* **24**, 48–50.
- EIE Analytic Endodontics (2002) *Apex Finder Introductory Fact Sheet*. Orange, CA: EIE/Analytic.
- ElAyouti A, Weiger R, Löst C (2001) Frequency of overinstrumentation with an acceptable radiographic working length. *Journal of Endodontics* **27**, 49–52.
- ElAyouti A, Weiger R, Löst C (2002) The ability of the Root ZX apex locator to reduce the frequency of overestimated radiographic working length. *Journal of Endodontics* **28**, 116–19.
- Felippe MC, Soares IJ (1994) In vitro evaluation of an audiometric device in locating the apical foramen of teeth. *Endodontics and Dental Traumatology* **10**, 220–2.
- Foreman PC, Howat M (1986) A home-made apex locator. *British Dental Journal* **161**, 336–7.
- Fouad AF, Reid LC (2000) Effect of using electronic apex locators on selected endodontic treatment parameters. *Journal of Endodontics* **26**, 364–7.
- Fouad AF, Krell KV, McKendry DJ, Koobusch GF, Olson RA (1990) Clinical evaluation of five electronic root canal length measuring instruments. *Journal of Endodontics* **16**, 446–9.
- Fouad AF, Rivera EM, Krell KV (1993) Accuracy of the Endex with variations in canal irrigants and foramen size. *Journal of Endodontics* **19**, 63–7.
- Frank AL, Torabinejad M (1993) An in vivo evaluation of Endex electronic apex locator. *Journal of Endodontics* **19**, 177–9.
- Friedlander LT, Love RM, Chandler NP (2002) A comparison of phosphor-plate digital images with conventional radiographs for the perceived clarity of fine endodontic files and periapical lesions. *Oral Surgery, Oral Medicine, Oral Pathology, Oral Radiology and Endodontics* **93**, 321–7.
- Fuss Z, Assouline LS, Kaufman AY (1996) Determination of location of root perforations by electronic apex locators. *Oral Surgery, Oral Medicine, Oral Pathology, Oral Radiology and Endodontics* **82**, 324–9.
- Garofalo RR, Ede EN, Dorn SO, Kuttler S (2002) Effect of electronic apex locators on cardiac pacemaker function. *Journal of Endodontics* **28**, 831–3.
- Green D (1956) A stereomicroscopic study of the root apices of 400 maxillary and mandibular anterior teeth. *Oral Surgery, Oral Medicine, Oral Pathology* **9**, 1224–32.
- Green D (1960) A stereomicroscopic study of 700 root apices of maxillary and mandibular posterior teeth. *Oral Surgery, Oral Medicine, Oral Pathology* **13**, 728–33.
- Grimberg F, Banegas G, Chiacchio L, Zmener O (2002) In vivo determination of root canal length: a preliminary report using the Tri Auto ZX apex-locating handpiece. *International Endodontic Journal* **35**, 590–3.
- Grove C (1930) Why canals should be filled to the dentinocemental junction. *Journal of the American Dental Association* **17**, 293–6.
- Gutierrez JH, Aguayo P (1995) Apical foraminal openings in human teeth. Number and location. *Oral Surgery, Oral Medicine, Oral Pathology, Oral Radiology and Endodontics* **79**, 769–77.
- Hasegawa K, Iizuka H, Takei M, Goto N, Nihei M, Ohashi M (1986) A new method and apparatus for measuring root canal length. *Journal of the Nihon University School of Dentistry* **28**, 117–28.
- Himel V (1993) An evaluation of two electronic apex locators in a dental student clinic. *Quintessence International* **24**, 803–6.
- Himel VT, Schott RN (1993) An evaluation of the durability of apex locator insulated probes after autoclaving. *Journal of Endodontics* **19**, 392–4.
- Hoer D, Attin T (2004) The accuracy of electronic working length determination. *International Endodontic Journal* **37**, 125–31.
- Hommez GM, Braem M, DeMoor RJ (2003a) Root canal treatment performed by Flemish dentists. Part 1. Cleaning and shaping. *International Endodontic Journal* **36**, 166–73.
- Hommez GM, De Moor RJ, Braem M (2003b) Endodontic treatment performed by Flemish dentists. Part 2. Canal filling and decision making for referrals and treatment of apical periodontitis. *International Endodontic Journal* **36**, 344–51.
- Huang L (1987) An experimental study of the principle of electronic root canal measurement. *Journal of Endodontics* **13**, 60–4.
- Hülsmann M, Pieper K (1989) Use of an electronic apex locator in the treatment of teeth with incomplete root formation. *Endodontics and Dental Traumatology* **5**, 238–41.
- Ibarrola JL, Chapman BL, Howard JH, Knowles KI, Ludlow MO (1999) Effect of preflaring on Root ZX apex locators. *Journal of Endodontics* **25**, 625–6.
- Ingle J, Himel T, Hawrish C et al. (2002) Endodontic cavity preparation. In: Ingle J, Bakland L, eds. *Endodontics*. Hamilton, Ontario: BC Decker, pp. 517–25.
- Inoue N (1972) Dental 'stethoscope' measures root canal. *Dental Survey* **48**, 38–9.
- Inoue N (1973) An audiometric method for determining the length of root canals. *Journal of the Canadian Dental Association* **39**, 630–6.
- Inoue N, Skinner DH (1985) A simple and accurate way to measuring root canal length. *Journal of Endodontics* **11**, 421–7.
- Jenkins JA, Walker WAr, Schindler WG, Flores CM (2001) An in vitro evaluation of the accuracy of the Root ZX in the presence of various irrigants. *Journal of Endodontics* **27**, 209–11.
- Katz A, Mass E, Kaufman AY (1996) Electronic apex locator: a useful tool for root canal treatment in the primary dentition. *ASDC Journal of Dentistry for Children* **63**, 414–7.
- Kaufman AY, Keila S (1989) Conservative treatment of root perforations using apex locator and thermatic compactor-

- case study of a new method. *Journal of Endodontics* **15**, 267–72.
- Kaufman AY, Szajkis S, Niv N (1989) The efficiency and reliability of the Dentometer for detecting root canal length. *Oral Surgery, Oral Medicine, Oral Pathology* **67**, 573–7.
- Kaufman AY, Fuss Z, Keila S, Waxenberg S (1997) Reliability of different electronic apex locators to detect root perforations in vitro. *International Endodontic Journal* **30**, 403–7.
- Kaufman AY, Keila S, Yoshpe M (2002) Accuracy of a new apex locator: an in vitro study. *International Endodontic Journal* **35**, 186–92.
- Keller ME, Brown CE Jr, Newton CW (1991) A clinical evaluation of the Endocater—an electronic apex locator. *Journal of Endodontics* **17**, 271–4.
- Kielbassa AM, Muller U, Munz I, Monting JS (2003) Clinical evaluation of the measuring accuracy of ROOT ZX in primary teeth. *Oral Surgery, Oral Medicine, Oral Pathology, Oral Radiology and Endodontics* **95**, 94–100.
- Kobayashi C (1995) Electronic canal length measurement. *Oral Surgery, Oral Medicine, Oral Pathology, Oral Radiology and Endodontics* **79**, 226–31.
- Kobayashi C, Suda H (1994) New electronic canal measuring device based on the ratio method. *Journal of Endodontics* **20**, 111–4.
- Kobayashi C, Okiji T, Kaqwashima N, Suda H, Sunada I (1991) A basic study on the electronic root canal length measurement: Part 3. Newly designed electronic root canal length measuring device using division method. *Japanese Journal of Conservative Dentistry* **34**, 1442–8.
- Kobayashi C, Yoshioka T, Suda H (1996) A new ultrasonic canal preparation system with electronic monitoring of file tip position. *Journal of Endodontics* **22**, 489–92.
- Kobayashi C, Yoshioka T, Suda H (1997) A new engine-driven canal preparation system with electronic canal measuring capability. *Journal of Endodontics* **23**, 751–4.
- Kovacevic M, Tamarut T (1998) Influence of the concentration of ions and foramen diameter on the accuracy of electronic root canal length measurement—an experimental study. *Journal of Endodontics* **24**, 346–51.
- Kuttler Y (1955) Microscopic investigation of root apices. *Journal of the American Dental Association* **50**, 544–52.
- Lauper R, Lutz F, Barbakow F (1996) An in vivo comparison of gradient and absolute impedance electronic apex locators. *Journal of Endodontics* **22**, 260–3.
- Lively B (2003) *Personal communication. Product Manager Diagnostic Products. Anaheim, CA, USA: Sybron Endo.*
- Martinez-Lozano MA, Forner-Navarro L, Sanchez-Cortes JL, Llana-Puy C (2001) Methodological considerations in the determination of working length. *International Endodontic Journal* **34**, 371–6.
- Mayeda DL, Simon JH, Aymar DF, Finley K (1993) In vivo measurement accuracy in vital and necrotic canals with the Endex apex locator. *Journal of Endodontics* **19**, 545–8.
- McDonald NJ (1992) The electronic determination of working length. *Dental Clinics of North America* **36**, 293–307.
- McDonald NJ, Hovland EJ (1990) An evaluation of the Apex Locator Endocater. *Journal of Endodontics* **16**, 5–8.
- McDonald NJ, Pileggi R, Glickman G, Varella C (1999) An in vivo evaluation of third generation apex locators [abstract]. *Journal of Dental Research* **78**, 373.
- McGinty DT, Fabre DD, Miller DA, Lautenschlager EP (1996) Do irrigants affect the precision of apex locators? [abstract]. *Journal of Endodontics* **22**, 195.
- Meares WA, Steiman HR (2002) The influence of sodium hypochlorite irrigation on the accuracy of the Root ZX electronic apex locator. *Journal of Endodontics* **28**, 595–8.
- Mente J, Seidel J, Buchalla W, Koch MJ (2002) Electronic determination of root canal length in primary teeth with and without root resorption. *International Endodontic Journal* **35**, 447–52.
- Morita J (1994) *Root ZX Operation Manual. Japan: J. Morita Mfg. Corp.*
- Nahmias Y, Aurelio JA, Gerstein H (1983) Expanded use of the electronic canal length measuring devices. *Journal of Endodontics* **9**, 347–9.
- Nekoofar MH, Sadeghi K, Akha ES, Namazikhah MS (2002) The accuracy of the Neosono Ultima EZ apex locator using files of different alloys: an in vitro study. *Journal of the Californian Dental Association* **30**, 681–4.
- Nguyen HQ, Kaufman AY, Komorowski RC, Friedman S (1996) Electronic length measurement using small and large files in enlarged canals. *International Endodontic Journal* **29**, 359–64.
- O'Neill LJ (1974) A clinical evaluation of electronic root canal measurement. *Oral Surgery, Oral Medicine, Oral Pathology* **38**, 469–73.
- Olson AK, Goerig AC, Cavataio RE, Luciano J (1991) The ability of the radiograph to determine the location of the apical foramen. *International Endodontic Journal* **24**, 28–35.
- Ounsi HF, Haddad G (1998) In vitro evaluation of the reliability of the Endex electronic apex locator. *Journal of Endodontics* **24**, 120–1.
- Ounsi HF, Naaman A (1999) In vitro evaluation of the reliability of the Root ZX electronic apex locator. *International Endodontic Journal* **32**, 120–3.
- Pagavino G, Pace R, Baccetti T (1998) A SEM study of in vivo accuracy of the Root ZX electronic apex locator. *Journal of Endodontics* **24**, 438–41.
- Pineda F, Kuttler Y (1972) Mesiodistal and buccolingual roentgenographic investigation of 7,275 root canals. *Oral Surgery, Oral Medicine, Oral Pathology* **33**, 101–10.
- Pommer O, Stamm O, Attin T (2002) Influence of the canal contents on the electrical assisted determination of the length of root canals. *Journal of Endodontics* **28**, 83–5.
- Pratten DH, McDonald NJ (1996) Comparison of radiographic and electronic working lengths. *Journal of Endodontics* **22**, 173–6.
- Ricucci D, Langeland K (1998) Apical limit of root canal instrumentation and obturation, part 2. *A histological study International Endodontic Journal* **31**, 394–409.

- Rivera EM, Seraji MK (1993) Effect of recapitulation on accuracy of electronically determined canal length. *Oral Surgery, Oral Medicine, Oral Pathology* **76**, 225–30.
- Rivera EM, Seraji MK (1994) Placement accuracy of electrically conductive gutta-percha. *Journal of Endodontics* **20**, 342–4.
- Saito T, Yamashita Y (1990) Electronic determination of root canal length by newly developed measuring device. Influences of the diameter of apical foramen, the size of K-file and the root canal irrigants. *Dentistry in Japan* **27**, 65–72.
- Saunders WP, Chestnutt IG, Saunders EM (1999) Factors influencing the diagnosis and management of teeth with pulpal and periradicular disease by general dental practitioners. Part 2. *British Dental Journal* **187**, 548–54.
- Schilder H (1967) Filling root canals in three dimensions. *Dental Clinics of North America* **11**, 723–44.
- Segura-Egea JJ, Jimenez-Pinzon A, Rios-Santos JV (2002) Endodontic therapy in a 3-rooted mandibular first molar: importance of a thorough radiographic examination. *Journal of the Canadian Dental Association* **68**, 541–4.
- Seidberg BH, Alibrandi BV, Fine H, Logue B (1975) Clinical investigation of measuring working lengths of root canals with an electronic device and with digital-tactile sense. *Journal of the American Dental Association* **90**, 379–87.
- Shabahang S, Goon WW, Gluskin AH (1996) An in vivo evaluation of Root ZX electronic apex locator. *Journal of Endodontics* **22**, 616–8.
- Shearer AC, Horner K, Wilson NH (1991) Radiovisiography for length estimation in root canal treatment: an in-vitro comparison with conventional radiography. *International Endodontic Journal* **24**, 233–9.
- Sjögren U, Hagglund B, Sundqvist G, Wing K (1990) Factors affecting the long-term results of endodontic treatment. *Journal of Endodontics* **16**, 498–504.
- Stabholz A, Rotstein I, Torabinejad M (1995) Effect of preflaring on tactile detection of the apical constriction. *Journal of Endodontics* **21**, 92–4.
- Steffen H, Splieth CH, Behr K (1999) Comparison of measurements obtained with hand files or the Canal Leader attached to electronic apex locators: an in vitro study. *International Endodontic Journal* **32**, 103–7.
- Stein TJ, Corcoran JF (1990) Anatomy of the root apex and its histologic changes with age. *Oral Surgery, Oral Medicine, Oral Pathology* **69**, 238–42.
- Stein TJ, Corcoran JF, Zillich RM (1990) Influence of the major and minor foramen diameters on apical electronic probe measurements. *Journal of Endodontics* **16**, 520–2.
- Stock C (1994) Endodontics-position of the apical seal. *British Dental Journal* **176**, 329.
- Sunada I (1962) New method for measuring the length of the root canal. *Journal of Dental Research* **41**, 375–87.
- Suzuki K (1942) Experimental study on iontophoresis. *Japanese Journal of Stomatology* **16**, 411–29.
- Tamse A, Kaffe I, Fishel D (1980) Zygomatic arch interference with correct radiographic diagnosis in maxillary molar endodontics. *Oral Surgery, Oral Medicine, Oral Pathology* **50**, 563–6.
- Thomas AS, Hartwell GR, Moon PC (2003) The accuracy of the Root ZX electronic apex locator using stainless-steel and nickel-titanium files. *Journal of Endodontics* **29**, 662–3.
- Tidmarsh BG, Sherson W, Stalker NL (1985) Establishing endodontic working length: a comparison of radiographic and electronic methods. *New Zealand Dental Journal* **81**, 93–6.
- Tinaz AC, Maden M, Aydin C, Turkoz E (2002a) The accuracy of three different electronic root canal measuring devices: an in vitro evaluation. *Journal of Oral Science* **44**, 91–5.
- Tinaz AC, Alacam T, Topuz O (2002b) A simple model to demonstrate the electronic apex locator. *International Endodontic Journal* **35**, 940–5.
- Trope M, Rabie G, Tronstad L (1985) Accuracy of an electronic apex locator under controlled clinical conditions. *Endodontics and Dental Traumatology* **1**, 142–5.
- Ushiyama J (1983) New principle and method for measuring the root canal length. *Journal of Endodontics* **9**, 97–104.
- Ushiyama J, Nakamura M, Nakamura Y (1988) A clinical evaluation of the voltage gradient method of measuring the root canal length. *Journal of Endodontics* **14**, 283–7.
- Vajrabhaya L, Tepmongkol P (1997) Accuracy of apex locator. *Endodontics and Dental Traumatology* **13**, 180–2.
- Weiger R, John C, Geigle H, Lost C (1999) An in vitro comparison of two modern apex locators. *Journal of Endodontics* **25**, 765–8.
- Welk AR, Baumgartner JC, Marshall JG (2003) An in vivo comparison of two frequency-based electronic apex locators. *Journal of Endodontics* **29**, 497–500.
- White P, Austin B, Walia H, Dhuru V (1996) Comparison of accuracy of four apex locators [abstract]. *Journal of Endodontics* **22**, 216.
- Whitten BH, Gardiner DL, Jeansonne BG, Lemon RR (1996) Current trends in endodontic treatment: report of a national survey. *Journal of the American Dental Association* **127**, 1333–41.
- Woolley LH, Woodworth J, Dobbs JL (1974) A preliminary evaluation of the effects of electrical pulp testers on dogs with artificial pacemakers. *Journal of the American Dental Association* **89**, 1099–101.
- Wu YN, Shi JN, Huang LZ, Xu YY (1992) Variables affecting electronic root canal measurement. *International Endodontic Journal* **25**, 88–92.
- Yoshikawa G, Sawada N, Wettasinghe KA, Suda H (2001) Survey of endodontic treatment in Japan [abstract]. *Journal of Endodontics* **27**, 236.