



Stephane Simon

Pierre Machtou, Phillip Tomson, Nick Adams and Philip Lumley

# Influence of Fractured Instruments on the Success Rate of Endodontic Treatment

**Abstract:** The fracture of an instrument is a recognized complication in endodontics. The immediate response to a fractured instrument is frequently to regard the treatment as a failure. Several factors must, however, be taken into account to evaluate the prognosis of the tooth in this situation. The objective of the endodontic treatment with or without a fractured instrument remains the same, namely to disinfect the root canal system and prevent its recontamination. The time at which file fracture occurred during treatment and the degree of canal infection should be considered when determining the potential effect of instrument fracture on treatment outcome. Patients must be informed about an instrument fracturing in their tooth for ethical and legal reasons. The aim of this paper is to attempt to place fractured instruments in context, not to provide an in depth description of fractured instrument management techniques.

**Clinical Relevance:** To understand the influence of fractured instruments on prognosis in endodontics.

**Dent Update 2008; 35: 172-179**

Rotary Nickel Titanium (NiTi) instruments can help the clinician to achieve excellent endodontic results, provided that the operator uses them carefully, following

sensible protocols including the establishment of straight line access and a glide path. Instrument fracture is not limited to NiTi files and it is important to maintain an adequate quality control programme, including not over using instruments and disposing of damaged files during treatment.

The success of endodontic treatment is affected negatively by inappropriate shaping, disinfection and obturation of the root canal system. It may take several months, or even years, for objective evidence of failure to appear radiographically as patients rarely experience pain. This can lead to patient confusion in regard to the relationship between failure and treatment carried out several years earlier. The fracture of an endodontic instrument during shaping can be a devastating experience for the practitioner. This paper explores whether a fragment of instrument left in the canal during root canal treatment should be considered a factor in failure and, if it is, how does it influence the prognosis?

## Is instrument fracture new to rotary NiTi?

A NiTi instrument, contrary to generally accepted belief, is not more fragile than a stainless steel instrument of equivalent size; fractured instruments occurred long before the introduction of rotary NiTi instruments. Radiographic evidence of treatment performed before 1991 shows remnants of endodontic instruments (stainless steel files, Lentulos®, thermocompactors, reamers, etc) left in root canals.

The effect of fractured instruments on prognosis became of greater interest following the introduction of rotary NiTi instruments since this resulted in a number of dental surgeons becoming aware of the problem through their own experience. To date, no study has demonstrated clearly that the number of fractured instruments has increased since the implementation of rotary NiTi instrumentation. Clinical studies have shown a relatively low rate of instrument fracture with these techniques: 2.7%<sup>1</sup> and 3.7%.<sup>2</sup> It was suggested that the fractures that did occur were caused by

**Stephane Simon**, FDS, MSc, Clinical Lecturer in Endodontics, Honorary Associate Specialist, University of Birmingham School of Dentistry (UK) and University of Paris 7 (France), **Pierre Machtou**, FDS, PhD, Professor of Endodontology, University of Paris 7 (France), **Phillip Tomson**, BDS, MFDS RCSEd, MFDS RCSEng, Clinical Lecturer and Honorary Specialist Registrar in Restorative Dentistry, University of Birmingham School of Dentistry, **Nick Adams**, BDS, MSc, MRD RCS(Eng), Specialist in Endodontics, Clinical Lecturer and Honorary Associate Specialist, University of Birmingham School of Dentistry and **Philip Lumley**, BDS, MDentSci, PhD, FDS RCPS, Professor of Endodontology and Honorary Consultant in Restorative Dentistry, University of Birmingham School of Dentistry, UK.

	Success rate	Influence of fractured files on outcome of endodontic treatment
Strindberg <sup>8</sup>	73%	Reduction of 19%
Engström <i>et al</i> <sup>9</sup>	67%	No effect
Engström and Lundberg <sup>10</sup>	100%	No effect
Grossman <sup>11</sup>	77%	Reduction in the success rate if periapical lesion
Crump and Natkin <sup>12</sup>	91%	No effect
Fox <i>et al</i> <sup>13</sup>	93%	Reduction in the success rate if periapical lesion
Kerekes and Tronstad <sup>14</sup>	82%	Reduction in the success rate on tooth necrosed
Molyvdas <i>et al</i> <sup>15</sup>	87%	Reduction in the success rate if periapical lesion

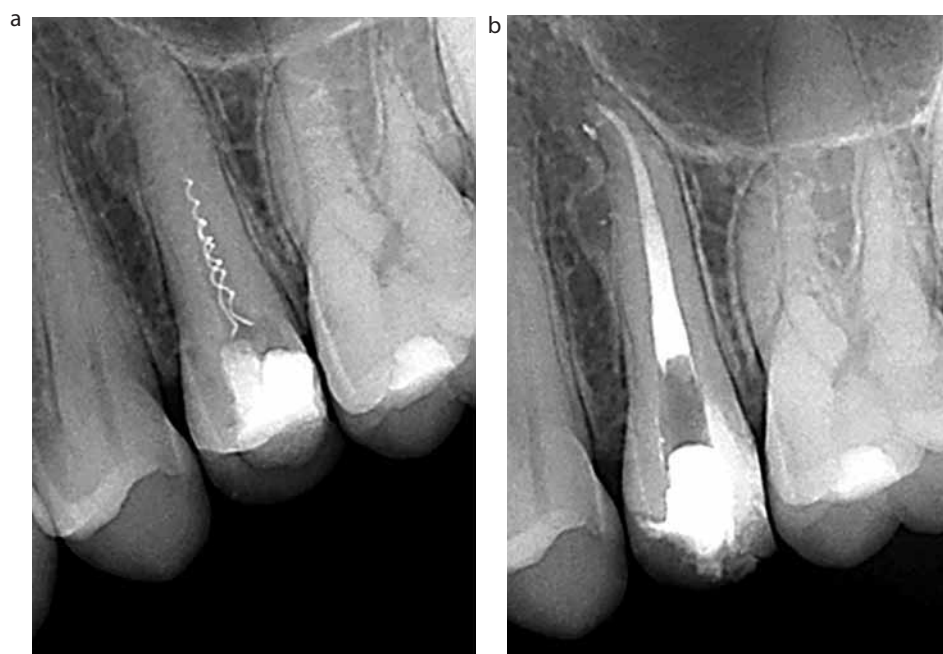**Table 1.** Influence on the success rate reviewed in the literature.

inappropriate use.

The apparent ease with which endodontic treatment can be performed using rotary NiTi instruments has increased the expectation of clinicians. The anticipation of a pleasing radiographic result following treatment is lost when an instrument fractures in a root canal. Such an event is frustrating for the operator, who then considers the treatment a failure, with the 'apparent' cause visible on a radiograph, although NiTi can be difficult to distinguish from gutta-percha. Clinicians may be misled by the concept that technical errors, such as fractured instruments, perforations, overfilling, etc can be the direct cause of endodontic failure. Whereas, in the majority of cases, the procedural mishap does not directly compromise the prognosis, unless a concomitant infection is already present.<sup>3</sup>

The concept of failure therefore remains relative, since an instrument is seldom the direct cause; it does, however, limit access to the apical part of the canal, compromising disinfection and obturation. Thus a fragment of instrument may be indirectly responsible for an endodontic failure but is rarely directly responsible. When treatment is completed in ideal conditions where asepsis, disinfection and three-dimensional obturation of the canal system are achieved, the risk of formation of an apical lesion, one sign of an endodontic failure, is low.<sup>4,5,6</sup> If one of these elements is missing, usually for technical reasons, the success rate decreases.<sup>7</sup>

The effect of instrument fracture on prognosis had been reported prior to the introduction of nickel titanium rotary



**Figure 1.** (a, b) The two fragments of a spiral filler fractured in the coronal third of the canal are an additional complication for retreatment of this tooth. The removal of these instruments makes it possible to shape, disinfect and fill the root canal conventionally.

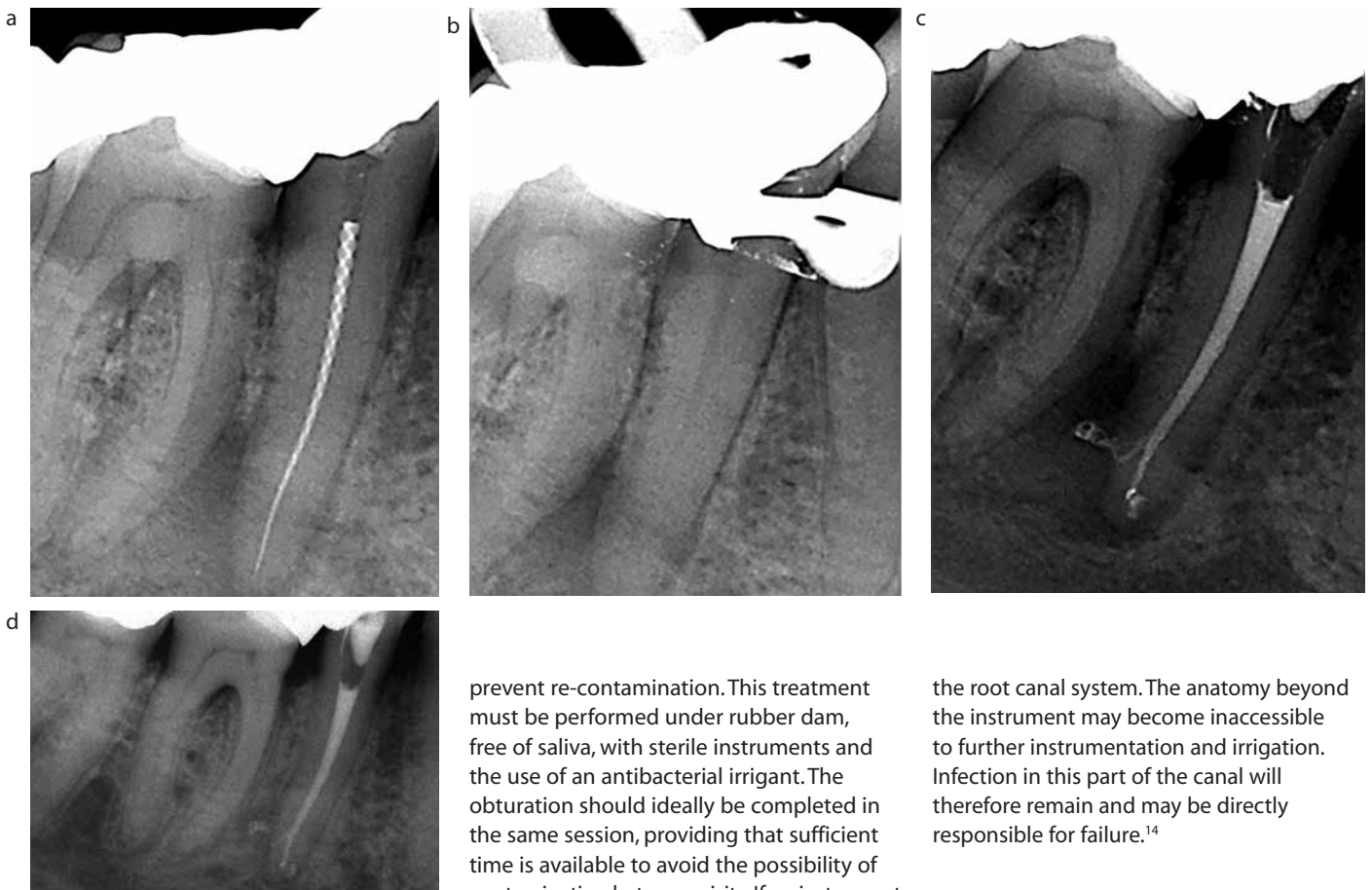
instruments (Table 1). All of these studies, with the exception of Grossman,<sup>11</sup> showed that the presence of a fractured instrument had little influence on success rates. It was also demonstrated that the failure rate increased when a periapical lesion was present. This suggests that the nature of the problem lies with the presence of infection rather than the fractured instrument.

A fractured instrument limits access to the apical part of the canal, compromising shaping and disinfection.

The fragment of instrument behaves as an additional complication alongside those already existing naturally, such as the size of the canal, its curvature, calcifications, etc (Figure 1).

### Influence of canal infection on prognosis

The clinical situation (absence or presence of infection) and the time of instrument fracture during treatment can



**Figure 2.** The long fragment of instrument is indirectly responsible for the bacterial contamination of the canal, which is now difficult to treat. (a) Complete disinfection after retrieval of the instrument (b) and the three-dimensional obturation of the canal system (c) are the key points to obtain the bony healing of the periapical lesion (d) (review at 14 months).

prevent re-contamination. This treatment must be performed under rubber dam, free of saliva, with sterile instruments and the use of an antibacterial irrigant. The obturation should ideally be completed in the same session, providing that sufficient time is available to avoid the possibility of contamination between visits. If an instrument fractures during the shaping process, then a radiograph should be taken to establish its position. If the location precludes easy removal or bypass, then *treatment should be concluded in the same visit*, including root canal filling and coronal seal. If the canal system has never been contaminated, the presence of the retained fragment should have no influence on the prognosis.

### Infected canals

When the root canal system is infected with bacteria, the objective of treatment is to obtain complete disinfection, and prevent re-infection with an appropriate endodontic and coronal seal. If the fracture occurs at the end of instrumentation, and disinfection has already been obtained, then the canal should be sealed conventionally, by embedding the fragment in the filling material. In this case, the prognosis is reasonable. If, on the other hand, the fracture occurs early in treatment, then there will have been little opportunity to disinfect

the root canal system. The anatomy beyond the instrument may become inaccessible to further instrumentation and irrigation. Infection in this part of the canal will therefore remain and may be directly responsible for failure.<sup>14</sup>

### Retreatment

This problem is comparable with the above, the objectives of treatment are the same; specifically, disinfection of the root canal system and prevention of its re-infection. The presence of an apical radiolucency confirms infection of the canal; nevertheless the absence of a lesion should not be regarded as a guarantee of sterility. During retreatment, the root canal system should be considered as contaminated and the presence of a retained instrument fragment may prevent access to the apical third of the canal, thus compromising disinfection. If the instrument can be removed or bypassed, treatment objectives can be achieved with a success rate equivalent to conventional retreatment.<sup>16</sup>

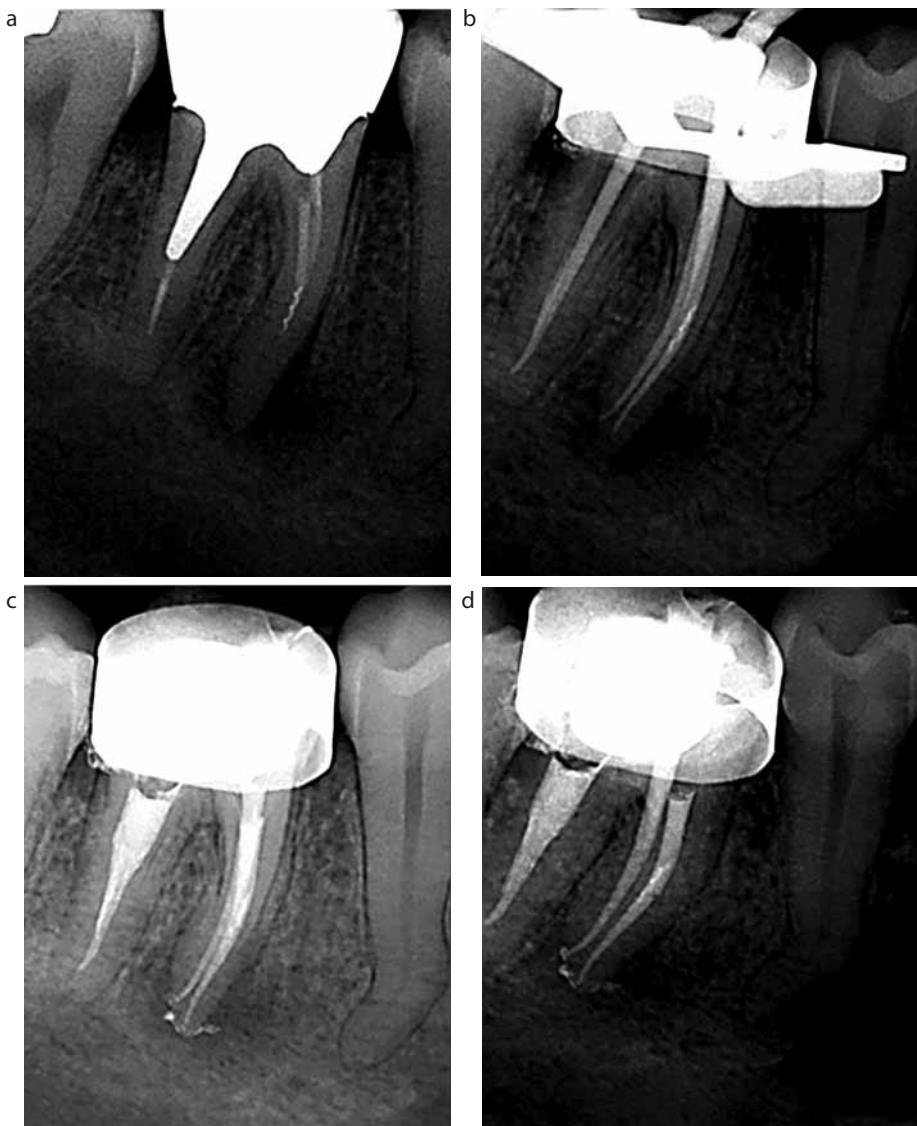### Which approach should be adopted in managing a fractured instrument?

Assessing the position and managing the presence of fractured instruments can be complex and, where

significantly influence prognosis and the approach to management. It is preferable to remove the fragment and pursue treatment under ideal conditions, but this is not always possible. The risks of removal should be balanced against benefits as weakening of the tooth or perforation during instrument removal may be more detrimental than the fragment of instrument.

### Vital pulpectomy

In this situation, the canal is virtually sterile, the objective of treatment is to remove all pulp tissue, shape, disinfect and fill the canal, sealing the access to



**Figure 3.** The fragment of spiral filler in the middle third of the mesio buccal root could not be removed. (a) It is by-passed, enabling the passage of endodontic files and fresh irrigant (b) to the apical root canal anatomy. The instrument has been embedded in the filling material (c, d).

doubt exists, patients should be referred for advice on management. Several approaches can be adopted:

- Removal of the fragment;
- Leaving it *in situ*;
- Bypassing the instrument; or
- Surgery.

The objective of the treatment remains the same, namely disinfection of the canal. If removal of the fragment is deemed to be the ideal solution (Figure 2), then the clinical procedure is often delicate and may compromise tooth conservation in the long term. Considerable care is required

during instrument removal; destruction of tooth structure is inherent in the procedure and, if extensive, can sometimes compromise the prognosis. If instrument removal is considered too dangerous, excellent results may be obtained by bypassing the fragment and embedding it in the root filling, as its presence within the gutta-percha should not unduly affect the quality of the obturation<sup>17</sup> (Figure 3). It could be argued that it is preferable to attempt instrument bypass initially in view of this technique normally being more conservative of dentine, especially in

difficult to access areas of the canal.

Finally, if it is not possible to bypass the fragment, then the canal should be shaped, disinfected and filled to the accessible length and restored. The success rate will be dependent on canal contamination and fragment position (apical, middle or coronal third) as this influences the amount of root canal system that has not been disinfected (Figure 4).

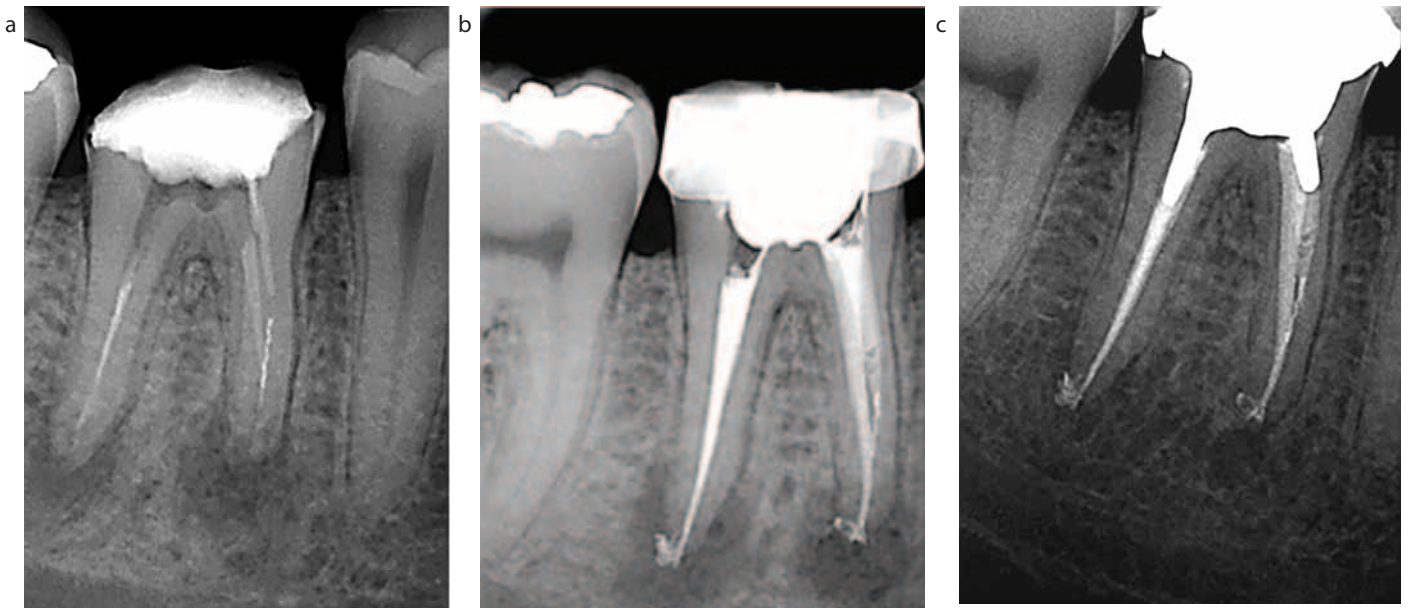
Radiographic follow-up to evaluate periapical health is necessary; if the lesion is seen to be increasing in size or there are clinical symptoms (pain, swelling, sinus tract), apical surgery or extraction must be performed to remove that part of the root which has not been disinfected during orthograde treatment.

### Patient management

Instrument fracture is a significant frustration for the practitioner, however, another problem that arises is informing the patient of the event. Legally, it is necessary to inform the patient about difficulties encountered during treatment. Within this framework, there is an obligation to inform the patient if an instrument has fractured during treatment and been left in the canal. Information must be focused on the possible consequences of this event, the influence on success rate, the complications which might occur, and any further treatment that may be required.

A recent study<sup>16</sup> considered 8460 teeth and concluded that the presence of a fragment of fractured instrument in the root canal did not significantly influence the success rate of endodontic treatment (91.8% if a fragment is present, and 94.5% if not). The authors, however, only considered cases in which the instrument had fractured during primary endodontic treatment; retreatment cases with a fragment already present were not included.

Given these results, one might argue that the effect in vital cases is so small that patients do not need to be informed of the event, especially as it is difficult to acknowledge one's weaknesses, and to have to share them with the patient. The necessity to inform the patient that a complication occurred during treatment, however, remains but, given the small effect on prognosis in vital cases, the message



**Figure 4.** The fragment of instrument located in the middle third of the mesio buccal canal could neither be removed nor bypassed. **(a)** In this situation, the accessible length of the canal has been shaped and disinfected. **(b)** Review at 12 months shows signs of healing, proof that the objectives of the treatment were still achieved **(c)**. In this case, the two canals joined in the middle of the root and demonstrate that, although the mesio buccal canal was not ideally disinfected, the apical part of the canal has been cleaned via the mesio lingual canal and healing has resulted.

could be adapted in order not to worry the patient unnecessarily. It is acknowledged that patients should be informed about a broken instrument even though it may have little effect on prognosis. This then begs the question, should we warn patients each time treatment does not result in a perfect outcome. In reality, few patients are informed about all aspects of non ideal treatment.

It is therefore necessary to find the right explanatory words and fulfil our ethical obligations without worrying the patient unnecessarily. This information must take into account the factors described previously, namely:

- The timing of the fracture during treatment;
- The level of contamination of the canal prior to treatment; and
- The degree to which the instrument will compromise the seal of the canal.

In the event of conflict with a patient, the retained instrument in the canal tends to be the focus of attention and failure to inform the patient is viewed in a negative light. However, defective endodontic treatment is rarely condemned to the same extent.

Management of instrument

fracture is complex. Its effect on the prognosis of treatment is small, although it can be associated with treatment failure. To the patient it is frequently the primary focus of any problems they may encounter. However, removal of an instrument fragment may actually make the situation worse. Ultrasonic tips have been miniaturized, but the use of grasping instruments (IRS, Masseran) can result in the removal of large amounts of dentine, especially if the instrument lies in the apical portion or is hidden beyond canal curvature. These factors need to be taken into account in order to avoid compromising the tooth.

Finally, it is necessary to organize appropriate follow-up of the patient in the event of any clinical complication. This allows periodical review and control radiographs to be taken, thereby enabling an evaluation of changes in associated pathology to be made. If deterioration of periapical health is detected, referral or endodontic surgery should be considered.

Lack of periodic reviews would leave the dental surgeon open to possible reproach. Regular follow-ups to anticipate and deal with any potential problems

are advocated. In this way, many difficult situations can be avoided and patient satisfaction maintained.

## Conclusion

The success rate of an endodontic treatment is related to disinfection of the canal, even in the presence of a fractured instrument. An instrument fragment is rarely the direct cause of the problem and, when the obstacle can be by-passed, and disinfection obtained, the prognosis is hardly affected. The fracture of an instrument, whether it is Nickel Titanium or Stainless Steel, is normally related to inappropriate use. Preventing fracture by operator training, monitoring instruments for signs of deformation and using them only once remain the best way of minimizing problems.

## References

1. Fishelberg G, Pawluk JW. Nickel-titanium rotary-file canal preparation and intracanal file separation. *Compend Contin Educ Dent* 2004; **25**: 17–24; quiz 25, 47.
2. Ramirez-Salomon M, Soler-Bientz R, de

- la Garza-Gonzalez R, Palacios-Garza CM. Incidence of Lightspeed separation and the potential for bypassing. *J Endod* 1997; **23**: 586–587.
3. Siqueira JF, Jr. Aetiology of root canal treatment failure: why well-treated teeth can fail. *Int Endod J* 2001; **34**: 1–10.
  4. Farzaneh M, Abitbol S, Friedman S. Treatment outcome in endodontics: the Toronto study. Phases I and II: Orthograde retreatment. *J Endod* 2004a; **30**: 627–633.
  5. Farzaneh M, Abitbol S, Lawrence HP, Friedman S. Treatment outcome in endodontics – the Toronto Study. Phase II: initial treatment. *J Endod* 2004b; **30**: 302–309.
  6. Marquis VL, Dao T, Farzaneh M, Abitbol S, Friedman S. Treatment outcome in endodontics: the Toronto Study. Phase III: initial treatment. *J Endod* 2006; **32**: 299–306.
  7. Sjögren U, Hagglund B, Sundqvist G, Wing K. Factors affecting the long-term results of endodontic treatment. *J Endod* 1990; **16**: 498–504.
  8. Strindberg LZ. The dependence of the results of pulp therapy on certain factors: an analytical study based on radiographic and clinical follow-up examinations. *Acta Odontol Scand* 1956; **14**(Suppl 21): 171–175.
  9. Engström B, Hård L, Segerstad AF, Ramström G, Frostell G. Correlation of positive cultures with the prognosis for root canal treatment. *Odontol Revy* 1964; **15**: 257–270.
  10. Engström B, Lundberg M. The correlation between positive culture and the prognosis of root canal therapy after pulpectomy. *Odontol Revy* 1965; **16**: 193–203.
  11. Grossman LI. Guidelines for the prevention of fracture of root canal instruments. *Oral Surg Oral Med Oral Pathol* 1969; **28**: 746–752.
  12. Crump MC, Natkin E. Relationship of broken root canal instruments to endodontic case prognosis: a clinical investigation. *J Am Dent Assoc* 1970; **80**: 1341–1347.
  13. Fox J, Moodnik RM, Greenfield E, Atkinson JS. Filling root canals with files. Radiographic evaluation of 304 cases. *NY State Dent J* 1972; **38**: 154–157.
  14. Kerekes K, Tronstad L. Long-term results of endodontic treatment performed with a standardized technique. *J Endod* 1979; **5**: 83–90.
  15. Molyvdas I, Lambrianidis T, Zervas P, Veis A. Clinical study on the prognosis of endodontic treatment of teeth with broken endodontic instruments. *Stoma* 1992; **20**: 63.
  16. Spili P, Parashos P, Messer HH. The impact of instrument fracture on outcome of endodontic treatment. *J Endod* 2005; **31**: 845–850.
  17. Saunders JL, Eleazer PD, Zhang P, Michalek S. Effect of a separated instrument on bacterial penetration of obturated root canals. *J Endod* 2004; **30**: 177–179.

# 100% tight!

## Rebilda®

### Coronal build-up system! Rebilda DC and Rebilda Post

A tight seal guarantees your endodontic success. Rebilda DC and Rebilda Post make a marginally tight post-and-core mono-block. Post cementation and core build-up in one go!

## VOCO

creative in research

P.O. Box 767 · 27457 Cuxhaven · Germany · Tel. +49 4721 719-0 · www.voco.com