

Permanent mimic musculature and nerve damage caused by sodium hypochlorite: a case report

Matthias Pelka, DMD,^a and Anselm Petschelt, DMD,^b Erlangen, Germany

Sodium hypochlorite is often used as an irrigation solution during routine endodontic treatment. Before recementation of a post-retained crown on the upper left lateral incisor, the root canal was irrigated with sodium hypochlorite. There was no root filling in the root canal, and the apex was open after an earlier apicoectomy. Sudden pain with swelling of the left face side occurred during root canal rinsing. Three years later, a paraesthesia still remained in the affected region and a paralysis of some mimic muscles in this region was observed. There were no signs of improvement. (*Oral Surg Oral Med Oral Pathol Oral Radiol Endod* 2008;106:e80-e83)

Sodium hypochlorite (NaOCl) in different concentrations is the irrigation solution most widely used by endodontists.¹⁻⁴ It dissolves proteins. Used in combination with citric acid, chlorine gas will be released.⁵ Sodium hypochlorite is effective against endodontic microorganisms organized in a biofilm.⁶ However, owing to the release of chlorine gas, it is extremely toxic to vital tissues,⁷⁻⁹ causing hemolysis, ulceration, inhibition of neutrophil migration, damage to endothelial and fibroblast cells, facial nerve weakness, and necrosis after extrusion during root canal treatment.^{10,11} We present a case in which NaOCl was accidentally injected beyond the root apex into the mimic muscular system and caused permanent anesthesia and damage of mimic muscle motor innervations, which did not show any signs of improvement 3 years later.

CASE REPORTS

A 54-year-old woman with penicillin allergy and hypothyroidism visited a dental polyclinic in 2004 for consultation about the possibility of implants in the upper and the lower left jaw. From the clinical examination, the upper left lateral incisor lost its post-retained crown. The radiographic picture showed that the region apical of the post was empty and the apical foramen was open, and the apical area showed a distinct apical translucency (Fig. 1). Prior to recementation of the crown the dentist rinsed the root canal with 3% NaOCl and 0.2% chlorhexidine digluconate (CHX). During rinsing with NaOCl a sudden pain and a left-side suborbital swelling occurred. The dentist administered local anesthesia and completed the irrigation with the CHX solution. The patient was

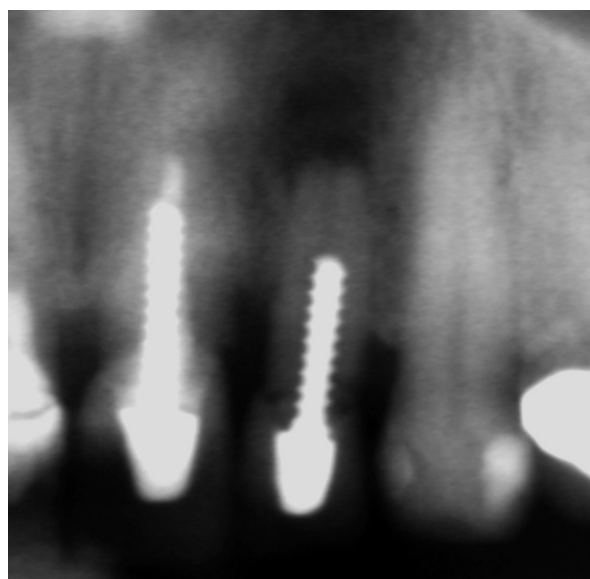


Fig. 1. Detail out of an orthopantomogram showing tooth 22 directly before the NaOCl accident. The space between pin and root apex is empty. The apical translucency shows a typical situation after surgical root resection.

given a cold compress, antibiotics, and analgesics. Pain and swelling worsened significantly over the next hours and the patient visited her general dental dentist for further medical care. On examination there was a firm left facial swelling which extended from below the border of the mandible up to the left eye (Fig. 2). Infraorbitally and in the region of the upper left lip up to the left lip corner, there was altered sensation. This is the area of the left infraorbital nerve. In addition the buccal branch of the facial nerve was affected. This resulted in a distinct loss of upper lip and cheek function (the corner of the mouth could not be pulled up by the mimic musculature). Mouth opening was limited to 20 mm. Intraorally there was no necrosis in the apical region of the tooth. Pain and swelling remained for 1 week, and the patient felt ill for this period. On review by the general dentist 1

Operative Dentistry and Periodontology, Dental Clinic 1, University of Erlangen-Nuremberg.

^aAssociate Professor.

^bProfessor and Chair.

Received for publication Apr 11, 2008; accepted for publication May 2, 2008.

1079-2104/\$ - see front matter

© 2008 Mosby, Inc. All rights reserved.

doi:10.1016/j.tripleo.2008.05.003

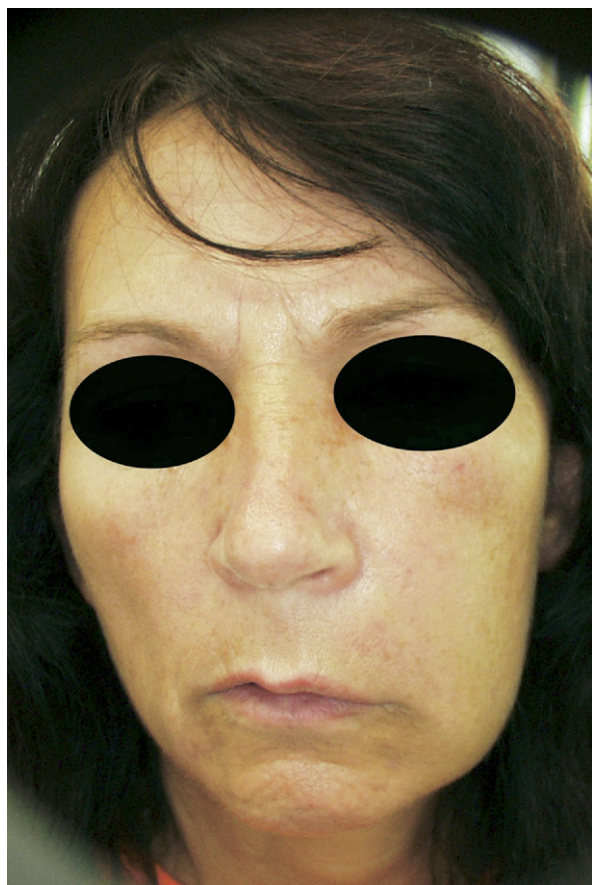

Fig. 2. The day after the accident. The left face side shows swelling from infraorbital to mandible. Only slight hematoma could be seen.

month later, the swelling had almost resolved, mouth opening was improved, and the patient was free of pain. On her own request the patient went to a neurologist because of persisting hyposensitivity and motor restriction. The neurologist found a paresthesia of the left facial nerve branch 3 and 4 with a nonsymmetric soft palate arch, an asymmetric mouth, and a hypotrophic left facial mimic musculature. The sensible arch of the trigeminal nerve was also altered infraorbitally on the left face side. The infraorbital nerve paresthesia was unchanged, and there was no improvement of the buccal branch facial nerve weakness.

The patient filed legal claims against the dental polyclinic. Three years later our clinic got involved in the complaint processing and we were requested, by the court, to examine the patient and provide a written testimony to the court. The main problem in the case was that the patient attended the dental polyclinic for consultation only and there was no informed consent about a root canal treatment with possible negative side effects.

During our examination in 2007—3 years after the NaOCl accident—we found new prosthetic implant rehabilitation replacing the upper front teeth, and the lateral left incisor was

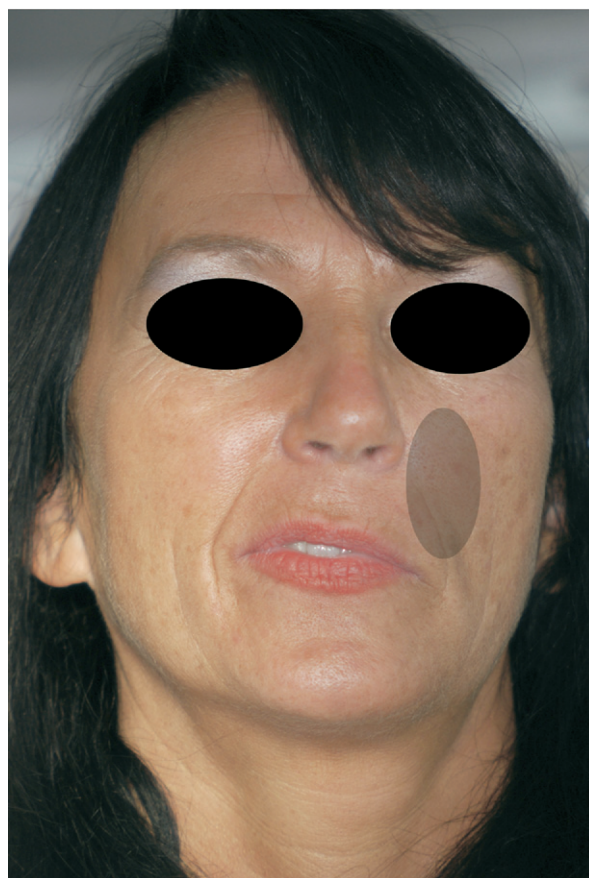

Fig. 3. Three years after the NaOCl accident. The weakness of the mimic musculature of the left face side is clearly visible. Trying to laugh leads to a hanging left lip corner owing to the weakness of the motor innervation by the facial nerve. In the gray-marked area there is a permanent hypoesthesia.

extracted and replaced by a pontic attached to implants at both middle front teeth. Mouth opening was unhindered up to 40 mm. We found in the upper left infraorbital region a reduced sensitivity in the area marked in Fig. 3. We asked the patient to smile and found that the left corner of her mouth was not pulled up by the mimic musculature (Fig. 3). The patient reported that these problems showed only slight improvement shortly after the accident up to one year. During the last two years no further improvement was observed. The problems with the mimic musculature in the region of the upper left lip side and the left lip corner led to some problems during drinking, and the patient noticed some involuntarily uncontrolled flow of saliva. These negative long-term effects of the NaOCl accident showed no signs of improvement, although the patient tried to train the mimic musculature every day.

DISCUSSION

Sodium hypochlorite is an effective endodontic irrigation solution used in different concentrations, rang-

ing from 0.5% to 6%.^{11,12} Sodium hypochlorite is able to disrupt the endodontic biofilm¹³ and therefore is the preferred disinfectant within the root canal system. Sodium hypochlorite is an extremely tissue-cytotoxic chemical solution. Heling et al.¹⁴ reported that NaOCl in concentrations above 0.01% was lethal to fibroblasts in vitro. When it comes in contact with vital tissue, it causes hemolysis and ulceration, inhibits neutrophil migration, and damages endothelial and fibroblast cells.⁹ The toxic effects of NaOCl occur because of its alkalinity (pH 10.8-12.9) and hypertonicity, which causes injury predominantly by oxidation of proteins and lipid membranes.^{15,16}

The acute problems—sudden pain during root canal rinsing, the extensive swelling of the left face side, and the adverse effects to nerves and musculature—described above are typical for sodium hypochlorite and have been repeatedly published in the literature during the last 30 years.^{7,10,11,17} The immediate sequel of these accidents includes severe sudden excruciating pain of 2-5 min duration, probably related to tissue destruction and distension, as well as immediate swelling of the tissue in the area. Several days of increasing edema and ecchymosis occur, accompanied by tissue necrosis and paresthesia, in addition to secondary infections and possible obstruction of the airway from edema in some cases.^{18,19}

The first endodontic case was published in 1974, reporting accidentally injected sodium hypochlorite beyond the root apex.²⁰ There are few cases showing a weakness of the facial nerve branch due to extravasation of NaOCl into soft tissue. These cases reported a complete resolution of the facial weakness within approximately 6 months after the incident.^{10,26} Only 1 case reported long-term paraesthesia—for 6 months—after inadvertently injected NaOCl.²¹ The present case is the first showing a permanent facial nerve weakness after inadvertent injection of NaOCl.

The clinical manifestations in the present case were consistent with severe soft tissue damage due to a sudden chemical burn, following extrusion of NaOCl into the connective tissues. The apical anatomy of this tooth was not normal (Fig. 1), so presumably the combination of periapical bone destruction due to earlier surgical root resection, unfilled root canal, and high pressure during irrigation led to the easy entry of NaOCl into the soft tissues of the left face side. The following irrigation with CHX was not able to eliminate or neutralize the NaOCl. Several authors have shown that the combination of “open apex” with a radiographically visible apical translucency is highly correlated with the risk for inadvertent injection of irrigation solution beyond the root apex.^{9,11,16,17,22,23}

The management of the complications related to NaOCl incidents have been described previously in detail.^{11,24} As an alternative irrigant for rinsing root canals during endodontic treatment a 0.1%-2% CHX solution could be used. The antimicrobial effect of CHX is well known, and adverse side effects of CHX during endodontic treatment have not been reported.²⁵

CONCLUSIONS

The present case showed that NaOCl—inadvertently injected beyond the apex—is able to produce permanent facial and trigeminal nerve weakness.

Because of this fact and the number of reported cases, it is very important to include the adverse reactions of NaOCl into the normal written information provided to the patient before endodontic treatment. Without such written consent, NaOCl should not be used as an irrigation solution during endodontic therapy.

In endodontic cases with a widely open apical foramen in combination with an apical translucency, CHX may be a better alternative than NaOCl for irrigation. If NaOCl is used despite this recommendation, it should be done carefully with meticulous length control.

REFERENCES

1. European Society of Endodontology. Quality guidelines for endodontic treatment: consensus report of the European Society of Endodontology. *Int Endod J* 2006;39:921-30.
2. Grandini S, Balleri P, Ferrari M. Evaluation of Glyde File Prep in combination with sodium hypochlorite as a root canal irrigant. *J Endod* 2002;28:300-3.
3. Averbach RE, Kleier DJ. Clinical update on root canal disinfection. *Compend Contin Educ Dent* 2006;27:284-9.
4. Regan JD, Fleury AA. Irrigants in nonsurgical endodontic treatment. *J Ir Dent Assoc* 2006;52:84-92.
5. Baumgartner JC, Ibay AC. The chemical reactions of irrigants used for root canal debridement. *J Endod* 1987;13:47-51.
6. Ercan E, Ozekinci T, Atakul F, Gul K. Antibacterial activity of 2% chlorhexidine gluconate and 5.25% sodium hypochlorite in infected root canal: in vivo study. *J Endod* 2004;30:84-7.
7. Zehnder M, Kosicki D, Luder H, Sener B, Waltimo T. Tissue-dissolving capacity and antibacterial effect of buffered and unbuffered hypochlorite solutions. *Oral Surg Oral Med Oral Pathol Oral Radiol Endod* 2002;94:756-62.
8. Lamers AC, van Mullem PJ, Simon M. Tissue reactions to sodium hypochlorite and iodine potassium iodide under clinical conditions in monkey teeth. *J Endod* 1980;6:788-92.
9. Gernhardt CR, Eppendorf K, Kozlowski A, Brandt M. Toxicity of concentrated sodium hypochlorite used as an endodontic irrigant. *Int Endod J* 2004;37:272-80.
10. Witton R, Henthorn K, Ethunandan M, Harmer S, Brennan PA. Neurological complications following extrusion of sodium hypochlorite solution during root canal treatment. *Int Endod J* 2005;38:843-8.
11. Hülsman M, Hahn W. Complications during root canal irrigation—literature review and case reports. *Int Endod J* 2000;33:186-93.
12. Zehnder M. Root canal irrigants. *J Endod* 2006;32:389-98.
13. Clegg MS, Vertucci FJ, Walker C, Belanger M, Britto LR. The

- effect of exposure to irrigant solutions on apical dentin biofilms in vitro. *J Endod* 2006;32:434-7.
14. Heling I, Rotstein I, Dinur T, Szwec-Levine Y, Steinberg D. Bactericidal and cytotoxic effects of sodium hypochlorite and sodium dichloroisocyanurate solutions in vitro. *J Endod* 2001;27:278-80.
 15. Kaufman AY, Keila S. Hypersensitivity to sodium hypochlorite. *J Endod* 1989;15:224-6.
 16. Serper A, Ozbek M, Calt S. Accidental sodium hypochlorite-induced skin injury during endodontic treatment. *J Endod* 2004;30:180-1.
 17. Bowden JR, Ethunandan M, Brennan PA. Life-threatening airway obstruction secondary to hypochlorite extrusion during root canal treatment. *Oral Surg Oral Med Oral Pathol Oral Radiol Endod* 2006;101:402-4.
 18. Gatot A, Arbelle J, Leiberman A, Yanai-Inbar I. Effects of sodium hypochlorite on soft tissues after its inadvertent injection beyond the root apex. *J Endod* 1991;17:573-4.
 19. Sabala CL, Powell SE. Sodium hypochlorite injection into periapical tissues. *J Endod* 1989;15:490-2.
 20. Becker GL, Cohen S, Borer R. The sequelae of accidentally injecting sodium hypochlorite beyond the root apex. Report of a case. *Oral Surg Oral Med Oral Pathol Oral Radiol Endod* 1974;38:633-8.
 21. Reeh ES, Messer HH. Long-term paresthesia following inadvertent forcing of sodium hypochlorite through perforation in maxillary incisor. *Endod Dent Traumatol* 1989;5:200-3.
 22. Mehra P, Clancy C, Wu J. Formation of a facial hematoma during endodontic therapy. *J Am Dent Assoc* 2000;131:67-71.
 23. Westbury B. Severe tissue damage. *Br Dent J* 2005;199:443.
 24. Pontes F, Pontes H, Adachi P, Rodini C, Almeida D, Pinto D Jr. Gingival and bone necrosis caused by accidental sodium hypochlorite injection instead of anaesthetic solution. *Int Endod J* 2008;41:267-70.
 25. Siqueira JF Jr., Paiva SS, Rocas IN. Reduction in the cultivable bacterial populations in infected root canals by a chlorhexidine-based antimicrobial protocol. *J Endod* 2007;33:541-7.
 26. Gallas-Torreira MM, Reboiras-Lopez MD, Garcia-Garcia A, Gandara-Rey J. Mandibular nerve paresthesia caused by endodontic treatment. *Med Oral* 2003;8:299-303.

Reprint requests:

Matthias Pelka, DMD
University Erlangen-Nuremberg
Dental Clinic 1—Restorative Dentistry and Periodontology
Glückstrasse 11
D-91054 Erlangen
pelka@dent.uni-erlangen.de