

## Apical transportation created using three different patency instruments

J. A. Gonzalez Sanchez, F. Duran-Sindreu, M. Albuquerque Matos, T. Garcia Carabaño, M. Mercade Bellido, S. Morello Castro & M. Roig Cayón

Department of Endodontics, Universitat Internacional de Catalunya, Barcelona, Spain

### Abstract

**Gonzalez Sanchez JA, Duran-Sindreu F, Albuquerque Matos M, Garcia Carabaño T, Mercade Bellido M, Morello Castro S, Roig Cayón M.** Apical transportation created using three different patency instruments. *International Endodontic Journal*, 43, 560–564, 2010.

**Aim** To evaluate root canal transportation at the major foramen through the use of stainless steel size 08 K-Flex files, size 10 reamers, and XF finger spreaders when used as patency instruments.

**Methodology** One hundred and two mesiobuccal canals of maxillary and mandibular first molars were randomly divided into three groups (34 canals each). Size 08 stainless steel K-Flex files, size 10 stainless steel reamers and stainless steel XF finger spreaders were used as patency instruments in groups A, B and C respectively. The major foramen was photographed before and after instrumentation. The images were

superimposed and then evaluated using Photoshop® to determine the frequency of apical transportation. The statistic analysis was performed using  $\chi^2$  test.

**Results** Transportation was detected in 22% of the specimens; 9% in group A, 12% in group B and 44% in group C. Significant differences were observed between groups A and C ( $P = 0.0025$ ) and between groups B and C ( $P = 0.0069$ ), but not between groups A and B ( $P = 1.00$ ).

**Conclusions** No transportation was found in the majority of the samples when size 08 K-Flex files and size 10 stainless steel reamers were used. The XF finger spreaders, when used to maintain apical patency, caused the greatest transportation of the major foramen.

**Keywords:** apical transportation, patency file, root canal preparation.

Received 21 September 2009; accepted 9 February 2010

### Introduction

The accumulation of debris during instrumentation of root canals may block access to the apical third (Buchanan 1991, Arias *et al.* 2009) and increase the possibility of apical transportation, ledges and perforations (Buchanan 1991, Cailleateau & Mullaney 1997). Patency filing has the potential to prevent debris accumulation in the apical portion of the canal, preserve the original foramen anatomy (Buchanan 1989, Cailleateau & Mullaney 1997), and allow access

for the irrigating solution to the apical region of the root canal (Castellucci 2004). Maintaining the canal patent in the apical region may prevent ledge formation, transportation, and apical perforation (Buchanan 1989).

Patency can be achieved with a small file (08 or 10), which is passively moved 0.5–1 mm through the apical constriction. However, the use of this technique is controversial because of potential biological effects such as periapical tissue damage (Holland *et al.* 2005), postoperative pain (Gutierrez *et al.* 1999) and damage to the apical foramen (Goldberg & Massone 2002).

Gutierrez *et al.* (1999) observed cementum fractures and dentinal chips at the apex after achieving patency with a size 15 K-file. According to Goldberg & Massone

Correspondence: Miguel Roig, Dentistry Faculty, Universitat Internacional de Catalunya, C/Josep Trueta s/n. 08195, Sant Cugat del Vallès, Spain (Tel.: + 34 504 2000; fax: +34 504 2031; e-mail: mroig@csc.uic.es).

(2002) when a size 20 file was used as a patency file, the possibility of transporting the apical foramen increased to 57% (17 of the 30 specimens analysed).

This study aimed to evaluate whether the use of a size 08 K-Flex file, a size 10 reamer, and an XF finger spreader as patency instruments transported the major foramen.

## Material and methods

One hundred and two mesiobuccal canals of maxillary and mandibular first molars with non-merged roots and closed apices were selected. The teeth were cleaned with 4.2% sodium hypochlorite (NaOCl) solution (Lejía Conejo, Henckel Ibérica, Spain) for 4 h. They were then washed with tap water and stored in saline solution for 1 week at room temperature. The mesial roots were removed with a carborundum disc and then washed to eliminate debris.

The estimated working length (WL) was determined by subtracting 1 mm from the total length of the tooth, measured by superimposing a size 10 K-file (Kerr USA, Romulus, MI, USA) over the tooth.

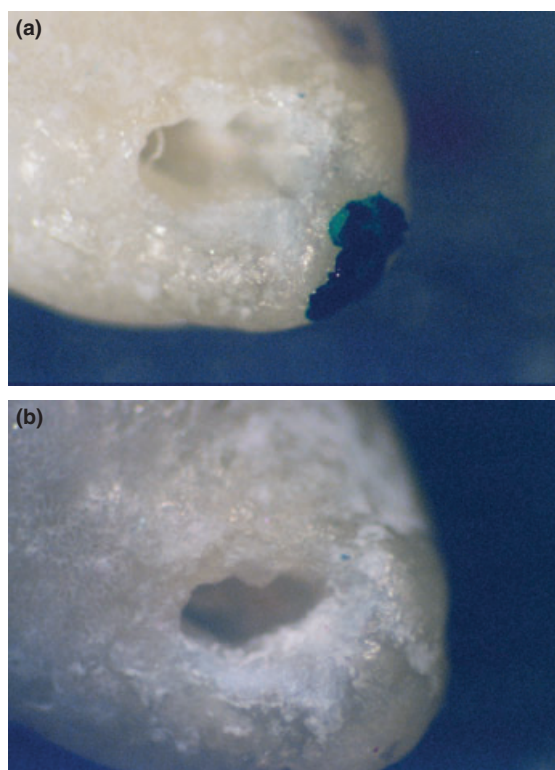
Each root was placed into a resin block, leaving the apical three mm of the root and the access cavity exposed to allow instrumentation, irrigation and patency filing. The resin block was adjusted with precision on an acrylic base under a stereomicroscope, to allow an exact reproduction of the major foramen position. The major foramen was then photographed under magnification using a 35-mm camera coupled to the stereomicroscope (pre-instrumentation photograph, Fig. 1a).

All root canals were instrumented as described in Table 1, and specimens were divided randomly into three experimental groups (34 canals each): A, B and C. Group A: size 08 stainless steel K-Flex file (Kerr, Turin, Italy) was used three times as a patency instrument, as described in Table 1. The patency instrument was passively introduced into the root canal until the file tip protruded 1 mm through the major foramen.

Group B: size 10 reamer (Kerr) was used as patency instrument, as described in group A.

Group C: XF finger spreader (Kerr USA) was used as patency instrument, as described in groups A and B.

The true WL was established when using the patency instrument for the first time. The patency instrument was withdrawn until the tip of the file was seen level with the root surface at the major foramen under stereomicroscope control. This length was measured by adjusting the rubber stop in contact with the flat

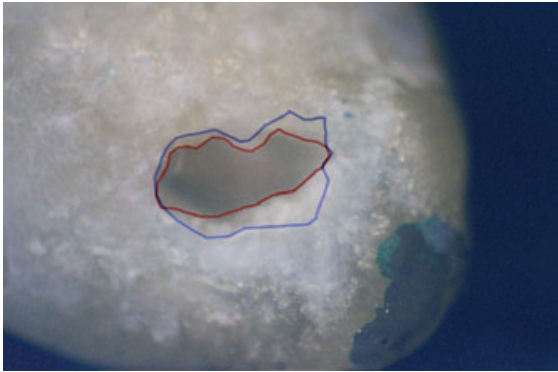


**Figure 1** (a) The apical foramen before instrumentation. (b) The apical foramen after instrumentation.

**Table 1** Crown-down sequence used to prepare the root canals

Step	Instrument	Part of the canal
1	Size 15 K-file	Estimated working length (WL)
2	Preflaring with Nos. 4, 3 and 2 Gates Glidden	Coronal third
3	Profile size 40, 0.06 taper	Coronal third
4	Profile size 35, 0.06 taper	Coronal third to middle third
5	Profile size 30, 0.06 taper	Middle third to apical third
6	Patency instrument	1 mm through the major foramen and establishment of true WL
7	Profile size 25, 0.06 taper	WL
8	Patency Instrument	1 mm through the major foramen
9	Profile size 30, 0.06 taper	WL
10	Patency instrument	1 mm through the major foramen

horizontal surface of the tooth. The distance between the file tip and the rubber stop was measured using a digital calliper to an accuracy of 0.1 mm. Then,



**Figure 2** Superimposed pictures using Photoshop (red: initial perimeter; blue: final perimeter).

0.5 mm was subtracted from this measurement and the resulting value was considered as the true WL.

Post-instrumentation digital images (Fig. 1b) of the major foramen were taken following an identical method to that used for pre-instrumentation images.

The digital images were transferred to a computer and post-instrumentation images were superimposed on the pre-instrumentation images to evaluate apical transportation (Fig. 1a,b). The photographs were transferred to Photoshop to outline the major foramen perimeter. Red was used to reveal the original major foramen perimeter, and blue the perimeter after instrumentation. By superimposing the two images, it was possible to establish whether there were variations in the initial and final apical perimeter or not (Fig. 2). The variation in the final perimeter was considered apical transportation.

Two previously calibrated individuals, blinded as to which patency instrument was used, marked together the perimeter of the major foramen. If the two individuals disagreed, a third previously calibrated individual was asked to make the final decision.

Chi square tests were used to determine significant differences in the frequency of apical transportation between the groups studied. To identify the source of these differences, the Chi-square test with Yates correction between the groups was applied.

**Table 2** Presence and absence of apical transportation

	Size 08 K-Flex	Size 10 reamer	XF finger spreader
Presence	8.8% (3)	11.8% (4)	44.1% (15)
Absence	91.2% (31)	88.2% (30)	55.9% (19)
Total	100% (34)	100% (34)	100% (34)

## Results

Of the 102 samples studied, 22 teeth (22%) had apical transportation (Table 2). Transportation was observed in 9% samples in group A, 12% in group B, and 44% in group C. After the  $\chi^2$  analyses, significant differences were found amongst the groups ( $P = 0.0004$ ). Significant differences were found between groups A and C after instrumentation ( $P = 0.0025$ ), and between groups B and C ( $P = 0.0069$ ), but no differences were found between groups A and B ( $P = 1.00$ ).

## Discussion

This study aimed to evaluate the effect of patency instrumentation on the major foramen. To this end, a similar protocol to that of Goldberg & Massone (2002) was used to determine transportation of the major foramen. In the present study, apical patency was achieved following the technique described by Buchanan (1989), without pre-bending the instrument and by moving it passively through the major foramen by 1 mm. The patency file was used only when the coronal two thirds of the canal had been prepared. This allowed the file to easily reach the major foramen and avoid changes in the WL (Camargo *et al.* 2009).

During instrumentation, dentine chips may sometimes accidentally be compacted into the apical portion of the root canal and form a dentine plug resulting in blockage of the apical foramen (Al-Omari & Dummer 1995). Hence, the aim of establishing apical patency is to maintain the apical portion of the root canal free of debris (mechanical goal) (Tsesis *et al.* 2008). In addition, it is important that after instrumentation the major foramen is both patent and clean (biological goal) (Tsesis *et al.* 2008).

The use of the patency file technique is controversial because of biological consequences such as over-enlargement of the major foramen (Goldberg & Massone 2002) and damage to the periapical tissues (Ricucci 1998). By contrast, Tsesis *et al.* (2008) observed no significant differences after using a patency file in the degree of apical transportation, showing a tendency for WL to be maintained when a patency file was used (Tsesis *et al.* 2008).

Some authors have suggested that in order to increase the accuracy of electronic apex locator readings, the files should protrude slightly from the major foramen and then be retracted (Plotino *et al.* 2006); hence, apical patency should be maintained. The incidence of post-endodontic pain was lower in teeth

with non-vital pulps when apical patency was maintained and apical patency did not seem to be related to post-endodontic pain in teeth with vital pulps (Arias et al. 2009). Siqueira et al. (2002) reported that this procedure had no influence on the incidence of flare-ups, even when patency file was used by inexperienced practitioners. Torabinejad et al. (1988) noted that accidental over-extension of small files during WL determination had no significant effect on the frequency of post-endodontic pain. These studies suggest that over-extension of small files does not necessarily cause post-endodontic pain (Torabinejad et al. 1988, Siqueira et al. 2002, Arias et al. 2009). One possible explanation is that the patency file is not as harmful to periapical tissues as some believe (Arias et al. 2009). However, the clinician should be aware of the risk of using large instruments as patency files, as this procedure can result not only in severe periapical tissue injury, but can also destroy an apical stop, as well as extrude a large amount of infected debris and material during filling of the root canal system (Torabinejad et al. 1988, Siqueira et al. 2002), which could increase the incidence of post-endodontic pain and jeopardize the outcome of the root canal treatment (Siqueira et al. 2002, Arias et al. 2009). It has also been reported that root canals with apical patency had less leakage after filling compared with those without patency filing (Monsef et al. 1997).

In this study, a size 08 K-Flex file was chosen, as Goldberg & Massone (2002) observed transportation of the major foramen using size 10, 15 and 20 K-files. Goldberg & Massone (2002) observed that if stainless steel size 20 K-file was used as a patency file, the probability of transportation of the major foramen was 60%. A size 10 reamer was selected instead of a size 08, as the reamer mass is less than that of a K-file of the same size, because of its fewer flutes per millimetre (Stock et al. 1995). An XF finger spreader was used, as it is the smallest available. This spreader has a 0.16-mm diameter tip, 1.4% taper and a non-cutting tip. Initially, the spreader was expected to cause less transportation than the other instruments, given that it has less taper than a K-file and has no flutes. However, this did not materialise, probably because this instrument has a greater mass and is stiffer, because of its circular geometry, than the other two instruments.

The results of this study differed from those of Goldberg & Massone (2002), who observed that apical transportation started with the use of a size 10 K-file in 33% of the specimens, and concluded that a smaller file should be chosen when using the patency technique.

This difference could be because of the reduced mass of a size 08 K-file or a size 10 reamer compared with that of a size 10 K-file and/or because a reamer cuts more effectively using rotary motion (Stock et al. 1995), and in the present study the patency instrument was passively introduced until the tip protruded 1 mm through the major foramen using a push-pull motion.

The patency file should be moved passively through the major foramen without widening it (Buchanan 1989). But, as the major foramen usually emerges laterally from the root apex (Kuttler 1955), the patency file may alter the apical anatomy by acting on one wall of the major foramen (Tsesis et al. 2008). In groups A and B, the major foramen was transported by 9% and 12% respectively. In these cases, a minor transportation towards the outer aspect of the major foramen was observed.

## Conclusions

No transportation was found in the majority of the samples when size 08 stainless steel K-Flex files and size 10 stainless steel reamers were used. XF finger spreaders, when used to maintain apical patency, caused the greatest transportation of the major foramen.

## References

- Al-Omari MA, Dummer PM (1995) Canal blockage and debris extrusion with eight preparation techniques. *Journal of Endodontics* **21**, 154–8.
- Arias A, Azabal M, Hidalgo JJ, de la Macorra JC (2009) Relationship between postendodontic pain, tooth diagnostic factors, and apical patency. *Journal of Endodontics* **35**, 189–92.
- Buchanan LS (1989) Management of the curved root canal. *Journal of California Dental Association* **17**, 18–25, 27.
- Buchanan LS (1991) Cleaning and shaping the root canal system. In: Cohen S, Burns RC, eds. *Pathways of the Pulp*, 5th edn. St Louis: CV Mosby, pp. 166–92.
- Cailleateau JG, Mullaney TP (1997) Prevalence of teaching apical patency and various instrumentation and obturation techniques in United States dental schools. *Journal of Endodontics* **23**, 394–6.
- Camargo EJ, Zapata RO, Medeiros PL et al. (2009) Influence of preflaring on the accuracy of length determination with four electronic apex locators. *Journal of Endodontics* **35**, 1300–2.
- Castellucci A (2004) *Endodontics*. Florence: Edizioni Odontoiatriche il Tridente, pp. 396–437.
- Goldberg F, Massone EJ (2002) Patency file and apical transportation: an *in vitro* study. *Journal of Endodontics* **28**, 510–1.

- Gutierrez JH, Brizuela C, Villota E (1999) Human teeth with periapical pathosis after overinstrumentation and overfilling of the root canals: a scanning electron microscopic study. *International Endodontic Journal* **32**, 40–8.
- Holland R, Sant'Anna Junior A, Souza V et al. (2005) Influence of apical patency and filling material on healing process of dogs' teeth with vital pulp after root canal therapy. *Brazilian Dental Journal* **16**, 9–16.
- Kuttler Y (1955) Microscopic investigation of root apices. *Journal of the American Dental Association* **50**, 544–52.
- Monsef M, Hamedzadeh K, Soluti A (1997) Effect of apical patency on the apical seal of obturated canals. *Journal of Endodontics* **23**, 253.
- Plotino G, Grande NM, Brigante L, Lesti B, Somma F (2006) *Ex vivo* accuracy of three electronic apex locators: root ZX, Elements diagnostic unit and apex locator and propex. *International Endodontic Journal* **39**, 408–14.
- Ricucci D (1998) Apical limit of the root canal instrumentation and obturation, part I Literature review. *International Endodontic Journal* **31**, 384–93.
- Siqueira JF, Rocas IN, Favieri A et al. (2002) Incidence of postoperative pain after intracanal procedures based on antimicrobial strategy. *Journal of Endodontics* **28**, 457–60.
- Stock CJR, Gulabivala K, Walker RT, Goodman JR (1995) *Colour Atlas and Text of Endodontics*, 2nd edn. London: Mosby-Wolf, pp. 97–144.
- Torabinejad M, Kettering JD, McGraw JC, Cummings RR, Dwyer TG, Tobias TS (1988) Factors associated with endodontic interappointment emergencies of teeth with necrotic pulps. *Journal of Endodontics* **14**, 261–6.
- Tsesis I, Amdor B, Tamse A, Kfir A (2008) The effect of maintaining apical patency on canal transportation. *International Endodontic Journal* **41**, 431–5.