
Severe tissue necrosis following intra-arterial injection of endodontic calcium hydroxide: a case series

Sanjay Sharma, MBBS, BDS, FDS, FRCS (OMFS),^a Robert Hackett, BDS, MFDS,^b
Roger Webb, MBBS, BDS, FDS, FRCS (OMFS),^c
David Macpherson, MBBS, BDS, FDS, FRCS (OMFS),^d and
Alan Wilson, MBBS, BDS, FDS, FRCS (OMFS),^e West Sussex
UK ROYAL WEST SUSSEX HOSPITALS NHS TRUST

We present 2 cases of intra-arterial injection of endodontic calcium hydroxide via the root canal system of molar teeth. Nonsetting calcium hydroxide paste was used as a temporary dressing during endodontic treatment and in both cases delivered via an injectable syringe technique. Retrograde flow of the calcium hydroxide occurred along the artery until its origin where orthograde flow continued to the capillary bed. Case 1 demonstrates calcium hydroxide injected into the distal root canal of a lower second molar resulting in its distribution to the external carotid bed and case 2 demonstrates calcium hydroxide injected into the palatal root of an upper second molar with flow into the infraorbital artery. In both cases this resulted in severe clinical signs and symptoms ending in tissue necrosis. Long-term sequelae included scarring, deformity, and chronic pain. This case series illustrates the high toxicity of calcium hydroxide when displaced into vessels and soft tissues. Caution should be exercised when using injectable systems for endodontic calcium hydroxide. (*Oral Surg Oral Med Oral Pathol Oral Radiol Endod* 2008;105:666-9)

Endodontic therapy often requires the use of temporary dressing materials before the placement of a permanent root canal filling. Nonsetting calcium hydroxide paste is commonly used for this purpose and is often delivered via an injectable syringe system. Previous reports have described the deleterious effects of displaced calcium hydroxide on the inferior alveolar nerve when extruded through the apices of lower molar teeth.¹ Here we describe the severe effects in 2 patients where the calcium hydroxide was displaced into an artery adjacent to the molar root apices.

CASE 1

A previously fit and well 50-year-old female was referred acutely to our maxillofacial unit by a local dental practitioner. She had undergone the first stage of endodontic treatment to a lower left second molar. Following local anesthesia with a left inferior dental block using a standard solution of lignocaine 2% with

adrenaline 1:80,000, the procedure progressed uneventfully. Thirty minutes later, calcium hydroxide paste (QED Calcium hydroxide, Nordiska Dental) was injected, using the manufacturer's syringe, into the distal root canal. Immediately following this, bleeding was noted in the access chamber and the patient experienced severe ipsilateral facial pain radiating to the orbit and scalp, blurring of vision, nausea, and trismus. A purple discoloration rapidly developed over the left cheek and temple area together with a progressive developing ipsilateral facial weakness.

The patient was transferred via ambulance to the Emergency Department where she was distressed, but had normal observations. The purplish discoloration was present in the territory of the maxillary and superficial temporal arteries but the skin in the mental region and all oral mucosal surfaces were spared (Fig. 1). Trismus of 1 centimetre was noted together with a House-Brackmann grade III facial nerve palsy. Complete anesthesia of the inferior alveolar nerve was also demonstrated. Remaining physical examination including ophthalmic review was unremarkable. A dental pantomogram clearly demonstrated opaque material within the inferior alveolar canal creating an angiogram effect within the inferior alveolar vessels (Fig. 2).

The patient was admitted, commenced on intravenous fluid, aspirin (300 mg), and methylprednisolone (125 mg). Morphine, diclofenac sodium, and amitriptyline were given for analgesia and anxiolysis. Vascular and radiological consultations considered further imag-

Royal West Sussex Hospitals NHS Trust, Spitalfields Lane, Chichester, West Sussex, UK

^aSpecialist Registrar, St Richards Hospital, Chichester, West Sussex.

^bSenior House Officer, St Richards Hospital, Chichester, West Sussex.

^cSpecialist Registrar, St Richards Hospital, Chichester, West Sussex.

^dConsultant, St Richards Hospital, Chichester, West Sussex.

^eConsultant, St Richards Hospital, Chichester, West Sussex.

Received for publication Oct 30, 2007; accepted for publication Nov 21, 2007.

1079-2104/\$ - see front matter

© 2008 Mosby, Inc. All rights reserved.

doi:10.1016/j.tripleo.2007.11.026

ing including computed tomography (CT), magnetic resonance imaging (MRI) and angiography but all were rejected in view of risk benefit ratio. The use of thrombolysis and prostacyclin infusions were thought to be of limited value.

The patient was discharged 3 days later. The facial

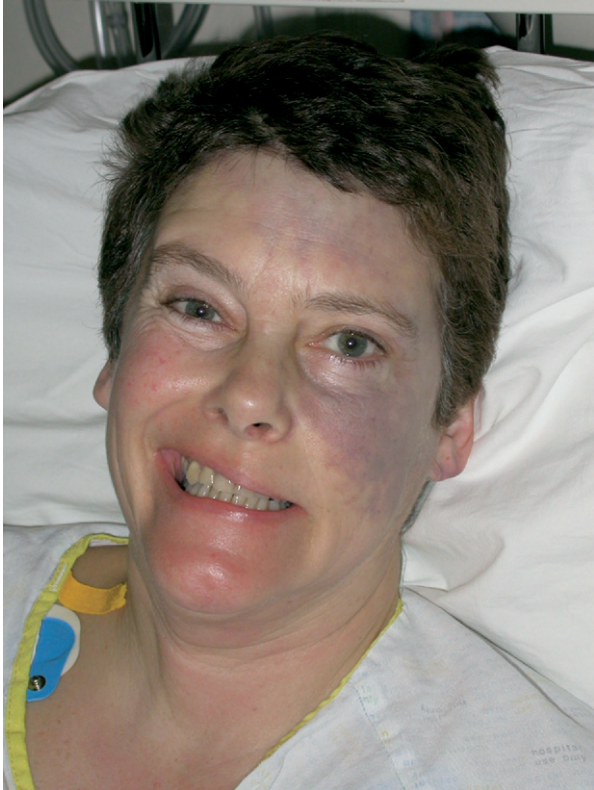

Fig. 1. Appearance on admission. Note the distribution of the skin discoloration and left-sided facial nerve weakness.

nerve weakness and trismus had improved and analgesia requirements reduced. The affected skin remained ischemic but with no evidence of necrosis. At review a week later, further evidence of regional ischemic injury was noted with large ulcerated areas present in the mucosa of the ipsilateral hard palate and upper buccal gingivae (Fig. 3). These were managed with chlorhexidine and benzydamine mouthwashes.

At 2 months, paresthesia in the inferior alveolar nerve was demonstrable and the majority of affected skin had recovered. However an exudative scab within the hair-bearing scalp required exploration and an 8 × 8 cm of full thickness area of necrotic skin was removed (Fig. 4). This area was left to heal by secondary intention, and reconstruction to replace hair-bearing scalp may be considered in the future.

CASE 2

A 55-year-old gentleman was undergoing routine endodontic treatment to the upper left second molar at his general dental practice. The root canals had been instrumented with hand files and nonsetting calcium hydroxide paste was injected into the palatal root canal. The patient immediately experienced a sharp, severe, well-localized pain in the left anterior maxillary region and left hard palate. The calcium hydroxide dressing was stopped and the dentist immediately irrigated the canal with 40 mL of normal saline. The patient attended the accident and emergency department later that day and on examination was found to have left infra-orbital swelling and bruising, tenderness over the anterior maxilla, and pallor of the ipsilateral hard palate (Fig. 5). There was anesthesia in the distribution of the infra-orbital nerve.

Plain radiographs revealed an arteriogram appearance with radiopaque material within the confines of

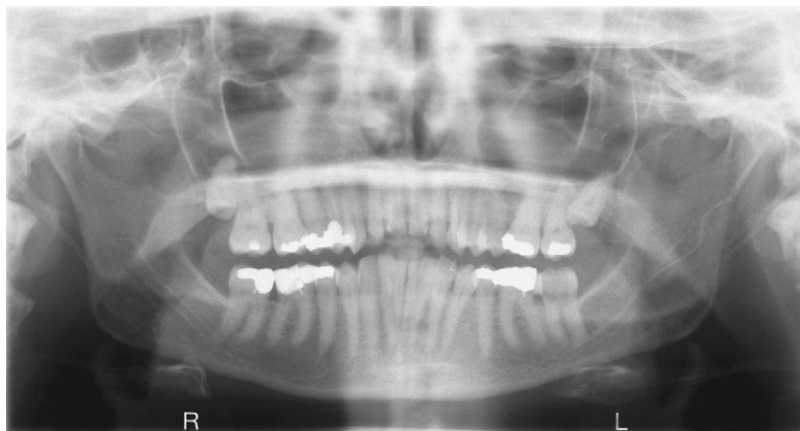

Fig. 2. Orthopantomogram showing radiopaque material in the left inferior alveolar canal.

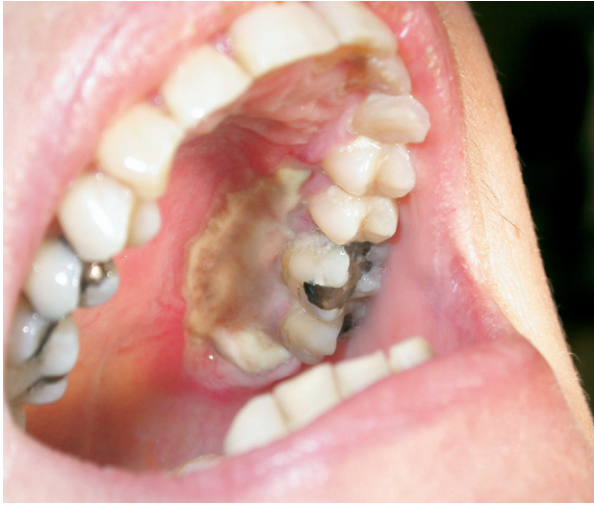

Fig. 3. Palatal ulceration at 2 weeks.

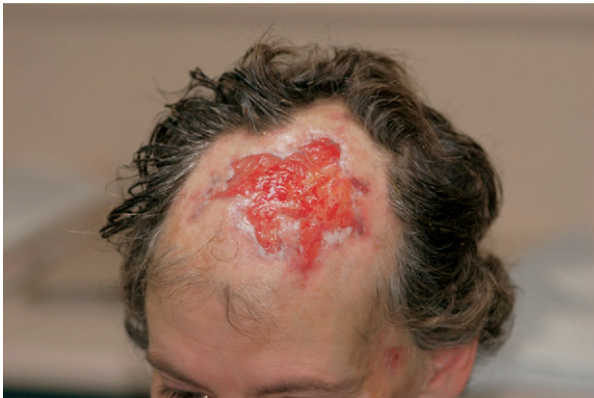

Fig. 4. Widespread loss of full thickness scalp following debridement.

the posterior superior alveolar artery and the infra-orbital artery. Foreign material could not be detected within the greater palatine artery despite the clinical appearances. A computerized tomography (CT) scan with 3-dimensional (3-D) reconstruction confirmed the distribution of the material (Fig. 6).

The patient was admitted and given methyl prednisolone, aspirin, low molecular weight heparin, and prophylactic antibiotics. The use of thrombolytic therapy and prostacyclin analogues was thought to be of limited value and therefore not used.

The patient was discharged after 48 hours and asked to continue with the aspirin and steroids for a further 5 days. At 1 week review the patient still experienced chronic pain in the left anterior maxillary region, which now showed increased bruising. The mucosa on the left hard palate was still pale and several areas of superficial

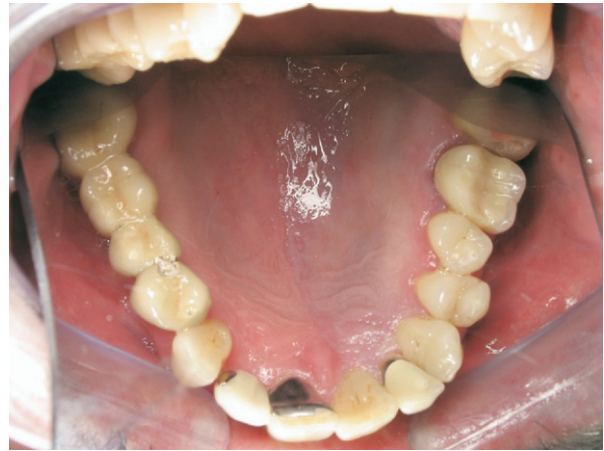

Fig. 5. Ipsilateral pallor of hard palate.

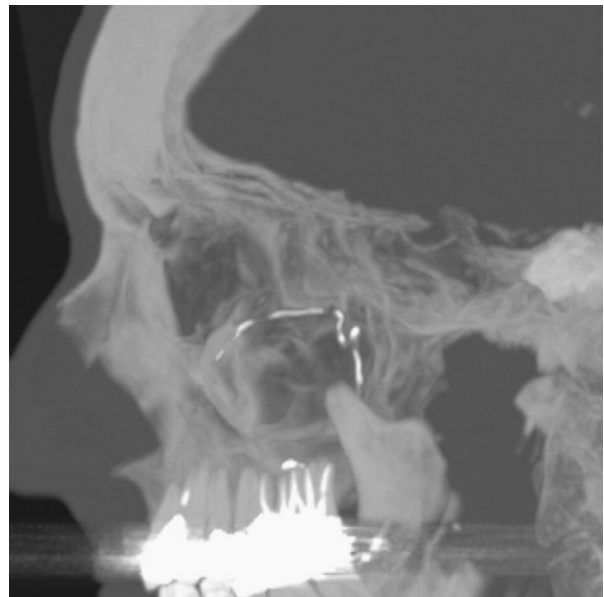


Fig. 6. 3-D CT reconstruction of intravascular course of calcium hydroxide (lateral view).

ulceration were noted along the palatal gingival margins.

At 1 month the ulceration had healed and sensation was beginning to return in the infra-orbital nerve distribution. However, the problem of chronic debilitating pain in the left maxilla still affects the patient and has probably been a trigger for his recently diagnosed reactionary depression.

DISCUSSION

Calcium hydroxide paste is able to induce intense inflammatory responses leading to necrotic and degen-

erative changes in animal models.^{2,3} The pH of most calcium hydroxide pastes is approximately 12. Exposure to blood results in crystalline precipitation due to the intensely differing pH values. Theoretically, it cannot be considered a totally biocompatible material.

These cases both demonstrate how a communication can be formed between the molar root apex and adjacent artery. Instrumentation may develop a traumatic communication to facilitate the passage of material into the artery. The syringe technique is then able to generate pressures higher than the intra-arterial pressure in order to get retrograde flow along the artery. Once material reaches its origin and is displaced into the stem artery the orthograde flow will carry the material distally. Both of these cases show evidence of tissue damage with areas of ischemia and tissue necrosis. Arterial obstruction alone is unlikely to be responsible for this phenomenon as the collateral circulation almost always able to compensate. We hypothesize that the necrosis must be due to calcium hydroxide reaching the capillary bed and causing a direct tissue toxicity. In Case 1 this occurred in the scalp, skin, and mucosa and in Case 2 the effect on the infra-orbital nerve and palatal mucosa was most obvious.

We treated our patients with aspirin, heparin, steroids, and prophylactic antibiotics. We feel that aspirin and heparin would be adequate to prevent propagation of existing thrombus. Steroid therapy would limit inflammatory damage and lessen neuronal injury, antral obstruction, and hence pain. Antibiotics were used to prevent infection of deep necrotic tissue. Thrombolysis and prostacyclin analogues have been tried previously. Lindgren et al.⁴ described a case of calcium hydroxide injected via the root of a lower second molar and into the maxillary artery bed causing necrosis of the earlobe and superficial necrosis of the cheek skin. They treated

the patient with a tissue plasminogen activator and a prostacyclin analogue. Using laser Doppler blood flow measurements they found no improvement in flow rates after treatment. This may be explained by the direct toxic effects of calcium hydroxide at the cellular level.

We have been able to highlight the dangers of calcium hydroxide when injected into root canals and have demonstrated the severe and long-lasting consequences. Caution should be exercised when using injectable systems for endodontic calcium hydroxide. Alternative dispensing routes should be used to prevent extra-radicular deposit of the calcium hydroxide slurry.

We thank Dr. Max Hookway for the 3-D CT reconstruction image and Mr. Robert Derret for the photographic images.

REFERENCES

1. Ahlgren FK, Johannessen AC, Hellem S. Displaced calcium hydroxide paste causing inferior alveolar nerve paraesthesia: report of a case. *Oral Surg Oral Med Oral Pathol Oral Radiol Endod.* 2003;96(6):734-7.
2. Nelson Filho P, Silva LA, Leonardo MR, Utrilla LS, Figueiredo F. Connective tissue responses to calcium hydroxide-based root canal medicaments. *Int Endod J* 1999;32(4):303-11.
3. Shimizu T, Kawakami T, Ochiai T, Kurihara S, Hasegawa H. Histopathological evaluation of subcutaneous tissue reaction in mice to a calcium hydroxide paste developed for root canal fillings. *J Int Med Res* 2004;32(4):416-21.
4. Lindgren P, Eriksson K, Ringberg A. Severe facial ischemia after endodontic treatment. *J Oral Maxillofacial Surg* 2002;60(5):576-9.

Reprint requests;

Robert Hackett, BDS, MFDS
Department of Oral & Maxillofacial Surgery
Royal West Sussex Hospitals NHS Trust
Spitalfields Lane, Chichester
West Sussex, PO19 6SE, UK.
rob_hackett@hotmail.co.uk