

Root and Root Canal Morphology of the Human Permanent Maxillary First Molar: A Literature Review

Blaine M. Cleghorn, DMD, MS,* William H. Christie, DMD, MS, FRCD(C),[†] and Cecilia C.S. Dong, DMD, BSc (Dent), MS, FRCD(C)[†]

Abstract

The objective of this study was to review the literature with respect to the root and canal systems in the maxillary first molar. Root anatomy studies were divided into laboratory studies (in vitro), clinical root canal system anatomy studies (in vivo) and clinical case reports of anomalies. Over 95% (95.9%) of maxillary first molars had three roots and 3.9% had two roots. The incidence of fusion of any two or three roots was approximately 5.2%. Conical and C-shaped roots and canals were rarely found (0.12%). This review contained the most data on the canal morphology of the mesiobuccal root with a total of 8399 teeth from 34 studies. The incidence of two canals in the mesiobuccal root was 56.8% and of one canal was 43.1% in a weighted average of all reported studies. The incidence of two canals in the mesiobuccal root was higher in laboratory studies (60.5%) compared to clinical studies (54.7%). Less variation was found in the distobuccal and palatal roots and the results were reported from fourteen studies consisting of 2576 teeth. One canal was found in the distobuccal root in 98.3% of teeth whereas the palatal root had one canal in over 99% of the teeth studied. (*J Endod* 2006;32:813–821)

Key Words

Maxillary first molar, number of canals, number of roots, root canal morphology, two canal systems

Successful root canal therapy requires a thorough knowledge of root and root canal morphology. It is generally accepted that the most common form of the permanent maxillary first molar has three roots and four canals (1). The broad buccolingual dimension of the mesiobuccal root and associated concavities on its mesial and distal surface is consistent with the majority of the mesiobuccal roots having two canals while there is usually a single canal in each of the distobuccal and palatal roots (1, 2). There is a wide range of variation in the literature with respect to frequency of occurrence of the number of canals in each root, the number of roots and incidence of fusion (1–63).

A number of factors contribute to the variation found in these studies. The root canal morphology of teeth is often extremely complex and highly variable (1, 2, 9, 48) as illustrated in the three-dimensional (3D) models in Figs. 1-3 (9). Variations may result may be because of ethnic background (55), age (22, 29, 34, 35), and gender (18, 37, 41) of the population studied.

Data generated from a specialty endodontic practice may not represent the frequency in a general population as more complex cases are more likely to be referred. Differences in reported results may also be because of the design of the study (clinical versus laboratory) (5). There are also a wide variety of methods used in these studies. These methods in the laboratory include various types of clearing studies using decalcification (31) with injection with India ink (4, 5, 7, 11, 24, 33, 41, 61), Chinese ink (60), hematoxylin dye (51), plastic (20), or metal castings (22, 63), in vitro endodontic access and with radiography and instruments (26, 55) or instruments only (3, 61), in vitro radiopaque gel infusion and radiography (50), in vitro root canal treatment (RCT) (30), in vitro radiography (34, 35, 47), in vitro macroscopic examination (32), scanning electron microscope examination of pulp floor (19), and grinding or sectioning (8, 28, 39, 56).

The clinical methods include clinical evaluation during endodontic treatment using magnification or a surgical operating microscope (SOM) (10, 18, 40, 46) or

From the *Department of Dental Clinical Sciences, Dalhousie University, Halifax, Nova Scotia; and [†]the Department of Restorative Dentistry, University of Manitoba, Winnipeg, Manitoba.

Address requests for reprints to Dr. Blaine M. Cleghorn, Dalhousie University, Faculty of Dentistry, 1210-5981 University Avenue, Halifax, Nova Scotia, B3H 3J5. E-mail address: blaine.cleghorn@dal.ca.

0099-2399/\$0 - see front matter

Copyright © 2006 by the American Association of Endodontists.

doi:10.1016/j.joen.2006.04.014

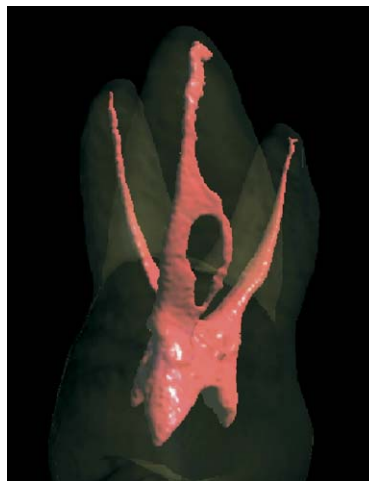

Figure 1. Mesiobuccal view of root canal system of a maxillary first molar (MB root is centered). (Reprinted with permission from Brown P, Herbranson E. Dental anatomy & 3D tooth atlas version 3.0. Illinois: Quintessence, 2005: Maxillary First Molars—3D Models 1. Unique Features.)

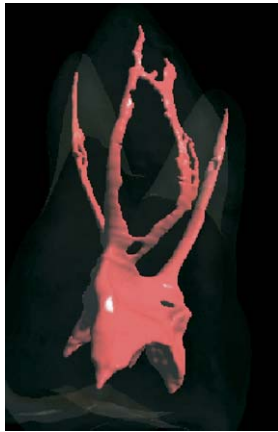

Figure 2. Mesio buccal view of root canal system of a maxillary first molar (MB root is centered). Reprinted with permission from Brown P, Herbranson E. Dental anatomy & 3D tooth atlas version 3.0. Illinois: Quintessence, 2005: Maxillary First Molars—3D Models 2. Bruce Fogel, UOP, Complex MB Root.)

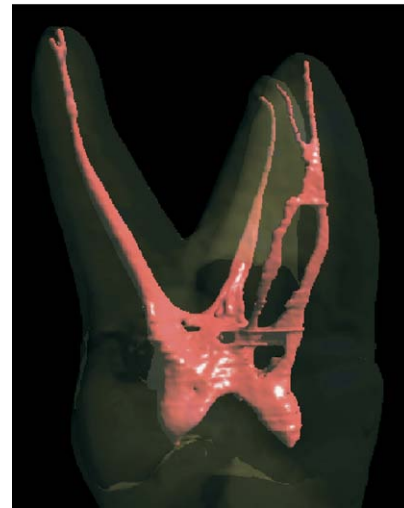


Figure 3. Mesial view of root canal system of a maxillary first molar (MB root is far right). Reprinted with permission from Brown P, Herbranson E. Dental anatomy & 3D tooth atlas version 3.0. Illinois: Quintessence, 2005: Maxillary First Molars—3D Models 3. Deep Distal Caries.)

during endodontic treatment where magnification was not specified (6, 7, 13, 14, 16, 17, 23, 25, 36, 39, 58, 59), retrospective evaluation of patient records of RCT teeth only (13, 21, 29, 43, 46, 62), or radiography of all teeth (38), and in vivo radiographic examination (37, 42, 57).

All of these factors contribute to variations in the reported results. There can also be variations in the number of canals reported because of the authors' definition of what constitutes a canal. A separate canal is defined in some studies as a separate orifice found on the floor of the pulp chamber (30), two instruments placed into two MB canals simultaneously to a minimum depth of 16 mm from the cusp of an intact tooth (39), one that can be instrumented to a depth of 3 to 4 mm (46) or a treatable canal in retrospective clinical studies (18). Other studies fail to provide a clear definition of what defines a canal in their reported data.

In 1969 Weine et al. (56) provided the first clinical classification of more than one canal system in a single root and used the mesio buccal root of the maxillary first molar as the type specimen. Pineda and Kuttler (35) and Vertucci (51) further developed a system for canal anatomy classification for any tooth that has a broad buccolingual diameter and may be more applicable for use in laboratory studies.

Materials and Methods

A review of the literature was performed for each of the teeth in the permanent dentition with respect to the number and type of roots and root canal morphology. Search topics included number of roots, number of canals, root canal morphology, extra roots, and abnormal morphology. Studies of the maxillary first molar identified through PubMed plus hand searching were included, but pooled data from teeth identi-

fied only as maxillary molars were generally avoided. The two exceptions were the pooled data from the classical studies by Hess (22) and Okamura (31). Studies were separated into laboratory (in vitro), clinical (in vivo), and case report articles. Over 8400 permanent maxillary first molars were analyzed in the studies contained in this review. The data were analyzed and weighted averages were determined for each of the following:

1. Number of roots
- Incidence of root fusion
2. Number of canals and apical foramina for the:
 - Mesio buccal root
 - Distobuccal root
 - Palatal root
3. Incidence of C-shaped canals
4. Summary of case reports of other anomalies

Results

The data from four anatomical studies (4, 8, 20, 50) outlined in Table 1 indicate that the maxillary molar normally has three roots (96.2% of 416 teeth). Two roots were found in 16 (3.8%) of the teeth studied. The incidence of one root or four roots is very rare and cannot be evaluated from case reports.

Seven studies (4, 20, 36–38, 50, 60) including 1629 teeth assessed the frequency of root fusion in the maxillary first molars as

TABLE 1. Number of roots in the maxillary first molar

Reference	Number of teeth in study	Type of study	2 Roots %	3 Roots %
al Shalabi RM, et al. (2000) (4)	83	Clearing	2.40% (2)	97.60% (81)
Thomas RP, et al., (1993) (50)	216	Radiographic exam with radiopaque gel infusion of canals	5.60% (12)	94.40% (204)
Gray R (1983) (20)	85	Clearing	—	100% (85)
Barrett MT, (1925) (8)	32	Sectioning	6.30% (2)	90.60% (30)
Total number of teeth	416			
Incidence			3.8% (16)	96.2% (400)

TABLE 2. Incidence of fused roots in the maxillary first molar

Reference	Number of teeth in study	Type of study	Total Incidence of Fused Roots %
al Shalabi, RM et al (2000) (4)	83	Clearing	11% (9)
Sabala, CL et al (1994) (38)	501	Review of patient records	0.4% (2)
Thomas, RP, Moule, AJ and Bryant, R (1993) (50)	216	Radiographic examination with radiopaque gel infusion of canals	5.6% (12)
Pecora, JD et al (1991) (32)	140	In vitro	13.6% (19)
Yang, ZP et al (1988) (60)	305	Clearing	6.2% (19)
Gray, R (1983) (20)	85	Clearing	0% (0)
Ross, IF and Evanchik, PA (1981) (37)	299	Clinical and radiographic examination	7.7% (23)
Total number of teeth Incidence	1629		5.2% (84)

shown in Table 2. Fusion of two or more roots occurred approximately 5.2% of the time. Fusion of roots may occur with the distobuccal to palatal root, or less frequently the distobuccal and mesiobuccal roots were fused.

The internal canal morphology of the mesiobuccal root of the maxillary first molar in 8399 teeth was assessed in 34 studies as shown in Table 3 (laboratory studies) and Table 4 (clinical studies). Two or more canals were present in 56.8% of the teeth in a weighted average of

TABLE 3. Mesiobuccal root of the maxillary first molar number of canals and apices (laboratory studies)

Reference	Number of teeth in study	Type of study	1 canal %	2 or more canal systems %	2 into 1 canal at apex %	2 or more canals at apex %
Sert, S and Bayirli, GS (2004) (41)	200	Clearing	6.5% (13)	93.5% (187)	60.50% (121)	39.50% (79)
Alavi, AM et al (2002) (5)	52	Clearing	35.0% (18)	65.0% (34)	54% (28)	46% (24)
Al Shalabi, RM et al (2000) (4)	83	Clearing	22.0% (18)	78.0% (65)	38% (32)	62% (51)
Weine, FS et al (1999) (55)	293	In vitro radiography	42.0% (123)	58.0% (170)	66.20% (194)	33.80% (99)
Imura, N et al (1998) (24)	42	Clearing	19.0% (8)	80.9% (34)	11.80% (5)	88.20% (37)
Çalışkan, MK et al (1995) (11)	100	Clearing	34.4% (34)	65.6% (66)	75.40% (75)	24.60% (25)
Thomas, RP, Moule, AJ and Bryant, R (1993) (50)	216	Radiographic examination with radiopaque gel infusion of canals	26.4% (57)	73.6% (159)	53.70% (116)	46.30% (100)
Pecora, JD et al (1992) (33)	120	Clearing	75.0% (90)	25.0% (30)	92.50% (111)	7.50% (9)
Kulild, JC and Peters, DD (1990) (26)	51	In vitro access using surgical telescope	4.0% (2)	96.0% (49)	48.20% (25)	51.80% (26)
Gilles, J and Reader, A (1990) (19)	21	Clearing and SEM	10.0% (2)	90.0% (19)	61.90% (13)	38.10% (8)
Vertucci, F (1984) (51)	100	Clearing	45.0% (45)	55.0% (55)	82% (82)	18% (18)
Gray, R (1983) (20)	85	Clearing	41.1% (35)	58.9% (50)	81% (69)	19% (16)
Acosta Vigouroux SA and Trugeda Bosaans, SA (1978) (3)	134	Ground and explored with .08 mm instruments and magnification	28.4% (38)	71.6% (96)	-	-
Seldberg, BH et al (1973) (39)	100	Sectioned	38.0% (38)	62.0% (62)	75% (75)	25% (25)
Pineda, F and Kuttler, Y (1972) (35)	262	In vitro radiographic examination	39.3% (103)	60.7% (159)	51.50% (135)	48.50% (127)
Sykaras, SN and Economou, PN (1971) (47)	100	Macroscopic and radiographic study	68.0% (68)	32.0% (32)	91% (91)	9% (9)
Weine, FS (1969) (56)	208	Sectioning	48.5% (101)	51.5% (107)	86% (179)	14% (29)
Okamura, T (1927) (31)	299	Clearing	47.1% (141)	52.9% (158)	—	—
Hess, W (1925) (22)	513	Clearing	46.4% (238)	53.6% (275)	—	—
Zürcher, E (1925) (63)	40	Clearing	57.0% (23)	42.5% (17)	—	—
Moral, H (1914) (28)	100	Sectioned	37.0% (37)	63.0% (63)	—	—
Total number of teeth Incidence	3119		39.5% (1233)	60.5% (1886)	2033 66.4% (1350)	33.6% (683)

TABLE 4. Mesio Buccal Root of the Maxillary First Molar Number of Canals and Apices (clinical studies)

Reference	Number of teeth in study	Type of study	1 canal %	2 or more canal systems %	2 into 1 canal at apex %	2 or more canals at apex %
Wolcott, J et al (2002) (58)	1193	Clinical examination of RCT treated and retreated teeth	39.0% (465)	61.0% (728)	—	—
Buhrley, LJ et al (2002) (10)	208	Clinical RCT using SOM or loupes	29.9% (62)	71.1% (148)	—	—
Sempira, HN and Hartwell, GR (2000) (40)	130	Clinical RCT using SOM or loupes	66.9% (87)	33.1% (43)	—	—
Stropko, JJ (1999) (46)	1096	Clinical patient record	26.6% (292)	73.2% (802)	45.10% (494)	54.90% (602)
Zaatar, El et al (1997) (62)	133	Clinical radiographs of RCT teeth	59.4% (79)	40.6% (54)	85% (113)	15% (20)
Fogel, HM, Peikoff, MD and Christie, WH (1994) (18)	208	Clinically using surgical telescope	28.8% (60)	71.2% (148)	68.30% (142)	31.70% (66)
Weller, RN and Hartwell, GR (1989) (57)	835	Clinical radiographic evaluation of RCT teeth	61.0% (509)	39.0% (326)	—	—
Neaverth, EJ et al (1987) (29)	228	Clinical RCT	19.3% (44)	80.3% (183)	35.60% (81)	64.40% (147)
Hartwell, G and Bellizzi, R (1982) (21)	538	In vivo RCT teeth	80.7% (434)	18.6% (100)	—	—
Pomeranz, HH and Fishelberg, G (1974) (36)	71	Clinical RCT	72.0% (51)	28.0% (20)	89% (63)	11% (8)
Slowey, RR (1974) (43)	103	Clinical radiographic examination	49.6% (51)	50.4% (52)	—	—
Nosonowitz, DM and Brenner, MR (1973) (30)	336	In vivo study of RCT teeth	35.4% (119)	64.6% (217)	84.90% (285)	15.10% (51)
Seidberg, BH et al (1973) (39)	201	In vivo radiographic examination	66.7% (134)	33.3% (67)	—	—
Total number of teeth Incidence	5280		45.2% (2387)	54.7% (2893)	2072 56.9% (1179)	43.1% (893)

TABLE 5. Distobuccal root of the maxillary first molar number of canals and apices (clinical and laboratory studies)

Reference	Number of teeth in study	Type of study	1 canal %	2 or more canal systems %	2 into 1 canal at apex %	2 or more canals at apex %
Sert, S and Bayirli, GS (2004) (41)	200	Clearing	90.50% (181)	9.50% (19)	97% (194)	3% (6)
Alavi, AM et al (2002) (5)	52	Clearing	98.10% (51)	1.90% (1)	100% (52)	—
Al Shalabi, RM et al (2000) (4)	83	Clearing	97.50% (81)	2.50% (2)	97.50% (81)	2.50% (2)
Zaatar, El et al (1997) (62)	133	Radiographs of RCT teeth	100% (133)	—	100% (133)	—
Çalışkan, MK et al (1995) (11)	100	Clearing	98.40% (98)	1.60% (2)	98.40% (98)	1.60% (2)
Thomas, RP, Moule, AJ and Bryant, R (1993) (50)	216	Radiographic examination with radiopaque gel infusion of canals	95.70% (207)	4.30% (9)	96.20% (208)	3.80% (8)
Pecora, JD et al (1992) (33)	120	Clearing	100% (120)	—	100% (120)	—
Vertucci, F (1984) (51)	100	Clearing	100% (100)	—	100% (100)	—
Gray, R (1983) (20)	85	Clearing	97.6% (83)	2.4% (2)	100% (85)	—
Hartwell, G and Bellizzi, R (1982) (21)	538	In vivo RCT teeth	100% (538)	—	—	—
Acosta Vigouroux SA and Trugeda Bosaans, SA (1978) (3)	134	Ground and explored with .08 mm instruments and magnification	100% (134)	—	—	—
Pineda, F and Kuttler, Y (1972) (34)	262	In vitro radiographic examination	96.40% (253)	3.60% (9)	96.40% (253)	3.60% (9)
Hess, W (1925) (22)	513	Clearing	100% (513)	—	—	—
Zürcher, E (1925) (63)	40	Clearing	100% (40)	—	—	—
Total number of teeth Incidence	2576		98.3% (2532)	1.7% (44)	1351 98.0% (1324)	2.0% (27)

TABLE 6. Palatal root of the maxillary first molar number of canals and apices (clinical and laboratory studies)

Reference	Number of teeth in study	Type of study	1 canal %	2 or more canal systems %	2 into 1 canal at apex %	2 or more canals at apex %
Sert, S and Bayirli, GS (2004) (11)	200	Clearing	94.50% (189)	5.50% (11)	96% (192)	4% (8)
Alavi, AM et al (2002) (5)	52	Clearing	100% (52)	—	100% (52)	—
Al Shalabi, RM et al (2000) (4)	83	Clearing	98.80% (82)	1.20% (1)	98.80% (82)	1.20% (1)
Zaatar, El et al (1997) (62)	133	Radiographs of RCT teeth	100% (133)	—	100% (133)	—
Çaliskan, MK et al (1995) (11)	100	Clearing	93% (93)	7% (7)	97% (97)	3% (3)
Thomas, RP, Moule, AJ and Bryant, R (1993) (50)	216	Radiographic exam with radiopaque gel infusion of canals	97.70% (211)	2.30% (5)	98.20% (212)	1.80% (4)
Pecora, JD et al (1992) (33)	120	Clearing	100% (120)	—	100% (120)	—
Vertucci, F (1984) (51)	100	Clearing	100% (100)	—	100% (100)	—
Gray, R (1983) (20)	85	Clearing	100% (85)	—	100% (85)	—
Hartwell, G and Bellizzi, R (1982) (21)	538	In vivo RCT teeth	99.80% (537)	0.20% (1)	—	—
Acosta Vigouroux SA and Trugeda Bosaans, SA (1978) (3)	134	Ground and explored with .08 mm instruments and magnification	100% (134)	—	—	—
Pineda, F and Kuttler, Y (1972) (35)	262	Radiographic examination in vitro	100% (262)	—	100% (100)	—
Hess, W (1925) (22)	513	Clearing	100% (100)	—	—	—
Zürcher, E (1925) (63)	40	Clearing	100% (40)	—	—	—
Total number of teeth	2576				1351	
Incidence			99.0% (2551)	1.0% (25)	98.8% (1335)	1.2% (16)

all 34 studies. One canal was found in 43.1%. A single apical foramen was found 61.6% of the time, while two separate apical foramina were present 38.3% of the time. The incidence of two canals in the laboratory studies was higher (60.5%) compared with the clinical studies (54.7%).

The canal morphology of the distobuccal and palatal roots was reported in 14 studies that included 2576 teeth as shown in Tables 5 and 6. The most common canal system configuration of the distobuccal root was a single canal (98.3%). Two canals were found 1.7% of the time. A single apical foramen was present 98% of the time. The palatal root has a single canal and a single foramen 99% and 98.8%, respectively.

Table 7 reviews data from two studies (16, 60) that included 2480 teeth. The maxillary first molars had an incidence of C-shaped canals of 0.12% indicating that this type of anomaly is a rare occurrence in the maxillary first molar. Conical single roots or canal systems are also a rare occurrence and are rarely mentioned in studies (31).

Other anomalies were documented in case reports as shown in Table 8. A sample of 16 case reports that described 34 teeth was reviewed.

Discussion

The root and root canal morphology of teeth varies greatly in the reported literature. Many studies provided no information on ethnic background, age or gender, or possible explanations for variation observed.

Walker (52–54) reported on the root anatomy of maxillary first premolars, mandibular first premolars and the high incidence of three-rooted mandibular first molars in Asian patients. He did not, however, report on the incidence of a second mesiobuccal canal (MB2) in the maxillary first molar. A study by Weine et al. (55) determined that the incidence of MB2 in a Japanese population was similar to the incidence reported for other ethnic backgrounds.

Age was found to have an effect on the incidence of MB2. Fewer canals were found in the MB root because of increasing age and calcification (18, 19, 29).

Sert and Bayirli (41) conducted a clearing study that identified gender, in a sample of 2800 teeth (1400 male and 1400 female) from Turkish patients. One hundred permanent teeth of each type

TABLE 7. C-shaped roots in the maxillary first molar

Reference	Number of teeth in study	Type of study	Total incidence of C-shaped roots and root canals (no. of teeth) %
De Moor, RJG (2002) (16)	2,175 (Belgium)	Review of patient records of RCT teeth	0.09% (2)
Yang, ZP et al (1988) (60)	305 (Taiwan; Chinese population)	Clearing	0.3% (1)
Total number of teeth	2,480		
Incidence			0.12% (3)

TABLE 8. Case reports of anomalies in the maxillary first molar

Reference	Number of teeth in study	Type of study	Other key information anatomic variation
Barbizam, JVB et al (2004) (7)	1 (Brazil; 35 year old male; ethnicity not identified)	clinical RCT	4 roots MB, DB and 2 palatal roots Each root contained 1 canal 5 roots 2 MB roots, DB root and 2 palatal roots Each root contained 1 canal
	1 (Brazil; ethnicity not identified)	clearing	
Sert, S and Bayirli, G (2004b) (41)	1 (Turkey; 18 year old Turkish male)	clinical and radiographic examination	Hypertaurodontism (extreme taurodontism with the furcation near the apices of the roots) in both mandibular second molars and the maxillary first and second molars
Baratto-Filho, F et al (2002) (6)	1 (Brazil; 38 year old Japanese female)	clinical RCT	4 roots 4 canals MB root contained 1 canal DB root contained 1 canal 2 palatal roots each contained 1 canal
Maggiore et al (2002) (27)	1 (USA; 19 year old African-American male)	clinical RCT	3 roots and 6 canals MB root contained 2 canals DB root contained 1 canal palatal root contained 3 canals; Vertucci type IX (1-3)
De Moor, RJG (2002) (14)	1 (Belgium; 44 year old Caucasian female)	clinical RCT	C-shaped root canals are most frequently found in mandibular second molars 2 of 2175 RCT maxillary first molars exhibited C-shaped canals C-shaped results from the fusion of the DB and palatal roots in the maxillary first molar
	1 (Belgium; 21 year old Caucasian male)	clinical RCT	
Fava, LRG (2001) (17)	1 (Brazil; 23 year old female)	clinical RCT	2 MB canals and a C-shaped canal because of fusion of DB and palatal roots 1 MB canal and a C-shaped canal with 2 orifices; C-shaped canals joined in the apical third
Johal, S (2001) (25)	1 (Canada; 42 year old male)	clinical RCT	2 roots (buccal and palatal); MB and DB roots fused B root has a Vertucci type V (1-2) canal system
Carlsen, O and Alexandersen, V (2000) (12)	7 (Denmark; age and ethnicity not identified)	Review of extracted tooth collection	3 roots MB, DB and palatal roots 2 MB canals in the MB root 1 canal in the DB root 2 orifices in palatal root and a common apex; Vertucci type 2 (2-1)
Hülsman, M (1997) (23)	4 (Denmark; age and ethnicity not identified)	clinical RCT	7 radix mesiolingualis (supplemental palatal root where the mesial palatal root component has a strong affinity to the mesiolingual part of the crown) 4 2L variants (two palatal roots present)
	1 (Germany; 36 year old Caucasian male)		
Christie, WH et al (1991) (13)	2 first molars (Canada; Caucasian)	clinical RCT	3 roots MB and palatal canal each contained 1 canal DB root contained 2 canals
Wong, M (1991) (59)	1 (USA; 22 year old female)	clinical RCT	Retrospective study of cases over a period of 40 years of full-time endodontic practice 4 roots MB, DB and 2 palatal roots Each root contained 1 canal
			3 canals in the palatal root; 1 canal split into 3 canals in the apical third with 3 separate foramina; MB root and DB root each had 1 canal

TABLE 8. (Continued)

Reference	Number of teeth in study	Type of study	Other key information anatomic variation	
Dankner, E et al (1990) (14)	2 (Israel; 11 year old Caucasian female)	clinical RCT	C-shape canal configuration in maxillary molars is rare	MB root had 2 canals DB and palatal roots fused into a C-shaped canal and root
Stabholz, A and Friedman, S (1983) (44)	1 (Israel; 13 year old female)	clinical RCT		5 canals; 2 palatal and 3 buccal probable example of fusion between maxillary second premolar and maxillary first molar
Hartwell, G and Bellizzi, R (1982) (21)	1 (USA; 23 year old white male)	clinical RCT		3 roots 2 MB canals, 1 DB canal and 2 palatal canals
Stone, LH and Stroner, WF (1981) (45)	1 (USA)	in vitro RCT		2 separate canals (mesial and distal) in the single palatal root
	1 (USA)	clinical RCT		2 separate canals (mesial and distal) in the single palatal root
	1 (USA; 22 year old)	clinical RCT		2 separate canals (mesial and distal) in the single palatal root
	1 (USA)	clinical RCT		2 palatal roots with one canal in each root
Thews, ME et al (1979) (49)	1 (USA; 21 year old male)	clinical RCT		2 palatal roots with one canal in each root
	1 (USA; 43 year old male)	clinical RCT		2 separate canals in a single palatal root that join in the apical third

(excluding third molars) for each gender, were included in the study. Although they did not consider age in their study, they concluded that gender and race were important factors to consider in preoperative evaluation of canal morphology for nonsurgical root canal therapy. Although only 100 of each type of tooth for each gender was included in their study, a single Vertucci type I canal was present in the mesiobuccal root in only 3% of males compared with 10% of females. There are conflicting results with respect to gender and the number of canals (11, 18, 29, 41).

Some studies (36, 39) compared in vivo versus in vitro techniques. Seidberg et al. (39) reported 33.3% of the 201 teeth studied had a MB2 canal in their in vivo study. This increased to 62% in their in vitro study of 100 teeth. Similar results were reported in a study by Pomeranz and Fishelberg (36). Only 31% of 100 teeth studied had a MB2 canal in their in vivo study compared with 69% of 100 teeth in their in vitro study. The in vitro portion of this study described the samples as extracted maxillary molars and may represent pooled data instead of maxillary first molar data alone. The definition of a canal as a treatable canals used in clinical studies (18, 46) versus the more complex canal configurations that are visible through clearing studies (4, 5, 11, 41, 51) can also lead to different results.

The more common use of SOM or loupes in recent clinical studies has resulted in an increased prevalence of the clinical detection of the MB2 canal (10, 26, 40, 46). The effect of magnification on the incidence of MB2 was assessed in a clinical study by Buhrey et al. (10). The MB2 canal was found in 41 of 58 teeth or 71.1% when using SOM. The group using loupes found MB2 in 55 of 88 teeth or 62.5%. The lowest incidence of MB2 was in the group performing RCT without any magnification. MB2 was found in only 10 of 58 teeth or 17.2%. A study by Sempira and Hartwell (40) found that use of a SOM did increase the incidence of MB2. They attributed the lower incidence in their study to their characterization of a canal as one that must be negotiated and obturated to within 4 mm of the apex.

The incidence of many of the anomalies in the case reports shown in Table 8 cannot be determined because of the lack of data collection. However, although rare, these anomalies can and do occur. There are reports of two palatal canals within three rooted teeth (21, 45, 49), three palatal canals in a reticular palatal root (27, 59), two palatal roots or four roots total (6, 7, 12, 13), five roots (2 palatal, two mesiobuccal and one distobuccal) (7), C-shaped canals (14, 16), multiple taurodont molar teeth in a patient (42), root fusion (14, 16, 17, 44), and one report of occurrence of two canal systems in the distobuccal root (23).

Of all the canals in the maxillary first molar, the MB2 can be the most difficult to find and negotiate in a clinical situation. Knowledge from laboratory studies is essential to provide insight into the complex root canal anatomy. A study by Davis et al. (15) compared the post debridement anatomy of the canals of 217 teeth. Injection of silicone impression material into the instrumented canals revealed that standard instrumentation left a significant portion of the canal walls untouched. Fins, webbing and canals were found sometimes to not be fully instrumented. Clinical instrumentation of this tooth, especially with respect to the mesiobuccal root, can be complicated. Failure to detect and treat the second MB2 canal system will result in a decreased long-term prognosis (58). Stropko (46) observed that by scheduling adequate clinical time, by using the recent magnification and detection instrumentation aids and by having thorough knowledge of how and where to search for MB2, the rate of location can approach 93% in maxillary first molars.

Conclusions

Major conclusions that can be drawn from this review article of a comprehensive analysis of the anatomy of roots and morphology of the root canal systems of maxillary first molars are as follows.

The maxillary first molar root anatomy is predominantly a three-rooted form, as shown in all anatomic studies of this tooth. The two-rooted form is rarely reported, and may be a result of fusion of the

distobuccal root to palatal root or fusion of the distobuccal root to the mesiobuccal root. The single root or conical form of root anatomy in the first maxillary molar is rarely reported, except as a case report. The C-shape root canal system morphology is also a rare anomaly. The four-rooted anatomy in its various forms is also very rare in the maxillary first molar and is more likely to occur in the second or third maxillary molar.

Internal root canal system morphology reflects the external root anatomy. The mesiobuccal root of the maxillary first molar contains a double root canal system more often than a single canal, in most studies.

In vitro studies of the mesiobuccal root canal system are slightly more likely to report two canals in the maxillary first molar than in vivo clinical studies, but the incidence appears to be increasing with the more routine use of the surgical operating microscope and other aids during the modified endodontic access opening procedure.

The two-canal system of the mesiobuccal root of the maxillary first molar has a single apical foramen roughly twice as often in proportion to the two-canal and two-foramen morphology, in weighted studies.

The single-canal system and single apical foramen in the palatal and distobuccal root of the maxillary first molar is the most predominant form, as reported in all studies, but multiple canals and more than one apical foramen variation does exist in 1 to 2% of these roots, in weighted studies.

References

1. Walton R, Torabinejad M. Principles and practice of endodontics, 2nd ed. Philadelphia: W.B. Saunders Co., 1996.
2. Ash M, Nelson S. Wheeler's dental anatomy, physiology and occlusion, 8th ed. Philadelphia: Saunders, 2003.
3. Acosta Vigouroux SA, Trugeda Bosaans SA. Anatomy of the pulp chamber floor of the permanent maxillary first molar. J Endod 1978;4:214-9.
4. al Shalabi RM, Omer OE, Glennon J, Jennings M, Claffey NM. Root canal anatomy of maxillary first and second permanent molars. Int Endod J 2000;33:405-14.
5. Alavi AM, Opananon A, Ng YL, Gulabivala K. Root and canal morphology of Thai maxillary molars. Int Endod J 2002;35:478-85.
6. Baratto-Filho F, Fariniuk LF, Ferreira EL, Pecora JD, Cruz-Filho AM, Sousa-Neto MD. Clinical and macroscopic study of maxillary molars with two palatal roots. Int Endod J 2002;35:796-801.
7. Barbizam JV, Ribeiro RG, Tanomaru Filho M. Unusual anatomy of permanent maxillary molars. J Endod 2004;30:668-71.
8. Barrett M. The internal anatomy of the teeth with special reference to the pulp and its branches. Dent Cosmos 1925;67:581-92.
9. Brown P, Herbranson E. Dental anatomy & 3D tooth atlas version 2.0, 2nd ed. Illinois: Quintessence, 2004.
10. Buhley LJ, Barrows MJ, BeGole EA, Wenckus CS. Effect of magnification on locating the MB2 canal in maxillary molars. J Endod 2002;28:324-7.
11. Caliskan MK, Pehlivan Y, Sepetcioglu F, Turkun M, Tuncer SS. Root canal morphology of human permanent teeth in a Turkish population. J Endod 1995;21:200-4.
12. Carlsen O, Alexandersen V. Radix mesiolingualis and radix distolingualis in a collection of permanent maxillary molars. Acta Odontol Scand 2000;58:229-36.
13. Christie WH, Peikoff MD, Fogel HM. Maxillary molars with two palatal roots: a retrospective clinical study. J Endod 1991;17:80-4.
14. Dankner E, Friedman S, Stabholz A. Bilateral C shape configuration in maxillary first molars. J Endod 1990;16:601-3.
15. Davis SR, Brayton SM, Goldman M. The morphology of the prepared root canal: a study utilizing injectable silicone. Oral Surg Oral Med Oral Pathol 1972;34:642-8.
16. De Moor RJ. C-shaped root canal configuration in maxillary first molars. Int Endod J 2002;35:200-8.
17. Fava LR. Root canal treatment in an unusual maxillary first molar: a case report. Int Endod J 2001;34:649-53.
18. Fogel HM, Peikoff MD, Christie WH. Canal configuration in the mesiobuccal root of the maxillary first molar: a clinical study. J Endod 1994;20:135-7.
19. Gilles J, Reader A. An SEM investigation of the mesiolingual canal in human maxillary first and second molars. Oral Surg Oral Med Oral Pathol 1990;70:638-43.

20. Gray R. The Maxillary first molar. In: Bjorndal, AM, Skidmore, AE, eds. Anatomy and morphology of permanent teeth. Iowa City: University of Iowa College of Dentistry, 1983.
21. Hartwell G, Bellizzi R. Clinical investigation of in vivo endodontically treated mandibular and maxillary molars. J Endod 1982;8:555-7.
22. Hess W. The anatomy of the root-canals of the teeth of the permanent dentition, part 1. New York: William Wood and Co., 1925.
23. Hülsmann M. A maxillary first molar with two disto-buccal root canals. J Endod 1997;23:707-8.
24. Imura N, Hata GI, Toda T, Otani SM, Fagundes MI. Two canals in mesiobuccal roots of maxillary molars. Int Endod J 1998;31:410-4.
25. Johal S. Unusual maxillary first molar with 2 palatal canals within a single root: a case report. J Can Dent Assoc 2001;67:211-4.
26. Kulild JC, Peters DD. Incidence and configuration of canal systems in the mesiobuccal root of maxillary first and second molars. J Endod 1990;16:311-7.
27. Maggiore F, Jou YT, Kim S. A six-canal maxillary first molar: case report. Int Endod J 2002;35:486-91.
28. Moral H. Ueber pulpausgüsse. Deutsche Monatsschrift für Zahnheilkunde, 1914.
29. Neaverth EJ, Kotler LM, Kaltenbach RF. Clinical investigation (in vivo) of endodontically treated maxillary first molars. J Endod 1987;13:506-12.
30. Nosonowitz DM, Brenner MR. The major canals of the mesiobuccal root of the maxillary 1st and 2nd molars. N Y J Dent 1973;43:12-5.
31. Okamura T. Anatomy of the root canals. J Am Dent Assoc 1927;14:632-6.
32. Pecora JD, Woelfel JB, Sousa Neto MD. Morphologic study of the maxillary molars. 1. External anatomy. Braz Dent J 1991;2:45-50.
33. Pecora JD, Woelfel JB, Sousa Neto MD, Issa EP. Morphologic study of the maxillary molars. Part II: internal anatomy. Braz Dent J 1992;3:53-7.
34. Pineda F. Roentgenographic investigation of the mesiobuccal root of the maxillary first molar. Oral Surg Oral Med Oral Pathol 1973;36:253-60.
35. Pineda F, Kuttler Y. Mesiodistal and buccolingual roentgenographic investigation of 7,275 root canals. Oral Surg Oral Med Oral Pathol 1972;33:101-10.
36. Pomeranz HH, Fishelberg G. The secondary mesiobuccal canal of maxillary molars. J Am Dent Assoc 1974;88:119-24.
37. Ross IF, Evanck PA. Root fusion in molars: incidence and sex linkage. J Periodontol 1981;52:663-7.
38. Sabala CL, Benenati FW, Neas BR. Bilateral root or root canal aberrations in a dental school patient population. J Endod 1994;20:38-42.
39. Seidberg BH, Altman M, Guttuso J, Suson M. Frequency of two mesiobuccal root canals in maxillary permanent first molars. J Am Dent Assoc 1973;87:852-6.
40. Sempira HN, Hartwell GR. Frequency of second mesiobuccal canals in maxillary molars as determined by use of an operating microscope: a clinical study. J Endod 2000;26:673-4.
41. Sert S, Bayirli GS. Evaluation of the root canal configurations of the mandibular and maxillary permanent teeth by gender in the Turkish population. J Endod 2004;30:391-8.
42. Sert S, Bayrl G. Taurodontism in six molars: a case report. J Endod 2004;30:601-2.
43. Slowey RR. Radiographic aids in the detection of extra root canals. Oral Surg Oral Med Oral Pathol 1974;37:762-72.
44. Stabholz A, Friedman S. Endodontic therapy of an unusual maxillary first molar. J Endod 1983;9:293-5.
45. Stone LH, Stroener WF. Maxillary molars demonstrating more than one palatal root canal. Oral Surg Oral Med Oral Pathol 1981;51:649-52.
46. Stropko JJ. Canal morphology of maxillary molars: clinical observations of canal configurations. J Endod 1999;25:446-50.
47. Sykaras S, Economou P. Root canal morphology of the mesiobuccal root of the maxillary first molar. Oral Res Abstr 1971;2025.
48. Taylor R Variations in morphology of teeth. Springfield, IL: Charles C. Thomas Pub., 1978.
49. Thews ME, Kemp WB, Jones CR. Aberrations in palatal root and root canal morphology of two maxillary first molars. J Endod 1979;5:94-6.
50. Thomas RP, Moule AJ, Bryant R. Root canal morphology of maxillary permanent first molar teeth at various ages. Int Endod J 1993;26:257-67.
51. Vertucci FJ. Root canal anatomy of the human permanent teeth. Oral Surg Oral Med Oral Pathol 1984;58:589-99.
52. Walker RT. Root form and canal anatomy of maxillary first premolars in a southern Chinese population. Endod Dent Traumatol 1987;3:130-4.
53. Walker RT. Root canal anatomy of mandibular first premolars in a southern Chinese population. Endod Dent Traumatol 1988;4:226-8.
54. Walker RT. Root form and canal anatomy of mandibular first molars in a southern Chinese population. Endod Dent Traumatol 1988;4:19-22.
55. Weine FS, Hayami S, Hata G, Toda T. Canal configuration of the mesiobuccal root of the maxillary first molar of a Japanese sub-population. Int Endod J 1999;32:79-87.
56. Weine FS, Healey HJ, Gerstein H, Evanson L. Canal configuration in the mesiobuccal root of the maxillary first molar and its endodontic significance. Oral Surg Oral Med Oral Pathol 1969;28:419-25.

57. Weller RN, Hartwell GR. The impact of improved access and searching techniques on detection of the mesiolingual canal in maxillary molars. *J Endod* 1989;15:82–3.
58. Wolcott J, Ishley D, Kennedy W, Johnson S, Minnich S. Clinical investigation of second mesiobuccal canals in endodontically treated and retreated maxillary molars. *J Endod* 2002;28:477–9.
59. Wong M. Maxillary first molar with three palatal canals. *J Endod* 1991;17:298–9.
60. Yang ZP, Yang SF, Lee G. The root and root canal anatomy of maxillary molars in a Chinese population. *Endod Dent Traumatol* 1988;4:215–8.
61. Yoshioka T, Kikuchi I, Fukumoto Y, Kobayashi C, Suda H. Detection of the second mesiobuccal canal in mesiobuccal roots of maxillary molar teeth ex vivo. *Int Endod J* 2005;38:124–8.
62. Zaatar EI, al-Kandari AM, Alhomaidah S, al-Yasin IM. Frequency of endodontic treatment in Kuwait: radiographic evaluation of 846 endodontically treated teeth. *J Endod* 1997;23:453–6.
63. Zürcher E. The anatomy of the root-canals of the teeth of the deciduous dentition and of the first permanent molars, part 2. New York: William Wood and Co., 1925.