

---

## REVIEW

# Review of the current status of tooth whitening with the walking bleach technique

T. Attin, F. Paqué, F. Ajam & Á. M. Lennon

Department of Operative Dentistry, Preventive Dentistry and Periodontology, Georg-August Universität Göttingen, Göttingen, Germany

---

### Abstract

**Attin T, Paqué F, Ajam F, Lennon ÁM.** Review of the current status of tooth whitening with the walking bleach technique. *International Endodontic Journal*, **36**, 313–329, 2003.

Internal bleaching procedures such as the walking bleach technique can be used for whitening of discoloured root-filled teeth. The walking bleach technique is performed by application of a paste consisting of sodium perborate-(tetrahydrate) and distilled water (3% H<sub>2</sub>O<sub>2</sub>), respectively, in the pulp chamber. Following a critical review of the scientific literature, heating of the mixture is contra-indicated as the risk of

external cervical resorption and the formation of chemical radicals is increased by application of heat. An intracoronal dressing using 30% H<sub>2</sub>O<sub>2</sub> should not be used in order to reduce the risk of inducing cervical resorption. This review provides advice based on the current literature and discusses how the walking bleach technique can lead to successful whitening of non-vital root-filled teeth without the risks of side-effects.

**Keywords:** bleaching, hydrogen peroxide, sodium perborate, tooth resorption.

Received 25 July 2001; accepted 23 January 2003

---

### Introduction

Discoloured teeth, especially in the anterior region, can result in considerable cosmetic impairment. Besides invasive therapies, such as crowning or the placement of veneers, the whitening of teeth is an alternative therapeutic method. In contrast to crowning or veneering, whitening of teeth is relatively non-invasive and conserves dental hard tissue. Vital teeth can be whitened by the nightguard vital bleaching technique utilizing carbamide peroxide gels as the bleaching medium (Fasanaro 1992, Haywood 1992a,b, Attin & Kielbassa 1995, Attin 1998). The whitening of root-filled teeth can be carried out by internal whitening treatment (walking bleach technique) (Weisman 1968, Vernieks & Geurtsen 1986, Arens 1989, Weiger 1992, Bose & Ott 1994, Beer

1995, Ernst *et al.* 1995, Glockner *et al.* 1997). This review of the walking bleach technique describes the recommended procedures to help reduce the risks of complications and to ensure a successful bleaching therapy.

### Indications for the walking bleach technique

Dissemination of blood components into the dentinal tubules caused by pulp extirpation or traumatically induced internal pulp bleeding is a possible reason for discolouration of non-vital teeth (Arens 1989, Goldstein & Garber 1995). A temporary colour change of the crown to pink can often be detected initially. Then, blood degradation products such as haemosiderin, haemin, haematin and haematoidin release iron during haemolysis (Guldener & Langeland 1993). The iron can be converted to black ferric sulphide with hydrogen sulphide produced by bacteria, which causes a grey staining of the tooth. Apart from blood degradation, degrading proteins of necrotic pulp tissue may also cause discolouration. If the access cavity is prepared inappropriately, pulp tissue

---

Correspondence: Professor Dr Thomas Attin, Department of Operative Dentistry, Preventive Dentistry and Periodontology, Georg-August Universität Göttingen, Robert-Koch-Str. 40, D-37075 Göttingen, Germany (Tel.: +49 551 392884; fax: +49 551 392037; e-mail: thomas.attin@med.uni-goettingen.de).

can be left in the pulp chamber in the pulp horns (Brown 1965, Faunce 1983, Kielbassa & Wrbas 2000), which may be another reason for discolouration. Coronal discolouration of root-filled teeth can also be caused by some root-filling materials (van der Burgt & Plaesschaert 1985, 1986, van der Burgt *et al.* 1986a,b, Davis *et al.* 2002) or tetracycline-containing medicaments (e.g. Ledermix, Lederle Pharmaceuticals, Wolfrathausen, Germany) (Kim *et al.* 2000). These discolourations arise when remnants of root-filling materials or medicaments are left in the pulp chamber and the staining substance infiltrates the dentinal tubules. Although no penetration of the dental enamel takes place, there is an observable difference of colour on the tooth (Vogel 1975). Discolouration caused by root-filling materials can be treated by bleaching depending on the staining substance (van der Burgt & Plaesschaert 1986). Discolouration caused by metallic ions (silver cones, amalgam) cannot be removed by whitening treatments (Glockner & Ebeleseder 1993).

Internal discolouration of teeth represents the primary indication for whitening of root-filled teeth (Arens 1989, Werner 1989, Glockner & Ebeleseder 1993). In addition, there are reports and studies on the successful use of the walking bleach technique for correction of severely discoloured teeth caused by incorporation of tetracycline in the dental hard tissue during pre-eruptive maturation of teeth (Hayashi *et al.* 1980, Abou-Rass 1982, 1998, Fields 1982, Walton *et al.* 1983, Lake *et al.* 1985, Anitua *et al.* 1990, Aldecoa & Mayordomo 1992). This procedure starts with intentional devitalization and root-canal treatment of the tooth in order to enable application of the bleaching agent into the pulp chamber. As the methods of intentional devitalization and root-canal treatment have risks, the advantages and disadvantages of this therapy should be assessed. Restorative treatment options such as ceramic veneers should be considered as an alternative procedure.

### **Bleaching agents for the whitening of root-filled teeth**

Reports on the bleaching of discoloured non-vital teeth were first described in the middle of the 19th century. Chlorinated lime was recommended for the whitening of non-vital teeth (Dwinelle 1850). Later, oxalic acid (Atkinson 1862, Bogue 1872) and other agents such as chlorine compounds and solutions (Taft 1878/1879, Atkinson 1879, Harlan 1891), sodium peroxide (Kirk 1893), sodium hypochlorite (Messing 1971) or mixtures consisting of 25% hydrogen peroxide in 75% ether

(pyrozone) (Atkinson 1892, Dietz 1957) were used to bleach non-vital teeth.

An early description of hydrogen peroxide application was reported by Harlan (1984/1885). Superoxol (30% hydrogen peroxide, H<sub>2</sub>O<sub>2</sub>) was also mentioned by Abbot (1918). Some authors proposed using light (Rosenthal 1911, Prinz 1924), heat (Brininstool 1913, Merrell 1954, Brown 1965, Stewart 1965, Caldwell 1967, Hodosh *et al.* 1970, Lemieux & Todd 1981, Leendert *et al.* 1984) or electric current (Kirk 1889, Westlake 1895) to accelerate the bleaching reaction by activating the bleaching agent. In these cases, the bleaching medium was applied in the dental surgery so that the effect on the tooth was restricted to a relatively short period of time.

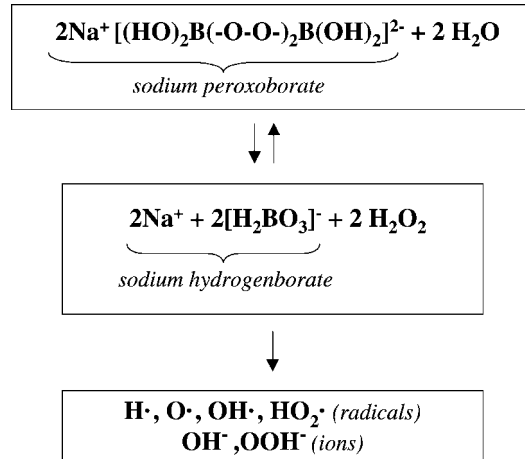
Prinz (1924) recommended using heated solutions consisting of sodium perborate and Superoxol for cleaning the pulp cavity. The first description of the walking bleach technique using a mixture of sodium perborate and distilled water was mentioned in a congress report by Marsh and published by Salvias (1938). In this procedure, the mixture was left in the pulp cavity for a few days and the access cavity was sealed with provisional cement. This concept of application of a mixture of sodium perborate and water to the tooth for a few days was re-considered again by Spasser (1961) and modified by Nutting & Poe (1963) who used 30% hydrogen peroxide instead of water to improve the bleaching effectiveness of the mixture. The use of an intracoronal filling of sodium perborate mixed with water or H<sub>2</sub>O<sub>2</sub> continued till today, and has been described many times as a successful technique (Nutting & Poe 1967, Serene & Snyder 1973, Boksmann *et al.* 1983, Rotstein *et al.* 1993, Attin & Kielbassa 1995).

In addition, some authors described the successful clinical use of external bleaching of non-vital root-filled teeth with carbamide peroxide gels (Putter & Jordan 1989, Swift 1992, Frazier 1998). The whitening gel can be applied by a bleaching tray without an access opening, other reports recommended that the pulp cavity should be open during this bleaching therapy to enable the penetration of the gel into the discoloured tooth (Liebenberg 1997, Carillo *et al.* 1998). However, it should be taken into consideration that an unsealed access cavity enables bacteria and staining substances to penetrate into dentine, and that even with a sound root filling the passage of bacteria through the tooth can be observed (Barthel *et al.* 1999). Therefore, a restorative material such as glass-ionomer cement or composite should be used to seal the root filling at the orifice.

The decomposition of H<sub>2</sub>O<sub>2</sub> into active oxygen is accelerated by application of heat, addition of sodium

hydroxide or light (Hardman *et al.* 1985, Chen *et al.* 1993). H<sub>2</sub>O<sub>2</sub>-releasing bleaching agents are therefore chemically unstable. Only fresh preparations should be utilized, which must be stored in a dark, cool place. The thermocatalytic technique was proposed for many years as the best way of whitening non-vital root-filled teeth because of the high reactivity of H<sub>2</sub>O<sub>2</sub> upon application of heat (Grossman 1940, Brown 1965, Ingle 1965, Abramson *et al.* 1966, Tewari & Chawla 1972, Kopp 1973, Howell 1980, Weine 1982, Boksmann *et al.* 1984, Grossman *et al.* 1988, Hülsmann 1993). In this thermocatalytic procedure, 30–35% H<sub>2</sub>O<sub>2</sub> is applied to the pulp cavity and heated by special lamps or hot instruments. In addition to this, cotton pellets impregnated with 30–35% H<sub>2</sub>O<sub>2</sub> were often used as temporary fillings (Weisman 1963, Lowney 1964, Cohen 1968).

Sodium perborate (sp.) in the form of mono-, tri- or tetrahydrate is used as a H<sub>2</sub>O<sub>2</sub>-releasing agent. Since 1907, sodium perborate has been employed as an oxidiser and bleaching agent especially in washing powder and other detergents. In 1990, the world-wide consumption of sodium perborate was 600 000 tonnes. New formulae (Römpf Lexikon Chemie 1991) characterize sodium perborate in the solid aggregate state as a cyclic peroxoborate (Table 1). The whitening efficacy of sodium perborate mono-, tri- or tetrahydrate mixtures with either water or hydrogen peroxide is not different (Ari & Üngör 2002). H<sub>2</sub>O<sub>2</sub> is released during the decomposition of perborate (Fig. 1). The released H<sub>2</sub>O<sub>2</sub> can generate different radicals or ions depending on pH value, light influence, temperature, existence of co-catalysts and metallic reaction partners (Feinman *et al.* 1991, Goldstein & Garber 1995). Thus, perhydroxy radicals preferably arise in an alkaline environment resulting in effective bleaching agents (Goldstein & Garber 1995). These products are formed after the cleavage of H<sub>2</sub>O<sub>2</sub> and are responsible for the oxidative and reductive and therefore the bleaching properties of H<sub>2</sub>O<sub>2</sub>. The radicals can crack unsaturated double bonds of long, coloured molecules or reduce the coloured metallic oxides like Fe<sub>2</sub>O<sub>3</sub> (Fe<sup>3+</sup>) to colourless FeO (Fe<sup>2+</sup>). It should be appreciated that free radicals can cause oxidative effects to lipids, proteins and nucleic acids (Floyd 1997). This means that important cellular enzymatic reactions can be influenced (Moore *et al.* 1989) and therefore radicals are suspected



**Figure 1** After adding water to sodium peroxoborate, H<sub>2</sub>O<sub>2</sub> is formed that is further decomposed into different radicals or ions.

of being mutagenic and carcinogenic. The sensitivity of tissue increases with age and existence of inflammation, or high concentration of H<sub>2</sub>O<sub>2</sub> and a long contact period of H<sub>2</sub>O<sub>2</sub> to tissue (Floyd & Carney 1992, Li 1998). However, H<sub>2</sub>O<sub>2</sub> is also synthesized by the human body itself, e.g. by neutrophil granulocytes for destruction of bacteria or by the human liver (Nathan 1987, McKenna & Davies 1988). Some bacteria also produce H<sub>2</sub>O<sub>2</sub> (Ryan & Kleinberg 1995). There are variety of human regulatory mechanisms that provide protection from oxidative reagents, e.g. peroxidases in saliva and plasma, glutathione peroxidase, catalases or the glutathione redox system (Tenovuo & Pruitt 1984, Maddipati *et al.* 1987, Gaetani *et al.* 1989, Bowles & Burns 1992, Sinensky *et al.* 1995, Tipton *et al.* 1995, Floyd 1997). It can be concluded that no carcinogenic or cytotoxic risk results from appropriate use of H<sub>2</sub>O<sub>2</sub> in bleaching therapy (Li 1998).

The chemical reaction mentioned above emphasizes that release of H<sub>2</sub>O<sub>2</sub> by mixing sodium perborate and water is achieved without supplementary addition of H<sub>2</sub>O<sub>2</sub>. Several studies have reported bleaching effectiveness by comparing mixtures of sodium perborate with distilled water or H<sub>2</sub>O<sub>2</sub> in different concentrations. Rotstein *et al.* (1991d, 1993) and Weiger *et al.* (1994a) did not report any significant difference in the effectiveness

**Table 1** Old and new formulae (as cyclic peroxoborate) of sodium perborate

Old formula	New formula
NaBO <sub>3</sub> ·n(H <sub>2</sub> O)	2 × (NaBO <sub>2</sub> (OH) <sub>2</sub> )·n(H <sub>2</sub> O)
with n = 1: monohydrate, n = 3: trihydrate, n = 4: tetrahydrate	with n = 0: monohydrate, n = 4: trihydrate, n = 6: tetrahydrate

between sodium perborate mixed with 3–30% H<sub>2</sub>O<sub>2</sub> and the sodium perborate–distilled water mixture. However, the whitening effect of the second mixture can take longer, so that more frequent changes of the bleaching agent may be necessary. The shade stability of teeth treated by a mixture of perborate and water is as high as the shade stability of teeth in which a mixture of sodium perborate with 3 or 30% H<sub>2</sub>O<sub>2</sub> was used (Rotstein *et al.* 1993, Ari & Üngör 2002). Other surveys found that mixing sodium perborate with 30% H<sub>2</sub>O<sub>2</sub> was more effective than mixing with water (Ho & Goerig 1989, Warren *et al.* 1990). Freccia *et al.* (1982) showed that the walking bleach technique with a mixture of 30% H<sub>2</sub>O<sub>2</sub> and sodium perborate was as effective as the thermocatalytic technique.

Complications of the walking bleach technique are contributed to an acidic pH of the bleaching reagent; 30% H<sub>2</sub>O<sub>2</sub> has a pH value between 2 and 3. When 30% H<sub>2</sub>O<sub>2</sub> is mixed with sodium perborate in a ratio of 2 : 1 (g mL<sup>-1</sup>), the pH of this mixture is alkaline. If further 30% H<sub>2</sub>O<sub>2</sub> is added, it becomes acidic (Kehoe 1987, Rotstein & Friedman 1991). Weiger *et al.* (1993) tested the pH value of mixtures consisting of 2 g sodium perborate and 1 mL of 10–30% H<sub>2</sub>O<sub>2</sub> or distilled water. Initially, a neutral or weak alkaline pH for all compositions was apparent, e.g. the mixture of 30% H<sub>2</sub>O<sub>2</sub> and perborate showed an initial pH value of 7.0–8.7 depending on the perborate used (mono-, tri- or tetrahydrate). It was also shown that the pH significantly increased with decreasing concentration of H<sub>2</sub>O<sub>2</sub>. The highest initial pH was observed when sodium perborate was mixed with water. Within a day, a distinct increase of the pH value of 9–11 was achieved. This is true for a sodium perborate suspension mixed with water or H<sub>2</sub>O<sub>2</sub>. This increase in pH is desirable because the whitening effectiveness of buffered alkaline H<sub>2</sub>O<sub>2</sub> is significantly higher than the effect of unbuffered H<sub>2</sub>O<sub>2</sub> (Frysh *et al.* 1995).

Other H<sub>2</sub>O<sub>2</sub>-separating agents such as sodium percarbonate (2Na<sub>2</sub>CO<sub>3</sub>·H<sub>2</sub>O<sub>2</sub>) can be used to bleach discoloured teeth. Suspensions consisting of sodium percarbonate and water or 30% H<sub>2</sub>O<sub>2</sub> had a good bleaching effect on teeth which were artificially stained *in vitro* by iron sulphide (Kaneko *et al.* 2000). However, clinical studies using sodium percarbonate have not been reported.

Aldecoa & Mayordomo (1992) described good clinical success rates when using a mixture consisting of sodium perborate and 10% carbamide peroxide gel. This suspension was used as a temporary intracoronal filling after application of a regular walking bleach paste with sodium perborate and H<sub>2</sub>O<sub>2</sub>. The authors claimed that

this procedure led to long-term stability of the tooth whitening therapy.

### **Influence of bleaching agents used for the walking bleach technique on tooth tissue**

A 30% H<sub>2</sub>O<sub>2</sub> irrigation at both 37 and 50 °C temperature leads to a reduction of the surface microhardness of enamel and dentine. However, the microhardness of teeth was not influenced when treated by a mixture of sodium perborate and 30% H<sub>2</sub>O<sub>2</sub> carried out under the same temperature conditions (Lewinstein *et al.* 1994). Apart from an attack on the inorganic components of teeth, the denaturation of collagen is presumed to be the mode of action of bleaching agents (Lado *et al.* 1983, Ramp *et al.* 1987, Rotstein *et al.* 1992a, 1996). Generally, changes of composition or structure of the inorganic components of teeth correlate with a shift of the calcium:phosphate ratio of apatite. Therefore, Rotstein *et al.* (1996) determined the calcium:phosphate ratio in enamel, dentine and cementum of teeth. They observed no significant change in the calcium:phosphate ratio in enamel, dentine and cementum after application of a suspension containing sodium perborate and water. In contrast to this, the calcium:phosphate ratio in all the three components of teeth reduced significantly when 30% H<sub>2</sub>O<sub>2</sub> was used. These findings do not correspond to the results of Ruse *et al.* (1990) who found no change in the calcium and phosphate content in enamel after application of 35% H<sub>2</sub>O<sub>2</sub>. Further research on dentine and cementum showed that loss of calcium was significantly higher after use of 30% than after use of 3% H<sub>2</sub>O<sub>2</sub>, or a mixture of sodium perborate and 3% H<sub>2</sub>O<sub>2</sub> or distilled water, respectively. There was no difference between a pure 30% H<sub>2</sub>O<sub>2</sub> solution and a suspension consisting of sodium perborate and 30% H<sub>2</sub>O<sub>2</sub> (Rotstein *et al.* 1992a). However, when mixing sodium perborate with 3% instead of 30% H<sub>2</sub>O<sub>2</sub>, a 10–12-fold reduction of dentine and cementum solubility is achieved (Rotstein *et al.* 1992a).

Scanning electron microscope photographs show a precipitate formed on the surface of enamel specimens after contact with a 35% H<sub>2</sub>O<sub>2</sub> solution for several minutes. The precipitate is intensified and the enamel surface becomes more porous by subsequent acid etching with 37% H<sub>3</sub>PO<sub>4</sub>. According to these authors, these changes to enamel could have an influence on the adhesion of composite restorations (Tittley *et al.* 1988a).

It was hypothesized that alterations in dentine permeability owing to whitening therapies may result in pronounced bacterial contamination of dentine. This

contamination may contribute to the occurrence of external resorptions (Cvek & Lindvall 1985). Heling *et al.* (1995) showed that the dentine permeability of *Streptococcus faecalis* was significantly higher after application of 30% H<sub>2</sub>O<sub>2</sub> than after use of a mixture of sodium perborate and water. The latter suspension did not change the dentine permeability for the microorganisms in comparison to the control group treated with water. The authors concluded that the low pH value of the 30% H<sub>2</sub>O<sub>2</sub> solution led to an acid-induced enlargement of the dentinal tubules.

Whether bleaching increases the brittleness of teeth is of importance to the clinical outcome. Unfortunately, there are only a few reports on this topic. Seghi & Denry (1992) observed a 30% reduction in fracture resistance of enamel when 10% carbamide peroxide gel (3.6% H<sub>2</sub>O<sub>2</sub>) was applied in the vital bleaching therapy. However, according to another study, no increase in the brittleness of dentine could be detected by using a mixture of sodium perborate with 30% H<sub>2</sub>O<sub>2</sub> (Glockner *et al.* 1995). In particular, 30% hydrogen peroxide had detrimental effects on the biomechanical properties of dentine, such as tensile and shear strength (Chng *et al.* 2002). These adverse effects are significantly lower for mixture of sodium perborate with either water or 30% hydrogen peroxide. Generally, no fractures of whitened teeth were reported in studies on internal bleaching (Brown 1965, Howell 1980, 1981, Feiglin 1987, Holmstrup *et al.* 1988, Anitua *et al.* 1990, Aldecoa & Mayordomo 1992, Glockner *et al.* 1995, 1999, Abou-Rass 1998). However, it should be appreciated that teeth can be weakened by removal of stained dentine. An increased risk of fracture may be expected when the tooth is already weakened by tooth tissue loss (Geurtsen & Günay 1995). Therefore, severely discoloured dentine should be removed cautiously to prevent further weakening.

## Clinical performance of the walking bleach technique

### Preliminary treatment

It is important to determine whether discolouration of the tooth is caused by internal staining. The surface of the tooth should be cleaned thoroughly to estimate the degree of external discolouration. The patient should be informed that the results of bleaching therapies are not predictable and that complete recovery of colour is not guaranteed in all cases (Baratieri *et al.* 1995). Moreover, information should be given about the different treatment stages, possible complications and the fact

that application of the bleaching agent often needs to be repeated for obtaining optimal results.

### Examination of root fillings, existing restorations and tooth substance

Prior to treatment, a radiograph should be taken to check the quality of the root filling. A thoroughly cleaned root canal and application of a dense root filling are prerequisites for a successful outcome of root-canal treatment. A root-canal filling should also prevent coronal–apical passage of microorganisms or other substances, such as bleaching agents, which might have detrimental effects on the apical tissue. Therefore, a deficient root filling should be replaced prior to bleaching therapy and the filling material should be completely set before the beginning of the bleaching therapy. Deficient restorations should be identified before bleaching therapy and should be replaced, carious lesions should be restored. If the restorations are only discoloured, they should be renewed at the end of treatment with materials matching the whitened tooth colour. Colour of the tooth resulting from bleaching cannot be reliably predicted and this makes it difficult to select the correct shade of filling material prior to bleaching. Therefore, it is advisable to either apply temporary materials (for carious lesions or replacement of deficient fillings) before treatment or to replace restorations after completion of bleaching. Generally, it is important that the tooth is restored with high quality fillings in order to ensure the effectiveness of the bleaching agent and to avoid leakage of the agent into the oral cavity.

### Preparation of the pulp cavity

Before preparation of the access cavity, a rubber dam should be applied to protect the adjacent structures. The access cavity should be shaped in such a way that remnants of restorative materials, root-filling materials and necrotic pulp tissue are removed completely. Additional cleaning of the cavity with 1–3% sodium hypochlorite for removal of difficult, accessible remnants of pulp tissue is recommended (Attin & Kielbassa 1995). In some reports, conditioning of the dentinal surface of the access cavity with 37% H<sub>3</sub>PO<sub>4</sub> is suggested in order to remove the smear layer (Hülsmann 1993, Beer 1995). Others advise cleaning the pulp cavity with alcohol before application of the bleaching agent so that the dentine becomes dehydrated (Werner 1989, Ernst *et al.* 1995). It is assumed that bleaching agents are able to penetrate more easily into the dentine and therefore

are more effective following pretreatment. However, studies have shown that removal of the smear layer with  $H_3PO_4$  does not improve the bleaching effectiveness of either sodium perborate or of high concentrated  $H_2O_2$  (Casey *et al.* 1989, Horn *et al.* 1998). However, the pretreatment of dentine with acid may lead to an increased diffusion of bleaching agents into the periodontium, as these agents are able to penetrate the dentine easily (Fuss *et al.* 1989). Therefore, it may not be advisable to remove the smear layer from the dentine of the pulp chamber prior to bleaching.

### Cervical seal

The root filling should be reduced 1–2 mm below the enamel–cementum junction. This can be controlled by using a periodontal probe placed into the pulp cavity. Root fillings do not effectively prevent diffusion of bleaching agents from the pulpal chamber to the apical foramen (Costas & Wong 1991, Smith *et al.* 1992). Therefore, sealing the root filling with glass-ionomer cement or composite is essential. Rotstein *et al.* (1992b) demonstrated that a 2 mm layer of glass-ionomer cement was required to prevent penetration of a 30% concentrated  $H_2O_2$  solution into the root canal. The seal material should reach the level of the epithelial attachment or the cemento–enamel junction, respectively, to avoid leakage of bleaching agents in the periodontium (Steiner & West 1994). The proximal cemento–enamel junction curves in an incisal direction. A flat barrier, level with the labial cemento–enamel junction, leaves a large portion of the proximal dentinal tubules unprotected. The barrier location should be determined by probing the level of the epithelial attachment at the mesial, distal and labial aspect of the tooth. The intracoronal level of the barrier is placed 1 mm incisal to the corresponding external probing of the attachment. With this method (Steiner & West 1994), the coronal outline of the attachment defines an internal pattern for the shape and location of the barrier. However, the impact of the bleaching agents on the discoloured dentine should not be hampered by the cervical seal. If bleaching of the cervical region of the tooth is required a stepwise reduction of the labial part of the seal and use of a mild bleaching agent is recommended for the final dressings (Rotstein *et al.* 1992b).

### Application of the bleaching agent

Sodium perborate (tetrahydrate) mixed with distilled water in a ratio of 2 : 1 ( $g\ mL^{-1}$ ) is a suitable bleaching

agent as mentioned above (Weiger 1992). In case of severe discolouration, 3%  $H_2O_2$  can be applied in place of water. The use of 30%  $H_2O_2$  is not appropriate because of possible risks such as cervical resorptions (Friedman *et al.* 1988, Kinomoto *et al.* 2001). The bleaching agent can be applied with an amalgam carrier or plugger and should be changed every 3–4 days. Successful bleaching becomes apparent after one to four visits. The patients should be instructed to evaluate the tooth colour on a daily basis and return when the bleaching is acceptable in order to avoid over-bleaching (Geurtsen & Günay 1995).

### Temporary filling

Before application of the bleaching agent, the enamel margins of the cavity should be etched with 37%  $H_3PO_4$  in order to enable an adhesive temporary filling. The walking bleach technique requires a sound seal around the access cavity with composite or compomer restorative to ensure its effectiveness and to avoid leakage of the bleaching agent into the oral cavity. This cannot be guaranteed if temporary filling materials are used (Waite *et al.* 1998). In addition, a good seal prevents re-contamination of the dentine with microorganisms and staining substances.

It is often difficult to insert filling material on to soft sodium perborate mixture or a cotton pellet. A cotton pellet, that is covered with a bonding material, placed on the sodium perborate mixture and then light-cured, simplifies the application of the temporary filling material.

The temporary filling is only attached to the enamel margins of the access cavity. In this phase of treatment, the pulp chamber is filled with the sodium perborate mixture and not with an adhesively attached restorative material, so that no internal stabilization of the tooth is provided. Therefore, the patient should be informed about the increased risk of fracture (Baratieri *et al.* 1995), and occlusal adjustment may be required in order to avoid overloading the tooth.

### Restoration of the access cavity and postoperative radiograph

Following bleaching, the access cavity should be restored with a composite which is adhesively attached to enamel and dentine. This avoids re-contamination with bacteria and staining substances and improves the stability of the tooth. A sound restoration with sealed dentinal tubules is a prerequisite to create a successful bleaching

therapy (Baratieri *et al.* 1995, Abou-Rass 1998). Some authors (Glockner *et al.* 1997, Abou-Rass 1998) recommend the use of composites with light colours, in case the bleaching therapy does not result in complete success. The adhesion of composites to bleached enamel and dentine is temporarily reduced (Titley *et al.* 1988b, 1992, Murchison *et al.* 1992, García-Godoy *et al.* 1993, Toko & Hisamitsu 1993, Dishman *et al.* 1994, Josey *et al.* 1996, Swift & Perdigão 1998). Glass-ionomer cement also has a reduced adhesion to bleached dentine (Titley *et al.* 1989). It is assumed that remnants of peroxide or oxygen on the surface or pores of the tooth inhibit the polymerization of composite (Torneck *et al.* 1990, Dishman *et al.* 1994). It is less likely that changes in the enamel structure may influence composite adhesion (Ruse *et al.* 1990, Torneck *et al.* 1990). The formation of composite tags in bleached enamel is less regular and distinct than in unbleached enamel (Titley *et al.* 1991). This could explain why access cavities of bleached teeth, which are filled with composite, occasionally show marginal leakage (Barkhordar *et al.* 1997). The negative influence of H<sub>2</sub>O<sub>2</sub>-containing bleaching agents on adhesion can be clearly reduced by moderate bevelling of the cavity before acid etching (Cvitko *et al.* 1991). The same can be achieved by pretreatment of enamel with dehydrating agents such as alcohol and the use of acetone-containing adhesives (Kalili *et al.* 1993, Barghi & Godwin 1994). To dissolve remnants of peroxide, the cavity can also be cleaned with catalase or sodium hypochlorite (Rotstein 1993, Attin & Kielbassa 1995). A contact time of at least 7 days with water is recommended to avoid the reduction of adhesion of composites to enamel (Torneck *et al.* 1991, Adibfar *et al.* 1992, Titley *et al.* 1993). Optimal bonding to prebleached dental hard tissue could be achieved after a period of about 3 weeks (Cavalli *et al.* 2001, Shinohara *et al.* 2001). During this period, the colour stability of the bleached tooth should be controlled and a calcium hydroxide dressing should be placed in the pulp cavity for buffering the acidic pH which can occur on cervical root surfaces after intracoronal application of bleaching agents (Kehoe 1987, Baratieri *et al.* 1995). The calcium hydroxide suspension temporarily placed into the pulp chamber after completion of the bleaching procedure does not interfere with the adhesion of composite materials used for final restoration of the access cavity (Demarco *et al.* 2001).

A radiograph of the bleached tooth should be taken after treatment in order to diagnose cervical resorption as early as possible. No information is available in the literature regarding the time intervals for taking postoperative radiographs after bleaching. In accordance

with the recommendations for postoperative radiographic controls of endodontically treated teeth, given by the European Society of Endodontology (1994), a radiographic inspection within the first year after bleaching is suggested.

### **Prognosis and complications during internal bleaching of non-vital root-filled teeth**

#### **Colour stability**

Despite many clinical reports, there are few evidence-based studies on aesthetic dentistry (Niederman *et al.* 1998). Most reports present initial results following bleaching (Table 2). Complete colour matching of the bleached tooth with the adjacent teeth is regarded as an optimal result. However, darkening after internal bleaching can be observed occasionally (Friedman 1997) that is caused presumably by diffusion of staining substances and penetration of bacteria through marginal gaps between the fillings and the tooth. It is worth noting that the opinion of the patient regarding the success of the therapy is often more positive than the opinion of the dentist (Anitua *et al.* 1990, Glockner *et al.* 1995, 1999).

Some have presumed that teeth with a discolouration existing for several years do not respond as well to bleaching therapy as teeth that are stained for a short period of time (Brown 1965, Howell 1980). Howell (1981) could not confirm this claim. Furthermore, it is uncertain whether darkening after bleaching is more probable when the tooth is heavily or mildly discoloured (Brown 1965, Howell 1980, 1981). Discolouration caused by restorative materials has a dubious prognosis (van der Burgt & Plasschaert 1986). Certain metallic ions (mercury, silver, copper, iodine) are extremely difficult to remove or alter by bleaching. No scientific study has yet directly compared the bleaching efficacy in differently (for example greyish or yellowish) discoloured non-vital teeth. However, Brown (1965) reported that trauma or necrosis induced discolouration can be successfully bleached in about 95% of cases compared to lower values for teeth discoloured as a result of medications or restorations (Brown 1965). There are differing opinions on whether teeth that respond rapidly to bleaching have a better long-term colour stability (Howell 1981, Feiglin 1987, Holmstrup *et al.* 1988). Some studies report that stained teeth can be more easily bleached in young patients than in older patients (Chandra 1967, Hodosh *et al.* 1970, Feiglin 1987, Glockner *et al.* 1996), as the wide open dentinal tubules of young

**Table 2** Studies concerning the success rate of internal whitening treatment of non-vital root-filled teeth

Reference	Number	Method	Period of time (years)	Success rate	Remarks
Abou-Rass (1998)	112*	wbt: sp. + 30% H <sub>2</sub> O <sub>2</sub>	5-15	93% success 7% failure	Failure because of internal cervical deposit which could be successfully bleached
Anitua <i>et al.</i> (1990)	258*	wbt (sp. + 110 vol H <sub>2</sub> O <sub>2</sub> )	4	<i>Assessment of the dentist:</i> 100% success (98% complete, 2% partial success) <i>Assessment of the patient:</i> 99.4% success 0.4% failure	
Aldecoa & Mayordomo (1992)			6	100% success (90% complete, 10% partial success)	
Brown (1965)	80	Thermocatalytic: 30% H <sub>2</sub> O <sub>2</sub> Following wbt: 30% H <sub>2</sub> O <sub>2</sub>	5	75% success (39% complete, 46% partial success) 25% failure (17.5% no improvement, 7.5% refractory discolouration)	
Chandra & Chawla (1972)	230	15 different techniques	1	93% success 7% failure	Failures were associated with insufficient fillings
Feiglin (1987)	20	Thermocatalytic: 130 vol H <sub>2</sub> O <sub>2</sub> Following wbt: sp. + mixture of 3/4 water and 1/4 130 vol H <sub>2</sub> O <sub>2</sub>	6	45% success 55% failure	Teeth of younger patients showed better success rates
Friedman <i>et al.</i> (1988)	58	Three different techniques (a) Thermocatalytic: 30% H <sub>2</sub> O <sub>2</sub> (b) wbt: 30% H <sub>2</sub> O <sub>2</sub> (c) Thermocatalytic + wbt: 30% H <sub>2</sub> O <sub>2</sub>	8	50%: successful 29%: acceptable 21%: failure	Highest percentage of failures occurred between 2 and 8 years after whitening treatment
Glockner <i>et al.</i> (1996)	34	wbt: sp. + 30% H <sub>2</sub> O <sub>2</sub>	3	<i>Entire cases:</i> 82% success 17% improvement 6% failure <i>Ideal cases:</i> 95% success 5% improvement 0% failure	Success and ideal cases: see above 100% success in patients between 15 and 25 years of age
Glockner <i>et al.</i> (1999)	86	wbt: sp. + 30% H <sub>2</sub> O <sub>2</sub>	5	<i>Assessment of the dentist:</i> 66% success of entire cases and 84% success of ideal cases <i>Assessment of the patient:</i> 92% success of entire cases and 98% of ideal cases	Ideal cases: anterior teeth without proximal restorations Success, if optimal, very good or good result
Holmstrup <i>et al.</i> (1988)	95	wbt: sp. + water	Immediately after bleaching therapy	63% success (63% good, 26% acceptable) 10% failure	Three teeth with transient pain
	69		3	79% success (49% good, 30% acceptable) 20% failure	
Howell (1980)	41	Thermocatalytic: 30% H <sub>2</sub> O <sub>2</sub> Following wbt: 30% H <sub>2</sub> O <sub>2</sub>	Immediately after bleaching therapy	97% success (90% complete, 7% partial success) 2% failure	One failure: one tooth which was discoloured since 40 years

Howell (1981)	36	Thermocatalytic: 30% H <sub>2</sub> O <sub>2</sub> Following wbt: 30% H <sub>2</sub> O <sub>2</sub>	1	97% success (53% complete, 44% partial success) 3% failure	The only failure was associated with an insufficient filling
	19		2	100% success (42% complete, 58% partial success) No failure	
Tewari & Chawla (1972)	19	Thermocatalytic: 30% H <sub>2</sub> O <sub>2</sub>	5	95% success 5% failure	The only failure was successfully bleached again

\*Intentional endodontic treatment of tetracycline-stained teeth; sp. sodium perborate; wbt: walking bleach technique.

teeth enable a better diffusion of the bleaching agent. However, not all studies confirm the age dependency of bleaching success (Brown 1965, Howell 1981). Teeth with internal discoloration caused by root-canal medications, root-filling materials or metallic restorations such as amalgam have a poor prognosis regarding bleaching success (Brown 1965). Anterior teeth with several approximal restorations occasionally show a less optimal result than teeth with a palatal access cavity only (Glockner *et al.* 1996, 1999). This may be because of the fact that composites cannot be bleached (Monaghan *et al.* 1992). In these cases, replacing the existing restorations after finishing the whitening treatment is recommended in order to get an optimal result.

### Complications

Occurrence of external cervical resorption is a serious complication following internal bleaching procedures (MacIsaac & Hoen 1994, Friedman 1997). Cervical resorption is mostly asymptomatic and is usually detected only through routine radiographs (Trope 1997). Heithersay (1999) analysed 257 teeth in 222 patients with cervical resorptions and discovered that in 24.1% of cases the resorption was caused by orthodontic treatment, 15.1% by dental trauma, 5.1% by surgery (e.g. transplantation or periodontal surgery) and 3.9% by intracoronal bleaching. A combination of internal bleaching procedures with one of the other causes is responsible for 13.6% of cervical resorption cases.

Table 3 provides an overview of clinical studies and case reports in which the occurrence of cervical resorption was observed, partly diagnosed many years after internal bleaching was applied (Harrington & Natkin 1979, Lado *et al.* 1983). However, experimental animal studies showed histological signs of resorptions only 3 months after internal thermocatalytic bleaching therapy with heated 30% H<sub>2</sub>O<sub>2</sub> (Rotstein *et al.* 1991a, Heller *et al.* 1992). One month after bleaching, no changes in the tooth substance could be detected. Cervical resorptions often proceed in an asymptomatic way, however, sometimes swelling of the papilla or percussion sensitivity of the bleached teeth can be observed (Harrington & Natkin 1979, Lado *et al.* 1983). Table 2 shows that teeth that were root-filled as a result of trauma often show cervical resorption. Furthermore, the studies and case reports indicate that application of heat (thermocatalytic method), lack of a cervical seal and the use of 30% H<sub>2</sub>O<sub>2</sub> are associated with the occurrence of cervical resorption. In an experimental animal study, Madison & Walton (1990) showed that the thermocatalytic

**Table 3** Occurrence of cervical resorption after internal bleaching procedures in clinical studies and case reports

Reference	Number of bleached teeth	Whitening treatment	Cases of cervical resorption	Age of patients (years)	Cervical seal	Trauma	Heat
Clinical studies							
Abou-Rass (1998)	112	wbt: sp. + 30% H <sub>2</sub> O <sub>2</sub>	None	–	–	–	–
Anitua <i>et al.</i> (1990)	258	wbt: sp. + 110 vol H <sub>2</sub> O <sub>2</sub>	None	–	–	–	–
Aldecoa & Mayordomo (1992)							
Friedman <i>et al.</i> (1988)	58	(a) thermocatalytic: 30% H <sub>2</sub> O <sub>2</sub>	1	24	No	No	Yes
		(b) wbt: 30% H <sub>2</sub> O <sub>2</sub>	1	18	No	No	No
		(c) thermocat. + wbt: 30% H <sub>2</sub> O <sub>2</sub>	2	14	No	No	Yes
Heithersay <i>et al.</i> (1994)	204	Thermocatalytic: 30% H <sub>2</sub> O <sub>2</sub>	4	1: 10–15	No	Yes	Yes
		Following wbt: 30% H <sub>2</sub> O <sub>2</sub>		3: 16–20	No	Yes	Yes
Holmstrup <i>et al.</i> (1988)	69	wbt: sp. + water	None	?	Yes	Predominantly	No
Case reports							
Al-Nazhan (1991)	1	Thermocatalytic: 30% H <sub>2</sub> O <sub>2</sub>	1	27	No	No	Yes
		Following wbt: sp. + 30% H <sub>2</sub> O <sub>2</sub>					
Cvek & Lindvall (1985)	11	Thermocatalytic: 30% H <sub>2</sub> O <sub>2</sub>	11	< 21	No	Yes: 10	Yes
		Following wbt: 30% H <sub>2</sub> O <sub>2</sub>				No: 1	
Friedman (1989)	3	No exact description	3	?	?	?	?
Gimlin & Schindler (1990)	1	wbt: sp. + 30% H <sub>2</sub> O <sub>2</sub>	1	13	No	Yes	No
Goon <i>et al.</i> (1986)	1	wbt: sp. + 30% H <sub>2</sub> O <sub>2</sub>	1	15	No	Yes	No
Harrington & Natkin (1979)	7	Thermocatalytic: 30% H <sub>2</sub> O <sub>2</sub>					
		Following wbt: sp. + 30% H <sub>2</sub> O <sub>2</sub>	7	14–29	No	Yes	Yes
Lado <i>et al.</i> (1983)	1	Thermocatalytic: 30% H <sub>2</sub> O	1	44	No	No	Yes
		Following wbt: sp. + 30% H <sub>2</sub> O <sub>2</sub>					
Latcham (1986)	1	wbt: Endoperox	1	8	No	Yes	No
Latcham (1991)	1	wbt: Endoperox	1	14	No	Yes	No
Montgomery (1984)	1	No exact description	1	19	?	Yes	?

The age of the patient means the age at the time of the whitening treatment. The columns cervical seal, occurrence of trauma and application of heat refer to teeth which showed cervical resorption.

?: No statement; sp. sodium perborate; wbt: walking bleach technique.

technique supported the development of external resorption. However, the walking bleach technique applied in that study with a sodium perborate–H<sub>2</sub>O<sub>2</sub> solution did not cause cervical resorption even 1 year after bleaching. This observation may be explained by the fact that sodium perborate inhibits the function of macrophages, because macrophages stimulate both osteoclastic bone resorption and destruction of dentine and cementum induced by lytic processes in periodontal tissue (Jiménez-Rubio & Segura 1998).

The mechanisms responsible for resorption in bleached teeth have not yet been adequately explained. It has been proven that formulations using either 30% H<sub>2</sub>O<sub>2</sub> alone or in combination with sodium perborate are more toxic for periodontal ligament cells as compared to a perborate–water suspension (Kinomoto *et al.* 2001). Lado *et al.* (1983) presumed that application of bleaching agents led to denaturation of dentine in the cervical region of tooth. According to the authors, this denatured dentine induces a foreign body reaction, although this could not be verified. Other authors claim that diffusion of H<sub>2</sub>O<sub>2</sub> via dentine causes irritation in the periodontium, which later results in bacterial colonization of the open dentinal tubules (Cvek & Lindvall 1985). This could trigger inflammation of adjacent tissues and external resorption. Harrington & Natkin (1979) suspected that H<sub>2</sub>O<sub>2</sub> diffuses into the periodontium via dentinal tubules and directly induces an inflammatory resorptive process. It is known that H<sub>2</sub>O<sub>2</sub> can diffuse through dentine (Pashley & Livingston 1978, Wang & Hume 1988, Hanks *et al.* 1994) and radicals and the low pH value of highly concentrated H<sub>2</sub>O<sub>2</sub> can be considered as tissue damage inducing factors (Friedman *et al.* 1988). Table 3 reveals that patients who had bleaching therapy at a young age often have external resorption. A possible explanation is that H<sub>2</sub>O<sub>2</sub> can more easily penetrate into the periodontium because of wide dentinal tubules in young teeth (Schröder 1992). Increasing permeability of dentine is associated with both decreasing dentine thickness and high surrounding temperature (Outhwaite *et al.* 1976). Application of heat leads to widening of dentinal tubules and facilitates diffusion of molecules in the dentine (Pashley *et al.* 1983). This explains the increasing dissemination of H<sub>2</sub>O<sub>2</sub> into dentine with rise in temperature (Rotstein *et al.* 1991c). Moreover, application of heat resulted in generation of hydroxyl radicals from H<sub>2</sub>O<sub>2</sub> that are extremely reactive and have been shown to degrade components of connective tissue (Dahlstrom *et al.* 1997). Diffusion of H<sub>2</sub>O<sub>2</sub> to cervical tissues is also increased after pretreatment of dentine in the pulp chamber with 5% NaOCl (Barbosa

*et al.* 1994). In addition, the penetration of H<sub>2</sub>O<sub>2</sub> into the cervical region can be facilitated by cervical defects or special morphological patterns at the enamel–cementum junction (Rotstein *et al.* 1991b, Koulaouzidou *et al.* 1996, Neuvald & Consolaro 2000). According to Rotstein (1991), lack of root cementum resulted in diffusion of up to 82% of the H<sub>2</sub>O<sub>2</sub> (30% concentration) which was applied in the pulp chamber. However, dissemination of H<sub>2</sub>O<sub>2</sub> into dentine cannot be totally prevented using mixtures of sodium perborate with 30% H<sub>2</sub>O<sub>2</sub> or water. The amount of H<sub>2</sub>O<sub>2</sub> diffusion is significantly lower when a mixture of sodium perborate-tetrahydrate and water is used, than in case of application of 30% H<sub>2</sub>O<sub>2</sub> mixed with different sodium perborates (Weiger *et al.* 1994b). Even if there is low-H<sub>2</sub>O<sub>2</sub> diffusion into adjacent tissues when sodium perborate solutions are applied, a sound cervical seal should be assured in order to prevent penetration of H<sub>2</sub>O<sub>2</sub> through dentine (see above).

Tooth extraction is often inevitable in cases of severe external root resorption (Goon *et al.* 1986, Latcham 1986). Inflammatory osteolytic lesions have a low-pH value that is optimal for hard tissue resorption (McCormick *et al.* 1983). Root-canal dressings consisting of calcium hydroxide are able to induce a higher pH in dentine (Tronstad *et al.* 1981, Webber 1983). Tronstad *et al.* (1981) assumed that reparative formations of hard tissue are supported by this treatment. Cases have shown that an intracoronal dressing with calcium hydroxide can sometimes prevent progression of external resorption (Montgomery 1984, Gimlin & Schindler 1990). However, on the radiograph, only osseous regeneration of the defect and no dental hard tissue regeneration could be detected.

Another possible therapy for external cervical resorption is orthodontic tooth extrusion, followed by restoration of the tooth with a post-retained crown (Latcham 1991, Emery 1996). Cervical resorption can also be treated by direct restorations after gaining surgical access to the defect (Meister *et al.* 1986, Friedman 1989, Al-Nazhan 1991).

## Conclusions

Discoloured root-filled teeth can be successfully treated using the walking bleach technique. Bleaching is performed by temporarily placing a mixture of sodium perborate-(tetrahydrate) and water into the pulp chamber. This mixture releases H<sub>2</sub>O<sub>2</sub> which is able to react with the staining substances. In the case of severe and refractory discolouration, 3% H<sub>2</sub>O<sub>2</sub> could be used instead of water. It is not advisable to use the thermocatalytic

method with heating of a 30% H<sub>2</sub>O<sub>2</sub> solution, as this procedure increases the risk of external cervical resorption. For the same reason, 30% H<sub>2</sub>O<sub>2</sub> should also not be used for the walking bleach technique. In order to prevent seepage of H<sub>2</sub>O<sub>2</sub> through dentine, it is necessary to place a dense root filling and an additional cervical seal prior to starting the walking bleach procedure. For long-term success, it seems to be important to restore the access cavity with an adhesive filling, which prevents leakage of bacteria and stains.

## References

- Abbot CH (1918) Bleaching discoloured teeth by means of 30 per cent perhydrol and the electric light rays. *Journal of the Allied Dental Society* **13**, 259.
- Abou-Rass M (1982) The elimination of tetracycline discoloration by intentional endodontics and internal bleaching. *Journal of Endodontics* **8**, 101–6.
- Abou-Rass M (1998) Long-term prognosis of intentional endodontics and internal bleaching of tetracycline-stained teeth. *Compendium of Continuing Education in Dentistry* **19**, 1034–50.
- Abramson II, Norris JP, Sachs WJ (1966) *Atlas of Endodontic Technique. A Clinical Guide*. St. Louis, USA: C.V. Mosby.
- Adibfar A, Steele A, Torneck CD, Titley KC, Ruse D (1992) Leaching of hydrogen peroxide from bleached bovine enamel. *Journal of Endodontics* **18**, 488–91.
- Al-Nazhan S (1991) External root resorption after bleaching: a case report. *Oral Surgery Oral Medicine Oral Pathology* **72**, 607–9.
- Aldecoa EA, Mayordomo FG (1992) Modified internal bleaching of severe tetracycline discolorations: a 6-year clinical evaluation. *Quintessence International* **23**, 83–9.
- Anitua E, Zabalegui B, Gil J, Gascon F (1990) Internal bleaching of severe tetracycline discolorations: four-year clinical evaluation. *Quintessence International* **21**, 783–8.
- Arens D (1989) The role of bleaching in esthetics. *Dental Clinics of North America* **33**, 319–36.
- Ari H, Üngör M (2002) *In vitro* comparison of different types of sodium perborate used for intracoronal bleaching of discolored teeth. *International Endodontic Journal* **35**, 433–6.
- Atkinson CB (1862) Bleaching teeth, when discolored from loss of vitality: means for preventing their discoloration and ulceration. *Dental Cosmos* **3**, 74–7.
- Atkinson CB (1879) Hints and queries. *Dental Cosmos* **21**, 471.
- Atkinson CB (1892) Fancies and some facts. *Dental Cosmos* **34**, 968–72.
- Attin T (1998) Sicherheit und Anwendung von Bleichtherapien mit Carbamidperoxid. *Deutsche Zahnärztliche Zeitschrift* **53**, 11–6.
- Attin T, Kielbassa AM (1995) Die Bleichbehandlung – ein fester Bestandteil ästhetischer Zahnheilkunde. *Zahnärztliche Mitteilungen* **85**, 2674–80.
- Baratieri LN, Ritter AV, Monteiro S, Jr, Caldeira de Andrada MA, Cardoso Vieira LC (1995) Non-vital tooth bleaching: guidelines for the clinician. *Quintessence International* **26**, 597–8.
- Barbosa SV, Safavi KE, Spangberg SW (1994) Influence of sodium hypochlorite on the permeability and structure of cervical human dentine. *International Endodontic Journal* **27**, 309–12.
- Barghi N, Godwin JM (1994) Reducing the adverse effect of bleaching on composite-enamel bond. *Journal of Esthetic Dentistry* **6**, 157–61.
- Barkhordar RA, Kempler D, Plesh O (1997) Effect of non-vital tooth bleaching on microleakage of resin composite restorations. *Quintessence International* **28**, 341–4.
- Barthel CR, Strobach A, Briedigkeit H, Göbe UB, Roulet JF (1999) Leakage in roots coronally sealed with different temporary fillings. *Journal of Endodontics* **25**, 731–4.
- Beer RF (1995) Bleichen – ein zahnschonendes Verfahren zur Verbesserung der Ästhetik. *Quintessenz* **46**, 873–86.
- Bogue EA (1872) Bleaching teeth. *Dental Cosmos* **14**, 1–3.
- Boksman L, Jordan RE, Skinner DH (1983) Non-vital bleaching – internal and external. *Australian Dental Journal* **28**, 149–52.
- Boksman L, Jordan RE, Skinner DH (1984) A conservative bleaching treatment for the non-vital discolored tooth. *Compendium of Continuing Education in Dentistry* **5**, 471–5.
- Bose M, Ott KHR (1994) Das Bleichen von Zähnen. *Deutsche Zahnärztliche Zeitschrift* **49**, 209–13.
- Bowles WH, Burns H, Jr (1992) Catalase/peroxidase activity in dental pulp. *Journal of Endodontics* **18**, 527–34.
- Brininstool CL (1913) Vapor bleaching. *Dental Cosmos* **55**, 532.
- Brown G (1965) Factors influencing successful bleaching of the discolored root-filled tooth. *Oral Surgery Oral Medicine Oral Pathology* **20**, 238–44.
- van der Burgt TP, Plaesschaert AJM (1985) Tooth discoloration induced by dental materials. *Oral Surgery Oral Medicine Oral Pathology* **60**, 666–9.
- van der Burgt TP, Plaesschaert AJM (1986) Bleaching of tooth discoloration caused by endodontic sealers. *Journal of Endodontics* **12**, 231–4.
- van der Burgt TP, Eronat C, Plaesschaert AJM (1986a) Staining patterns in teeth discolored by endodontic sealers. *Journal of Endodontics* **12**, 187–91.
- van der Burgt TP, Mullaney TP, Plaesschaert AJM (1986b) Tooth discoloration induced by endodontic sealers. *Oral Surgery Oral Medicine Oral Pathology* **61**, 84–9.
- Caldwell CB (1967) Heat source for bleaching discolored teeth. *Arizona Dental Journal* **13**, 18–9.
- Carillo A, Trevino MVA, Haywood VB (1998) Simultaneous bleaching of vital and an open-chamber non-vital tooth with 10% carbamide peroxide. *Quintessence International* **29**, 643–8.
- Casey LJ, Schindler WG, Murata SM, Burgess JO (1989) The use of dentinal etching with endodontic bleaching procedures. *Journal of Endodontics* **15**, 535–8.
- Cavalli V, Reis AF, Giannini M, Ambrosano GM (2001) The effect of elapsed time following bleaching on enamel bond strength of resin composite. *Operative Dentistry* **26**, 597–602.

- Chandra S (1967) Bleaching of discoloured non-vital teeth. *Journal of the Indian Dental Association* **39**, 157–61.
- Chandra S, Chawla TN (1972) Clinical evaluation of various chemicals and techniques of bleaching of discoloured root filled teeth. *Journal of the Indian Dental Association* **44**, 165–71.
- Chen JH, Xu JW, Shing CX (1993) Decomposition rate of hydrogen peroxide bleaching agents under various chemical and physical conditions. *Journal of Prosthetic Dentistry* **69**, 46–8.
- Chng HK, Palamara JE, Messer HH (2002) Effect of hydrogen peroxide and sodium perborate on biomechanical properties of human dentin. *Journal of Endodontics* **28**, 62–7.
- Cohen S (1968) A simplified method for bleaching discolored teeth. *Dental Digest* **74**, 301–3.
- Costas FL, Wong M (1991) Intracoronal isolating barriers: effect of location on root canal leakage and effectiveness of bleaching agents. *Journal of Endodontics* **17**, 365–8.
- Cvek M, Lindvall AM (1985) External root resorption following bleaching of pulpless teeth with oxygen peroxide. *Endodontics and Dental Traumatology* **1**, 56–60.
- Cvitko E, Denehy GE, Swift EJ, Jr, Pires JA (1991) Bond strength of composite resin to enamel bleached with carbamide peroxide. *Journal of Esthetic Dentistry* **3**, 100–2.
- Dahlstrom SW, Heithersay GS, Bridges TE (1997) Hydroxyl radical activity in thermo-catalytically bleached root-filled teeth. *Endodontics and Dental Traumatology* **13**, 119–25.
- Davis MC, Walton RE, Rivera EM (2002) Sealer distribution in coronal dentin. *Journal of Endodontics* **28**, 464–6.
- Demarco FF, Freitas JM, Siva MP, Justino LM (2001) Microleakage in endodontically treated teeth; influence of calcium hydroxide dressing following bleaching. *International Endodontic Journal* **34**, 495–500.
- Dietz VH (1957) The bleaching of discolored teeth. *Dental Clinics of North America* **1**, 897–902.
- Dishman MV, Covey DA, Baughan LW (1994) The effects of peroxide bleaching on composite to enamel bond strength. *Dental Materials* **9**, 33–6.
- Dwinelle WW (1850) Ninth Annual Meeting of American Society Of Dental Surgeons. Article X. *American Journal of Dental Science* **1**, 57–61.
- Emery C (1996) External cervical resorption: a case study using orthodontic extrusion. *Dental Update* **23**, 325–8.
- Ernst CP, Briseño B, Hickel R (1995) Bleichbehandlung von vitalen und avitalen Zähnen. *Phillip Journal* **12**, 229–36.
- European Society of Endodontology (1994) Consensus report of the European Society of Endodontology on quality guidelines for endodontic treatment. *International Endodontic Journal* **27**, 115–24.
- Fasanaro TS (1992) Bleaching teeth: history, chemicals, and methods used for common tooth discolorations. *Journal of Esthetic Dentistry* **4**, 71–8.
- Faunce F (1983) Management of discolored teeth. *Dental Clinics of North America* **27**, 657–70.
- Feiglin B (1987) A 6-year recall study of clinically chemically bleached teeth. *Oral Surgery Oral Medicine Oral Pathology* **63**, 610–3.
- Feinman RA, Mandray G, Yarborough D (1991) Chemical, optical and physiologic mechanisms of bleaching products: a review. *Practical Periodontics and Aesthetic Dentistry* **3**, 32–7.
- Fields JP (1982) Intracoronal bleaching of tetracycline-stained teeth. *Journal of Endodontics* **8**, 512–3.
- Floyd RA (1997) The effect of peroxides and free radicals on body tissues. *Journal of the American Dental Association* **128** (Suppl.), 37–40.
- Floyd RA, Carney JM (1992) Free radical damage to protein and DNA: mechanisms involved and relevant observations on brain undergoing oxidative stress. *Annals of Neurology* **32**, 22–7.
- Frazier KB (1998) Nightguard bleaching to lighten a restored, non-vital discolored tooth. *Compendium of Continuing Education in Dentistry* **19**, 810–3.
- Freccia WE, Peters D, Lorton L, Bernier W (1982) An *in vitro* comparison of non-vital bleaching techniques in the discolored tooth. *Journal of Endodontics* **8**, 70–7.
- Friedman S (1989) Surgical-restorative treatment of bleaching-related external root resorption. *Endodontics and Dental Traumatology* **5**, 63–7.
- Friedman S (1997) Internal bleaching: long-term outcomes and complications. *Journal of the American Dental Association* **128** (Special issue), 51–5.
- Friedman S, Rotstein I, Libfeld H, Stabholz A, Heling I (1988) Incidence of external root resorption and esthetic results in 58 bleached pulpless teeth. *Endodontics and Dental Traumatology* **4**, 23–6.
- Frysh H, Bowles WH, Baker F, Rivera-Hidalgo F, Guillen G (1995) Effect of pH on hydrogen peroxide bleaching agents. *Journal of Esthetic Dentistry* **9**, 130–3.
- Fuss Z, Szajkis S, Tagger M (1989) Tubular permeability to calcium hydroxide and to bleaching agents. *Journal of Endodontics* **15**, 362–4.
- Gaetani GE, Galiano S, Canepa L, Ferraris AM, Kirkman HN (1989) Catalase and glutathione peroxidase are equally active in detoxification of hydrogen peroxide in human erythrocytes. *Blood* **73**, 334–9.
- Garcia-Godoy F, Dodge WW, Donohue M, O'Quinn JA (1993) Composite resin bond strength after enamel bleaching. *Operative Dentistry* **18**, 144–7.
- Geurtsen W, Günay H (1995) Bleichen von Zähnen. In: Hupfauf L, Nolden R, eds. *Ästhetik in der Zahn-Mund-und Kieferheilkunde – PdZ spezial*. München, Germany: Urban & Schwarzenberg, pp. 143–55.
- Gimlin DR, Schindler WG (1990) The management of postbleaching cervical resorption. *Journal of Endodontics* **16**, 292–7.
- Glockner K, Ebeleseder K (1993) Indikationen und Grenzfälle für das Bleichen von devitalen verfärbten Frontzähnen. *Quintessenz* **44**, 519–27.
- Glockner K, Ebeleseder K, Städtler P (1996) 3-Jahres-Nachuntersuchung nach Internal-Bleaching. *Stomatologie* **93**, 347–50.
- Glockner K, Ebeleseder K, Städtler P (1997) Das Bleichen von verfärbten Frontzähnen. *Deutsche Zahnärztliche Zeitschrift* **52**, 311–7.

- Glockner K, Hulla H, Ebeleseder K, Städler P (1999) Five-year follow-up of internal bleaching. *Brazilian Dental Journal* **10**, 105–10.
- Glockner K, Jeglitsch F, Städler P, Ebeleseder K (1995) Die Zunahme der Sprödigkeit von Dentin beim Internal bleaching. *Zahnärztliche Welt* **104**, 84–8.
- Goldstein RE, Garber DA (1995) *Complete Dental Bleaching*. Berlin: Quintessence.
- Goon WWY, Cohen S, Borer RF (1986) External cervical root resorption following bleaching. *Journal of Endodontics* **12**, 414–8.
- Grossman LI (1940) *Root Canal Therapy*. Philadelphia, USA: Lea & Febiger.
- Guldener PHA, Langeland K (1993) *Endodontologie*, 3rd edn. Stuttgart. New York: Thieme.
- Grossman LI, Oliet S, Del Río CE (1988) *Endodontic Practice*, 11th edn. Philadelphia, USA: Lea & Febiger.
- Hanks CT, Wataha JC, Parsell RR, Strawn SE, Fat JC (1994) Permeability of biological and synthetic molecules through dentine. *Journal of Oral Rehabilitation* **21**, 475–87.
- Hardman PK, Moore DL, Petteway GH (1985) Stability of hydrogen peroxide as a bleaching agent. *General Dentistry* **33**, 121–2.
- Harlan AW (1884/1885) The removal of stains from teeth caused by administration of medical agents and the bleaching of a pulpless tooth. *American Journal of Dental Science* **18**, 521.
- Harlan AW (1891) The dental pulp, its destruction, and methods of treatment of teeth discolored by its retention in the pulp chamber or canals. *Dental Cosmos* **33**, 137–41.
- Harrington GW, Natkin E (1979) External resorption associated with bleaching of pulpless teeth. *Journal of Endodontics* **5**, 344–8.
- Hayashi K, Takamizu M, Momoi V, Furuya K, Kusunoki M, Kono A (1980) Bleaching teeth discolored by tetracycline therapy. *Dental Survey* **56**, 17–25.
- Haywood VB (1992a) Bleaching of vital and non-vital teeth. *Current Opinion in Dentistry* **2**, 142–9.
- Haywood VB (1992b) History, safety, and effectiveness of current bleaching techniques and applications of the nightguard vital bleaching technique. *Quintessence International* **23**, 471–88.
- Heithersay GS (1999) Invasive cervical resorption: an analysis of potential predisposing factors. *Quintessence International* **30**, 83–95.
- Heithersay GS, Dahlstrom SW, Marin PD (1994) Incidence of invasive cervical resorption in bleached root-filled teeth. *Australian Dental Journal* **39**, 82–7.
- Heling I, Parson A, Rotstein I (1995) Effect of bleaching agents on dentin permeability to *Streptococcus faecalis*. *Journal of Endodontics* **21**, 540–2.
- Heller D, Skriber J, Lin LM (1992) Effect of intracoronal bleaching on external cervical root resorption. *Journal of Endodontics* **18**, 145–8.
- Ho S, Goerig AC (1989) An *in vitro* comparison of different bleaching agents in the discolored tooth. *Journal of Endodontics* **15**, 106–11.
- Hodosh M, Mirman M, Shklar G, Povar M (1970) A new method of bleaching discolored teeth by the use of a solid state direct heating device. *Dental Digest* **76**, 344–6.
- Holmstrup G, Palm AM, Lambjerg-Hansen H (1988) Bleaching of discoloured root-filled teeth. *Endodontics and Dental Traumatology* **4**, 197–210.
- Horn DJ, Hicks L, Bulan-Brady J (1998) Effect of smear layer removal on bleaching of human teeth *in vitro*. *Journal of Endodontics* **24**, 791–5.
- Howell RA (1980) Bleaching discoloured root-filled teeth. *British Dental Journal* **148**, 159–62.
- Howell RA (1981) The prognosis of bleached root-filled teeth. *International Endodontic Journal* **14**, 22–6.
- Hülsmann M (1993) *Endodontie*. Stuttgart, New York: Georg Thieme Verlag.
- Ingle JI (1965) *Endodontics*. Philadelphia, USA: Lea & Febiger.
- Jiménez-Rubio A, Segura JJ (1998) The effect of the bleaching agent sodium perborate on macrophage adhesion *in vitro*: implications in external cervical root resorption. *Journal of Endodontics* **24**, 229–32.
- Josey AL, Meyers IA, Romaniuk K, Symons AL (1996) The effect of a vital bleaching technique on enamel surface morphology and the bonding of composite resin to enamel. *Journal of Oral Rehabilitation* **23**, 244–50.
- Kalili KT, Caputo AA, Yoshida K (1993) Effect of alcohol of composite bond strength to bleached enamel. *Journal of Dental Research* **72** (Spec Iss), 285 (Abstract. 1440).
- Kaneko J, Inoue S, Kawakami S, Sano H (2000) Bleaching effect of sodium percarbonate on discolored pulpless teeth *in vitro*. *Journal of Endodontics* **26**, 25–8.
- Kehoe JC (1987) pH reversal following *in vitro* bleaching of pulpless teeth. *Journal of Endodontics* **13**, 6–9.
- Kielbassa AM, Wrbas KT (2000) Extrinsische und intrinsische Zahnverfärbungen. Teil 1: Ursachen. *Zahnärztliche Welt* **109**, 177–83.
- Kim ST, Abbot PV, McGinley P (2000) The effects of Ledermix paste on discolouration of mature teeth. *International Endodontic Journal* **33**, 227–32.
- Kinamoto Y, Carnes DL, Ebisu S (2001) Cytotoxicity of intracanal bleaching agents on periodontal ligament cells *in vitro*. *Journal of Endodontics* **27**, 574–7.
- Kirk EC (1889) The chemical bleaching of teeth. *Dental Cosmos* **31**, 273–83.
- Kirk EC (1893) Hints, queries, and comments: sodium peroxide. *Dental Cosmos* **35**, 1265–7.
- Kopp RS (1973) A safe, simplified bleaching technique for pulpless teeth. *Dental Survey* **49**, 42–4.
- Koulaouzidou E, Lambrianidis T, Beltes P, Lyroudia K, Papadopoulos C (1996) Role of cemento-enamel junction on the radicular penetration of 30% hydrogen peroxide during intracoronal bleaching *in vitro*. *Endodontics and Dental Traumatology* **12**, 146–50.
- Lado EA, Stanley HR, Weismann MI (1983) Cervical resorption in bleached teeth. *Oral Surgery Oral Medicine Oral Pathology* **55**, 78–80.

- Lake FT, O'Dell N, Walton RE (1985) The effect of internal bleaching on tetracycline in dentin. *Journal of Endodontics* **11**, 415–20.
- Latcham NL (1986) Postbleaching cervical resorption. *Journal of Endodontics* **12**, 262–4.
- Latcham NL (1991) Management of a patient with severe post-bleaching cervical resorption. A clinical report. *Journal of Prosthetic Dentistry* **65**, 603–5.
- Leendert B, Jordan RE, Skinner DH (1984) A conservative bleaching treatment for the non-vital discolored tooth. *Compendium of Continuing Education in Dentistry* **5**, 471–5.
- Lemieux JJ, Todd MJ (1981) Simplified bleaching of discolored pulpless teeth. *Journal of the Canadian Dental Association* **47**, 729–31.
- Lewinstein I, Hirschfeld Z, Stabholz A, Rotstein I (1994) Effect of hydrogen peroxide and sodium perborate on the microhardness of human enamel and dentin. *Journal of Endodontics* **20**, 61–3.
- Li Y (1998) Tooth bleaching using peroxide-containing agents: current status of safety issues. *Compendium of Continuing Education in Dentistry* **19**, 783–94.
- Liebenberg WH (1997) Intracoronal lightening of discolored pulpless teeth: a modified walking bleach technique. *Quintessence International* **28**, 771–7.
- Lowney JJ (1964) Simplified technique for bleaching a discolored tooth. *Dental Digest* **70**, 446.
- MacIsaac AM, Hoen MM (1994) Intracoronal bleaching: concerns and considerations. *Journal of the Canadian Dental Association* **60**, 57–64.
- Maddipati KR, Gasparski C, Marnett LJ (1987) Characterization of the hydroxyperoxide-reducing activity of human plasma. *Archives of Biochemistry and Biophysics* **254**, 9–17.
- Madison S, Walton R (1990) Cervical root resorption following bleaching of endodontically treated teeth. *Journal of Endodontics* **16**, 570–4.
- McCormick JE, Weine FS, Maggio JD (1983) Tissue pH of developing periapical lesions in dogs. *Journal of Endodontics* **9**, 47–51.
- McKenna SM, Davies KJ (1988) The inhibition of bacterial growth by hypochlorous acid. Possible role in the bactericidal activity of phagocytes. *Biochemistry Journal* **254**, 685–92.
- Meister F, Haasch GC, Gerstein H (1986) Treatment of external resorption by a combined endodontic–periodontic procedure. *Journal of Endodontics* **12**, 542–5.
- Merrell JH (1954) Bleaching of discoloured pulpless tooth. *Journal of the Canadian Dental Association* **20**, 380.
- Messing JJ (1971) Bleaching. *Journal of the British Endodontic Society* **5**, 84–5.
- Monaghan P, Lim E, Lautenschlager E (1992) Effects of home bleaching preparations on composite resin color. *Journal of Prosthetic Dentistry* **68**, 575–8.
- Montgomery S (1984) External cervical resorption after bleaching a pulpless tooth. *Oral Surgery Oral Medicine Oral Pathology* **57**, 203–6.
- Moore RB, Brummitt ML, Mankad VN (1989) Hydroperoxides selectivity inhibit human erythrocyte membrane enzymes. *Archives of Biochemistry and Biophysics* **273**, 527–34.
- Murchison DF, Charlton DG, Moore BK (1992) Carbamide peroxide bleaching: effects on enamel hardness and bonding. *Operative Dentistry* **17**, 181–5.
- Nathan CF (1987) Neutrophil activation on biological surfaces. Massive secretion of hydrogen peroxide in response to products of macrophages and lymphocytes. *Journal of Clinical Investigation* **80**, 1550–60.
- Neuvald L, Consolaro A (2000) Cemento–enamel junction: microscopic analysis and external cervical resorption. *Journal of Endodontics* **24**, 74–7.
- Niedermaier R, Ferguson M, Urdaneta R, et al. (1998) Evidence-based esthetic dentistry. *Journal of Esthetic Dentistry* **10**, 229–34.
- Nutting EB, Poe GS (1963) A new combination for bleaching teeth. *Journal of the Southern Californian Dental Association* **31**, 289.
- Nutting EB, Poe GS (1967) Chemical bleaching of discolored endodontically treated teeth. *Dental Clinics of North America* **11**, 655–62.
- Outhwaite WC, Livingston MJ, Pashley DH (1976) Effects of changes in surface area, thickness, temperature and post-extraction time on human dentine permeability. *Archives of Oral Biology* **21**, 599–603.
- Pashley DH, Livingston MJ (1978) Effect of molecular size on permeability coefficients in human dentine. *Archives of Oral Biology* **23**, 391–5.
- Pashley DH, Thompson SM, Stewart FP (1983) Dentine permeability: effects of temperature on hydraulic conductance. *Journal of Dental Research* **62**, 956–9.
- Prinz H (1924) Recent improvements in tooth bleaching. A clinical syllabus. *Dental Cosmos* **66**, 558–60.
- Putter H, Jordan RE (1989) The 'walking' bleach technique. *Journal of Esthetic Dentistry* **1**, 191–3.
- Ramp WK, Arnold RR, Russell JE, Yancey JM (1987) Hydrogen peroxide inhibits glucose metabolism and collagen synthesis in bone. *Journal of Periodontology* **58**, 340–4.
- Römpp Lexikon Chemie (1991), 9th edn. Stuttgart, New York: Georg Thieme Verlag, 2933 p.
- Rosenthal P (1911) The combined use of ultra-violet rays and hydrogen dioxide for bleaching teeth. *Dental Cosmos* **53**, 246–7.
- Rotstein I (1991) *In vitro* determination and quantification of 30% hydrogen peroxide penetration through dentin and cementum during bleaching. *Oral Surgery Oral Medicine Oral Pathology* **72**, 602–6.
- Rotstein I (1993) Role of catalase in the elimination of residual hydrogen peroxide following tooth bleaching. *Journal of Endodontics* **19**, 567–9.
- Rotstein I, Friedman S (1991) pH variation among materials used for intracoronal bleaching. *Journal of Endodontics* **17**, 376–9.
- Rotstein I, Friedman S, Katznelson J, Sommer M, Bab I (1991a) Histological characterization of bleaching-induced external root resorption in dogs. *Journal of Endodontics* **17**, 436–41.

- Rotstein I, Torek Y, Misgav R (1991b) Effect of cementum defects on radicular penetration of 30% H<sub>2</sub>O<sub>2</sub> during intracoronary bleaching. *Journal of Endodontics* **17**, 230–3.
- Rotstein I, Torek Y, Lewinstein I (1991c) Effect of bleaching time and temperature on the radicular penetration of hydrogen peroxide. *Endodontics and Dental Traumatology* **7**, 196–8.
- Rotstein I, Zalkind M, Mor C, Tarabeah A, Friedman S (1991d) *In vitro* efficacy of sodium perborate preparations used for intracoronary bleaching of discolored non-vital teeth. *Endodontics and Dental Traumatology* **7**, 177–80.
- Rotstein I, Lehr Z, Gedalia I (1992a) Effect of bleaching agents on inorganic components of human dentin and cementum. *Journal of Endodontics* **18**, 290–3.
- Rotstein I, Zyskind D, Lewinstein I, Bamberger N (1992b) Effect of different protective base materials on hydrogen peroxide leakage during intracoronary bleaching *in vitro*. *Journal of Endodontics* **18**, 114–7.
- Rotstein I, Mor C, Friedman S (1993) Prognosis of intracoronary bleaching with sodium perborate preparations *in vitro*: 1-year study. *Journal of Endodontics* **19**, 10–2.
- Rotstein I, Dankner E, Goldman A, Heling I, Stabholz A, Zalkind M (1996) Histochemical analysis of dental hard tissues following bleaching. *Journal of Endodontics* **22**, 23–4.
- Ruse ND, Smith DC, Torneck CD, Titley KC (1990) Preliminary surface analysis of etched, bleached, and normal bovine enamel. *Journal of Dental Research* **69**, 1610–3.
- Ryan CS, Kleinberg I (1995) Bacteria in human mouths involved in the production and utilization of hydrogen peroxide. *Archives of Oral Biology* **40**, 753–63.
- Salvas CJ (1938) Perborate as a bleaching agent. *Journal of the American Dental Association* **25**, 324.
- Schröder HE (1992) *Orale Strukturbiologie*, 4th edn. Stuttgart, New York: Thieme. 106 p.
- Seghi RR, Denry I (1992) Effects of external bleaching on indentation and abrasion characteristics of human enamel *in vitro*. *Journal of Dental Research* **71**, 1340–4.
- Serene TP, Snyder DE (1973) Bleaching technique (pulpless anterior teeth). *Journal of the Southern Californian Dental Association* **41**, 30–2.
- Shinohara MS, Rodrigues A, Pimenta AF (2001) *In vitro* microleakage of composite restorations after non-vital bleaching. *Quintessence International* **32**, 413–7.
- Sinensky MC, Leiser AL, Babich H (1995) Oxidative stress aspects of the cytotoxicity of carbamide peroxide *in vitro* studies. *Toxicology Letters* **75**, 1101–19.
- Smith JJ, Cunningham CJ, Montgomery S (1992) Cervical canal leakage after internal bleaching procedures. *Journal of Endodontics* **18**, 476–81.
- Spasser HF (1961) A simple bleaching technique using sodium perborate. *New York State Dental Journal* **27**, 332–4.
- Steiner DR, West JD (1994) A method to determine the location and shape of an intracoronary bleach barrier. *Journal of Endodontics* **20**, 304–6.
- Stewart GG (1965) Bleaching discolored pulpless teeth. *Journal of the American Dental Association* **70**, 325–8.
- Swift EJ, Jr (1992) Treatment of a discolored, endodontically treated tooth with home bleaching and composite resin. *Practical Periodontics and Aesthetic Dentistry* **4**, 19–21.
- Swift EJ, Jr, Perdigão J (1998) Effects of bleaching on teeth and restorations. *Compendium of Continuing Education in Dentistry* **19**, 815–20.
- Taft J (1878/1879) Bleaching teeth. *American Journal of Dental Science* **12**, 364.
- Tenovuuo J, Pruitt KM (1984) Relationship of the human salivary peroxidase system to oral health. *Journal of Oral Pathology* **13**, 573–84.
- Tewari A, Chawla HS (1972) Bleaching of non-vital discoloured anterior teeth. *Journal of the Indian Dental Association* **44**, 130–3.
- Tipton DA, Braxton SD, Dabbous MK (1995) Role of saliva and salivary components as modulators of bleaching agent toxicity to human gingival fibroblasts *in vitro*. *Journal of Periodontology* **66**, 766–74.
- Titley K, Torneck CD, Smith D (1988a) The effect of concentrated hydrogen peroxide on the surface morphology of human tooth enamel. *Journal of Endodontics* **14**, 69–74.
- Titley KC, Torneck CD, Smith DC, Adibfar A (1988b) Adhesion of composite resin to bleached and unbleached bovine enamel. *Journal of Dental Research* **67**, 1523–8.
- Titley KC, Torneck CD, Smith DC, Applebaum NB (1989) Adhesion of a glass ionomer cement to bleached and unbleached bovine dentin. *Endodontics and Dental Traumatology* **5**, 132–8.
- Titley KC, Torneck CD, Smith DC, Chernecky R, Adibfar A (1991) Scanning electron microscopy observations on the penetration and structure of resin tags in bleached and unbleached bovine enamel. *Journal of Endodontics* **17**, 72–5.
- Titley KC, Torneck CD, Ruse ND (1992) The effect of carbamide-peroxide gel on the shear bond strength of a microfil resin to bovine enamel. *Journal of Dental Research* **71**, 20–4.
- Titley KC, Torneck CD, Ruse ND, Krmec D (1993) Adhesion of a resin composite to bleached and unbleached human enamel. *Journal of Endodontics* **19**, 112–5.
- Toko T, Hisamitsu H (1993) Shear bond strength of composite resin to unbleached and bleached human dentine. *Asian Journal of Aesthetic Dentistry* **1**, 33–6.
- Torneck CD, Titley KC, Smith DC, Adibfar A (1990) The influence of time of hydrogen peroxide exposure on the adhesion of composite resin to bleached bovine enamel. *Journal of Endodontics* **16**, 1123–8.
- Torneck CD, Titley KC, Smith DC, Adibfar A (1991) Effect of water leaching on the adhesion of composite resin to bleached and unbleached bovine enamel. *Journal of Endodontics* **17**, 156–60.
- Tronstad L, Andreasen JO, Hasselgren G, Kristerson L, Riis I (1981) pH changes in dental tissues after root canal filling with calcium hydroxide. *Journal of Endodontics* **7**, 17–21.
- Trope M (1997) Cervical root resorption. *Journal of the American Dental Association* **128** (Spec Iss), 56–9.
- Vernieks AA, Geurtsen W (1986) Das Bleichen verfärbter marktoter Zähne. *Zahnärztliche Welt* **95**, 130–4.

- Vogel RI (1975) Intrinsic and extrinsic discoloration of the dentition. *Journal of Oral Medicine* **30**, 99–104.
- Waite RM, Carnes DL, Walker WA III (1998) Microleakage of TERM used with sodium perborate/water and sodium perborate/superoxol in the 'walking bleach' technique. *Journal of Endodontics* **24**, 648–50.
- Walton RE, O'Dell NL, Lake FT, Shimp RG (1983) Internal bleaching of tetracycline-stained teeth in dogs. *Journal of Endodontics* **9**, 416–20.
- Wang J-D, Hume WR (1988) Diffusion of hydrogen ion and hydroxyl ion from various sources through dentine. *International Endodontic Journal* **21**, 17–26.
- Warren MA, Wong M, Ingram TA III (1990) An *in vitro* comparison of bleaching agents on the crowns and roots of discolored teeth. *Journal of Endodontics* **16**, 463–7.
- Webber RT (1983) Traumatic injuries and the expanded endodontic role of calcium hydroxide. In: Gerstein, H, ed. *Techniques in Clinical Endodontics*. W.B. Saunders, Philadelphia, pp. 210–1.
- Weiger R (1992) Bleichen verfärbter wurzelkanalbehandelter Zähne. *Endodontie* **1**, 109–16.
- Weiger R, Kuhn A, Löst C (1993) Effect of various types of sodium perborate on the pH of bleaching agents. *Journal of Endodontics* **19**, 239–41.
- Weiger R, Kuhn A, Löst C (1994a) *In vitro* comparison of various types of sodium perborate used for intracoronary bleaching of discolored teeth. *Journal of Endodontics* **20**, 338–41.
- Weiger R, Kuhn A, Löst C (1994b) Radicular penetration of hydrogen peroxide during intra-coronal bleaching with various forms of sodium perborate. *International Endodontic Journal* **27**, 313–7.
- Weine FS (1982) *Endodontic Therapy*, 3rd edn. St. Louis–Toronto–London: C.V. Mosby.
- Weisman MI (1963) Efficient bleaching procedure for the pulpless tooth. *Dental Digest* **69**, 347–52.
- Weisman HN (1968) Bleaching non-vital teeth. *Dental Survey* **44**, 52–3.
- Werner J (1989) Die Beseitigung von Verfärbungen devitaler Frontzähne. *Quintessenz* **40**, 1593–608.
- Westlake A (1895) Bleaching teeth by electricity. *American Journal of Dental Science* **29**, 101.