

Clinical

Two canals in a single root: clinical and practical considerations

Arnaldo Castellucci considers the clinical and practical implications of having two canals in a single root

According to Franklin Weine, two canals in the same root can present one of the following types of configurations (Figure 1):

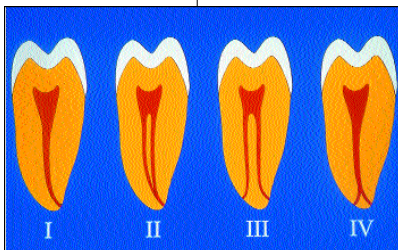


Figure 1: Four types of canal configuration present in one root, according to Weine

- Two separate and distinct canals from chamber to apex (type III) (Figures 2a, 2b)
- Two separate and distinct canals from chamber to apex, with communications at any levels (Figures 3a, 3b)

- Two canals leaving the chamber and merging to form a single canal short of the apex (type II) (Figures 4a, 4b).

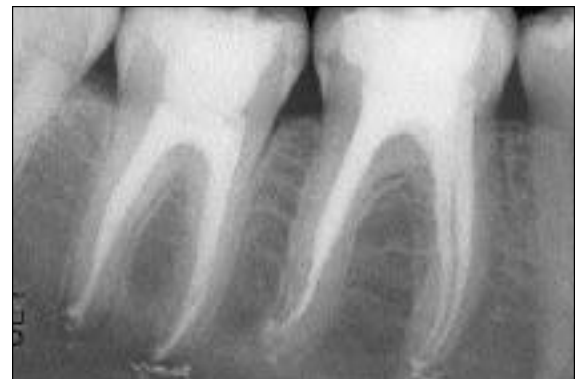In the first configuration the two existing canals can be cleaned, shaped and packed separately, as if they were in different roots.

In the second configuration, which is impossible to diagnose early and should be always expected great care should be taken during the obturation procedure, in order to obtain a perfect apical seal.

In the third configuration, which is easy to diagnose early, great care must be used during the cleaning and shaping and the packing procedures.

Cleaning and shaping of confluent root canals

Cleaning and shaping two canals in the same root which merge to a common foramen requires particular precautions to prevent tearing of the apical foramen or



pointless weakening of the root, including stripping.

It is futile to reach the same foramen arising from a different canal and thus from a different direction, because this risks tearing the foramen. It is equally useless to enlarge the apical portion of the canal common to the two canals of the same root; this could lead to stripping of the canal wall or fracture of an endodontic instrument. Therefore, it is important to establish as soon as possible if the two canals

existing in the same root have a common apex or if they are independent. The easiest way to do this is to prepare one canal at a time. As soon as you are ready to check the working length of the second canal (after early coronal enlargement) insert a gutta percha cone in the first prepared canal and the file in the second (Figure 5).

The confluence is detected by the impression left by a small file on the gutta percha cone inserted into the

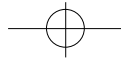
Figure 2a: The mesial root of the second molar has two separate and distinct canals from chamber to apex

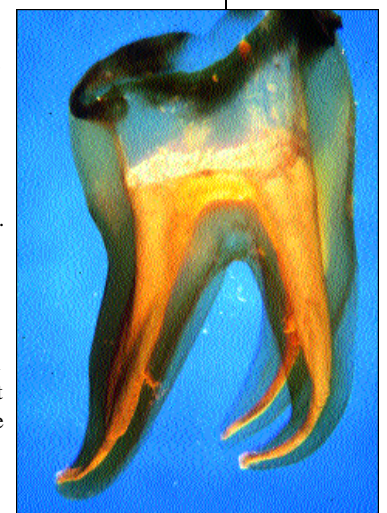

Figure 2b: The same anatomy is shown in this transparent tooth



Arnaldo Castellucci is a Professor of Endodontics at the University of Siena, Dental School. He is author of the book *Endodontia* and has had numerous articles published. He lectures worldwide and is an active member of the AAE, European Society of Endodontology and the Italian Society of Restorative Dentistry



Clinical

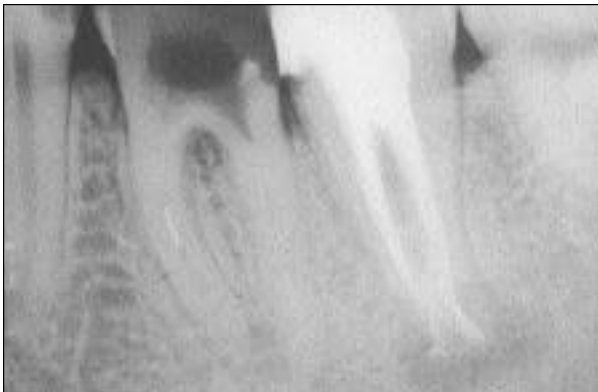

Figure 3a:
Lower molar with two separate and distinct canals in one single root: a communication exists in the apical third

prepared canal (Figure 6). You can now determine the position of the confluence (distance from the apical foramen) and adjust the working length of the instruments in the second canal, as well as the flare to be given to it.

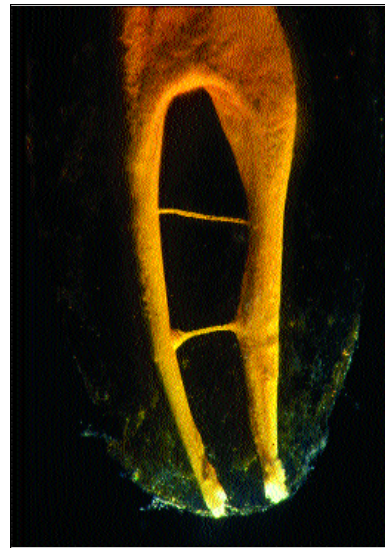


Figure 3b:
Two separate canals in the same root with two communications

one, will therefore begin from the confluence itself rather than from the apical foramen.

The mesial root of a lower molar will serve as an example to illustrate the operative sequence:

1. Clean and shape the mesiolingual canal, which has a more rectilinear course. It is more difficult to cause stripping in this canal, since it is more centered within the root
2. When the mesiobuccal canal is ready to receive a small size instrument to determine the working length, introduce a gutta percha cone in the already prepared mesiolingual canal and then the file (e.g. no 10 K-file) in the mesiobuccal canal to measure its length
3. The file is worked with short movements and it is possible to check whether the cone present in the other

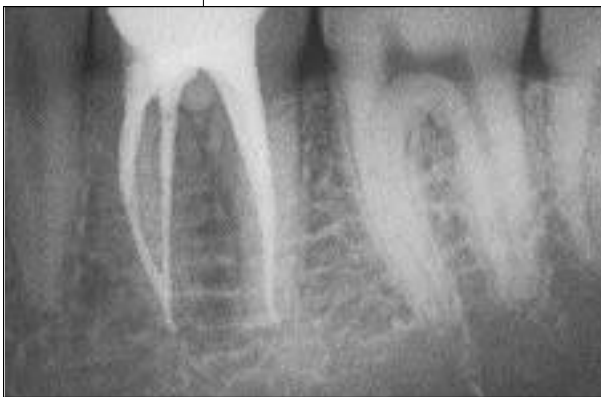

Figure 4a (above):
The mesial root of the lower first molar has two canals leaving the chamber and merging to form a single canal short of the apex

The conical form that is developed in the second canal which has been diagnosed to be confluent with the first

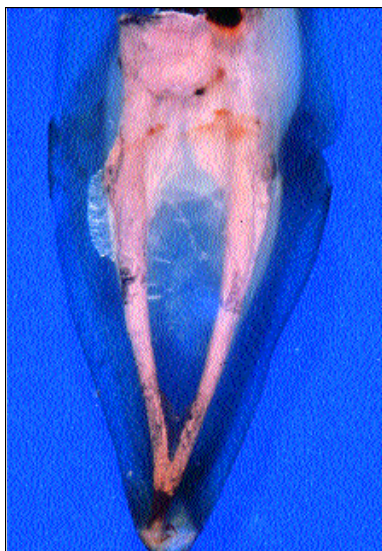


Figure 4b:
The same anatomy is shown in this transparent tooth

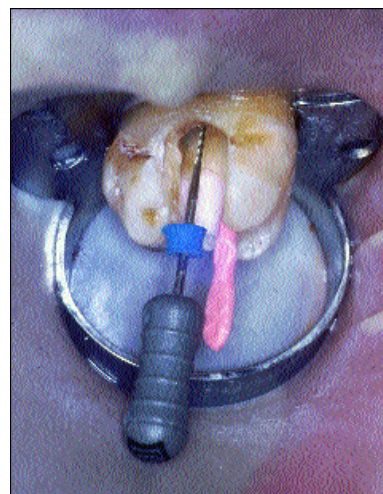
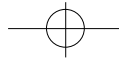


Figure 5:
A gutta percha cone in the mesiobuccal canal (M-B-1) and a no 08 file in the mesiopalatal canal (M-B-2)



Clinical

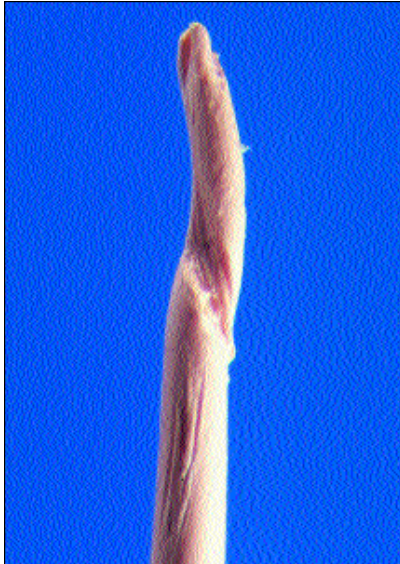

Figure 6:
Gutta percha point
of Figure 5

canal is being displaced
4. The file is withdrawn from the mesiobuccal canal
5. The gutta percha cone is withdrawn from the mesiolingual canal and carefully examined, preferably with a magnifying lens, to search for any grooves, scratches, or folds left by the file (Figures 7a to 7d)

6. Once the presence of the confluence and its distance from the apical foramen has been confirmed, start the cleaning and shaping of the mesiobuccal canal, measuring the working length from the point of confluence. The preparation of this canal is therefore shorter and less marked than the canal already prepared.

The same sequence is suggested in the mesiobuccal root of an upper molar, once the confluence of the two canals to a single foramen has been diagnosed. It is extremely important to perform a moderate enlargement of the mesiopalatal canal, given the natural buccopalatal thinning of this root that is very often present (Figure 8). This is an important consideration to prevent the high risk of stripping.

Obturation of communicating and confluent root canals

When you perform the obturation of the two canals that lie in the same root, and when there is a suspicion of presence of a communication between canals of two different roots (Figures 9a and 9b), you must obturate the two canals simultaneously. This prevents obturation material introduced into the first canal during the compaction procedure from passing into

the second canal through the natural communication, hindering proper filling of the latter.

The approach is different in the following instances:

- Two canals merging to a single foramen
- Two canals with independent apical foramina, which could communicate at any level.

Single foramen

In the case of two canals merging to a single foramen, the endodontist very often recognizes the convergence only when the radiograph of the cone fit is obtained.

Individually, the cones advance unhindered to the desired maximal depth, but when they are placed simultaneously in the various canals, they advance only alternately in the mesial root of a lower molar, for example, if the buccal goes to length, the lingual remains short and vice versa.

This is clear proof that the two canals merge together, and only one of the two cones can be engaged at the apical foramen. The endodontist must decide which of


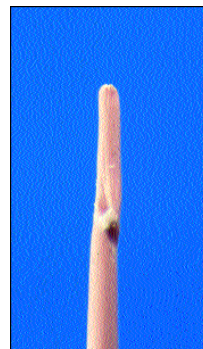
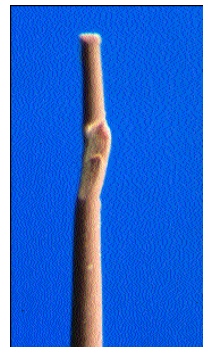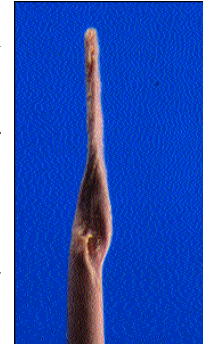
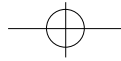


Figure 7a,b,c,d:
Different kinds of
impression left on
the gutta percha
cones by the
instruments



Clinical

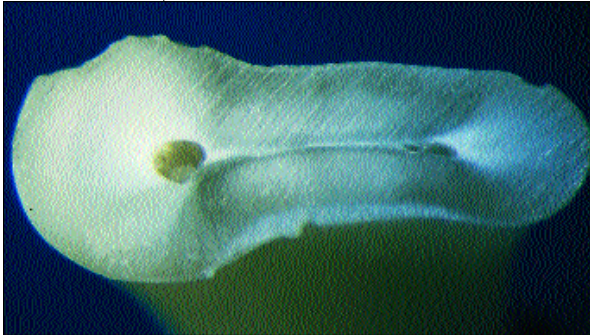

Figure 8:
A cross section of the mesiobuccal root of an upper molar showing how narrow the root is around the M-B-2. (mesio-palatal)

the two is preferable to advance to the apex and this would be the one that has better 'tug-back' and is found in the more easily obturated canal. The other point is then shortened so that it touches

Figure 9a:
Upper first premolar with two roots communicating before they become separate

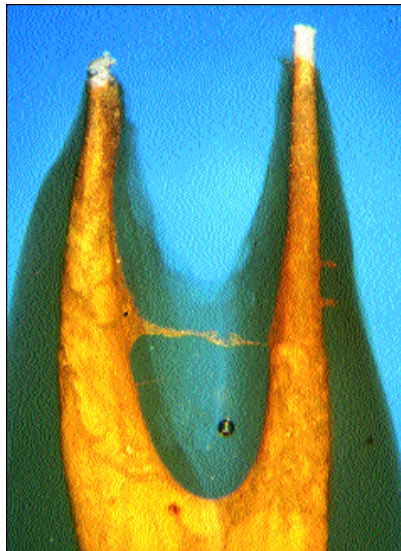
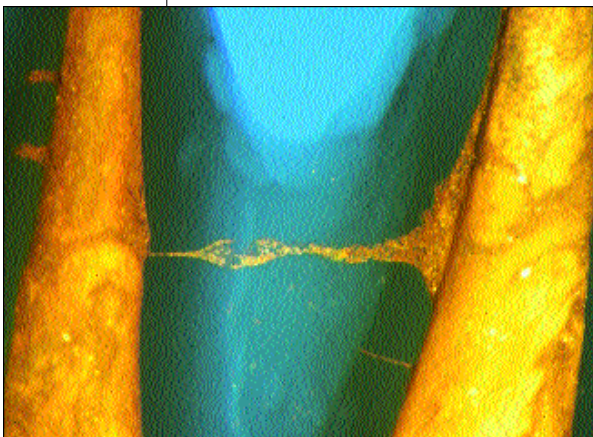


Figure 9b:
Higher magnification of the first premolar

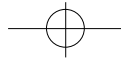


the other cone.

As previously mentioned, nevertheless, it is preferable to diagnose the confluence of two canals at a common apex as early as possible, to prevent unnecessary over-instrumentation and transportation of the apical foramen, which could occur as a result of cleaning and shaping it twice from two different directions. The early diagnosis of a common apex will also prevent the risk of instrument fracture.

At the time of obturation when using the vertical compaction of warm gutta percha technique, each of the two cones must be inserted in its canal (simultaneous introduction) (Figures 10a and 10b) but the compaction must proceed only at the expense of the cone that has been positioned at the foramen (alternate compaction, Figures 10c and 10d). For the sake of convenience, this will be called the first canal. Only after the successful obturation of the apical third of this canal has been confirmed radiographically (the gutta percha has moved apically and the obturation appears well compacted), the operator can proceed with the compaction of the second cone of gutta percha that will be pushed, heated, and compacted against the gutta percha in the first canal (Figures 10e and 10f). If instead of using this important trick, you perform simultaneous downpacking in the two canals, short apical obturation may occur (because the gutta percha of the first canal was not pushed sufficiently apically) and it may then be impossible to advance this mass of gutta percha further apically because the cone in the second canal has already been compacted against the first one (Figure 11).

This technique of downpacking must be used in every case of two merging canals of a single root and more specifically in the mesiobuccal root of upper molars, after you have ascertained the presence of the mesio-palatal canal and its convergence in the mesiobuccal canal, and in the mesial canals of lower molars.



Clinical

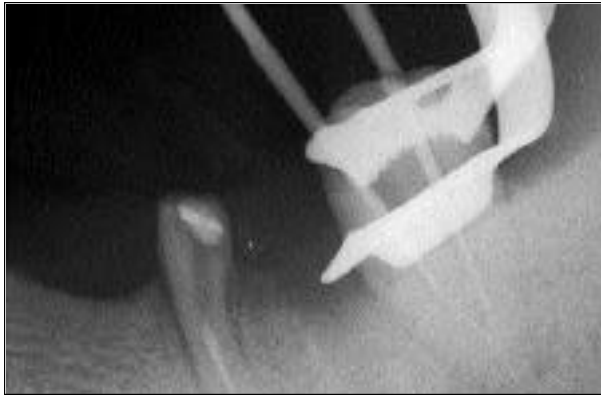

Figure 10a,b:
Fitting the cones. The distal cone is engaging the foramen




Figure 10c,d:
Downpacking of the cone fitted to the apex

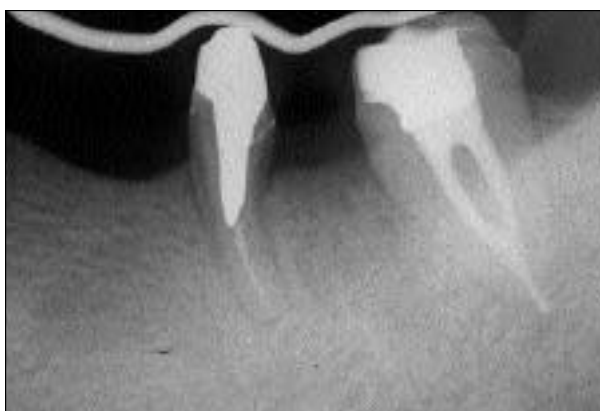

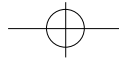


Figure 10f (above):
6-month recall


Figure 10e(right): After the packing is checked radiographically, the other gutta percha cone is packed against the previous one (alternate downpacking)





Clinical

Figure 11: Packing the two gutta percha cones at the same time could result in an inadequate apical seal, losing any further possibility to move the gutta-percha more apically



Independent foramina

In the case of canals that communicate half way along their length (obviously, this communication cannot be diagnosed, but must always be suspected in two canals of the same root), but that flow into independent foramina, you must simultaneously perform not only the introduction of the two cones (simultaneous introduction as in the preceding case), but also their compaction (simultaneous compaction) (Figures 12a-12c). This serves to prevent obstruction, with material that flows into one of the canals and to have simultaneously good apical con-

trol of the obturation of the two distinct foramina. The communication will be filled more or less in equal parts by the gutta percha of the two cones. Packing one canal at the time could lead to an inadequate seal in the second canal, because the material flowing back from the first one will impede the correct introduction and downpacking of the second gutta percha cone.

This technique of obturation must be applied any time you suspect communications, even among roots that appear to be independent on the radiograph.

As previously indicated, it is extremely important to know early whether the two canals of the same root are independent or if there is a convergence of the two canals into a common foramen, since this could influence your approach. For example, the mesiopalatal canal of an upper molar sharing an apex with the mesiobuccal canal can and must be enlarged less with less risk of weakening the root.

There are several methods available to aid this early diagnosis. The easiest and safest way is to try this little trick: place the gutta percha cone in the canal that has just been prepared, and introduce a small instrument (no 10 K-file) into the other canal that you wish to determine whether its apical foramen is independent or not. If the foramen is shared, the file, working in the canal, will leave its impression on the gutta

Figure 12a: Fitting the cones in a lower molar with two canals in a single rooted tooth. The two canals have separate foramina but they could have some communication at any level

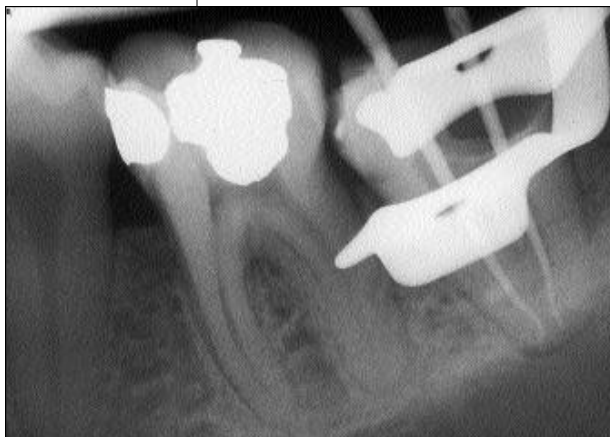
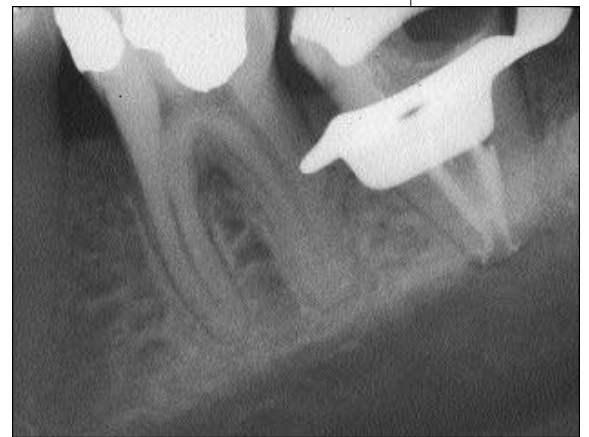
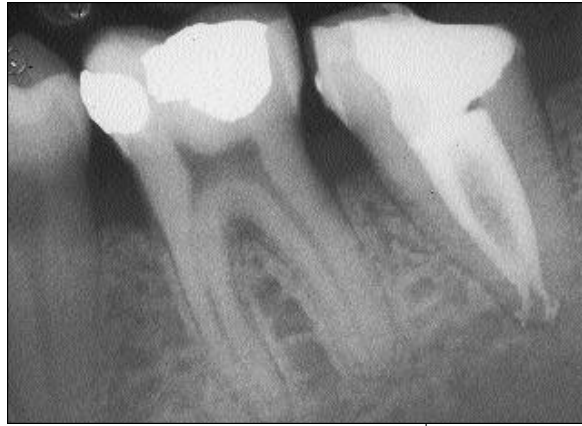Figure 12b: The two cones have been packed at the same time (simultaneous downpacking). The communication between the two canals is quiet evident



Clinical

Figure 12c:
The postoperative film shows the communication in the middle one third



percha cone. In this way, it is possible to determine whether there is a confluence and at how many millimeters from the foramen it is located.


In this author's opinion, the introduction of two instruments into two canals with the aim of demonstrating a possible confluence is not free of risks or false indicators. If the canals are narrow, you can easily fracture one of the two instruments. If a canal has already been prepared and can receive a larger instrument, the small instrument introduced into the other canal can pass between the spirals of the preceding instrument and the dentinal walls, arriving equally at the foramen and conceal the tactile sensation of the confluence.

Another very safe and precise method requires the use of an electronic apex locator (EAL). After the first canal has been prepared, the operator checks the working length of the second canal with the use of the EAL. Then repeat the operation leaving the last apical file inserted in the first canal at the foramen.

If the working length of the second canal this time appears to be shorter by several millimeters, this would indicate that the second canal is sharing the foramen with the first one and the communication is at the same distance from the common

foramen.

Conclusions

An awareness of the presence of two canals in a single root is very important today, when using rotary nickel titanium instruments. The main disadvantage of rotary instrumentation is the risk of instrument fracture. It is well known that the introduction of a rotary instrument in the common part of two canals joining together is one of the main causes of fracture. It is therefore crucial to fully understand and show the maximum respect to this kind of root canal configuration in order not to transport the foramen, not to strip the root and not to fracture an endodontic instrument. Furthermore, this increased awareness of the anatomy of the root canal system will help us fill our canals with a perfect apical seal, thus guaranteeing long term success. 

References

- Berutti E (1990). Il rispetto dell'apice dentario nella strumentazione dei canali confluenti. *G It Endo* **1**: 6-21
- Castellucci A (1993). *Endodonzia*, Bologna, ed; 371
- Castellucci A (1993). *Endodonzia*, Bologna, ed; 492-6
- Castellucci A, Becciani R (1994). I canali comunicanti e i canali confluenti: considerazioni cliniche e suggerimenti pratici. *G It Endod* **3**: 90-6
- Ruddle JC (1994). Endodontic Canal Preparation: Breakthrough cleaning and shaping strategies, *Dentistry Today*, February
- Weine FS (1982). *Endodontic Therapy*, 3rd ed 207-55