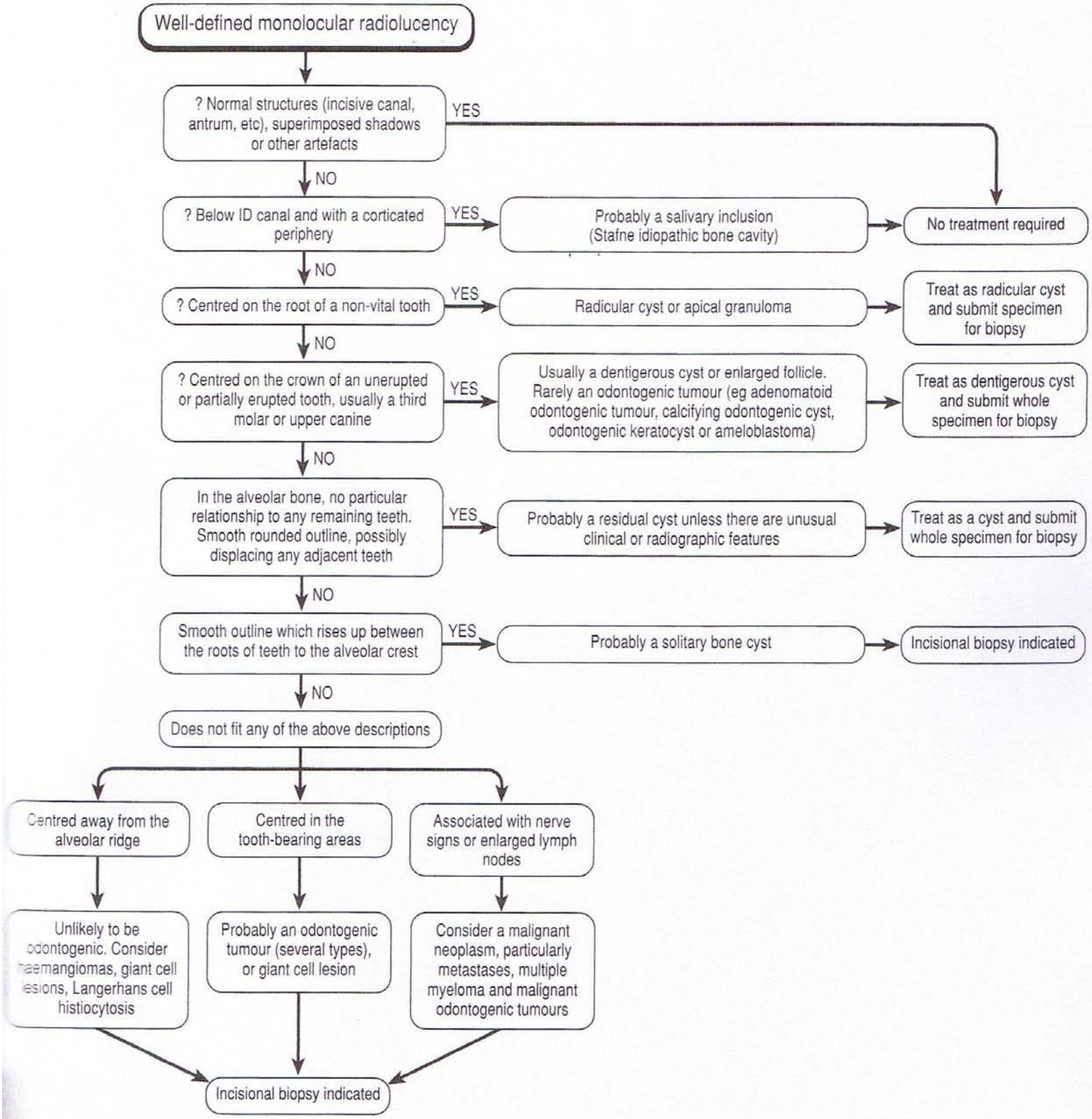
Well-defined monolocular radiolucency
? Normal structures (incisive canal, antrum, etc), superimposed shadows or other artefacts
YES
NO
? Below ID canal and with a corticated periphery
YES
Probably a salivary inclusion (Stafne idiopathic bone cavity)
No treatment required
NO
? Centred on the root of a non-vital tooth
YES
Radicular cyst or apical granuloma
Treat as radicular cyst and submit specimen for biopsy
NO
? Centred on the crown of an unerupted or partially erupted tooth, usually a third molar or upper canine
YES
Usually a dentigerous cyst or enlarged follicle. Rarely an odontogenic tumour (eg adenomatoid odontogenic tumour, calcifying odontogenic cyst, odontogenic keratocyst or ameloblastoma)
Treat as dentigerous cyst and submit whole specimen for biopsy
NO
In the alveolar bone, no particular relationship to any remaining teeth. Smooth rounded outline, possibly displacing any adjacent teeth
YES
Probably a residual cyst unless there are unusual clinical or radiographic features
Treat as a cyst and submit whole specimen for biopsy
NO
Smooth outline which rises up between the roots of teeth to the alveolar crest
YES
Probably a solitary bone cyst
Incisional biopsy indicated
NO
Does not fit any of the above descriptions
Centred away from the alveolar ridge
Centred in the tooth-bearing areas
Associated with nerve signs or enlarged lymph nodes
Unlikely to be odontogenic. Consider haemangiomas, giant cell lesions, Langerhans cell histiocytosis
Probably an odontogenic tumour (several types), or giant cell lesion
Consider a malignant neoplasm, particularly metastases, multiple myeloma and malignant odontogenic tumours
Incisional biopsy indicated