

# Evaluation of Apical Filling after Root Canal Filling by 2 Different Techniques

Tamer Tasdemir, DDS, PhD; Cemal Yesilyurt, DDS, PhD;  
Kadir Tolga Ceyhanli, DDS; Davut Celik, DDS; Kursat Er, DDS, PhD

## Contact Author

Dr. Tasdemir  
Email: [tamertd72@yahoo.com](mailto:tamertd72@yahoo.com)



## ABSTRACT

**Objective:** To determine the percent gutta-percha-filled area in the apical third of root canals after filling with 2 different root filling techniques.

**Materials and Methods:** Thirty extracted human lower premolars were instrumented with ProTaper rotary files (Dentsply Maillefer) and then randomly divided into 2 groups of 15 teeth each. The first group was filled using the single-cone technique with a tapered gutta-percha cone. The second group was filled with the lateral condensation technique. Horizontal sections were cut 2 and 4 mm from the apical foramen of each tooth. Photomicrographs of the apical surface of each cross-section were obtained at magnification  $\times 40$ . Digital image analysis was used to measure the overall area of the canal and the aggregate area occupied by gutta-percha; from these values, the percent gutta-percha-filled area was calculated. The data were compared by *t* test.

**Results:** The single-cone technique produced significantly greater percent gutta-percha-filled area at 2 mm from the apex ( $p = 0.046$ ), but there was no significant difference between the techniques at 4 mm from the apex ( $p = 0.17$ ).

**Conclusions:** These results suggest that the single-cone technique with tapered gutta-percha cones may yield better filling (measured as the percent gutta-percha-filled area) than the lateral condensation technique, at a level 2 mm from the apex.

For citation purposes, the electronic version is the definitive version of this article: [www.cda-adc.ca/jcda/vol-75/issue-3/201.html](http://www.cda-adc.ca/jcda/vol-75/issue-3/201.html)

The purpose of root canal obturation is to create a complete, 3-dimensional seal of the root canal system, with the aim of preventing recurrence of bacterial infection. By hindering microleakage between the root canal and the periapical tissues, this procedure should also deprive any surviving microorganisms of nutrients and prevent toxic bacterial products from entering the periapical tissues.<sup>1-4</sup>

Numerous materials and techniques have been developed for filling root canals. It has been reported that the quality of adaptation

between the surface of the root canal and the gutta-percha is uncertain in fillings created by the lateral condensation technique,<sup>5</sup> even though this method has the advantage of creating a tight apical seal through compression of several gutta-percha cones with spreaders. However, canal curvature and other anatomic features may prevent achievement of this tight seal.<sup>6</sup> In addition, metal spreaders must be placed in the canal several times during the filling process for lateral compaction of the gutta-percha, but practitioners may have difficulty achieving the required balance between

optimal compression of the gutta-percha and avoidance of root fracture through application of too much pressure.<sup>7</sup>

Both the amount of sealer used to fill the canal and the ratio of sealer to gutta-percha affect the long-term seal of a root filling,<sup>8</sup> because the sealers become variably soluble after a certain time,<sup>9,10</sup> whereas gutta-percha is not subject to such dimensional degradation.<sup>11</sup> Given the difference in properties of these materials, the preferred filling techniques are those that minimize the amount of the sealer component and hence the ratio of sealer to gutta-percha.

A recently introduced configuration of gutta-percha point has the same taper as the final ProTaper Finisher instrument (Dentsply Maillefer, Ballaigues, Switzerland). The manufacturer claims that a root canal can be filled rapidly and completely with a single, correspondingly tapered gutta-percha point of appropriate size, after preparation with ProTaper files.

One of the methods of evaluating the quality of root-filling is to determine the area of gutta-percha in the filling relative to the total cross-sectional area of the prepared canal from transverse sections obtained at several levels of the filled root.<sup>1,5,12-16</sup> The ratio between these 2 values can be expressed as a percentage, the magnitude of which shows how much of the residual space is available to sealer or voids. The smaller the ratio, the higher the quality of the filling.<sup>12</sup>

The purpose of this in vitro study was to compare the percent gutta-percha-filled area at 2 levels in the apical third of root canals, after filling by 2 different techniques.

## Materials and Methods

### *Specimen Selection and Preparation*

Thirty single-rooted lower premolars of similar dimensions were used for this study. Images obtained with digital radiographic equipment (Schick Technologies Inc., Long Island City, N.Y.) in the buccal and proximal planes were used to confirm that only teeth with a single canal were included in the study. All teeth had negligible root curvature (0°–10°),<sup>17</sup> and teeth with calcified canals or large apical foramina were excluded. The teeth were cleaned of debris and soft-tissue remnants and were stored in physiological saline at 4°C until required.

The teeth were sectioned at the cemento-enamel junction with a multipurpose bur in a high-speed handpiece with continuous water spray, and the roots were adjusted to a length of about 18 mm. A size 15 K-type file was used to establish apical patency. When the tip of the file was visible flush with the apical foramen, its length was recorded; the working length was defined to be 1 mm less than the measured length. The root canal system of each tooth was instrumented using ProTaper rotary files; the

crown-down technique was used, with a gentle in-and-out motion, according to manufacturer's instructions.

A shaping file (S1) was used first and was worked apically to 2 mm short of the working length. An SX file was then used until resistance was encountered (typically 4 to 5 mm from the working length), followed by S1 and S2 files to the full working length for shaping the coronal two-thirds of the canal. The apical third was finished by using F1, F2 and F3 files sequentially to the working length, with only one pecking motion for each instrument. Once a particular instrument had been negotiated to the end of the canal and could be rotated freely, it was removed.

Each root canal was irrigated with 2 mL of 2.5% NaOCl solution after each instrument and was kept flooded with irrigant during the instrumentation phase. The irrigant was delivered via a 27-gauge blunt needle that was inserted into the canal until slight resistance was felt. When instrumentation was complete, a final irrigation was applied using 5 mL of solution, after which the canal was dried with size F3 absorbent paper points (Dentsply Maillefer). The prepared roots were randomly divided into 2 groups of 15 teeth each.

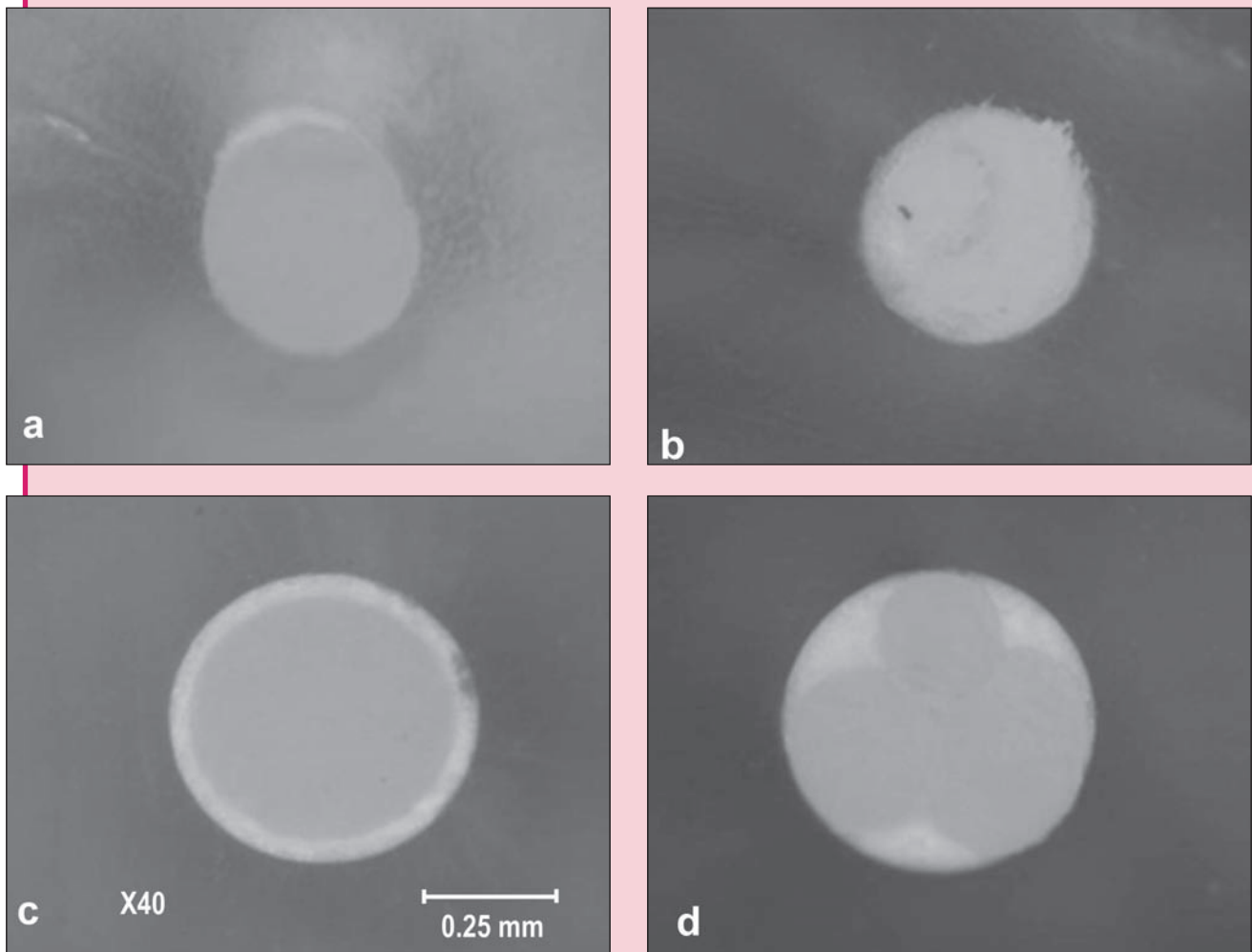
### *Filling Techniques*

#### *Single-Cone Technique*

An F3 ProTaper gutta-percha cone (Dentsply Maillefer) was selected, and its apical portion was adjusted as necessary with a scalpel blade until tugback was achieved. A size 30 Lentulo spiral (Mani, Tochigi-ken, Japan) was placed in a slow-speed handpiece and coated with AH Plus root canal sealer (Dentsply Maillefer). The Lentulo spiral was introduced into the root canal to a location 3 to 4 mm short of the working length and then slowly withdrawn from the canal, with continuing rotation. The gutta-percha point was coated with sealer and was seated at the working length. Excess gutta-percha was removed with a hot instrument.

#### *Lateral Condensation Technique*

An ISO size 30 gutta-percha cone (DiaDent, Choong Chong Buk-Do, Korea) was trimmed to give tugback at working length. After the sealer was placed in the canal with the Lentulo spiral, as described above, the master cone was coated with sealer and inserted slowly into the canal to the full working length. The first finger spreader (size 25; Medin, Nové Město na Moravě, Czech Republic) was inserted between the master cone and the canal wall to within 1 mm of the working length. Cold lateral condensation was performed using size 25, 20 and 15 accessory gutta-percha points until the canal was completely filled. The filling was judged to be complete when a size 15 finger spreader could not penetrate beyond the coronal third of the canal. A heated instrument was used



**Figure 1:** Representative cross-sections of specimens: (a) section obtained 2 mm from the apex in tooth filled by single-cone method, (b) section obtained 2 mm from the apex in tooth filled by lateral condensation method, (c) section obtained 4 mm from the apex in tooth filled by single-cone method, and (d) section obtained 4 mm from the apex in tooth filled by lateral condensation method.

to remove excess coronal gutta-percha. The same operator prepared and filled the canals for all teeth (T.T.).

Once filling was complete, radiographs of all specimens were obtained in the buccal and proximal planes to check the adequacy of filling with regard to homogeneity and apical extension. All specimens had the radiographic appearance of well-compacted fillings extending to 1 mm short of the apical foramen. The specimens were then stored for 7 days at 37°C and 100% humidity, to allow complete setting of the sealer. Specimens with any sign of failure were excluded from subsequent analysis and were replaced to maintain 15 specimens in each group.

#### **Cross-Section of Root Filling**

Each root was mounted for cutting with a low-speed saw (Micracut 125, Metkon, Bursa, Turkey). Copious

cold-water irrigation was provided during horizontal sectioning at 2 and 4 mm from the apex. A digital camera was used to obtain colour photographs of the sections at  $\times 40$  magnification under a polarizing optic microscope (Eclipse ME 600, Nikon, Kogaku, Japan) (Fig. 1). The micrographs were then analyzed by computer, using the Adobe Photoshop CS2 9.0 image program (Adobe Systems Incorporated, San Jose, Calif.). The area occupied by the gutta-percha and that enclosed by the total canal circumference were measured in terms of pixel counts. The ratio of these 2 values was calculated as percentage, and the differences in ratios between the 2 groups at 2 and 4 mm from the apex were analyzed using a *t* test. The level of significance was set at  $\alpha = 0.05$ .

**Table 1** Mean gutta-percha filled area 2 and 4 mm from the apex, expressed as percentage of total root canal area

Filling technique	Level of section; mean gutta-percha-filled area (%) ± SD	
	2 mm from apex	4 mm from apex
Single cone	83.9 ± 12.1	76.9 ± 9.5
Lateral condensation	72.7 ± 16.9	82.9 ± 13.3
<i>p</i> value <sup>a</sup>	0.046	0.17

SD= standard deviation.

<sup>a</sup>The level of significance was set  $\alpha = 0.05$ .

## Results

At the 2-mm level, the single-cone technique yielded significantly higher percent gutta-percha-filled area than the lateral condensation technique ( $p = 0.046$ ) (Table 1). At 4 mm, the percent gutta-percha-filled area was greater with the lateral condensation method, but this difference was not significant ( $p = 0.17$ ).

## Discussion

Prepared root canals are usually obturated with solid core material and a sealer. The long-term seal provided by such root fillings has been considered essential to success. The sealer can fill in imperfections, thus improving the filling capacity of the gutta-percha.<sup>11</sup> However, sealers are subject to problems such as shrinkage and solubility that are incompatible with long-term sealing. If dissolution occurs, either at the interface between the gutta-percha and the dentin wall or between the gutta-percha points themselves, leakage may occur within the space originally taken up by sealer.<sup>10</sup> Consequently, the goal of various filling techniques is to maximize the amount of gutta-percha applied and minimize the amount of sealer. Further research is needed to determine the in vivo biological significance of the percent gutta-percha-filled area in the apical third.

The gutta-percha content obtained with the thermo-mechanical, vertical and lateral condensation techniques have been reported, but there have been few studies of other techniques. Silver and others<sup>18</sup> recently reported that System B root fillings contained more than 90% gutta-percha. Gencoglu<sup>19</sup> found that core techniques (Thermafil, JS Quick-Fill and Soft Core) produced higher gutta-percha content than the Microseal, System B and lateral condensation techniques. Wu and others<sup>20</sup> found that the percentage of sealer-coated canal perimeter in the apical and middle regions was significantly greater for canals filled by the single-cone method than for those filled by the lateral or vertical condensation technique. However, at 6 mm from the apex, the percentage of sealer-coated canal perimeter was significantly greater in the lateral condensation group. Hembrough and others<sup>21</sup> reported that after using ProFile .06 rotary instruments to

shape the canal, they obtained similar-quality obturation with master cones of 3 different tapers with the lateral condensation technique.

Single-cone filling of root canals has recently been popularized through the introduction of cones with greater tapering, which closely match the geometry of rotary instrumentation systems. Gordon and others<sup>14</sup> reported similar percent gutta-percha-filled area when they filled curved canals using .06 tapered instruments with the single-cone and lateral condensation techniques. However, they also found that the single-cone technique was faster than the lateral condensation method. Hörsted-Bindslev and others<sup>22</sup> reported that the lateral condensation technique did not differ from the single-cone technique with respect to the radiographic quality of the root filling. Conversely, Monticelli and others<sup>23</sup> reported that neither of 2 contemporary single-cone techniques ensured a durable apical seal against bacterial leakage, whereas a vertical compaction technique for applying warm gutta-percha created such a seal.

In the present study, the canals filled by the single-cone technique contained more gutta-percha at 2 mm from the apex than those filled by the lateral condensation technique, whereas the extent of filling was similar for the sections at the 4-mm level. However, standard deviation for the lateral condensation group was appreciably greater at both levels, implying greater predictability with the single-cone method. The greater amount of gutta-percha in the sections from the 2-mm level filled by the single-cone technique is understandable, given that the sole gutta-percha point used with this method was the same diameter and taper as the last instrument used during canal preparation. A previous study<sup>24</sup> showed that the well-adapted single cone method provides adequate filling when accompanied by canal sealer, if preparation yields a circular canal. It was difficult to standardize the total amount of sealer on the gutta-percha points because 6–8 additional points were used in the lateral condensation method, and the tip of every point was lightly coated with sealer. Thus, the total amount of sealer introduced into the canals by the gutta-percha points was greater in the lateral condensation group than in the single-cone

group. This differential amount of sealer may have affected the results reported here.

The teeth used in this study were straight, with single canals that could easily be prepared in a standardized manner with rotary instruments. However, the anatomy of most posterior teeth is much more complex, with curves, isthmuses and fins that are less amenable to rotary canal preparation. Further study is needed to determine whether using file-matched gutta-percha cones to fill teeth with more complex anatomy results in a comparably acceptable seal. The single-cone filling technique is simpler than the lateral condensation technique, which means the operator is less subject to fatigue, but such considerations must be subordinate to the primary goal of achieving the best prognosis for the patient.

## Conclusions

Under the experimental conditions of the present study, the single-cone filling technique with matched-taper gutta-percha cones yielded greater percent gutta-percha-filled area than the lateral condensation method at 2 mm from the apex. ♦

## THE AUTHORS



**Dr. Tasdemir** is an assistant professor in the department of endodontics, faculty of dentistry, Karadeniz Technical University, Trabzon, Turkey.



**Dr. Yesilyurt** is an assistant professor in the department of operative dentistry, faculty of dentistry, Karadeniz Technical University, Trabzon, Turkey.



**Dr. Ceyhanli** is a research assistant in the department of endodontics, faculty of dentistry, Karadeniz Technical University, Trabzon, Turkey.



**Dr. Celik** is a research assistant in the department of endodontics, faculty of dentistry, Karadeniz Technical University, Trabzon, Turkey.



**Dr. Er** is an assistant professor in the department of endodontics, faculty of dentistry, Karadeniz Technical University, Trabzon, Turkey.

**Acknowledgements:** The authors thank Prof. Gamze Çan, School of Medicine, University of Karadeniz, Technical, Trabzon, Turkey, for his help with the statistical analyses.

**Correspondence to:** Dr. Tamer Tasdemir, Karadeniz Teknik Üniversitesi Dis Hekimliği Fakültesi 61080, Trabzon, TURKEY.

The authors have no declared financial interests in any company manufacturing the types of products mentioned in this article.

This article has been peer reviewed.

## References

- Cathro PR, Love RM. Comparison of MicroSeal and System B/Obtura II obturation techniques. *Int Endod J* 2003; 36(12):876–82.
- Bailey GC, Ng YL, Cunnington SA, Barber P, Gulabivala K, Setchell DJ. Root canal obturation by ultrasonic condensation of gutta-percha. Part II: An in vitro investigation of the quality of obturation. *Int Endod J* 2004; 37(10):694–8.
- Jarrett IS, Marx D, Covey D, Karmazin M, Lavin M, Gound T. Percentage of canals filled in apical cross sections — an in vitro study of seven obturation techniques. *Int Endod J* 2004; 37(6):392–8.
- Economides N, Kokorikos I, Kolokouris I, Panagiotis B, Gogos C. Comparative study of apical sealing ability of a new resin-based root canal sealer. *J Endod* 2004; 30(6):403–5.
- Gencoglu N, Garip Y, Bas M, Samani S. Comparison of different gutta-percha root filling techniques: Thermafil, Quick-Fill, System B, and lateral condensation. *Oral Surg Oral Med Oral Pathol Oral Radiol Endod* 2002; 93(3):333–6.
- Guess GM, Edwards KR, Yang ML, Iqbal MK, Kim S. Analysis of continuous-wave obturation using a single-cone and hybrid technique. *J Endod* 2003; 29(8):509–12.
- Wu MK, van der Sluis LW, Wesselink PR. A 1-year follow-up study on leakage of single-cone fillings with RoekoRSA sealer. *Oral Surg Oral Med Oral Pathol Oral Radiol Endod* 2006; 101(5):662–7.
- Wu MK, van der Sluis LW, Wesselink PR. A preliminary study of the percentage of gutta-percha-filled area in the apical canal filled with vertically compacted warm gutta-percha. *Int Endod J* 2002; 35(6):527–35.
- Tronstad L, Barnett F, Flax M. Solubility and biocompatibility of calcium hydroxide-containing root canal sealers. *Endod Dent Traumatol* 1988; 4(4):152–9.
- Kontakiotis EG, Wu MK, Wesselink PR. Effect of sealer thickness on long-term sealing ability: a 2-year-follow-up study. *Int Endod J* 1997; 30(5):307–12.
- Wu MK, Fan B, Wesselink PR. Diminished leakage along root canals filled with gutta-percha without sealer over time: a laboratory study. *Int Endod J* 2000; 33(2):121–5.
- Wu MK, Kast'akova A, Wesselink PR. Quality of cold and warm gutta-percha fillings in oval canals in mandibular premolars. *Int Endod J* 2001; 34(6):485–91.
- Ardila CN, Wu MK, Wesselink PR. Percentage of filled canal area in mandibular molars after conventional root-canal instrumentation and after a noninstrumentation technique (NIT). *Int Endod J* 2003; 36(9):591–8.
- Gordon MP, Love RM, Chandler NP. An evaluation of .06 tapered gutta-percha cones for filling of .06 taper prepared curved root canals. *Int Endod J* 2005; 38(2):87–96.
- van der Sluis LW, Wu MK, Wesselink PR. An evaluation of the quality of root fillings in mandibular incisors and maxillary and mandibular canines using different methodologies. *J Dent* 2005; 33(8):683–8.
- De-Deus G, Gurgel-Filho ED, Magalhaes KM, Coutinho-Filho T. A laboratory analysis of gutta-percha-filled area obtained using Thermafil, System B and lateral condensation. *Int Endod J* 2006; 39:378–83.
- Schneider SW. A comparison of canal preparations in straight and curved root canals. *Oral Surg Oral Med Oral Pathol* 1971; 32(2):271–5.
- Silver GK, Love RM, Purton DG. Comparison of two vertical condensation obturation techniques: Touch 'n Heat modified and System B. *Int Endod J* 1999; 32(4):287–95.
- Gencoglu N. Comparison of 6 different gutta-percha techniques (part II): Thermafil, JS Quick-Fill, Soft Core, Microseal, System B, and lateral condensation. *Oral Surg Oral Med Oral Pathol Oral Radiol Endod* 2003; 96(1):91–5.
- Wu MK, Ozok AR, Wesselink PR. Sealing distribution in root canals obturated by three techniques. *Int Endod J* 2000; 33(4):340–5.
- Hembrough MW, Steiman HR, Belanger KK. Lateral condensation in canals prepared with nickel titanium rotary instruments: an evaluation of the use of three different master cones. *J Endod* 2002; 28(7):516–9.
- Hörsted-Bindslev P, Andersen MA, Jensen MF, Nilsson JH, Wenzel A. Quality of molar root canal fillings performed with the lateral compaction and the single-cone technique. *J Endod* 2007; 33(4):468–71.
- Monticelli F, Sadek FT, Schuster GS, Volkman KR, Looney SW, Ferrari M, and others. Efficacy of two contemporary single-cone filling techniques in preventing bacterial leakage. *J Endod* 2007; 33(3):310–3.
- Kardon BP, Kuttler S, Hardigan P, Dorn SO. An in vitro evaluation of the sealing ability of a new root-canal-obturation system. *J Endod* 2003; 29(10):658–61.