

# External Cervical Resorption: A Review

Shanon Patel, BDS, MSc,\* Shalini Kanagasingham, BDS, MFDS,\*<sup>†</sup>  
and Thomas Pitt Ford, BDS, PhD, FDS\*

## Abstract

External cervical resorption (ECR) is the loss of dental hard tissue as a result of odontoclastic action; it usually begins on the cervical region of the root surface of the teeth. The etiology, predisposing factors, diagnosis, and management of ECR are reviewed. Effective management and appropriate treatment can only be carried out if the true nature and exact location of the ECR lesion are known. The role of cone beam computed tomography as a diagnostic adjunct for the management of ECR is also reviewed. (*J Endod* 2009;35:616–625)

## Key Words

Cone beam computed tomography, diagnosis, external cervical resorption

---

From the \*Endodontic Postgraduate Unit, King's College London Dental Institute, London, UK and the <sup>†</sup>National University of Malaysia, Kuala Lumpur, Malaysia.

Address requests for reprints to Shanon Patel, 45 Wimpole Street, London, W1G 8SB, UK. E-mail address: shanonpatel@hotmail.com.

0099-2399/\$0 - see front matter

Published by Elsevier on behalf of American Association of Endodontists.

doi:10.1016/j.joen.2009.01.015

Root resorption is the loss of hard dental tissue (ie, cementum and dentin) as a result of odontoclastic action (1). Physiologic root resorption associated with primary teeth is desirable because it results in exfoliation of the teeth, thereby allowing eruption of the permanent successors. However, root resorption of permanent dentition is usually unfavorable because it might result in irreversible damage and/or eventual tooth loss.

Root resorption might be classified by its location in relation to the root surface, ie, internal or external resorption. External root resorption can be further classified into surface resorption, external inflammatory resorption, external replacement resorption, external cervical resorption, and transient apical breakdown (1).

One of the least understood of the types of external resorption is external cervical resorption (ECR). This form of external resorption has been described at length by Heithersay (2–5), who preferred the term *invasive cervical resorption*, which describes its invasive and aggressive nature. Other terms used to describe ECR include odontoclastoma (6), peripheral cervical resorption (7), extracanal invasive resorption (8), supraosseous extracanal invasive resorption (9), peripheral inflammatory root resorption (10), and subepithelial external root resorption (11). In this article it will be described as ECR, which reflects its starting point on the tooth.

ECR usually occurs immediately below the epithelial attachment of the tooth at the cervical region (1, 2, 12). ECR defects can be difficult to diagnose and manage. This article will review the etiology, diagnosis, and management of ECR.

## Etiology

The exact cause of ECR is poorly understood. Cementum is considered to protect the underlying root dentin from being resorbed. It is broadly accepted that damage to or deficiency of this protective cementum layer below the epithelial attachment exposes the root surface to osteoclasts, which then resorb the dentin (10, 13). The anatomic profile of the cemento-enamel junction might also predispose this region to ECR. Microscopic analysis of the cervical region of teeth has shown that there appears to be frequent gaps of cementum in this area, leaving the underlying mineralized dentin exposed and vulnerable to osteoclastic root resorption (14). The pulp tissue plays no role in the etiology of ECR (2, 9, 12).

Several etiologic factors have been suggested that might damage the cervical region of the root surface and therefore initiate ECR (Table 1). These include dental trauma (2, 15), orthodontic treatment (2, 16), intracoronary bleaching (2, 17), periodontal therapy (2, 11), and idiopathic etiology (18, 19).

There appear to be polarized views on the nature of the resorptive process. Some have regarded it as a purely inflammatory reaction (17, 20). ECR has been described as an “aseptic resorptive process, which may on occasions become secondarily invaded with microorganisms” (15). Others have suggested that microorganisms from either the gingival sulcus (11, 21, 22) or the pulp space and dentinal tubules in teeth with necrotic pulps provide the necessary stimulus to sustain ECR lesions.

Heithersay (2) investigated the potential predisposing factors in 257 ECR lesions in 222 patients. He concluded that a history of orthodontic treatment, dental trauma, and bleaching were the most commonly associated predisposing factors for ECR (Table 1).

## Orthodontic Treatment

Excessive orthodontic forces at the cervical region of the tooth might result in tissue necrosis adjacent to exposed root dentin. This might result in mononuclear precursor cells being stimulated to differentiate into odontoclasts, which are attracted to and resorb the exposed root dentin (3).

**TABLE 1.** Predisposing Factors for ECR

Predisposing factors
<ul style="list-style-type: none"> <li>● Orthodontics</li> <li>● Trauma</li> <li>● Intracoronal bleaching</li> <li>● Surgical procedures</li> <li>● Periodontal therapy</li> <li>● Other factors: bruxism, intracoronal restorations, developmental defects, systemic diseases</li> </ul>

Heithersay (3) found that orthodontic treatment alone was a potential predisposing factor for 24.1% of teeth with ECR. Diagnosis of ECR ranged from 1½ years–33 years after the removal of appliances. There appeared to be no correlation between the orthodontic technique used and the development of ECR. Teeth most commonly affected by ECR were maxillary canines, maxillary incisors, and mandibular first molars. A study by Cwyk et al (23) recorded only 1 case of ECR (1.5% of teeth) out of 87 patients who had undergone orthodontic treatment and were 20–25 years old. The lower incidence of ECR associated with orthodontic treatment in this study might be due to only anterior teeth being assessed, different type of orthodontic treatment carried out, and/or a shorter follow-up period compared with the study by Heithersay (3).

It is possible that Class II elastics used on the abovementioned teeth during orthodontic fixed appliance treatment might result in increased forces resulting in ECR. However, the question arises as to why ECR does not occur during or immediately after orthodontic treatment but usually several years after orthodontic treatment (and therefore the stimulating factor) has ceased. It is interesting to note that surface resorption generated by excessive orthodontic forces resulting in blunting of the root apices is normally detected during the course of orthodontic treatment and not years or decades later (24). Mandibular molars might be rendered prone to resorption as a result of the placement of orthodontic bands that might damage the vulnerable cemento-enamel region of the tooth.

It is likely that a combination of factors including orthodontic treatment will ultimately result in the predisposition to ECR. This is supported by Hines (25), who reported that resorption of previously avulsed or partially avulsed teeth occurred more readily during and after orthodontic treatment.

Heithersay (3) found that the most commonly affected teeth were maxillary canines, maxillary incisors, and mandibular molars. It is interesting to note that mandibular incisors and canines are not affected by ECR in the same frequency as their maxillary counterparts.

## Trauma

ECR is a recognized complication of luxation and avulsion injuries (3, 11, 26). Heithersay (3) confirmed that dental trauma was a major potential predisposing factor (15.1% of teeth). This increased to 25.7%

of teeth when other contributory factors (for example, intracoronal bleaching, orthodontic treatment) were included. Bleaching was an associated factor in 7.4% of all ECR cases with a history of trauma. Maxillary central incisors were the teeth most frequently traumatized that subsequently developed ECR in the study. This is consistent with their location in the dental arch and associated susceptibility to trauma (27, 28).

Dental trauma might cause ECR indirectly. Intruded primary incisors might cause developmental defects in the cervical region on the unerupted permanent successor teeth as a result of direct trauma of the root apices on the unerupted successor. The use of splints (especially interdental wiring) might also potentially damage the cemento-enamel junction and therefore predispose to ECR (4).

To minimize damage to the cemento-enamel junction, it is advisable to carefully reposition luxated teeth.

Andreasen and Andreasen (29) recommend the application of orthodontic forces to reposition luxated teeth rather than forcibly moving the tooth because this might result in further damage to the cemento-enamel junction and result in ECR. This is especially advantageous when dealing with permanent teeth with completed roots because spontaneous re-eruption is unlikely to take place. Andreasen and Andreasen found that orthodontic extrusion seems to produce better marginal bone healing as compared with surgical repositioning. Heithersay (4) favors placement of composite resin onto the crown of the tooth to allow force application away from the sensitive cemento-enamel junction when surgically repositioning teeth.

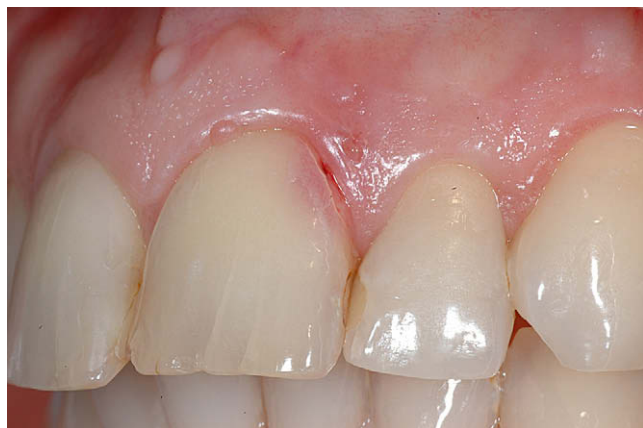Trauma as a predisposing factor might be underestimated because patients often might not be able to recall trauma to their dentition. This is especially so if the traumatic incident occurred several years before ECR was diagnosed. It is also likely that orthodontic treatment in combination with trauma results in most ECR cases.

## Intracoronal Bleaching

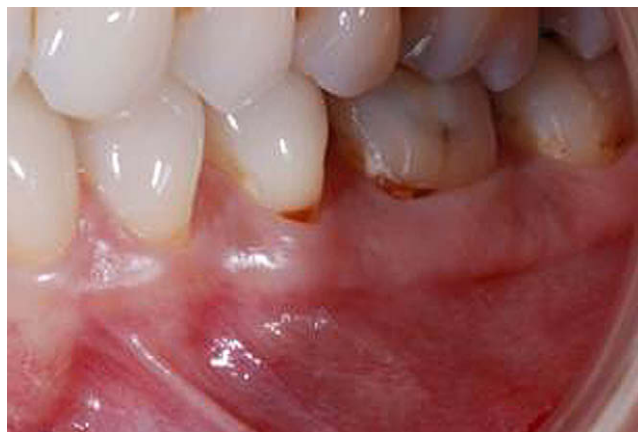Intracoronal bleaching has been widely documented as a predisposing factor for ECR (2, 15, 17, 20, 26, 30). Heithersay (3) reported intracoronal bleaching as a sole and associated predisposing factor for ECR in 3.9% and 13.6% of cases, respectively. Several suggestions have been put forward for the actual mechanism by which intracoronal bleaching might result in ECR. Rotstein et al (31) demonstrated that the presence of cemental defects at the cemento-enamel junction could result in hydrogen peroxide from the pulp chamber of root-filled teeth escaping to the external tooth surface via dentinal tubules during intracoronal bleaching with 30% hydrogen peroxide. It has been suggested that hydrogen peroxide might denature dentin and provoke an immunologic response (26, 32). In addition, the pH at the root surface of teeth is reduced to about 6.5 by intracoronal placement of a “walking bleach” paste (33). This slightly acidic environment is known to enhance osteoclastic activity, which might result in ECR (34).

**TABLE 2.** Common Clinical and Radiographic Signs of ECR

Clinical signs
<ul style="list-style-type: none"> <li>● Located in cervical region of tooth</li> <li>● Pink spot might be noted by patient/dentist</li> <li>● Tooth usually responds positively to vitality tests unless there is pulpal involvement (in very advanced cases)</li> <li>● Spontaneous and profuse bleeding on probing</li> <li>● Sharp, thinned out edges around the resorptive cavity</li> </ul>
Radiologic signs
<ul style="list-style-type: none"> <li>● Detected as chance radiologic finding because tooth is usually asymptomatic</li> <li>● Varies from asymmetrically located radiolucency with irregular margins in cervical/proximal region of tooth to uniformly round radiolucency centered over the root</li> <li>● Early lesions are usually radiolucent in appearance</li> <li>● Advanced lesions might have mottled appearance because of fibro-osseous nature of the lesion</li> <li>● Root canal should be visible and intact (indicating lesion is external)</li> </ul>



**Figure 1.** (A) Pink spot and a probable defect on the distal aspect in the cervical region of the maxillary left central incisor, indicating ECR.



**Figure 2.** Root caries on the buccal aspects of the mandibular left second premolar and first molar tooth might be confused with ECR. Active root caries will be sticky on probing.

Harrington and Natkin (17) assessed a series of cases and suggested that the resorptive process might be related to injury to the periodontium from the heat lamp or bleaching tool used. However, the authors of this study did not eliminate other indirect forms of injuries to the cementum such as rubber dam clamp placement during root canal treatment causing damage to the root surface.

Cvek and Lindvall (26) found that 2 of 11 teeth that were bleached had superficial ECR that did not progress. This prompted them to propose that repair could take place as long as there is no secondary microbial involvement. Friedman et al (30) found that about 6.9% teeth (n = 58) exhibited ECR after bleaching. The authors supported the conclusions of previous reports dismissing trauma and heat as the etiologic factors in bleaching-related cases of ECR. They also found that the occurrence of resorption was not related to the type of bleaching.

Glockner et al (35) conducted a 5-year follow-up study of 86 patients who had internal bleaching with sodium perborate and hydrogen peroxide. No cases of ECR were detected. It was claimed that the authors were very careful in selecting cases without cervical defects. However, how they ascertained the presence or lack of cervical defects was not stated in the article. It is also not clear whether the authors simply excluded teeth with existing ECR. As a preventative measure against the development of ECR, the access cavities were dressed with calcium hydroxide for a week, and the root canal entrance was sealed with a phosphate cement.

As a preventative step before embarking on an internal bleaching treatment, clinical and radiologic examination must be carried out to ensure that there is no cervical defect that could allow excessive pene-

tration of hydrogen peroxide (36). Coronal sealing of the root canal with a protective material (for example, placement of glass ionomer cement or intermediate restorative material at the cervical level of the root canal) is necessary to reduce the likelihood of periodontal and cervical leakage of the bleaching agent (4, 36, 37).

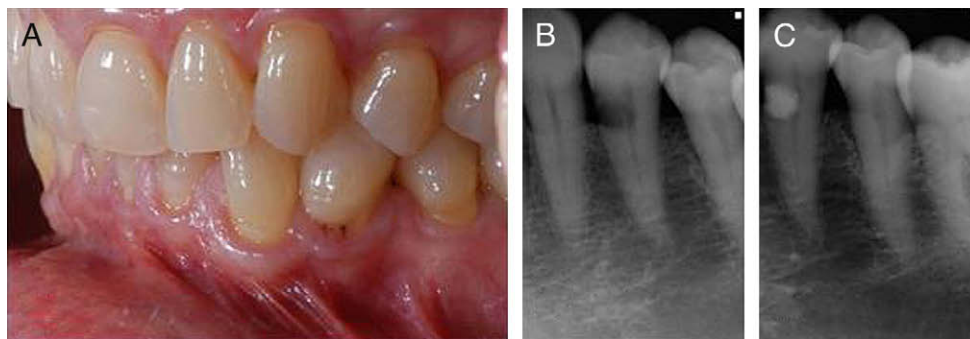
Sodium perborate mixed with water might be a safer alternative to hydrogen peroxide as an intracoronal bleaching agent. It has also been suggested that 35% carbamide peroxide (urea peroxide) appears to combine the safety of sodium perborate together with the efficacy of 35% hydrogen peroxide (37, 38).

### Surgery

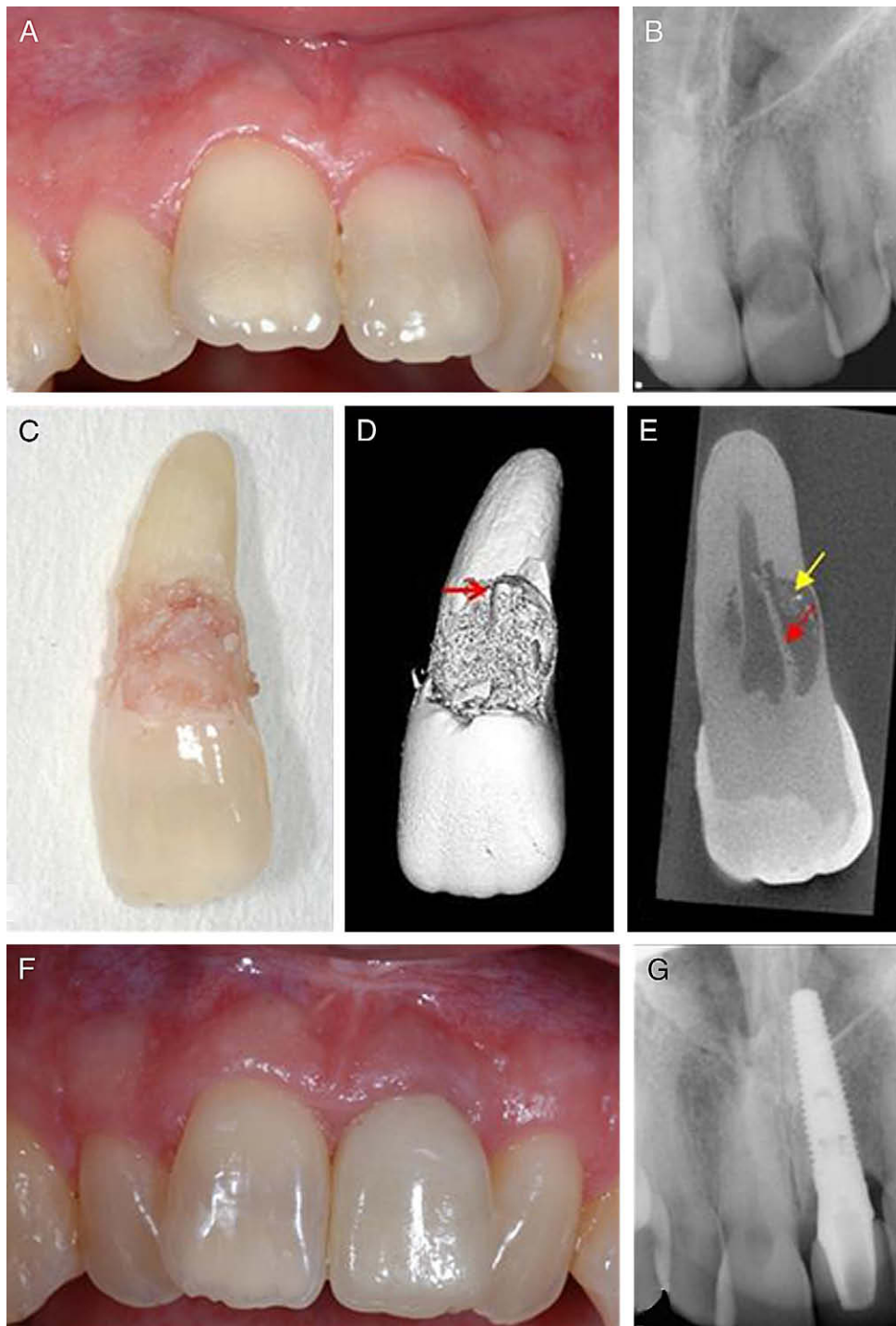
Surgical procedures that result in damage to the cemento-enamel junction were also identified as a significant predisposing factor in the study by Heithersay (3). This category represents a relatively low incidence, considering the frequency of such procedures. The cases that were included in the study involved procedures such as removal of adjacent partially or fully erupted third molars or supernumerary teeth, transplantation of canine teeth, the surgical exposure of an unerupted canine, and periodontal surgery for root amputation.

### Periodontal Therapy

Unexpectedly, periodontal debridement that might inadvertently result in damage/removal of the cementum was not identified in the study by Heithersay (3) as a major predisposing factor. Periodontal



**Figure 3.** (A) Probable defect is detected on the buccal cervical aspect of the mandibular left first premolar. (B) Radiograph reveals a radiolucent lesion with poorly defined borders, indicating the lesion is ECR. (C) Post-treatment radiograph after the ECR cavity has been restored with glass ionomer cement.

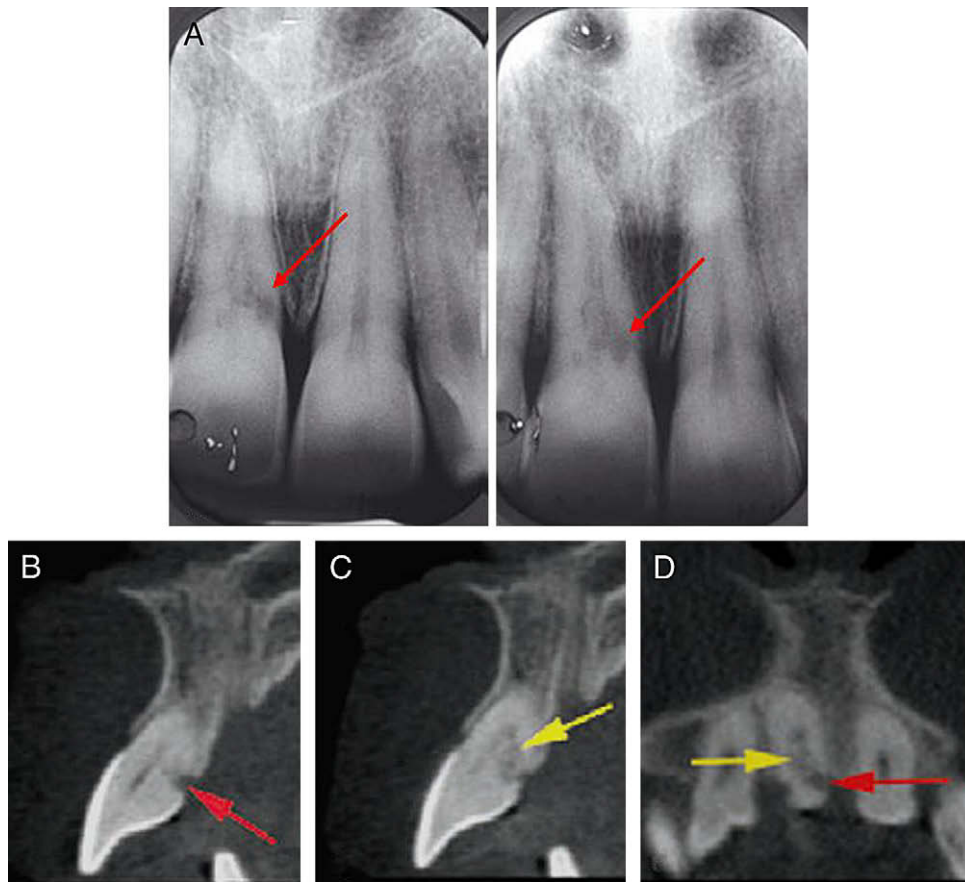


**Figure 4.** (A) Maxillary left central incisor tooth has a pink spot and is cavitated. (B) Radiograph reveals an unusual presentation of ECR; the lesion is circular and has well-defined margins. Note that the outline of the root canal is visible and intact through the radiolucent lesion. (C) The tooth was unrestorable and was extracted. Note the large amount of granulation tissue. (D) 3D reconstruction of the extracted tooth from a microtomography scan reveals bone-like tissue below the overlying granulation tissue. Note the intact root canal wall (red arrow). (E) Coronal reconstruction from a microtomography scan revealing how the pre-dentin (red arrow) prevents the ECR defect invading the root canal, and also bone-like tissue can be seen (yellow arrow). (F, G) An implant retained crown has been used to replace the tooth.

therapy was recorded as the sole predisposing factor in only 1.6% of patients (3). The incidence appeared to be consistently low, even when combined with other factors. ECR might be prevented after periodontal debridement of the root surface by rapid epithelial down-

growth preventing contact of connective tissue cells with that surface, thus hindering the inflammatory process (21).

Ben-Yehouda (39) described a case of ECR that had previously been treated with tetracycline root-conditioning. Blomlof and Lindskog



**Figure 5.** (A) Two periapical radiographs made at different horizontal angles confirm the resorptive lesion is palatally positioned by using the parallax principle. The lesion appears to extend mesially, although this is difficult to confirm. (B, C) A series of CBCT sagittal slices and (D) an axial view clearly show 2 distinct areas within the resorptive lesion: outer inflammatory (red arrow) and an inner fibro-osseous (yellow arrow) resorption. Adapted with permission from Patel S, Dawood A. The use of cone beam computed tomography in the management of external cervical resorption cavities. *Int Endod J* 2007; 40:818–830.

(40) also presented a case report of progressive ECR in a patient who had received periodontal regenerative treatment with guided tissue regeneration.

**Other Factors**

Other factors that have been suggested as potential predisposing factors to ECR include bruxism and intracoronal restorations (3). Developmental defects such as hypoplasia or hypomineralization of cementum have also been suggested as predisposing factors. Heithersay (3) was of the opinion that this could also make up a majority of the 14.9% of patients who had no other obvious potential predisposing factor associated with their ECR lesions. He also suggested that 15.3% of patients were categorized as having intracoronal restorations as their predisposing factors. However, it appears that when there were no other potential predisposing factors identifiable and a coronal restoration was present, it was by default classified as the potential predisposing factor for ECR. This might not be true reflection of the actual etiology.

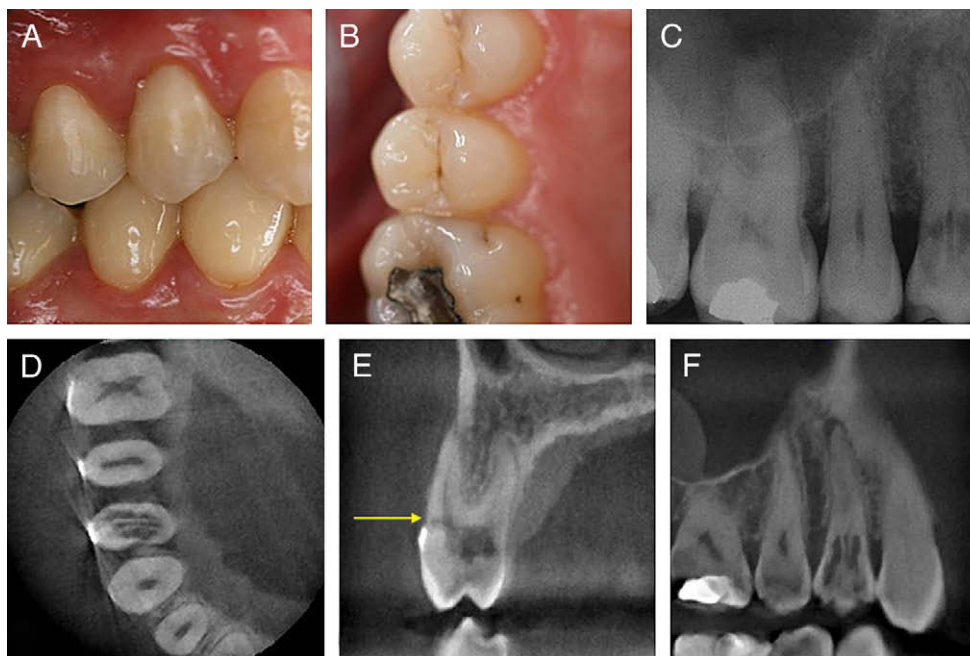
In much of the literature reviewed, the possible association with systemic diseases has not been adequately reviewed. Although the available evidence is weak, it cannot be ruled out that there could be a causal link. Moskow (41) suggested that hyperoxaluria and oxalosis could cause root resorption. This is due to an increased concentration of oxalates in blood caused by kidney failure, resulting in precipitation of crystals in hard tissues, which the author claims could initiate the

root resorptive process. Ilena-Puy et al (42) described 3 cases of ECR that they attributed to the coexisting conditions of normocalcemic hypercalciuria and nephrolithiasis. Neely and Gordon (43) have suggested that certain individuals might have a genetic predisposition to ECR.

It is impossible to appreciate the true etiologic factor(s) of ECR because it is not always possible to separate different factors associated with each ECR event, for example, an individual with a class 2 division I incisal relationship that undergoes orthodontic treatment, and then several years later his anterior tooth becomes discolored. The tooth is successfully endodontically treated and bleached; several years later he presents with ECR of his maxillary incisor teeth. What is the cause of the ECR? Was it the orthodontic treatment, intracoronal bleaching, or perhaps the rubber dam clamp impinging on the cementum, or the subsequent intracoronal restoration? Was it a cumulative effect of all these factors? Perhaps the true etiologic factor was dental trauma to his maxillary teeth that he does not recall and has therefore been discounted by the clinician managing the patient.

**Diagnosis**

As its name suggests, ECR is usually found at the cervical region of the tooth (Table 2). A pink spot in the cervical region of the tooth is usually the clinical sign noticed by the patient and/or dentist that brings



**Figure 6.** (A, B) Clinical views of the maxillary right quadrant. Note there are no clinical signs of ECR. (C) A periapical radiograph reveals extensive ECR. (D–F) With CBCT the true nature of the lesion can be established, including the portal of entry (yellow arrow).

the problem to light (Fig. 1). This discoloration is a result of the highly vascular granulation (resorptive) tissue within the tooth becoming visible through the thinned out (resorbed) dentin and translucent overlying enamel (1, 44). If there is no pink spot indicating ECR, then the condition might go unnoticed until there is pulpal and/or periodontal involvement, because these lesions are usually painless.

It is important to differentiate ECR from subgingival caries, which will feel sticky on probing (Fig. 2) and does not present with the pink spot (1). The base of an ECR defect will feel hard and also result in a scraping sound when probed (19). Probing the ECR defect and/or the associated periodontal pocket will cause profuse bleeding of the underlying highly vascular resorptive tissue (44). Once the granulation tissue has been removed from an ECR lesion, the cavity walls will feel hard and mineralized on probing. The edges of the cavity usually appear sharp and narrow. Teeth with ECR will respond positively to sensitivity testing because the pulp only becomes involved in very advanced cases of ECR.

Early ECR defects are commonly detected as chance findings on radiographs. The severity of ECR determines its radiographic appearance. In our experience, early lesions are more likely to be detected when they are present on the proximal surfaces of the tooth. The lesion classically presents as an asymmetrical radiolucency with ragged or irregular margins in the cervical region of the tooth (Fig. 3). Early lesions might be radiolucent; however, more advanced lesions might have a mottled appearance caused by the osseous nature of the advanced lesion (1, 2). However, this mottling appearance might not always be apparent on radiographs, especially when ECR lesions have relatively small amounts of fibro-osseous tissue at the base of the cavity (Fig. 4).

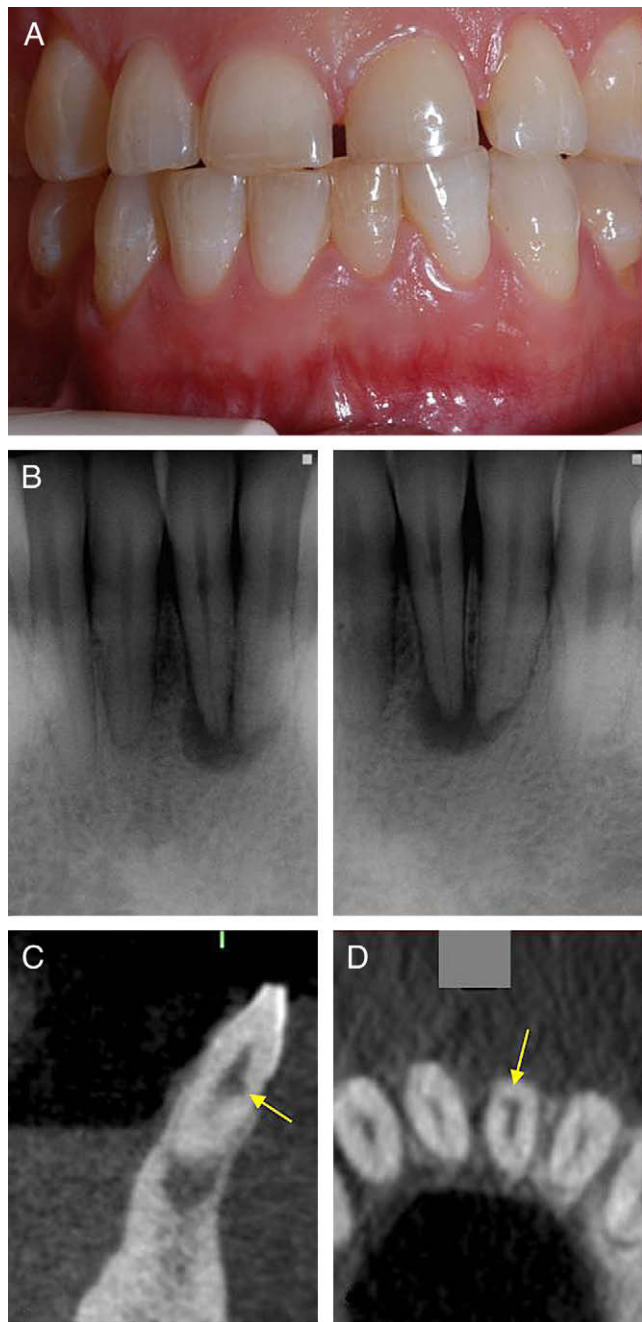
The outline of the root canal should be visible and intact, indicating that the lesion lies on the outer surface of the root (Fig. 4). With more advanced lesions, the lesion tends to balloon out within the root in all directions; this will also be reflected in the size and position of the radiolucency detected on the radiograph. The lesion might involve the adjacent alveolus, resulting in a radiographic appearance of an intrabony defect (21, 44).

The parallax technique is useful to follow the continuity of the pulp canal and to distinguish between internal and external resorption (Fig. 5). With internal resorption, the defect remains centered on the root canal system regardless of the angle of the radiograph exposure, whereas with ECR the defect will either move in the same (lingual/palatal) or in the opposite (labial) direction of the x-ray tube (1, 45, 46). The radiologic appearance of ECR does not always follow this classic appearance. It might vary from a round, uniformly radiolucent lesion with well-defined smooth symmetrical borders (Fig. 4B) to a multiloculated lesion with a mottled appearance.

A distinction must also be made between early ECR and cervical "burnout," which might appear as a radiolucent band across the entire neck of the tooth (47). It has been shown that conventional radiographic techniques reveal limited information on the true extent and nature of the resorptive lesion (48). Recently, cone beam computed tomography (CBCT), which is an extraoral 3-dimensional imaging technique, has been used to assess ECR lesions (Fig. 6). The position, depth in relation to the root canal, and ultimately the restorability of the tooth can be assessed objectively before any treatment is carried out (48–50). Atypical internal resorption lesions located on the outer aspects of the root canal might also be confused with ECR. As a result of the internal resorption lesion not being located centrally, the root canal might still be visible on a conventional radiograph, and the parallax principle might confuse matters more because the lesion will move with the changing position of the tube head (Fig. 7). The co-authors of this article have recently demonstrated that the diagnostic accuracy of CBCT was superior to intraoral radiographs (51).

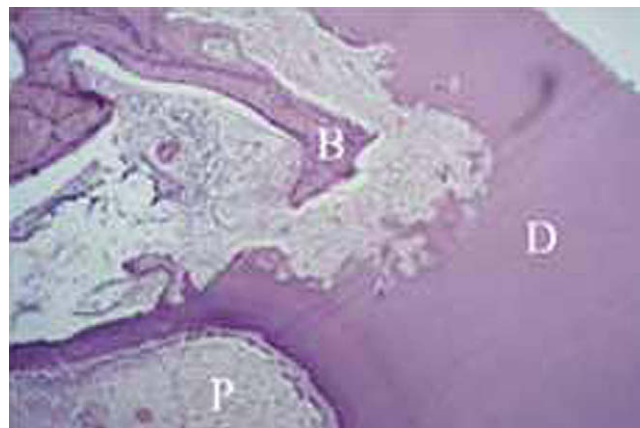
### Histology and Nature of the Lesion

The histologic appearance of the ECR is similar to external inflammatory resorption; the resorptive cavity in ECR lesions consists of granulomatous tissue. Osteoclasts might be observed on the resorbing front within the lacunae. The predentin and innermost layer of dentin prevent the ECR lesion from involving the pulp, which remains healthy



**Figure 7.** (A) Clinical examination reveals that the mandibular left central incisor tooth was discolored. (B) Two periapical radiographs taken at different horizontal angles confirm the resorptive lesion is labially positioned by using the parallax principle. The root canal outline is still visible through the lesion, indicating that the lesion is ECR. (C, D) Sagittal and axial CBCT slices reveal that the lesion is actually internal resorption, which is located at the periphery of the root canal. The true nature of the resorptive lesion could only be assessed with CBCT. Adapted with permission from Patel S. New dimensions in Endodontic imaging: Part 2. Cone Beam Computed Tomography. *Int Endod J* (2009) in press.

(uninflamed) until the ECR has become very advanced (2). Resorption channels extend into the dentin and interconnect within the periodontal ligament. As the lesion advances, bone-like material (replacement resorption) might also become deposited within the lesion and also in direct contact with the adjacent dentin (Figs. 4 and 8); this indicates



**Figure 8.** Horizontal histologic section of ECR shows bone (B) forming within the dentin (D). The resorptive process avoids the dentin that surrounds the pulp. Reprinted with permission of Patel S, Pitt Ford T. Is the resorption external or internal? *Dental Update* 2007;34:218–29.

that the lesion is not destructive but attempting to repair itself (1, 3, 15). This hard resorptive tissue might be mistaken for dentin when the contents of the resorptive cavity are excavated.

The advancing ECR lesions characteristically stop short of the root canal and underlying pulp; instead, the resorptive process usually expands in a circumferential and apico-coronal direction around the root canal (Fig. 4). Perforation of the root canal is prevented by a thin protective layer of inner dentin and predentin (2, 52). The predentin has been shown to contain an anti-invasion factor and resorption inhibitor that prevent ECR from advancing into the root canal until the ECR is very advanced (53). It has also been suggested that the outer surface of enamel might also be resistant to resorption as a result of preferential odontoclastic dissolution of interprismatic enamel (52).

Early ECR defects do not usually contain acute inflammatory cells, implying a nonbacterial etiology. However, at a later stage, a secondary bacterial colonization of dentinal tubules might induce an inflammatory response in the associated periodontal or pulpal tissue (15, 26). In long-standing lesions, the root canal might be perforated by the advancing resorptive lesion. If pulpal involvement occurs, the fibro-osseous tissue can be found deposited within the root canal system (54).

### Treatment

Treatment depends on the severity, location, whether the defect has perforated the root canal system, and the restorability of the tooth. Several treatment regimes have been suggested in the literature, depending on the nature of the ECR lesion, and are usually based on isolated case reports. These include intentional replantation (55), guided tissue regeneration (56), treating the ECR lesion by an internal approach only (9), and forced orthodontic eruption (57).

Essentially, treatment involves complete removal of the resorptive tissue and restoring the resulting defect with a plastic tooth-colored restoration. Endodontic treatment might also be required in cases in which the ECR lesion has perforated the root canal. Table 3 lists the treatment objectives for managing ECR.

Heithersay (2) classified ECR according to the extent of the lesion within the tooth (Fig. 9): class 1, a small invasive resorptive lesion near the cervical area with shallow penetration into dentin; class 2, a well-defined invasive resorptive lesion that has penetrated close to the coronal pulp chamber but shows little or no extension into radicular dentin; class 3, a deeper invasion of dentin by resorbing tissue, not only involving the coronal dentin but also extending at least to the

**TABLE 3.** Treatment Objectives to be Considered When Managing ECR

Treatment objectives
Arrest resorptive process
Restore damaged root surface
Prevent further resorption
Improve esthetics of tooth (in cases where resorption has led to a pink spot)

coronal third of the root.; and class 4, a large invasive resorptive process that has extended beyond the coronal third of the root canal.

Heithersay (15) stated that careful case selection was important to achieve a good prognosis; he recommended only treating defects categorized as classes 1–3. Because of the extensive nature of class 4 lesions, treatment will prove difficult, and these cases will have a higher risk of failure. As such, teeth with class 4 lesions might be left untreated for as long as they are asymptomatic. Otherwise, extraction might be the only viable option.

The classification by Heithersay (15) is useful for assessing the extent and managing ECR defects that are present on the proximal (ie, mesial and distal) aspects of the tooth. However, although it might be possible to detect (and therefore classify) resorptive lesions located on the proximal (mesial and distal) aspects of the tooth, it is much more challenging to identify confidently the true nature and extent of ECR defects located on (or which have progressed) onto the labial or palatal aspects of a tooth by using conventional radiographic techniques (48). An example of the problem with this classification is shown in Fig. 6. The true nature of this class II defect can only be assessed with CBCT, which confirms that the tooth is unrestorable.

Patel and Dawood (48) illustrated 2 cases of ECR in which CBCT scans revealed the true nature and degree of resorption in 3 dimensions. The resorption lesion in the one case was found to be confined to the buccal aspect of the root with no perforation of the root canal, therefore allowing the clinician to advise the patient confidently of the true nature and severity of the ECR lesion and also the exact treatment required. In their second case, the ECR lesion appeared to be a class 3 lesion on conventional radiographs. However, CBCT scans revealed that the ECR defect was far more extensive (class 4) and was therefore un-treatable. This vital information prevented the patient from undergoing an unnecessary exploratory surgical procedure.

As would be expected, smaller lesions offer the most favorable long-term outcome. These defects would fall into Heithersay class 1 and 2 ECR categories. As previously mentioned, the pulp is usually not involved. However, if the resorptive defect is in close proximity to

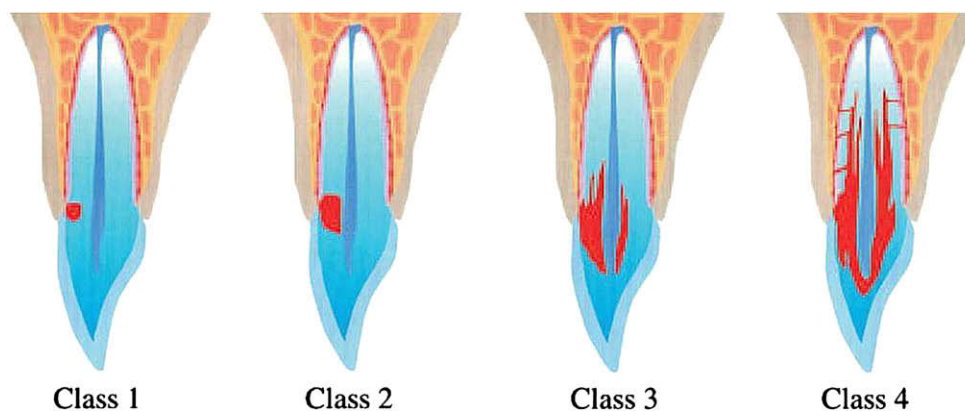
the pulp and there is high risk of pulpal exposure, endodontic treatment should be carried out before external repair of the ECR defect (11).

To treat the ECR lesions confidently, it is usually necessary to reflect a full-thickness periosteal flap to allow complete access and removal of the ECR lesion from the root, curetting away the granulomatous tissue from the adjacent periodontium to sever the blood supply to the resorbing cells, thereby decreasing the chances of recurrence. Ongoing bleeding from the cavity indicates that there is a blood supply apical or lateral to the cavity margin. The root defect can then be filled with composite resin or glass ionomer cement (Fig. 3); the flap is then replaced (1, 11). Long-standing advanced ECR lesions might also contain fibro-osseous tissue that might be hard to differentiate from the underlying dentin against which it directly abuts. If this hard ECR tissue is not removed, there is every chance that ECR might recur in the future. Magnification and good illumination are essential to differentiate this fibro-osseous tissue from the underlying dentin.

Heithersay (5) recommended topical application of a 90% aqueous solution of trichloroacetic acid, curettage, and restoration with glass ionomer cement. Topical application of trichloroacetic acid results in coagulation necrosis of the ECR resorptive tissue, with no damage to adjacent periodontal tissues (5). It also infiltrates the small channels and recesses of ECR that would otherwise be unreachable by mechanical instrumentation.

Endodontic treatment might be necessary with some class 2 and usually class 3 lesions when pulpal involvement has occurred or is very close to occurring. Heithersay has reported a 100% success rate in the treatment of class I and II ECR lesions treated in this way. The success rate in class 3 lesions was 77.8% and only 12.5% of teeth in class 4 cases. Heithersay concluded that classes 1–3 were treatable, but class 4 lesions were not amenable to treatment, and these cases would have benefited from alternative treatment such as extraction and replacement with an implant retained crown restoration. In the instance of classes 1–3, the root canal should be nonsurgically accessed and temporarily occluded with a finger spreader or gutta-percha point. Then the surgical repair to the resorptive defect might be carried out without blocking the root canal with filling material. Once the ECR cavity has been restored, endodontic treatment might be completed confidently without risk of expelling irrigants and debris via the ECR cavity into the adjacent periodontium.

When discussing treatment options with patients, it is important to advise patients that the final decision on the treatment (surgical repair ± endodontic treatment versus extraction) can only be objectively made once the full extent of the ECR is assessed, and this usually means surgical exposure of the ECR defect. However, if a CBCT scan



**Figure 9.** The Heithersay classification for ECR. From Heithersay GS. Invasive cervical resorption: An analysis of potential predisposing factors. Quintessence International. 1999;30:83-95. Used with permission.

has been taken, then the treatment approach might confidently be decided on, rather than undertaking exploratory surgical exposure of the defect.

Pierce et al (58) suggested dressing root canals with calcitonin to prevent further progression of resorption caused by trauma. Calcitonin is a pharmacologically active polypeptide responsible for inhibitory action on osteoclasts via specific cell receptors. It might also act to directly inhibit odontoclast activity and to suppress inflammation (59). In a series of studies Wiebkin et al (60, 61) found that the primary prevention of external root resorption by intra-root canal insertion of calcitonin was due to the exposure of odontoclasts at the very site where cementum and dentin were being actively damaged. This would obviously entail elective endodontic therapy of the involved tooth. A recent study by Kitchens et al (62) found that iontophoresis greatly increased transdentinal delivery of calcitonin. They suggested a new method of treatment of ECR that involves chemomechanical debridement of the root canal, obturation of the apical part of the canal, removal of the smear layer, and subsequent iontophoretic delivery of calcitonin via the dentinal tubules directly to the ECR lesion (62). Some other potential medicaments that could also be used with this method are osteoprogenitor and bisphosphonates (62). Further research into this novel technique will pave the way toward a more conservative approach to managing ECR cases.

## Conclusion

Early detection is essential for successful management and outcome of ECR. Patients with an ECR lesion with no apparent identifiable etiologic factor should have their entire dentition assessed to ensure that no other teeth are affected by ECR.

Patients with a history of 1 or more predisposing factors should be monitored closely for initial signs of ECR. The very low risk of developing ECR does not justify taking additional radiographs. However, every radiographic investigation carried out for general examination or diagnostic purposes should be routinely checked for ECR lesions if the teeth in question have been exposed to 1 or more of the predisposing factors.

CBCT appears to be a promising diagnostic tool for confirming the presence, appreciating the true nature, and managing ECR.

## Acknowledgments

*We thank Cavendish Imaging, London, UK, for their help and advice in preparation of this article and Heather Pitt Ford, King's College London Dental Institute, London, UK, for her help in the preparation of this manuscript. Implant placement in Figure 4 by Andrew Dawood.*

## References

- Patel S, Pitt Ford T. Is the resorption external or internal? *Dental Update* 2007;34:218–29.
- Heithersay GS. Clinical, radiologic and histopathologic features of invasive cervical resorption. *Quintessence Int* 1999;30:27–37.
- Heithersay GS. Invasive cervical resorption: an analysis of potential predisposing factors. *Quintessence Int* 1999;30:83–95.
- Heithersay GS. Invasive cervical resorption following trauma. *Aust Endod J* 1999;25:79–85.
- Heithersay GS. Treatment of invasive cervical resorption: an analysis of results using topical application of trichloroacetic acid, curettage and restoration. *Quintessence Int* 1999;30:96–110.
- Fish EW. Benign neoplasia of tooth and bone. *Proc R Soc Med* 1941;34:427–32.
- Southam JC. Clinical and histological aspects of peripheral cervical resorption. *J Periodontol* 1967;38:534–8.
- Frank AL. External-internal progressive resorption and its non-surgical correction. *J Endod* 1981;7:473–6.
- Frank AL, Blakland LK. Non endodontic therapy for supra osseous extracanal invasive resorption. *J Endod* 1987;13:348–55.
- Gold SI, Hasselgren G. Peripheral inflammatory root resorption: a review of the literature with case reports. *J Clin Periodontol* 1992;19:523–34.
- Trope M. Root resorption due to dental trauma. *Endod Topics* 2002;1:79–100.
- Bergmans L, Van Cleynbreugel J, Verbeke E, Wevers M, Van Meerbeek B, Lambrechts P. Cervical external root resorption *in vital* teeth: X-ray microfocus—tomographical and histopathological study. *J Clin Periodontol* 2002;29:580–5.
- Hammarström L, Lindskog S. Factors regulating and modifying dental root resorption. *Proc Finn Dent Soc* 1992;88(Suppl 1):115–23.
- Neuvald L, Consolaro A. Cementoenamel junction: microscopic analysis and external cervical resorption. *J Endod* 2000;26:503–8.
- Heithersay GS. Invasive cervical resorption. *Endod Topics* 2004;7:73–92.
- Tronstad L. Endodontic aspects of root resorption in clinical endodontics: a textbook. 2<sup>nd</sup> ed. Stuttgart: Thieme; 2002.
- Harrington GW, Natkin E. External resorption associated with the bleaching of pulpless teeth. *J Endod* 1979;5:344–8.
- Gunraj MN. Dental root resorption. *Oral Surg Oral Med Oral Pathol Oral Radiol Endod* 1999;88:647–53.
- Liang H, Burkes EJ, Frederiksen NL. Multiple idiopathic cervical root resorption: systematic review and report of four cases. *Dent Radiol* 2003;32:150–5.
- Goon WWY, Cohen S, Borer RF. External cervical root resorption following bleaching. *J Endod* 1986;12:414–8.
- Tronstad L. Root resorption: etiology, terminology and clinical manifestations. *Endod Dent Traumatol* 1988;4:241–52.
- Fuss Z, Tsesis I, Lin S. Root resorption: diagnosis, classification and treatment choices based on stimulation factors. *Dent Traumatol* 2003;19:175–82.
- Cwyk F, Saint-Perre F, Tronstad L. Endodontic implications of orthodontic tooth movement. *J Dent Res* 1984;63:1039.
- Linge L, Linge BO. Patient characteristics and treatment variables associated with apical root resorption during orthodontic treatment. *Am J Orthod Dentofacial Orthop* 1991;99:35–43.
- Hines FB. A radiographic evaluation of the response of previously avulsed teeth and partially avulsed teeth to orthodontic movement. *Am J Orthod* 1979;75:1–19.
- Cvek M, Lindvall AM. External root resorption following bleaching of pulpless teeth with oxygen peroxide. *Endod Dent Traumatol* 1985;1:56–60.
- Malikaew P, Watt RG, Sheiham A. Prevalence and factors associated with traumatic dental injuries (TDI) to anterior teeth of 11–13 year old Thai children. *Community Dental Health* 2006;23:222–7.
- Nguyen QV, Bezemer PD, Habets L, Prahl-Andersen B. A systematic review of the relationship between overjet size and traumatic dental injuries. *Eur J Orthod* 1999;21:503–15.
- Andreasen JO, Andreasen FM. Textbook and color atlas of traumatic injuries to the teeth. 4th ed. Copenhagen: Munksgaard; 2007.
- Friedman S, Rotstein I, Libfield H, Stabholz A, Heling I. Incidence of external root resorption and esthetic results in 58 bleached pulpless teeth. *Endod Dent Traumatol* 1988;4:23–6.
- Rotstein I, Torek Y, Misgav R. Effect of cementum defects on radicular penetration of 30% hydrogen peroxide during intracoronal bleaching. *J Endod* 1991;17:230–3.
- Lado AE, Stanley HR, Weisman MI. Cervical resorption in bleached teeth. *Oral Surg Oral Med Oral Pathol* 1983;55:78–80.
- Kehoe JC. pH reversal following *in vitro* bleaching of pulpless teeth. *J Endod* 1987;13:6–9.
- McCormick JE, Weine FS, Maggio JD. Tissue pH of developing periapical lesions in dogs. *J Endod* 1983;9:47–51.
- Glockner K, Hulla H, Ebeleseder K, Stadler P. Five-year follow-up of internal bleaching. *Braz Dent J* 1999;10:105–10.
- Walton RE, Rotstein I. Bleaching discolored teeth: internal and external. In: Walton RE, ed. Principles and practice of endodontics. 2nd ed. Philadelphia: WB Saunders; 1996.
- Lim KC. Considerations in intracoronal bleaching. *Aust Endod J* 2004;30:69–73.
- Chng HK. Update on materials used in intracoronal bleaching. *Ann R Aust Coll Dent Surg* 2002;16:147–50.
- Ben-Yehouda A. Progressive cervical root resorption related to tetracycline root conditioning. *J Periodontol* 1997;68:432–5.
- Blomlof L, Lindskog S. Cervical root resorption associated with guided tissue regeneration: a case report. *J Periodontol* 1998;69:392–5.
- Moskow BS. Periodontal manifestations of hyperoxaluria and oxalosis. *J Periodontol* 1989;60:271–8.
- Llena-Puy MC, Amengual-Lorenzo J, Forner-Navarro I. Idiopathic external root resorption associated to hypercalciuria. *Medicina Oral* 2002;7:192–9.
- Neely AL, Gordon SC. A familial pattern of multiple idiopathic cervical root resorption in a father and son: a 22-year follow-up. *J Periodontol* 2007;78:367–71.

44. Trope M, Chivian N. Root resorption. In: Cohen S, Burns RC, eds. *Pathways of the pulp*. 8<sup>th</sup> ed. St Louis: Mosby; 2006:626–47.
45. Andreasen FM, Sewerin I, Mandel U, Andreasen JO. Radiographic assessment of simulated root resorption cavities. *Endod Dent Traumatol* 1987;3:21–7.
46. Gulabivala K, Searson L. Clinical diagnosis of internal resorption: an exception to the rule. *Int Endod J* 1995;28:255–60.
47. Wuerhmann AH, Manson-Hing LR. *Dental radiology*. 3rd ed. St Louis: CV Mosby Co; 1973:288–9.
48. Patel S, Dawood A. The use of cone beam computed tomography in the management of external cervical resorption lesions. *Int Endod J* 2007;40:818–30.
49. Patel S, Dawood A, Whaites E, Pitt Ford T. The potential applications of cone beam computed tomography in the management of endodontic problems. *Int Endod J* 2007;40:818–30.
50. Cohenca N, Simon JH, Mathur A, Malfaz JM. Clinical indications for digital imaging in dento-alveolar trauma: part 2—root resorption. *Dent Traumatol* 2007;23:105–13.
51. Patel S. New dimensions in Endodontic imaging: Part 2. Cone Beam Computed Tomography. *Int Endod J* 2009 in press.
52. Iqbal MK. Clinical and scanning electron microscopic features of invasive cervical resorption in a maxillary molar. *Oral Surg Oral Med Oral Pathol Oral Radiol Endod* 2007;103:e49–54.
53. Wedenberg C, Lindskog S. Evidence for a resorption inhibitor in dentin. *Scand J Dent Res* 1987;95:270–1.
54. Coyle M, Toner M, Barry H. Multiple teeth showing invasive cervical resorption: an entity with little known histologic features. *J Oral Pathol Med* 2006;35:55–7.
55. Frank AL, Torabinejad M. Diagnosis and treatment of extracanal invasive resorption. *J Endod* 1998;7:500–4.
56. Rankow HJ, Krasner PR. Endodontic applications of guided tissue regeneration in endodontic surgery. *Oral Health* 1996;86:33–5.
57. Trope M. Subattachment inflammatory root resorption: treatment strategies. *Pract Period Aesthet Dent* 1998;10:1005–10.
58. Pierce A, Berg JO, Lindskog S. Calcitonin as an alternative therapy in the treatment of root resorption. *J Endod* 1988;14:459–64.
59. Warshawsky H, Goltzman D, Rouleau MF, Bergeron JJ. Direct in vivo demonstration by radioautography of specific binding sites for calcitonin in skeletal and renal tissues of the rat. *J Cell Biol* 1980;85:682–94.
60. Wiebkin OW, Cardaci SC, Heithersay GS, Pierce AM. Therapeutic delivery of calcitonin to inhibit external inflammatory root resorption: diffusion kinetics of calcitonin through the dental root. *Endod Dent Traumatol* 1996;12:265–71.
61. Wiebkin OW, Cardaci SC, Heithersay GS, Pierce AM. Therapeutic delivery of calcitonin to inhibit external inflammatory root resorption: influence of calcitonin binding to root mineral. *Endod Dent Traumatol* 1996;12:272–6.
62. Kitchens JA, Schwartz SA, Schindler WG, Hargreaves KM. Iontophoresis significantly increases the trans-dentinal delivery of osteoprotegerin, alendronate and calcitonin. *J Endod* 2007;33:1208–11.