

# Surgical treatment of peri-implantitis using a bone substitute with or without a resorbable membrane: a prospective cohort study

Ann-Marie Roos-Jansåker<sup>1,2</sup>, Helena Renvert<sup>1</sup>, Christel Lindahl<sup>1,2</sup> and Stefan Renvert<sup>1,3</sup>

<sup>1</sup>Department of Health Sciences, Kristianstad University, Kristianstad, Sweden;

<sup>2</sup>Department of Periodontology, Public Dental Health Service, Kristianstad, Sweden;

<sup>3</sup>School of Dental Sciences, Trinity College, Dublin, UK

Roos-Jansåker A-M, Renvert H, Lindahl C, Renvert S. Surgical treatment of peri-implantitis using a bone substitute with or without a resorbable membrane: a prospective cohort study. *J Clin Periodontol* 2007; 34: 625–632. doi: 10.1111/j.1600-051X.2007.01102.x.

## Abstract

**Objectives:** The aim of this prospective cohort study was to compare two regenerative surgical treatment modalities for peri-implantitis.

**Material and Methods:** Thirty-six patients having a minimum of one osseointegrated implant, with a progressive loss of bone amounting to  $\geq 3$  threads (1.8 mm) following the first year of healing, combined with bleeding and/or pus on probing, were involved in this study. The patients were assigned to two different treatment strategies. After surgical exposure of the defect, granulosomatous tissue was removed and the infected implant surface was treated using 3% hydrogen peroxide. The bone defects were filled with a bone substitute (Algipore<sup>®</sup>). In 17 patients (Group 1), a resorbable membrane (Osseoquest<sup>®</sup>) was placed over the grafted defect before suturing. In 19 patients (Group 2), the graft was used alone.

**Results:** One-year follow-up demonstrated clinical and radiographic improvements. Probing depths were reduced by 2.9 mm in Group 1 and by 3.4 mm in Group 2. Defect fill amounted to 1.5 and 1.4 mm, respectively. There was no significant difference between the groups.

**Conclusion:** It is possible to treat peri-implant defects with a bone substitute, with or without a resorbable membrane.

Key words: bone substitute; defect fill; healing; peri-implantitis; resorbable membrane; surgery

Accepted for publication 4 April 2007

In a previous paper, we reported peri-implantitis at 6.6% of the implants, demonstrating progressive loss of bone in combination with clinical signs of inflammation (Roos-Jansåker et al. 2006a). If peri-implantitis is not suc-

cessfully treated, the implants may be totally disintegrated and lost (Esposito et al. 1998, Quirynen et al. 2002, Leonhardt et al. 2003). Exposure and microbial colonization of the implant threads result in a clinically difficult situation to treat using non-surgical treatment options (Kreisler et al. 2005, Schwarz et al. 2006b). Even if specially designed curettes and/or specially designed tips for ultrasonic devices are used, it is difficult in removing the biofilm from the implant surface. Thus, the surface structure of the implant contributes to the difficulties to remove

hard and soft deposits from the implant surface without surgical intervention. If the implant threads are exposed after healing following a surgical intervention, plaque retention will be facilitated (Teughels et al. 2006) and challenge the patient's oral hygiene performance. The use of resective surgical approaches and smoothing of the implant surface as a treatment option has therefore been proposed, and was reported to affect the long-term survival of implants positively (Romeo et al. 2005). It would, however, be an advantage, especially in areas of aesthetic importance, if the

## Conflict of interest and source of funding statement

The authors declare that they have no conflict of interests.

This project was supported by research foundations from the Public Dental Health Service, County of Skåne, Sweden and Kristianstad University, Sweden.

bone defects occurring around the implants could be regenerated. Animal research has demonstrated that it is possible to obtain re-osseointegration on previously infected implants and to regenerate bone in experimentally created defects (Jovanovic et al. 1993, Hürzeler et al. 1997, Persson et al. 2001, Kolonidis et al. 2003, Schou et al. 2003a, b, Shibli et al. 2003, 2006).

Different regenerative therapies have been proposed in humans and many case reports are available in the literature (for a review, see: Roos-Jansåker et al. 2003, Schou et al. 2004). However, limited data exist from comparative clinical trials. In a clinical trial evaluating osseous grafting with or without the use of a resorbable or a non-resorbable membrane, Khoury & Buchmann (2001) reported an average bone fill of 1.7–2.5 mm. The technique used included bone to be taken elsewhere in the oral cavity and placed in the defects, followed by submerged healing of the treated implant. Owing to prosthetic reasons, submerged healing is often not possible to perform. Treatments involving autologous bone transplants in a defect may result in increased trauma and discomfort for the patient if an additional surgery is needed to obtain the transplant. It would therefore be an advantage to use commercially available bone substitutes. In a case series over 6 months, Schwarz et al. (2006a) reported probing depth (PD) reduction and gain in clinical attachment level using a bone substitute in combination with a resorbable membrane, without submerged healing.

The aim of the present study was to compare two surgical techniques using a bone substitute (Algipore<sup>®</sup>), with or without the use of a resorbable membrane (Ossequest<sup>®</sup>) and non-submerged healing. The main outcome variable for this study was PD reduction, probing attachment gain, mucosal recession (MR) and defect fill. The null hypothesis was that there are no differences in defect fill between the groups.

## Material and Methods

### Subjects

This study was approved by the Institutional Review Board, University of Lund, Sweden. All participating individuals signed an informed consent.

Patients for this study were recruited from (i) individuals examined in a sur-

vey evaluating the prevalence of peri-implant lesions 9–14 years following placements of Brånemark implants (Brånemark system<sup>®</sup>, Nobelpharma, Göteborg, Sweden) and (ii) patients who had been referred to the Speciality Clinic of Periodontology, Public Dental Health Services and Kristianstad University, for treatment of peri-implantitis.

Thirty-eight patients, having a minimum of one osseointegrated implant with peri-implantitis, demonstrating progressive loss of  $\geq 3$  threads (1.8 mm) following the first year of healing, in combination with bleeding and/or pus on probing, were involved in the study. All patients had surgical treatment using a bone substitute (Algipore<sup>®</sup>, Friadent, Malmö, Sweden) in the defects. In Group 1, the bone substitute was covered with a resorbable membrane (Ossequest<sup>®</sup>, W.L. Gore & Associates Inc., Flagstaff, Arizona, USA), whereas in Group 2 the bone substitute was used alone. Two patients died before the 1-year control, leaving 17 patients, with 29 treated implants in Group 1 and 19 patients with 36 treated implants in Group 2. All implants were Brånemark implants with machined surfaces, except one implant in each group, which was an Astra implant (Astra Tech system<sup>®</sup>, Astra Tech, Mölndal, Sweden) with a rough surface.

### Clinical and radiographic examination

All clinical and radiographic examinations were performed by the same examiner (author A.-M. R. J). Radiographs were obtained of implants in a standardized way using individually made bite-blocks on an Eggen holder (Renvert et al. 1981). The bite-blocks were made of Provil<sup>®</sup> Novo, Putty Soft (Heraeus Kulzer, GmbH I, Hannau, Germany). The X-ray films (Kodak Insight, EKC, Rochester, NY, USA) were supported by the bite-block on the film holder to avoid displacement and curving of the films. Attempts were made to place the film parallel to the long axis of the implant examined. During the exposure, the extension arm of the film holder was inserted into an acrylic track mounted on the long cone of the X-ray apparatus (Fig. 1). Pre- and postoperative films from the treated implants in all patients were coded and randomly mounted. A specialist in radiology made all measurements from the coded radiographs at the completion of the study. Threads not




Fig. 1. Patient using a bite-block on an Eggen holder inserted into an acrylic track mounted on the long cone of the X-ray apparatus for obtaining reproducible radiographs.

supported by bone at the mesial and distal sites of the implant were counted.

An update of the medical and dental history was performed, and the patients were asked the reason for tooth loss. The medical history also included a questionnaire on smoking habits (current, former or never smoker, smoking duration, packyears and whether smoking at the time of surgery). If the patient in conjunction with peri-implantitis had periodontal disease, periodontal treatments were given before the peri-implant surgery was performed.

After removing the supra-structure, the following measurements were performed:

- *Probing depth (PD)* measured in millimetre at four sites (mesial, buccal, distal and lingual) of each implant to the nearest mm using a standardized force of 0.25 N (Hawe Click-Probe<sup>®</sup>, KerrHawe SA, Bioggio, Switzerland) modified with a titanium probe tip graded in millimetre.
- *Probing attachment level (PAL)* measured in millimetre from the abutment connection of the supra-structure at four sites (mesial, buccal, distal and lingual).
- *Mucosal recession (MR)* calculated as the difference between the PAL and PD at four sites (mesial, buccal, distal and lingual).

- *Bleeding index* measured at the implants after probing at four sites (mesial, buccal, distal and lingual), and graded (0–3): 0 = no bleeding, 1 = spot bleeding, 2 = line bleeding and 3 = profound bleeding.
- *BOP* (*bleeding on probing*) measured at implants and teeth at four sites (mesial, buccal, distal and lingual).
- *Suppuration* if apparent following probing the sulcus.
- *Full-mouth plaque index (PI)* measured at implants and teeth at four sites (mesial, buccal, distal and lingual) after using an erythrosine dye (Top Dent Lifco Dental AB, Enköping, Sweden).

### Surgical treatment

The patients were prescribed systemic antibiotics, Amoxicillin (375 mg × 3) in combination with Metronidazole (400 mg × 2), for 10 days. The antibiotic therapy was initiated the day before surgery. In cases of allergy to penicillin, Clindamycin (300 mg) two times a day was prescribed.

The supra-structure was removed and the peri-implant lesion was surgically exposed. Following anaesthesia, a sulcular incision was made around the neck of the implant abutments, and full-thickness flaps were raised at the buccal and lingual surfaces to access the peri-implant defects. The abutment was removed, cleaned and sterilized. All granulated tissue was carefully removed in the bone defect with titanium instruments. The threads were carefully cleaned from mineralized calculus and the implant surface was cleansed using hydrogen peroxide (3%), followed by profuse rinsing with saline. The osseous defects were filled with a bone substitute (Algapore®) mixed with blood (Fig. 2). In the first 19 consecutive patients, a resorbable membrane (Osseoquest®) was placed over the filled defect (Group 1). In order to place the membrane over the defect, it was punched and trimmed to cover the defect completely. The subsequent 19 consecutive patients were treated with bone substitute alone (Group 2). The abutment was then reconnected. The flaps were sutured with non-resorbable sutures (Gore 5-0, W. L. Gore & Associates, Flagstaff, AZ, USA). Following suturing, the following parameters were registered: primary flap closure or not, wound stability or not after pulling the lip and blanching of the flap in the sutured area.

Postoperatively, the patients rinsed with Chlorhexidine (0.1%) for 5 weeks. The first 3 days after surgery, the patients were prescribed an anti-inflammatory and analgesic drug (Ibuprofen, 400 mg × 3). All patients had to report on the daily intake of antibiotics and the anti-inflammatory drug, and to comment

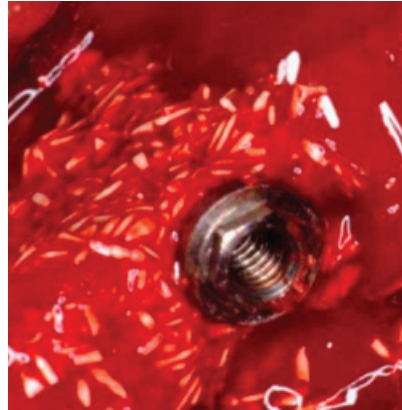


Fig. 2. Bone substitute mixed with blood in the peri-implant defect.

on any possible adverse events during the healing phase, as for example pain and swelling. The sutures were removed after 14 days. At healing checkups at 2, 6 weeks and every third month, membrane exposure and the presence of mucosal craters were registered.

After the healing phase, the patients were enrolled in a maintenance programme with visits to the dental hygienist every third month. At the visits, full-mouth plaque scores were obtained. Plaque was disclosed using an erythrosine dye (Top Dent Lifco Dental AB, Enköping, Sweden). The plaque chart was shown to the patient and re-motivation and re-instruction in oral hygiene procedures was performed if necessary. Teeth and implants were cleaned using a rubber cup and low-abrasive paste.

### Statistical methods

Patient characteristics at baseline were compared between the groups (Groups 1 versus 2) using the Mann–Whitney test

Table 1. Patient characteristics at baseline in Group 1 (bone substitute + membrane)  $N = 17$ , and in Group 2 (bone substitute)  $N = 19$ . Means ± SD (range); Numbers (%)

	Group 1	Group 2	<i>p</i>
Age	65.6 ± 7.4 (54–76)	66.3 ± 6.8 (55–79)	1.0*
Female	10 (58.8)	12 (63.2)	0.6†
Current smokers	12 (70.6)	13 (68.4)	
Former smokers	4 (23.5)	4 (21.1)	0.9‡
Never smoking	1 (5.9)	2 (10.5)	
Pack years	33.9 ± 13.5 (12–60)	30.8 ± 12.9 (15–62)	0.2*
Smoking duration (years)	43.0 ± 6.2 (35–57)	43.2 ± 8.9 (25–62)	0.9*
Smoked after implant surgery (%)	11 (64.7)	15 (78.9)	0.5†
Patients with diabetes (%)	1 (5.9)	2 (10.5)	1.0†
Patients with coronary heart disease (%)	3 (17.6)	3 (15.8)	1.0†
Tooth loss due to periodontitis			
Yes	9 (52.9)	9 (47.4)	
No	1 (5.9)	1 (5.2)	0.9‡
Do not know	7 (41.2)	9 (47.4)	
No. of patients with bone loss ≥ 4 mm on ≥ 30% of teeth§			
Yes	10 (91)	12 (86)	
No	1 (9)	2 (14.3)	0.9‡
Not available	6	5	
Teeth with bone loss ≥ 4 mm (%)	69.6 ± 27.8 (33–100)	69.3 ± 35.5 (21–100)	0.8*
Edentulous	9 (52.9)	7 (36.8)	0.11†
Implant age¶	8.3 ± 2.8 (2–13)	9.4 ± 3.4 (3–17)	0.2*
PI	48.3 ± 28.6 (5–100)	50.7 ± 28.8 (10–100)	0.9*
BOP	64.4 ± 21.0 (25–100)	75.1 ± 23.5 (33–100)	0.17*

\*Mann–Whitney test.

†Fisher's exact test.

‡ $\chi^2$  test.

§In Group 1 data on six patients and in Group 2 data on five patients were missing due to long time edentulouism. One patient in Group 1 and 2 patients in Group 2 had bone loss around <30% around their teeth.

¶Data on two patients in Group 1 not available.

||Data in one patient missing.

PI, plaque index; BOP, bleeding on probing.

Table 2. Baseline clinical and radiographic measurements at implants, in Group 1 (bone substitute+membrane)  $N=29$ , and in Group 2 (bone substitute)  $N=36$ , at implants. Means  $\pm$  SD (range)

Variable	Baseline: mean $\pm$ SD (range)		
	Group 1	Group 2	$p$
PD*	5.44 $\pm$ 1.78 (3;11)	5.64 $\pm$ 1.84 (3;11)	0.18
PAL <sup>†</sup>	6.82 $\pm$ 1.98 (3;12)	7.09 $\pm$ 2.10 (4;12) <sup>‡</sup>	0.6
MR <sup>§</sup>	1.38 $\pm$ 1.50 (0;4)	1.91 $\pm$ 2.13 (-1;8) <sup>‡</sup>	0.3
Bone loss <sup>¶</sup> (threads)	5.62 $\pm$ 1.99 (3;11.5)	4.74 $\pm$ 1.37 (3;8)	0.04
Bone loss <sup>  </sup> (mm)	3.37 $\pm$ 1.19 (1.8;6.9)	2.84 $\pm$ 0.82 (1.8;4.8)	0.04

\*Probing depth, at the deepest site.

<sup>†</sup>Probing attachment level, at the deepest site.

<sup>‡</sup>One patient with three implants were excluded in the baseline comparison in PAL and MR, as no abutments were used between the suprastructure and the implant.

<sup>§</sup>Mucosal recession, at the deepest site.

<sup>¶</sup>Number of threads not supported by bone on radiographs, mean of mesial and distal site.

<sup>||</sup>Each thread measure 0.6 mm.

Table 3. Bleeding index score (%) at baseline and at the 1 year control in Group 1 (bone substitute+membrane)  $N=29$  (116 sites), and in Group 2 (bone substitute)  $N=36$  (144 sites)

Bleeding score	Group 1				Group 2			
	0	1	2	3	0	1	2	3
Baseline	20.7	4.3	69.8	5.2	7.1	8.6	77.9	6.4
1 year	78.4	12.1	9.5	0	75.0	9.3	15.7	0

Table 4. Bleeding index score change since baseline observed after 1 year; highest score-change observed on implant level, in Group 1 (bone substitute+membrane)  $N=29$ , and in Group 2 (bone substitute)  $N=36$ . Numbers (%)

Score-change since baseline*	Group1	Group2	$p$ <sup>†</sup>
0	0 (0%)	4 (11.1%)	0.8
1	2 (6.9%)	2 (5.6%)	
2	25 (86.2%)	26 (72.2%)	
3	2 (6.9 %)	4 (11.1%)	

\*For each of the four implant sites, the difference between baseline and 1 year scores was calculated. The maximum site-level score on implant level was then calculated.

<sup>†</sup>Comparing the binary response variable " $\geq 2$  or  $< 2$  bleeding score change" between the treatment groups.

for numerical variables, Fisher's exact test for binary variables and the  $\chi^2$  test for categorical variables (Altman 1991).

Treatment response data were compared (i.e. observed changes between baseline and 1-year follow-up) between the two patient groups (Group 1 *versus* 2). The baseline and response data on implant level are likely to be correlated within patients. Therefore, linear mixed models (SPSS for Windows, Release 11.5.1, SPSS Inc., Chicago, USA) for the following baseline variables were used at baseline on implant level: PD, PAL, MR and bone loss and treatment response variable, PD reduction, probing attachment gain, MR and defect fill. Treatment response variables on implant

level with a few outcome values, viz. defect fill and bleeding index-score change, were dichotomized in order to use logistic regression with random effects (EGRET for windows, Version 2.0, Cytel soft Corp., USA) as the binary outcome observations within patients might be correlated (EGRET for Windows User Manual 1999).

Data on reported complications (on patient level) were compared between the patient groups by the  $\chi^2$  test (Altman 1991); exact  $p$ -values were calculated (StatXact-6, Cytel Software Corp.). By using the linear-mixed models and logistic regression with random effects, "clustering" effects of implant-level data within patients are taken into consideration.

## Results

Patient characteristics are presented in Table 1. A majority of the patients were current or former smokers; only 5.9% in Group 1 and 10.5% in Group 2 were non-smokers. The total plaque and bleeding scores were 48.3% and 64.4% for Group 1 and 50.7% and 75.1% for Group 2, respectively. Periodontitis defined as bone loss of  $\geq 4$  mm at existing teeth or at teeth before extraction was evident in around 69% of the teeth in both groups.

Baseline clinical measurements at treated implants are presented in Table 2. The mean PD at baseline was around 5.5 mm in both groups. There was no significant difference between PD, PAL or MR. However, a mean of 5.6 threads in Group 1 were not supported by bone compared with 4.7 threads in Group 2 ( $p=0.04$ ). The mean PD at all sites at baseline was 4.3 mm in Group 1 and 4.9 mm in Group 2. When probing the sulcus, pus occurred at 48 % of the implants in Group 1 and 40 % in Group 2.

BOP was a frequent finding at baseline, whereas 78% of the sites in Group 1 and 75% of the sites in Group 2 did not bleed at the 1-year examination (Table 3). Bleeding index score changes are presented in Table 4. In Group 1, 86% and in Group 2, 72% changed bleeding score two steps between baseline and the 1-year examination. There was no significant difference between the groups.

The effects of treatment are presented in Table 5. The mean PD reduction was 2.9 mm in Group 1 and 3.4 mm in Group 2. Probing attachment gain was 1.6 mm in Group 1 and 1.8 mm in Group 2. The mean defect fill in millimetre was 1.5 mm (2.5 threads) in Group 1 and 1.4 mm (2.4 threads) in Group 2 (Fig. 3a and b). There was no significant difference between the groups. No implants were lost during the follow-up period; however, one implant demonstrated continued bone loss.

No significant differences between the groups were found with regard to defect fill  $\geq 2$  threads (1.2 mm) (Table 6). More than or equal to 4 threads (2.8 mm) of defect fill were obtained in 35% of the implants in Group 1 and 33% in Group 2. Bone loss  $\geq 2$  threads was observed only in one implant in Group 2 (Table 7).

Clinical healing complications are presented in Table 8. A good primary

Table 5. Results of treatment on implant level observed after 1 year in Group 1 (bone substitute+membrane)  $N = 29$  and in Group 2 (bone substitute)  $N = 36$ . Means  $\pm$  SD (range)

Variable	Baseline: mean $\pm$ SD (range)		$P$
	Group 1	Group 2	
PD*	2.86 $\pm$ 2.00 (0;9)	3.44 $\pm$ 1.58 (0;9)	0.19
PAL†	1.59 $\pm$ 2.0 (-2;7)	1.8 $\pm$ 1.37 (-1;4)	0.6
MR‡	-1.28 $\pm$ 1.51 (-5;0)	-1.61 $\pm$ 1.61 (-6;0)	0.4
Defect fill§ (number of threads)	2.53 $\pm$ 1.94 (-1;6.5)	2.4 $\pm$ 2.12 (-1.5;7)	0.8
Defect fill¶ (mm)	1.52 $\pm$ 1.16 (-0.6;3.9)	1.44 $\pm$ 1.27 (-0.9;4.2)	0.8

\*Probing depth reduction, at the deepest site.

†Probing attachment gain, at the deepest site.

‡Mucosal recession, at the deepest site.

§Defect fill. Mean of mesial and distal site.

¶Each thread measure 0.6 mm.

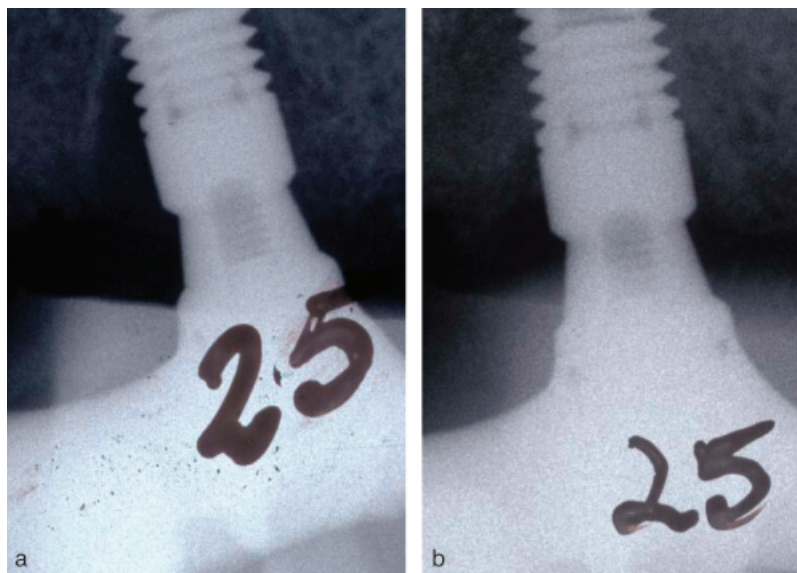


Fig. 3. (a) Initial radiograph demonstrating peri-implant bone loss. (b) One-year radiograph demonstrating defect fill.

Table 6. Defect changes since baseline observed after 1 year in Group 1 (bone substitute+membrane)  $N = 29$  and in Group 2 (bone substitute)  $N = 36$ . Numbers (%)

Defect change	Group 1	Group 2	$P^*$
Defect fill			
≥2 threads	22 (75.9%)	24 (66.7%)	0.8
Bone loss			
≥2 threads	0	1 (2.8)	
no difference			
± 1 thread	7 (24.1%)	11 (30.5%)	

\*Comparing the binary response variable bone level change or not between the treatment groups.

closure was accomplished in both groups, although in Group 1, in 11.8% of the implants, a complete primary closure was not accomplished. At a few implants, 15–17% in both groups, blanching occurred in the flap margin after suturing when pulling the lip, and almost all implants demonstrated soft

tissue craters after 2 weeks. There was no significant difference between the groups.

When membranes were used, membrane exposure after 2 weeks was noted in 43.8% of the treated implants (Fig. 4). Complications, as reported by the patients are shown in Table 9. Most

Table 7. Defect changes since baseline observed after 1 year in Group 1 (bone substitute+membrane)  $N = 29$  and in Group 2 (bone substitute)  $N = 36$ . Numbers (%)

Bone level change threads	No. (%)	
	Group 1	Group 2
-2 threads	0 (0)	1 (2.8)
-1 thread	2 (6.9)	3 (8.3)
0 thread	3 (10.3)	2 (5.6)
1 thread	2 (6.9)	6 (16.7)
2 threads	5 (17.2)	8 (22.2)
3 threads	7 (24.1)	4 (11.1)
4 threads	1 (3.4)	5 (13.9)
5 threads	8 (27.6)	4 (11.1)
6 threads	0 (0)	2 (5.6)
7 threads	1 (3.4)	1 (2)

patients did not report any complications, and there was no significant difference.

## Discussion

In this study, the effect of a bone substitute with or without the concomitant use of a resorbable membrane was used to treat osseous defects due to peri-implantitis.

The first 19 consecutive individuals were allocated to Group 1 and next 19 patients to Group 2. This may have influenced the results of the study even though the treatment groups became quite comparable regarding baseline data (see Table 1). Operator bias and increase in competence in treating peri-implantitis may, however, inevitably have affected the outcome of the different treatment modalities.

The majority of the patients in this study were smokers with a history of periodontitis disease. Fifty per cent of the patients reported that they had lost their teeth due to periodontitis, and using bone loss  $\geq 4$  mm at  $\geq 30\%$  of the teeth as a definition of periodontitis, before implant placement, around 60% of the patients were classified as periodontitis patients. Both smoking and periodontitis have been reported to be patient-related risk factors for peri-implantitis (Karoussis et al. 2004, Roos-Jansåker et al. 2006b).

Smoking is considered to be a major risk factor for periodontal disease (Bergström et al. 1991, Bergström & Preber 1994), and has been demonstrated to negatively influence treatment outcome following periodontal regenerative procedures (Tonetti et al. 1995, Rosén et al. 1996, Mayfield et al. 1998, Trombelli et al.

Table 8. Clinical healing features (% implants) in Group 1 (bone substitute+membrane)  $N = 29$  and in Group 2 (bone substitute)  $N = 36$

	Group 1	Group 2
Primary flap disclosure (at surgery)	11.8	0
Wound instability (at surgery)	37.5	14.3
Blanching (at surgery)	15.6	17.1
Soft tissue craters (at 2 weeks)	82.4	78.9
Membrane exposure (at surgery)	9.4	–
Membrane exposure (at 2 weeks)	43.8	–
Membrane exposure (at 7 weeks)	34.4	–
Membrane exposure (at 3 months)	3.1	–

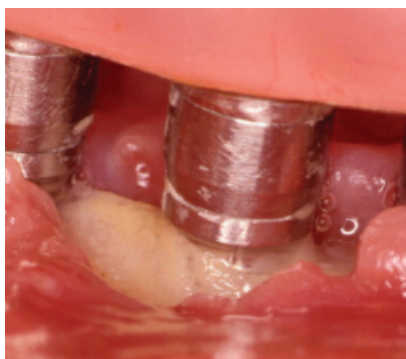


Fig. 4. Membrane exposure.

1997, Kornman & Robertson 2000). Smoking is also considered to be a risk factor during wound healing following fixture placement (Sadig & Almas 2004), and less favourable results were obtained among smokers treated for peri-implantitis in a 5-year follow-up study (Leonhardt et al. 2003). The treatment result in this study may accordingly have been affected by the fact that the majority of the patients were smokers. In spite of the possible negative influence of smoking on the healing following therapy, the results from this study regarding probing attachment gain are comparable with the results from a recent study evaluating bone substitutes in a non-smoking population (Schwarz et al. 2006a).

Pocket depth at the deepest site ranged from 3 to 11 mm, with an overall mean pocket depth of 4.3 and 4.9 mm. Probing has been recommended to detect peri-implant disease (Salvi & Lang 2004). Mombelli et al. (1997), evaluating probing forces around implants, concluded that peri-implant PD measurements were more sensitive to force variation than periodontal pocket probing, and this was particularly noticeable using low probing forces. In spite of the fact that probing measurements in the present study were obtained after the suprastructure was removed, the probing force of 25 N chosen

Table 9. Reported healing complications and adverse events by the patients. Group 1 (bone substitute+membrane)  $N = 17$  and in Group 2 (bone substitute)  $N = 19$

	Group 1	Group 2	$p$
None	15	12	0.13
Pain (% patients)	1	1	1.0
Swelling (% patients)	1	2	1.0
Allergic reactions to the antibiotics	None	1	1.0

seemed to be inadequate to allow the probe to penetrate to the bottom of the sulcus, around some implants. From a clinical point of view, the variability in probing measurements may make it difficult to diagnose peri-implantitis predictably without using radiographs.

Attachment-level measurements have been used to evaluate periodontal-treatment outcome (Badersten et al. 1990, Renvert & Persson 2002). Clinical attachment level gain may, to some degree, reflect bone-level changes. However, the clinical measurements (PD/attachment level) do not necessarily mirror hard tissue changes and therefore probing bone-level measurements have been used (Kolonidis et al. 2003). In order not to interfere with the healing process in the transplanted area, bone-level measurements were not used in this study. However, in this study, the attachment gain (1.6–1.8 mm) mirrors the hard-tissue fill registered on radiographs (1.4–1.5 mm).

A majority of the sites in both groups demonstrated BOP at baseline. Bleeding (scores 2 and 3) was found at 75–84% of the sites compared with 10–16% 1 year after treatment. Absence of bleeding around teeth has been considered to be a sign of healthy gingival tissues (Lang et al. 1990). The improved bleeding scores after treatment found in the present study indicate a clinically healthier situation 1 year after therapy compared with baseline.

Defect fill (graft material and possible newly formed bone), at proximal sites, was evaluated using radiographs. Two threads (1.2 mm) were used as a diagnostic cut-off value, as minor differences in angulations could not be ruled out, although a system in order to obtain identical radiographs was used. Defect fill occurred in  $\geq 2$  threads in around 71% of all treated implants and 51% of the implants had at least 1.8 mm (3 threads) of defect fill. There was no significant difference between the groups. The mean defect fill (measured on radiographs mesially and distally at each implant) in this study was 2.5 threads (1.5 mm) in Group 1 and 2.4 threads (1.4 mm) in Group 2. In a study by Khoury & Buchmann (2001), treating advanced peri-implant intra-bony defects, using an autologous bone graft alone or in combination with a resorbable or non-resorbable membrane, and a submerged healing period, a radiographic bone fill of 1.7 mm was demonstrated in the group with bone graft in combination with a resorbable membrane. The use of autologous bone, with its possible osseointegrative potential, combined with a submerged healing phase, did not result in bone-level changes more favourable than the ones in the present study. The results from the present study are encouraging, as it is an advantage for the patient to avoid the extra surgery needed to obtain autologous bone for the transplantation. Also, clinically it may not be possible to allow submerged healing in all situations. Although defect fill has been demonstrated in this study, it is not known whether it is bone or graft material as no histological data were available.

Surgical technique and flap management are important variables for the healing outcome following periodontal surgery (Cortellini 2006). In the present study, blanching of the flaps occurred in around 16% of the surgeries, indicating tension in the flaps. Membrane exposure was a frequent phenomenon, which is in agreement with many previous studies (see review by Roos-Jansåker et al. 2003). Regardless of the use of membranes, soft-tissue craters were commonly found. This has also been reported by others and may be related to the surgical technique used and/or membrane exposure (see review by Roos-Jansåker et al. 2003).

In conclusion, both surgical techniques resulted in clinically healthy situations around the treated implants

evidenced by low bleeding scores, a reduction of PD, gain of probing attachment and defect fill.

### Acknowledgements

We acknowledge and thank Professor Ulf Strömberg, University of Lund, Sweden, for help with the statistical analyses, Professor Jan Egelberg for comments on the manuscript, Senior consultant in maxillofacial radiology Håkan Håkansson, Kristianstad Hospital, Sweden, for valuable help with analysis of the radiographs, Senior consultant in prosthodontics Torgil Rundq-rantz, Kristianstad, Sweden, for help with removal of the suprastructures in the first patients and Dental technician Magnus Ervik, Kristianstad, Sweden, for modifying the probe.

### References

- Altman, D. G. (1991) *Practical Statistics for Medical Research*, 1st edition, pp. 194–197, 241–257, 173 London: Chapman & Hall.
- Badersten, A., Nilvéus, R. & Egelberg, J. (1990) Scores of plaque, bleeding, suppuration and probing depth to predict probing attachment loss. 5 years of observation following non-surgical therapy. *Journal of Clinical Periodontology* **17**, 102–107.
- Bergström, J., Eliasson, S. & Preber, H. (1991) Cigarette smoking and periodontal bone loss. *Journal of Periodontology* **62**, 242–246.
- Bergström, J. & Preber, H. (1994) Tobacco use as a risk factor. *Journal of Periodontology* **65**, 545–550.
- Cortellini, P. (2006) Reconstructive periodontal surgery: a challenge for modern periodontology. *International Dental Journal* **56** (Suppl. 1), 250–255.
- EGRET for Windows (1999) *Software for Analysis of Biomedical and Epidemiological Studies. User Manual*. Cambridge, MA, USA: CYTEL, Software Corporation.
- Esposito, M., Hirsch, J. M., Lekholm, U. & Thomsen, P. (1998) Biological factors contributing to failures of osseointegrated oral implants. (II) etiopathogenesis. *European Journal of Oral Sciences* **106**, 721–764.
- Hürzeler, M. B., Quinones, C. R., Schüpbach, P., Morrison, E. C. & Caffesse, R. G. (1997) Treatment of peri-implantitis using guided bone regeneration and bone grafts, alone or in combination, in beagle dogs. Part 2: histological findings. *International Journal of Oral and Maxillofacial Implants* **12**, 168–175.
- Jovanovic, S. A., Kenney, B., Carranza, F. A. & Donath, K. (1993) The regenerative potential of plaque-induced peri-implant bone defects treated by a submerged membrane technique: an experimental study. *International Journal of Oral and Maxillofacial Implants* **8**, 13–18.
- Karoussis, I. K., Müller, S., Salvi, G. E., Heitz-Mayfield, L. J. A., Brägger, U. & Lang, N. P. (2004) Association between periodontal and peri-implant conditions: a 10-year prospective study. *Clinical Oral Implants Research* **15**, 1–7.
- Khoury, F. & Buchmann, R. (2001) Surgical therapy of peri-implant disease: a 3-year follow-up study of cases treated with 3 different techniques of bone regeneration. *Journal of Periodontology* **72**, 1498–1508.
- Kolonidis, S. G., Renvert, S., Hämmerle, C. H. F., Lang, N. P., Harris, D. & Claffey, N. (2003) Osseointegration on implant surfaces previously contaminated with plaque. An experimental study in the dog. *Clinical Oral Implants Research* **14**, 373–380.
- Kornman, K. & Robertson, P. (2000) Fundamental principles affecting the outcomes of therapy for osseous lesions. *Periodontology* **2000** **22**, 22–43.
- Kreisler, M., Kohnen, W., Christoffers, A. B., Gotz, H., Jansen, B., Duschner, H. & d'Hoedt, B. (2005) *In vitro* evaluation of the biocompatibility of contaminated implant surfaces treated with an Er:YAG laser and an air powder system. *Clinical Oral Implants Research* **16**, 36–43.
- Lang, N. P., Adler, R., Joss, A. & Nyman, S. (1990) Absence of bleeding on probing. An indicator of periodontal stability. *Journal of Clinical Periodontology* **17**, 714–721.
- Leonhardt, Å., Dahlen, G. & Renvert, S. (2003) Five-year clinical, microbiological, and radiographical outcome following treatment of peri-implantitis in man. *Journal of Periodontology* **74**, 1415–1422.
- Mayfield, L., Söderholm, G., Hallström, H., Kullendorff, B., Edwardsson, S., Bratthall, G., Brägger, U. & Attström, R. (1998) Guided tissue regeneration for treatment of intraosseous defects using a bioabsorbable membrane. A controlled clinical study. *Journal of Clinical Periodontology* **25**, 585–595.
- Mombelli, A., Mühle, T., Brägger, U., Lang, N. P. & Bürgin, W. B. (1997) Comparison of periodontal and peri-implant probing by depth-force pattern analysis. *Clinical Oral Implants Research* **8**, 448–454.
- Persson, L., Berglundh, T., Lindhe, J. & Sennerby, L. (2001) Re-osseointegration after treatment of peri-implantitis at different implant surfaces. An experimental study in the dog. *Clinical Oral Implants Research* **12**, 595–603.
- Quirynen, M., De Soete, M. & van Steenberghe, D. (2002) Infectious risks for oral implants: a review of the literature. *Clinical Oral Implants Research* **13**, 1–19.
- Renvert, S., Badersten, A., Nilvéus, R. & Egelberg, J. (1981) Healing after treatment of periodontal intraosseous defects. I. Comparative study of clinical methods. *Journal of Clinical Periodontology* **8**, 387–399.
- Renvert, S. & Persson, R. (2002) A systemic review on the use of residual probing depth, bleeding on probing and furcation status following initial periodontal therapy to predict further attachment and tooth loss. *Journal of Clinical Periodontology* **3**, 82–89.
- Romeo, E., Ghisolfi, M., Murgolo, N., Chiapasco, M., Lops, D. & Vogel, G. (2005) Therapy of peri-implantitis with resective surgery. A 3-year clinical trial on rough screw-shaped oral implants. Part I: clinical outcome. *Clinical Oral Implants Research* **16**, 9–18.
- Roos-Jansäker, A. M., Lindahl, C., Renvert, H. & Renvert, S. (2006a) Nine- to fourteen-year follow-up of implant treatment. Part II: presence of peri-implant lesions. *Journal of Clinical Periodontology* **33**, 290–295.
- Roos-Jansäker, A. M., Lindahl, C., Renvert, H. & Renvert, S. (2006b) Nine- to fourteen-year follow-up of implant treatment. Part III: factors associated with peri-implant lesions. *Journal of Clinical Periodontology* **33**, 296–301.
- Roos-Jansäker, A. M., Renvert, S. & Egelberg, J. (2003) Treatment of peri-implant infections: a literature review. *Journal of Clinical Periodontology* **30**, 467–485.
- Rosén, P. S., Marks, M. H. & Reynolds, M. A. (1996) Influence of smoking on long-term results of intrabony defects treated with regenerative therapy. *Journal of Periodontology* **67**, 1159–1163.
- Sadig, W. & Almas, K. (2004) Risk factors and management of dehiscence wounds in implant dentistry. *Implant Dentistry* **13**, 140–147.
- Salvi, G. & Lang, N. P. (2004) Diagnostic parameters for monitoring peri-implant conditions. *International Journal of Oral and Maxillofacial Implants* **19** (Suppl. 3), 116–127.
- Schou, S., Berglundh, T. & Lang, N. P. (2004) Surgical treatment of peri-implantitis. *International Journal of Oral and Maxillofacial Implants* **19** (Suppl.), 140–149.
- Schou, S., Holmstrup, P., Jorgensen, T., Skovgaard, L. T., Stoltze, K., Hjorting-Hansen, E. & Wenzel, A. (2003a) Implant surface preparation in the surgical treatment of experimental peri-implantitis with autogenous bone graft and ePTFE membrane in cynomolgus monkeys. *Clinical Oral Implants Research* **14**, 412–422.
- Schou, S., Holmstrup, P., Skovgaard, L. T., Stoltze, K., Hjorting-Hansen, E. & Gundersen, H. J. (2003b) Autogenous bone graft and ePTFE membrane in the treatment of peri-implantitis. II. Stereologic and histologic observations in cynomolgus monkeys. *Clinical Oral Implants Research* **14**, 404–411.
- Schwarz, F., Bieling, K., Latz, T., Nuesry, E. & Becker, J. (2006a) Healing of intrabony peri-implantitis defects following application of a noncrystalline hydroxyapatite (Ostim™) or a bovine-derived xenograft (Bio-Oss™) in combination with a collagen membrane (Bio-Gide™). A case series. *Journal of Clinical Periodontology* **33**, 491–499.
- Schwarz, F., Papanicolaou, P., Rothamel, D., Beck, B., Herten, M. & Becker, J. (2006b) Influence of plaque biofilm removal on establishment of the biocompatibility of contaminated titanium surfaces. *Journal of Biomedical Materials and Research A* **77**, 437–444.

- Shibli, J., Martins, M., Nociti, F., Garcia, V. & Marcantonio, E. (2003) Treatment of ligature-induced peri-implantitis by lethal photosensitization and guided bone regeneration: a preliminary histologic study in dogs. *Journal of Periodontology* **74**, 338–345.
- Shibli, J., Martins, M., Ribeiro, F., Garcia, V., Nociti, F. & Marcantonio, E. (2006) Lethal photosensitization and guided bone regeneration in treatment of peri-implantitis: an experimental study in dogs. *Clinical Oral Implants Research* **17**, 273–281.
- Teughels, W., Van Assche, N., Sliepen, I. & Quirynen, M. (2006) Effect of material characteristics and/or surface topography on biofilm development. *Clinical Oral Implants Research* **17** (Suppl. 2), 68–81.
- Tonetti, M. S., Pini-Prato, G. & Cortellini, P. (1995) Effect of cigarette smoking on periodontal healing following GTR in intrabony defects. A preliminary retrospective study. *Journal of Clinical Periodontology* **22**, 229–234.
- Trombelli, L., Kim, C. K., Zimmerman, G. J. & Wikesjö, U. M. E. (1997) Retrospective analysis of factors related to clinical outcome of guided tissue regeneration procedures in intrabony defects. *Journal of Clinical Periodontology* **24**, 366–371.

Address:  
 Stefan Renvert  
 Department of Health Sciences  
 Kristianstad University  
 291 88 Kristianstad  
 Sweden  
 E-mail: stefan.renvert@hv.hkr.se

**Clinical Relevance**

*Scientific rationale for the study:* Limited information is available regarding defect fill following surgical treatment of peri-implantitis lesions in humans.

*Principal findings:* Placing a bone substitute material in the defect, with or without a resorbable membrane, resulted in clinical and radiographic improvements after 1 year.

*Practical implications:* It seems unnecessary to use a resorbable membrane to cover the bone substitute in peri-implantitis defects.