

Detection of Vertical Root Fractures in Endodontically Treated Teeth by a Cone Beam Computed Tomography Scan

Bassam Hassan, BDS, MSc,^{*‡} Maria Elissavet Metska, DDS, MSc,^{‡#} Ahmet Rifat Ozok, DDS, PhD,[†] Paul van der Stelt, DDS, PhD,^{*} and Paul Rudolf Wesselink, DDS, PhD[†]

Abstract

Our aim was to compare the accuracy of cone beam computed tomography (CBCT) scans and periapical radiographs (PRs) in detecting vertical root fractures (VRFs) and to assess the influence of root canal filling (RCF) on fracture visibility. Eighty teeth were endodontically prepared and divided into four groups. The teeth in groups A and B were artificially fractured, and teeth in groups C and D were not. Groups A and C were root filled. Four observers evaluated the CBCT scans and PR images. Sensitivity and specificity for VRF detection of CBCT were 79.4% and 92.5% and for PR were 37.1% and 95%, respectively. The specificity of CBCT was reduced ($p = 0.032$) by the presence of RCF, but its overall accuracy was not influenced ($p = 0.654$). Both the sensitivity ($p = 0.006$) and overall accuracy ($p = 0.008$) of PRs were reduced by the presence of RCF. The results showed an overall higher accuracy for CBCT (0.86) scans than PRs (0.66) for detecting VRF. (*J Endod* 2009;35:719–722)

Key Words

Cone-beam computed tomography scan, diagnosis, periapical radiograph, root canal filling, vertical root fracture

From the Departments of *Oral and Maxillofacial Radiology; †Cariology Endodontology Pedodontlogy, Academic Centre for Dentistry Amsterdam (ACTA), Amsterdam, The Netherlands. ‡Bassam Hassan and Maria Elissavet Metska contributed equally to this manuscript.

Address requests for reprints to Dr Ahmet Rifat Ozok, Department of Cariology Endodontology Pedodontlogy, Academic Centre for Dentistry Amsterdam, Louwesweg 1 1066 EA Amsterdam, The Netherlands. E-mail address: r.ozok@acta.nl.

0099-2399/\$0 - see front matter

Copyright © 2009 American Association of Endodontists. doi:10.1016/j.joen.2009.01.022

A definitive diagnosis of vertical root fractures (VRFs) in endodontically treated teeth is challenging. The clinical symptoms and radiographic signs are not completely pathognomonic (1–7), although dual sinus tracts or sinus tract–like pockets on opposite sides of a root are considered almost pathognomonic for a VRF (8). The prognosis of VRF is poor. In a 5-year follow-up study of nonsurgically endodontically treated teeth, root fracture was the untoward event in 32.1%, and the elected treatment was extraction (9).

Because periapical radiographs (PRs) are two-dimensional (2D) images of three-dimensional anatomic structures, the superimposition of adjacent tissues may obscure the visibility of VRFs. Thus, direct visualization of a radiolucent fracture line on radiographs is the only explicit feature for detecting VRFs. A three-dimensional diagnostic imaging system could diagnose VRF more accurately. Conventional multidetector computed tomography (MDCT) scans were found superior to PRs in detecting VRFs (10). However, the radiation dose involved in MDCT scans, the limited availability, and the increased costs impede its use in dentistry (11, 12). Cone beam computed tomography (CBCT) scans, which provide comparable images at reduced dose and costs, are a better alternative to MDCT scans in endodontics (13, 14). CBCT scans use a cone-shaped x-ray beam to acquire a three-dimensional scan of the patient head in a single 360° rotation (15).

Prototype local computed tomography scans and flat-panel detector CBCT systems that are used to scan ex vivo tissue samples were found useful for detecting VRFs (16, 17). The feasibility of clinical dental CBCT systems with a rotating x-ray tube and detector apparatus in detecting VRFs is thus far unknown. Also, because VRFs are most commonly associated with endodontically treated teeth, it is important to assess the possible influence of root canal filling on fracture line visibility.

The first aim of this study was to evaluate the accuracy of a clinical dental CBCT system in comparison with digital PRs in detecting VRFs in root-filled and nonfilled teeth. The second aim was to assess the influence of gutta-percha root canal filling on the detection of VRFs with CBCT scans or PRs.

Materials and Methods

Sample Preparation

Eighty extracted human teeth (40 premolars and 40 molars) were inspected using a stereomicroscope (Wild Photomakroskop M400, Wild, Heerbrugg, Switzerland) for the absence of VRFs. Access opening was made for each tooth, and the root canals were prepared with the ProTaper rotary system (Dentsply Maillefer, Tulsa, OK) until size F3. The teeth were divided into four groups: two experimental (A and B) and two controls (C and D). Each group consisted of 10 premolars and 10 molars ($n = 20$), which were decoronated to eliminate bias of enamel fractures.

In groups A and B, the teeth were stabilized in copper rings filled with light body impression material (Express 2 VPS; 3M ESPE, Zoeterwoude, The Netherlands), and a holder was used to fix the samples in place. A tapered chisel inserted in the canal space was tapped gently with a hammer to induce a VRF. The fractured teeth were inspected again under the stereomicroscope to confirm the presence of VRFs. The fracture line orientation (buccolingual or mesiodistal) was also recorded. A well-fitting gutta-percha cone was inserted in the canals of groups A and C. One investigator, who was not involved in the observation, coded the teeth and placed them in premade sockets in

10 dry human mandibles bilaterally in the posterior region. The mandibles were coated with three layers of dental wax buccally and lingually to simulate soft tissue. Agar-agar (Merck, Darmstadt, Germany) was used to fix the teeth in these holes and to fill the gaps between the root surface and the socket.

Radiographic Scan

The sample was scanned using the I-CAT CBCT (120 KvP, 5 mA; Imaging Sciences, Hatfield, PA). The scans were made according to the manufacturer's recommended protocol to scan the mandible with the 10 × 16 cm field of View (FoV) selection. The datasets were exported in DICOM 3 file format, and the size of the isotropic voxel was 0.25 mm. The PR images were made with a fixed x-ray unit (Siemens Heliodent MD, Erlangen, Germany) and size 2 phosphor-plate films (Digora, Tuusula, Finland) following manufacturer's recommendations, two radiographs per tooth, one using parallel technique and the other with mesial angulation.

Data Analysis

The images were imported into image analysis and visualization software (Amira 4.2.0; Visage Imaging, Carlsbad, CA). Orthographic tomographic reconstructions were created in axial, sagittal, and coronal directions. Four observers (two endodontists and two fourth-year dental students) were calibrated by training them in CBCT images using dummy datasets from a pilot study. All images were displayed on a 21-inch flat-panel screen (Philips Brilliance, Amsterdam, The Netherlands). Each observer assessed the presence or absence of a VRF on a dichotomous scale (fractured/nonfractured). CBCT images were reviewed in the three reconstruction planes (axial, coronal, and sagittal), and a single score was obtained for each tooth (Fig. 1). PR images were reviewed, and a single score was also obtained per tooth.

The radiographic features for detecting a VRF on a CBCT scan were the direct visualization of a radiolucent line, which traversed the trunk of the root separating it either partially or completely into two segments that is followed on at least two consecutive slices (10). The radiographic feature for detecting VRF on PRs was also the direct visualization of a radiolucent line, which traversed the root surface on either the parallel or the mesially angulated images.

Statistical Analysis

The data were analyzed on SPSS 16.0 software (SPSS Benelux, Gorinchem, The Netherlands). A two-sided chi-square test was used to measure the sensitivity and specificity of both CBCT scans and PRs for the detection of VRF. A univariate analysis of variance was used to assess the influence of the radiographic technique (CBCT scans or PRs), filling material (filled or nonfilled), and the level of expertise (endodontists or dental students) on overall accuracy in detecting VRFs. Overall sensitivity and specificity were first calculated for all teeth and then separately for filled and nonfilled teeth. Sensitivity was also calculated per fracture orientation (buccolingual and mesiodistal). The overall agreement among the observers was measured by using Cohen's kappa. The alpha value was set to 0.05.

Results

The sensitivity and specificity results for CBCT scans and PRs are reported in Table 1. The overall sensitivity of detecting VRFs was significantly higher for CBCT scans compared with PRs ($p = 0.0001$). The overall specificity of CBCT scans was slightly lower than PRs but not significantly different ($p = 0.489$). CBCT scans were overall significantly more accurate than PRs in detecting VRFs ($p = 0.0001$). The accuracy of CBCT scans was 0.86 and that of PRs was 0.66.

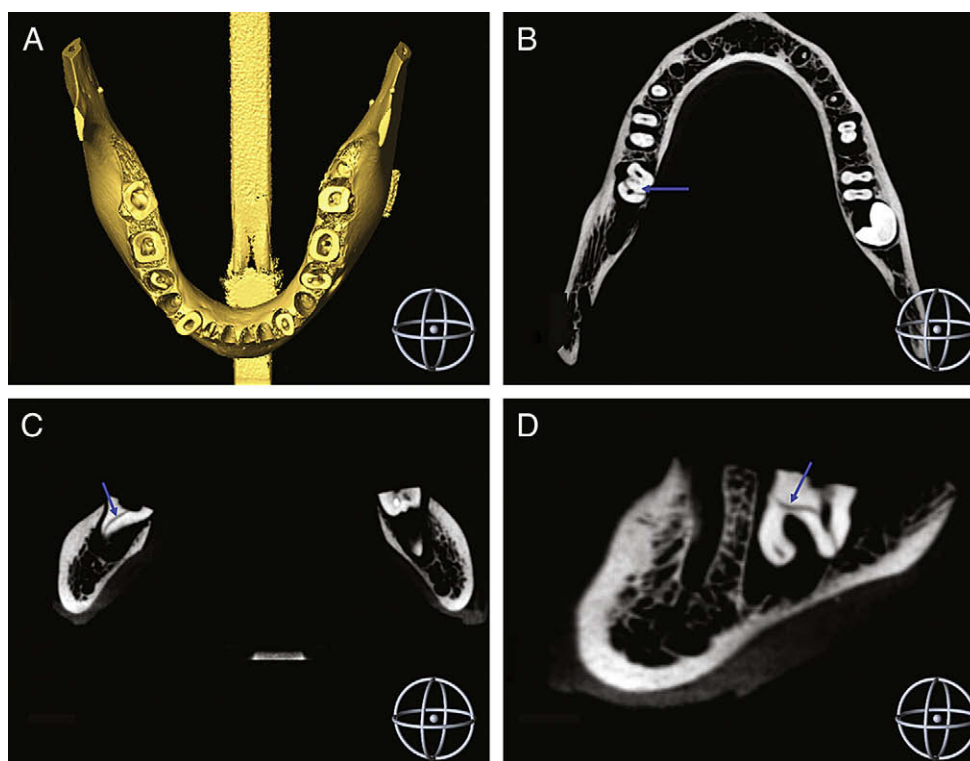


Figure 1. I-CAT CBCT reconstructions. (A) Three-dimensional surface reconstruction of the mandible. Fracture line is visible on 2D slices (arrow). (B) Axial, (C) coronal, and (D) sagittal.

TABLE 1. Overall Sensitivity and Specificity Percentages of CBCT Scans and PRs per Observer Group and Root Filling.

Scanner	Endodontists	Dental Students	Both Groups	Root Filled	Non Filled	Bucco Lingual	Mesio Distal
CBCT							
Sensitivity	77.5	81.3	79.4	78.8	80.0	87.0	63.5
Specificity	91.3	93.8	92.5	87.5	97.5	—	—
PR							
Sensitivity	37.5	36.7	37.1	26.6	47.5	51.4	7.7
Specificity	95.0	95.0	95.0	93.8	96.2	—	—

CBCT, cone beam computed tomography; PR, periapical radiograph. Sensitivity results per fracture line orientation (bucco lingual and mesio distal).

The presence of root canal filling (RCF) did not significantly influence the sensitivity of CBCT scans ($p = 0.84$), but it reduced their specificity ($p = 0.016$). For PRs, the presence of RCF reduced sensitivity ($p = 0.006$) with no significant influence on specificity ($p = 0.471$). The presence of RCF reduced overall accuracy of PRs ($p = 0.008$) but not that of CBCT scans ($p = 0.654$). Of all fractured roots, fracture lines in 67.5% were in the buccolingual direction and 32.5% were in the mesiodistal direction (Fig. 2). The sensitivity of CBCT scans was higher than PRs for detecting both buccolingual and mesiodistal fractures (Table 1).

The overall agreement among the observers was moderate ($\kappa = 0.521$). There was no significant difference in overall accuracy between and among the observers for detecting VRFs by both CBCT scans and PRs ($p = 0.76$).

Discussion

This study investigated the feasibility of CBCT scans in detecting VRFs in endodontically treated teeth. The results show an overall higher accuracy of CBCT scans in comparison with PRs. The overall sensitivity of CBCT scans was significantly higher than PRs in detecting fracture lines. The high sensitivity of CBCT scans is evidently caused by the higher inherent contrast of tomographic imaging in comparison with conventional 2D projection imaging. The three-dimensional nature of CBCT scans allows visualizing the fracture line from multiple angles and different orientations at very thin slices and at a very high contrast. Conversely, the 2D nature of PRs obscured the visibility of the fracture line because of the inherent superimposition artifact, which may explain the low sensitivity of PRs in detecting VRFs. The overall specificity was high and comparable for both CBCT scans and PRs. The high specificity for PRs could be explained by the fact that most teeth were scored negatively for VRF because most fractures were not visible.

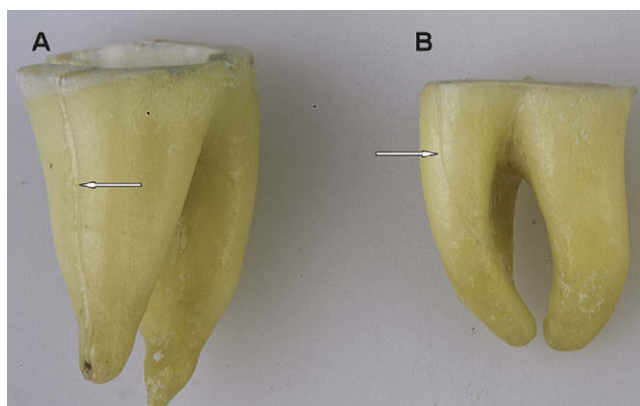


Figure 2. A light photograph showing vertical root fracture on two teeth by fracture line orientation (arrow). (A) Mesiodistal and (B) buccolingual.

Although the overall accuracy of CBCT scans was not reduced by the presence of RCF, its specificity was reduced. Radiopaque substances such as gutta-percha cones create distinct star-shaped streak artifacts on tomographic slices that can mimic fracture lines on CBCT images (18), which may decrease observer confidence in diagnosing VRFs. On the other hand, RCF significantly reduced the overall accuracy of PRs and the overall sensitivity, leading to more false-negative results. In accord with previous findings, there were more buccolingual fractures (67.5%) than mesiodistal fractures (32.5%) in this study (15). Therefore, it is probable that most of the fracture lines were obscured by the filling. The sensitivity of PRs for detecting mesiodistal fractures was very low (7.7%) compared with the detection of buccolingual fractures (51.4%). The mesiodistal fractures are almost impossible to detect with 2D radiographs because the x-ray beam must be within 4° of the fracture plane to allow detection (19). In fact, this suggests that the sensitivity of PR could have been even lower if there were more mesiodistal fractures in the sample. The sensitivity of CBCT scans was higher than PRs for both fracture types (87% and 63.5%), respectively.

Both observer groups were comparable in their ability to detect VRF on both systems with no observable predilection of the more experienced group over the less experienced group. Both groups received similar training during the calibration session and the detection criteria of a VRF on both systems were clearly defined, which can explain this lack of significant difference. The detection of VRF was limited by the voxel size (0.25 mm) and the contrast-to-noise ratio of the selected scan field. The method in which the fractures were created may not reflect the actual clinical situation. For example, the distance between the fragments may in some teeth slightly deviate from that generally seen in vivo. However, our aim was to compare the accuracy of the two radiographic techniques, and this was performed under same conditions for both techniques.

Our results corroborate previous findings that CBCT scans are superior to PRs in detecting longitudinal root fractures (16, 17). Previous studies used prototype CBCT systems, which are not clinical and cannot be used to scan patients. Also, they have different scanning and reconstruction settings from dental CBCT systems currently available. In those studies, the influence of the presence of RCF on the visibility of VRFs was not assessed either. More research is required to determine patient scanning and data-reconstruction parameters with CBCT scans that could influence the visibility of the fracture line. In conclusion, CBCT scans are more accurate than PRs for detecting VRFs, and the presence of RCF does not reduce its accuracy.

Acknowledgment

We would like to thank Dr Hans Verbeij for his contribution in conducting the statistical analysis and Dr H. de Jonge for his support with the I-CAT scans.

References

1. Tamse A, Fuss Z, Lustig J, Ganor Y, et al. Radiographic features of vertically fractured, endodontically treated maxillary premolars. *Oral Surg Oral Med Oral Pathol Oral Radiol Endod* 1999;88:348–52.
2. Tamse A, Fuss Z, Lustig J, et al. An evaluation of endodontically treated vertically fractured teeth. *J Endod* 1999;25:506–8.
3. Tamse A, Kaffe I, Lustig J, et al. Radiographic features of vertically fractured endodontically treated mesial roots of mandibular molars. *Oral Surg Oral Med Oral Pathol Oral Radiol Endod* 2006;101:797–802.
4. Tamse A. Vertical root fractures in endodontically treated teeth: diagnostic signs and clinical management. *Endod Topics* 2006;13:84–94.
5. Krell KV, Rivera EM. A six year evaluation of cracked teeth diagnosed with reversible pulpitis: treatment and prognosis. *J Endod* 2007;33:1405–7.
6. Opdam NJ, Roeters JJ, Loomans BA, et al. Seven-year clinical evaluation of painful cracked teeth restored with a direct composite restoration. *J Endod* 2008;34:808–11.
7. Shemesh H, van Soest G, Wu M-K, et al. Diagnosis of vertical root fractures with optical coherence tomography. *J Endod* 2008;34:739–42.
8. Pitts DL, Natkin E. Diagnosis and treatment of vertical root fractures. *J Endod* 1983;9:338–46.
9. Chen SC, Chueh LH, Hsiao CK, et al. First untoward events and reasons for tooth extraction after nonsurgical endodontic treatment in Taiwan. *J Endod* 2008;34:671–4.
10. Youssefzadeh S, Gahleitner A, Dorffner R, et al. Dental vertical root fractures: value of CT in detection. *Radiology* 1999;210:545–9.
11. Ludlow JB, Ivanovic M. Comparative dosimetry of dental CBCT devices and 64-slice CT for oral and maxillofacial radiology. *Oral Surg Oral Med Oral Pathol Oral Radiol Endod* 2008;106:106–14.
12. Cotton TP, Geisler TM, Holden DT, et al. Endodontic applications of cone-beam volumetric tomography. *J Endod* 2007;33:1121–32.
13. Loubele M, Bogaerts R, Van Dijk E, et al. Comparison between effective radiation dose of CBCT and MSCT scanners for dentomaxillofacial applications. *Eur J Radiol* 2008. in press.
14. Tsiklakis K, Donta C, Gavala S, et al. Dose reduction in maxillofacial imaging using low dose cone beam CT. *Eur J Radiol* 2005;56:413–7.
15. Patel S, Dawood A, Ford TP, et al. The potential applications of cone beam computed tomography in the management of endodontic problems. *Int Endod J* 2007;40:818–30.
16. Mora MA, Mol A, Tyndall DA, et al. In vitro assessment of local computed tomography for the detection of longitudinal tooth fractures. *Oral Surg Oral Med Oral Pathol Oral Radiol Endod* 2007;103:825–9.
17. Hannig C, Dullin C, Hülsmann M, et al. Three-dimensional, non-destructive visualization of vertical root fractures using flat panel volume detector computer tomography: an *ex vivo in vitro* case report. *Int Endod J* 2005;38:904–13.
18. Zhang Y, Zhang L, Zhu XR, et al. Reducing metal artifacts in cone-beam CT images by preprocessing projection data. *Int J Radiat Oncol Biol Phys* 2007;67:924–32.
19. Rud J, Omnell K. Root fractures due to corrosion. Diagnostic aspects. *Scand J Dent Res* 1970;78:397–403.