


available at [www.sciencedirect.com](http://www.sciencedirect.com)journal homepage: [www.intl.elsevierhealth.com/journals/jden](http://www.intl.elsevierhealth.com/journals/jden)

## Review

# A paradigm shift in endodontic management of immature teeth: Conservation of stem cells for regeneration

George T.-J. Huang\*

University of Maryland, College of Dental Surgery, Dental School, Department of Endodontics, Prosthodontics and Operative Dentistry, 650 West Baltimore Street, Baltimore, MD 21201, United States

### ARTICLE INFO

#### Article history:

Received 11 January 2008

Received in revised form

4 March 2008

Accepted 4 March 2008

#### Keywords:

Stem cells

Regenerative endodontics

Immature teeth

Apexogenesis

Apexification

### ABSTRACT

**Objective:** This article will review the new concept of regenerative endodontics in the management of immature permanent teeth. The potential role of stem cells to regenerate immature permanent teeth after conservative treatment will be discussed.

**Data and sources:** Two sets of data source are focused in this review: (i) the characterization of various dental stem cells discovered since 2000 and (ii) recent clinical case reports showing that after conservative treatment, severely infected immature teeth with periradicular periodontitis and abscess can undergo healing and apexogenesis or maturogenesis.

**Results:** A new protocol of treating endodontically involved immature permanent teeth based on published articles to date is summarized in the review. The key procedures of the protocol are (1) minimal or no instrumentation of the canal while relying on a gentle but thorough irrigation of the canal system, (2) the disinfection is augmented with intra-canal medication of a triple-antibiotic paste between appointments, and (3) the treated tooth is sealed with mineral trioxide aggregate (MTA) and glass ionomer/resin cement at the completion of the treatment. Periodical follow-ups will take place to observe any continued maturation of the root.

**Conclusion:** While more clinical research is needed, regenerative endodontics promotes a paradigm shift in treating endodontically involved immature permanent teeth from performing apexification procedures to conserving any dental stem cells that might remain in the disinfected viable tissues to allow tissue regeneration and repair to achieve apexogenesis/maturogenesis.

© 2008 Elsevier Ltd. All rights reserved.

## 1. Introduction

Two scientific disciplines have made major progress in the recent decade. One is Stem Cell Biology and the other is Tissue Engineering. These two lines of research have promoted the emergence of regenerative medicine. Although its exact definition is still being discussed in the scientific community, generally regenerative medicine is defined as a process that

combines diverse disciplines aiming at creating living, functional tissues to regenerate, repair or replace tissue or organ function lost due to age, disease, damage, or congenital defects. The diverse disciplines include stem cell biology, cellular and molecular biology, gene therapy, chemical engineering, nanotechnology, tissue engineering, etc. Regenerative medicine provides the elements and designs the replacements for in vivo repair, stimulating the body's

\* Tel.: +1 410 706 7680; fax: +1 410 706 3028.

E-mail address: [ghuang@umaryland.edu](mailto:ghuang@umaryland.edu).

0300-5712/\$ – see front matter © 2008 Elsevier Ltd. All rights reserved.

doi:10.1016/j.jdent.2008.03.002

intrinsic capacities for regeneration. The elements may be growth factors or live cells and the replacement may be engineered tissues established *in vitro* ready for transplantation.<sup>1-3</sup>

Modern concept of medicine emphasizes prevention and reversal of the diseases. Only when these attempts failed will we take on the unfavorable approaches, i.e., surgical intervention and restoration with artificial prostheses. Utilization of stem cells to regenerate the lost tissues may thereby reverse tissues to their normal state. Regenerative endodontics deals with the healing of impaired dental tissues, including dentin, pulp, cementum and periodontal tissues. The endodontic community is highly motivated in the promotion of tissue regeneration research and practice.<sup>4</sup> The American Association of Endodontists has established a Regenerative Endodontics Committee and its mission is to promote related scientific research and clinical practice as well as evaluating the role of the association in regenerative endodontics.

There are two approaches to practice regenerative endodontics. One is to take the more conservative treatment approach for well-selected cases which is to be discussed in this article. The other is to advance tissue engineering technologies for dentin, pulp, cementum and periodontal ligament regeneration, which currently is either still at the laboratory stage or in animal studies. Recent isolation and characterization of adult dental stem cells and the emergence of regenerative medicine concept, clinicians should re-evaluate current clinical protocols when treatment planning of certain clinical cases. This is especially important in dealing with immature teeth, as they are still at the growing phase and likely to carry potent stem cells that enables the tissue to regenerate and repair better than matured tissues. Therefore, a clinical protocol that favors the reservation and conservation of the harbored stem cells in the tissue should be considered.

The goal of this review article has two folds. First, to understand the process of tissue regeneration, one should first understand stem cell biology. There will be a brief review of the definition of stem cells, their characteristics and properties, particularly the recently discovered dental stem cells. Second, while the utilization of tissue engineering technologies to regenerate endodontic tissues is still unavailable at present, certain clinical observations published recently have shed light on the possibility of practicing regenerative endodontics on selected immature permanent teeth. The key is the establishment of a clinical protocol that will be discussed thoroughly in the text, i.e., conservation of stem cells to allow endodontic tissue self-regeneration in disinfected immature permanent teeth.

---

## 2. Recent progress on dental stem cell research

Stem cell biology has become an important field for the understanding of tissue regeneration, although much knowledge in this area has been from the *in vitro* studies. In general, stem cells are defined by having two major properties: (1) they are capable of self-renewal and (2) when they divide, some daughter cells give rise to cells that eventually become differentiated cells. Depending on the type of stem cells and

their ability and potency to become different tissues, the following categories of stem cells have been established—(i) totipotent stem cells: each cell is capable of developing into an entire organism; (ii) pluripotent stem cells: cells from embryos (embryonic stem cells) that when grown in the right environment *in vivo* are capable of forming all types of tissues; and (iii) multipotent stem cells: postnatal stem cells or commonly called adult stem cells that are capable of giving rise to multiple lineages of cells.<sup>5</sup> Dental stem cells belong to the third category as described below.

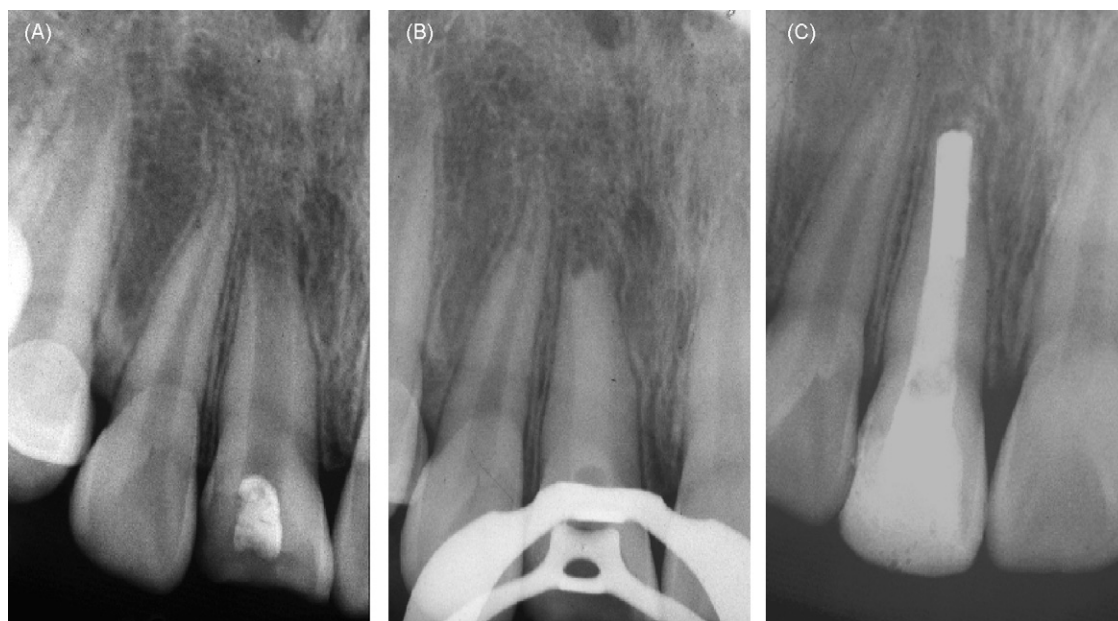To date, four types of human dental stem cells have been isolated and characterized: (i) dental pulp stem cells (DPSCs),<sup>6</sup> (ii) stem cells from exfoliated deciduous teeth (SHED),<sup>7</sup> (iii) stem cells from apical papilla (SCAP),<sup>8,9</sup> and (iv) periodontal ligament stem cells (PDLSCs)<sup>10</sup>. Among them, all except SHED are from permanent teeth. These dental stem cells are considered as mesenchymal stem cells (MSCs) and possess different levels of capacities to become specific tissue forming cells. DPSCs and SHED are from the pulp and SCAP is from the pulp precursor tissue, apical papilla. These *ex vivo* expanded cells can differentiate into odontoblast-like cells and produce dentin-like tissue in both *in vitro* and *in vivo* study systems. When grown in cultures and induced under specific conditions, DPSCs and SHED can differentiate into neuronal and adipogenic cells in addition to dentinogenic cells.<sup>7,11</sup> Some reports have shown that DPSCs also have chondrogenic, myogenic and osteogenic potentials,<sup>12-15</sup> although rather weak compared to MSCs from bone marrow. SCAP together with PDLSCs are able to form a root-like structure when seeded onto the hydroxyapatite-based scaffold and implanted in pig jaws.<sup>8</sup> These dental stem cells may potentially be utilized for dental tissue regeneration, i.e., pulp/dentin and periodontal ligament.<sup>16-18</sup> More importantly, the identification of these dental stem cells provided us a better understanding of the biology of pulp and periodontal ligament tissues and their regenerative potential after tissue damage. For example, the observation of severely infected pulp in immature teeth capable of undergoing complete root maturation after proper disinfection procedures may be explained by the possibility that SCAP somehow survive from infection.<sup>9,19</sup>

---

## 3. Recent endodontic case reports on treatment of immature teeth

Individuals of age 6-16 are having sequential permanent tooth eruption and maturation of the roots. Any factors that inflict upon the normal physiological process of pulp may interfere with the completion of root development. Losing immature teeth is difficult to manage as the jaws are still in development, any restorative procedure is likely to be a temporary measure. Because of the important role of Hertwig's epithelial root sheath (HERS) in continued root development, after pulpal injury, every effort should be made to maintain its viability.<sup>20</sup>

Two distinct clinical situations require to be well defined before a clinical treatment approach can be determined because of the dramatic difference in their clinical outcomes. The first situation is dealing with the immature teeth with vital pulp. A procedure that induces *apexogenesis* is undertaken



**Fig. 1 – Traditional apexification with calcium hydroxide. (A) Tooth #8 of an 11-year old was tested non-vital with open apex. (B) The canal was cleaned and shaped and filled with calcium hydroxide every 3 months until an apical stop was detected. (C) The apical half of the canal was filled with gutta-percha and the remaining canal with composite (1 year after initial treatment).**

to preserve the remaining vital tissue and to allow completion of root formation and apical maturation.<sup>21–23</sup> The second is the immature teeth with necrotic pulp. Apexification is then performed to treat immature teeth with non-vital pulp by inducing a calcific barrier at the open apex.<sup>20,21</sup> Teeth after apexogenesis with vital pulp therapy develop a normal thickness of dentin, root length and apical morphology, whereas teeth receiving apexification normally gain only an apical hard tissue bridge without a further development of the root (Fig. 1).

Recently, several clinical case reports demonstrated that despite the formation of periapical abscesses with extensive periradicular bone resorption as the result of root canal infection in immature teeth, conservative treatment may allow root development to reach their maturation.<sup>19,22,24–26</sup> The interest generated from this clinical observation appears to be underscored by the discovery of some of the dental stem cells mentioned above, which may shed light on the understanding of the repair of the pulpodentin complex, healing within the root canal space and the continued maturation of roots after endodontic treatment of the immature permanent teeth.

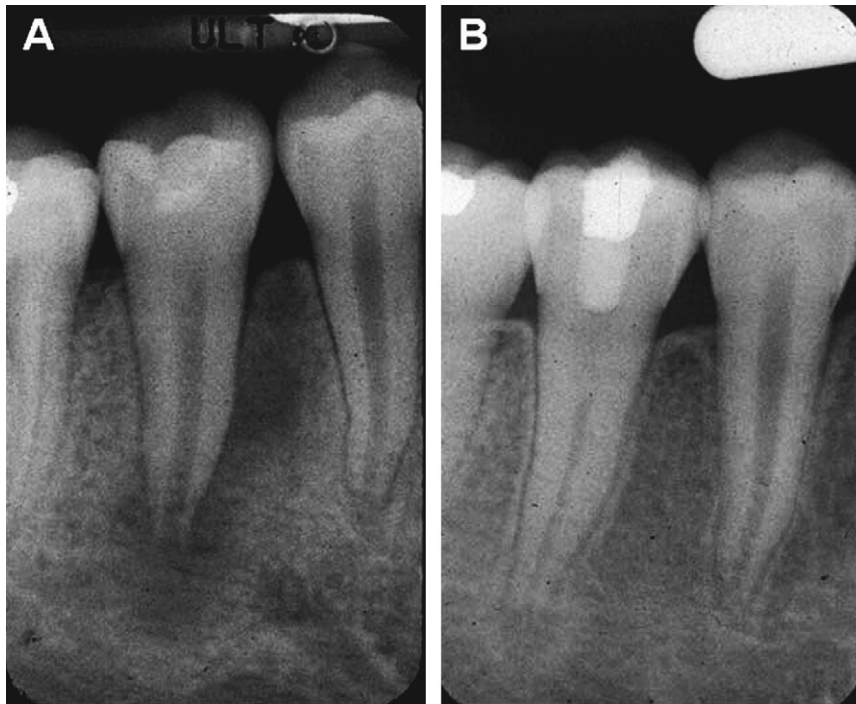
#### **4. More conservative approach in the management of immature teeth—paradigm shift**

The common clinical indications for vital pulp therapy are cases having mechanical, traumatic or carious pulp exposure. Direct pulp capping may be carried out as needed. A shallow pulpotomy (Cvek pulpotomy) is performed when the pulp is minimally exposed by mechanical reason or trauma, whereas when the pulp injury or inflammation is more extensive,

pulpotomy may be the optimal approach.<sup>27</sup> In principle, immature teeth should be treated as conservatively as practical to allow any possible apexogenesis to occur.<sup>28</sup> Therefore, pulp capping is the first treatment of choice if the pulp is considered largely normal. For cases that the coronal pulp tissue has more advanced damage or inflammation, pulpotomy is the next treatment of choice in the hope to reserve the vitality of the remaining pulp in the canals.<sup>20,27</sup>

While the decision for teeth undergoing apexogenesis or apexification has been determined by the result of pulp vitality, i.e., vital pulp/apexogenesis vs non-vital pulp/apexification; recent case reports have shown that this straightforward dichotomized approach may sacrifice certain cases that still have the potential to undergo apexogenesis even when clinical condition qualifies for an apexification treatment. These case reports have shown convincingly that immature teeth clinically diagnosed with non-vital pulp with periradicular periodontitis or abscess can undergo apexogenesis.<sup>19,24–26</sup> In fact, before these recent reports that provoked us to rethink the traditional conception, there had been sporadic case reports in the literature documenting this observation.<sup>29–34</sup> One explanation is that the clinical diagnosis of pulp vitality is inaccurate that some of those teeth must have remaining vital tissues in the pulp space despite that the vitality test was negative.

These reports stimulated a new perspective as to how we determine the treatment plans for these cases. A common aspect of the reported cases<sup>19,24,25</sup> is that those teeth showing continual maturation of root and apex had developed extensive periradicular lesions with sinus tract formation before the treatment—a condition normally considered a total necrosis and infection of the pulp and requires apexification (Figs. 2–4). Most reasonable explanation is that certain



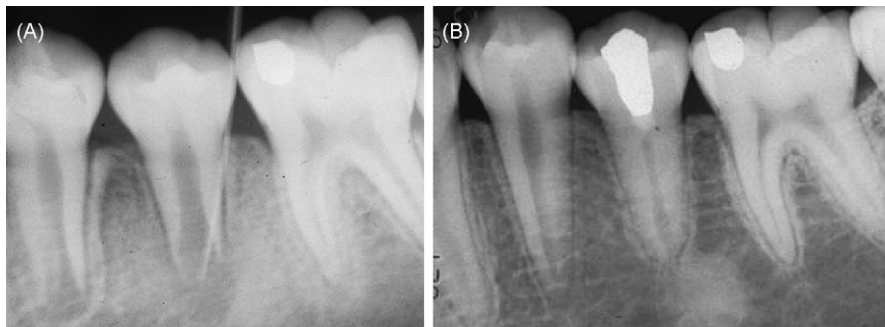**Fig. 2 – Clinical case of a 10-year-old patient. (A) Radiograph showing an immature root of tooth #29 with an open apex and an extensive radiolucency at the periapical and mesial regions of the root. (B) Seven months after the initial treatment showing complete maturation of the root apex, healing of the periradicular bone, a significant increase of the calcified tissue in the root, a significant decrease of root canal space, and the calcified coronal third of the root canal. The pulp chamber and the accessed space were filled with Cavition and Ketac silver, respectively. (Adapted from the original article with approval.<sup>19</sup>)**

important types of cells and tissues must have survived after the disinfection, thereby allowing the root to undergo maturation, for example, the HERS and SCAP in the apical papilla. SCAP have been proposed to be the cell source of root odontoblasts.<sup>9</sup>

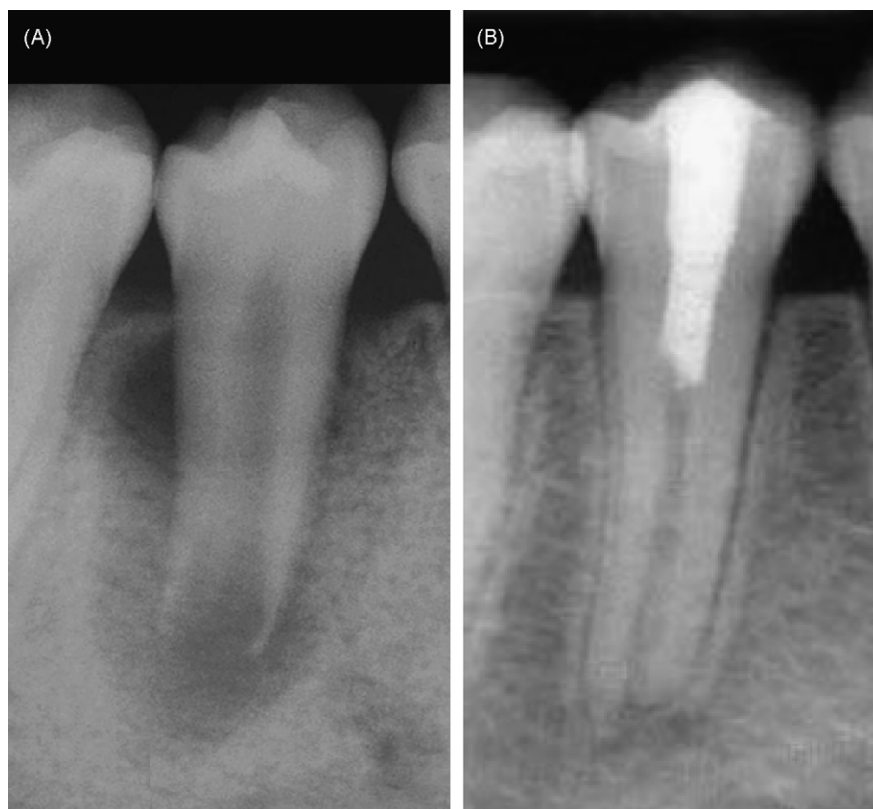#### 4.1. Case selection

Currently there is no evidence-based guideline that can be established to help clinicians determine which condition of cases that can be treated with this conservative approach. As

mentioned, the presence of radiolucency at the periradicular region can no longer be used as a determining factor, nor is the vitality test. In both situation, vital pulp tissue or apical papilla may still present in the canal and at the apex. Logically, any remnant of visible soft tissue that can be visualized under the microscope should give the clinician an incentive to take the conservative approach, even though the soft tissue may be purely granulation tissues. However, one cannot rule out the possibility that there are not any remaining pulp tissues in the very apical part of the canal only because it cannot be detected clinically.



**Fig. 3 – Clinical case of a 10-year-old patient. (A) Radiograph showing a radiolucent lesion at the periapical area of tooth #20 with a wide-open apex (a gutta-percha point into the sinus tract). (B) Thirty-five months after the initial treatment revealing a marked reduction of the root canal space and maturation of the root apex. The accessed cavity was filled with Cavition and amalgam. (Adapted from the original article with approval.<sup>19</sup>)**



**Fig. 4 – (A) Radiograph showing a lower premolar (#29) of an 11-year-old patient having an extensive periradicular lesion. (B) Twenty-four-month radiograph after treatment showing complete root development. (Adapted from the original article with approval.<sup>25</sup>)**

Another obvious consideration is the duration of the infection. Hypothetically, the longer standing of an infected pulp in immature teeth there is the less survived pulp tissue and stem cells may remain. Additionally, the longer the infection there is in the canal, the more likelihood of a deeper penetration of microbial colonies into dentinal tubules that would occur, which renders the disinfection more difficult to accomplish.

Since there is a lack of clinical studies on the success rate of treating immature teeth with periradicular bone resorption, clinicians may consider always choosing the conservative approach first. Apexification is only undertaken when the attempt is failed.

#### 4.2. Disinfection protocol

The management of these immature teeth in the case reports has the following features: (a) minimal or no instrumentation; (b) irrigation with 2.5–5.25% NaOCl, 3% hydrogen peroxide and/or Peridex; and (c) intra-canal medication with antimicrobial agents consisting of equal parts of metronidazol, minocycline and ciprofloxacin in a paste form at the concentration of 20 mg/ml (Professional Compounding Centers of America, Houston, TX).<sup>35–37</sup> It was recommended by the authors in these case reports that calcium hydroxide is not recommended as intra-canal medicament to prevent damage of the remaining pulp tissue, apical papilla and HERS.<sup>19,25</sup> The

gentle treatment regimen is an attempt to conserve any viable tissues that may be remained in the canal system which harbor stem cells, i.e., SCAP in the apical papilla and DPSCs in the pulp. Cooke and Robotham in 1988 advised avoidance of trauma to the tissue around the apex. They speculated that the remnants of the survived HERS at the apices of immature teeth, after disinfection, may organize the apical mesodermal tissue into root components<sup>38</sup>. This mesodermal tissue is now considered to be the apical papilla by Sonoyama et al.<sup>9</sup>

Based on these case reports, a clinical protocol to treat immature teeth after a thorough irrigation may be established and is summarized as the following: (a) The antimicrobial paste is to be introduced into the canal carefully to a depth slightly shy of the remaining vital tissue with a lentulo spiral and the accessed cavity sealed with 2 mm-thick cavite as an inner layer and 2 mm-thick durable cement such as glass ionomer as the outer layer. (b) After 2 weeks, the patient should return for evaluation. If the tooth is asymptomatic and lack of clinical signs of pathology, the canal will be re-accessed to visually examine the condition under the microscope. If there is no observable virulent exudate, the canal system will be irrigated with NaOCl and chlorhexidine followed by sterile normal saline and then dried. A small piece of collacote may be placed at the pulp chamber to support the MTA cement which is to be placed over it. The accessed cavity will then be sealed with glass ionomer or resin-modified glass ionomer cement and the tooth should be followed up periodically to

observe the maturation of the root. The use of MTA is for its excellent microleakage-proof property and biocompatibility. Additional placement with glass ionomer/resin further secures the sealing ability and the integrity of the filled access. If after several rounds of intra-canal irrigation and medication the clinical symptoms show no sign of improvement, i.e., persistent presence of sinus tract, swelling and/or pain, apexification procedure should then be carried out.

#### 4.3. The use of antimicrobial paste

Since the introduction of  $\text{Ca}(\text{OH})_2$  as an intra-canal medication, it has been a popular clinical regimen over the use of antibiotic paste especially in the case of apexification.<sup>20</sup> However, if there is remaining vital pulp tissue in the canal, the direct contact of  $\text{Ca}(\text{OH})_2$  paste with the tissue will induce the formation of a layer of calcific tissue which may occupy the pulp space therefore preventing the pulp tissue to regenerate into that space. As shown in Fig. 2, calcific layer was formed in the coronal third of the canal due to the placement of  $\text{Ca}(\text{OH})_2$  which prevented the pulp tissue to grow into that space.<sup>19</sup> Whereas by using the antibiotic paste, the pulp tissue appears to be able to fill in the remaining canal space as shown in Fig. 4 and the cases presented by Iwaya et al.<sup>24</sup> and by Thibodeau and Trope.<sup>26</sup> Another concern is that  $\text{Ca}(\text{OH})_2$  may damage the HERS and thereby losing its ability to induce the nearby undifferentiated cells to become odontoblasts.<sup>25</sup>

The triple-antibiotics regimen was first tested by Sato et al. to be effective against the *Escherichia coli* infected dentin in vitro.<sup>35</sup> The same research group also tested their bactericidal efficacy against microbes from carious dentin and infected pulp. They found that the mixture of antibiotics is sufficiently potent to eradicate the bacteria.<sup>36</sup> The clinical effectiveness of the triple-antibiotic paste in the disinfection of immature teeth with apical periodontitis has been reported.<sup>39</sup> The concern of the antibiotic paste is that it may cause bacterial resistance. Also, the paste contains both bactericidal (metronidazol and ciprofloxacin) and bacteriostatic (minocycline) antibiotics. Additionally, whether minocycline will cause tooth discoloration like the Ledermix requires investigation.<sup>40,41</sup>

#### 4.4. Blood clot formation in canal space

Some investigators<sup>25,26</sup> induced hemorrhage by an endodontic explorer penetrating slightly into the remaining pulp tissue or periapical tissue allowing the blood clot to form in the canal and stopped at a level 3 mm below CEJ. MTA was then placed over the blood clot. They considered the blood clot as a scaffold and source of growth factors to facilitate the regeneration and repair of tissues into the canal. Induction of bleeding to facilitate healing is a common surgical procedure. It was proposed by Ostby in 1961 to induce hemorrhage and form blood clot in the canal space of mature teeth in the hope to guide the tissue repair in the canal.<sup>42</sup> Myers and Fountain in 1974 attempted to regenerate dental pulp with blood clot filled in the canal.<sup>43</sup>

Currently, there is lack of histological evidence showing that blood clot is required for the formation of repaired tissues in the canal space, nor are there systematic clinical studies to

show that this approach is significantly better than without it. However, these cases reports at least provide some guidelines as to what extent the healing potential these immature teeth are capable of. One study using a dog model showed no statistical significance of healing by inducing blood clot into the canal, although the authors of the study suggested the inclusion of blood clot to improve the chance of healing.<sup>37</sup>

#### 4.5. Outcome

Given a condition that is free of infection, many tissues are programmed and capable of self-regeneration to repair the damaged portion. The literature is replete with the finding that if disinfection can be performed effectively, pulp tissue can heal and new dentin bridge will form.<sup>44</sup> Pulp tissue in immature teeth with open apex has larger volume of pulp tissue with a rich blood supply which may explain why it is more potent in defending infection and to heal. Farsi et al. found a success rate of 93% with evidence of continued root growth after using MTA as direct pulp capping to treat carious exposure in young permanent teeth.<sup>45</sup> In contrast, the success rate of direct pulp capping with carious exposure is only 33.3% in mature teeth.<sup>46</sup>

As noted above, clinical experience on the outcome of those teeth that inherit a thin and weak root after successful apexification is that they are susceptible to fracture.<sup>47</sup> Shifting apexification to apexogenesis even for teeth that show a negative response to pulp vitality test and with periradicular periodontitis or abscess is a clinically beneficial approach for the patients. Whether the thickened root is formed by pulp tissue from the remaining vital pulp and dental papilla at the apical region, or that is formed by PDL tissue which has grown into the root canal from the apical foramen and deposited the cementum onto the inner surface of the root dentin, is not clear. One may speculate that there was survived pulp tissue that allowed apexogenesis to occur. The dental papilla at the apex contains stem cells (SCAP) that have been recently described to be more robust stem cells than DPSCs.<sup>8</sup> The SCAP may survive the infection to allow root maturation while the survived DPSCs in the remaining vital pulp rebuild the lost pulp tissue in the canal and may give rise to replacement odontoblasts to substitute for the damaged primary odontoblasts.<sup>9</sup> Iwaya et al.<sup>24</sup> suggested that the open apex provide a good communication from pulp space to the periapical tissues, therefore it may be possible for periapical disease to occur while the pulp is only partially necrotic and infected. Deposition of cementum or bone in the canal may also occur and gradually narrowing the space. The studies using rhesus monkey demonstrated that after total pulp tissue removal in immature teeth, either treated with calcium hydroxide or collagen gel, there was cementum tissue formation at the apex and in the canal. PDL-like tissue can also be found in canal treated with collagen gel.<sup>48,49</sup> Similar results were obtained using dogs as a study model.<sup>37</sup> Although it lacks data from clinical research to show what the success rate is by the conservative treatment of the infected human immature teeth, the study on dogs demonstrated that after successful disinfection of the root canals, 64.6% of the cases had no radiographic evidence of periapical radiolucencies or showed improvement/healing of previous periapical radiolucencies.<sup>37</sup>

## 5. Conclusion and prospects

Although the healing potential and defense mechanism of pulp have been long recognized, the intensity and the nature of the virulence of infection are still the determining factors for the outcome of pulp recovery. Immature teeth, by having a large and young pulp tissue and an open apex to allow good blood supply, remarkable healing potential has been observed in conditions that would not have been possible for mature teeth. The discovery and understanding of pulp stem cells provide us a better insight into the healing potential of the immature teeth. Along with an improved regimen of canal disinfection, it seems to be the right time to establish a new protocol for a paradigm shift in treating these infected immature teeth. In the same time, clinical and basic research is urgently needed to provide information on the success rate of this treatment modality.

## REFERENCES

1. NIH. Regenerative medicine. *National Institute of Health Fact Sheet* 2006; [www.nih.gov/about/researchresultsforthepublic/Regen.pdf](http://www.nih.gov/about/researchresultsforthepublic/Regen.pdf).
2. Mason C, Dunnill P. A brief definition of regenerative medicine. *Regenerative Medicine* 2008;**3**:1–5.
3. Daar AS, Greenwood HL. A proposed definition of regenerative medicine. *Journal of Tissue Engineering and Regenerative Medicine* 2007;**1**:179–84.
4. Murray PE, Garcia-Godoy F, Hargreaves KM. Regenerative endodontics: a review of current status and a call for action. *Journal of Endodontics* 2007;**33**:377–90.
5. Robey PG, Bianco P. The use of adult stem cells in rebuilding the human face. *Journal of the American Dental Association* 2006;**137**:961–72.
6. Gronthos S, Mankani M, Brahimi J, Robey PG, Shi S. Postnatal human dental pulp stem cells (DPSCs) in vitro and in vivo. *Proceedings of the National Academy of Sciences* 2000;**97**:13625–30.
7. Miura M, Gronthos S, Zhao M, Lu B, Fisher LW, Robey PG, et al. SHED: stem cells from human exfoliated deciduous teeth. *Proceedings of the National Academy of Sciences* 2003;**100**:5807–12.
8. Sonoyama W, Liu Y, Fang D, Yamaza T, Seo BM, Zhang C, et al. Mesenchymal stem cell-mediated functional tooth regeneration in Swine. *PLoS ONE* 2006;**1**:e79.
9. Sonoyama W, Liu Y, Yamaza T, Tuan RS, Wang S, Shi S, et al. Characterization of the apical papilla and its residing stem cells from human immature permanent teeth: a pilot study. *Journal of Endodontics* 2008;**34**:166–71.
10. Seo BM, Miura M, Gronthos S, Bartold PM, Batouli S, Brahimi J, et al. Investigation of multipotent postnatal stem cells from human periodontal ligament. *Lancet* 2004;**364**:149–55.
11. Gronthos S, Brahimi J, Li W, Fisher LW, Cherman N, Boyde A, et al. Stem cell properties of human dental pulp stem cells. *Journal of Dental Research* 2002;**81**:531–5.
12. Zhang W, Walboomers XF, Shi S, Fan M, Jansen JA. Multilineage differentiation potential of stem cells derived from human dental pulp after cryopreservation. *Tissue Engineering* 2006;**12**:2813–23.
13. d'Aquino R, Graziano A, Sampaolesi M, Laino G, Pirozzi G, De Rosa A, et al. Human postnatal dental pulp cells co-differentiate into osteoblasts and endothelial cells: a pivotal synergy leading to adult bone tissue formation. *Cell Death & Differentiation* 2007.
14. Laino G, d'Aquino R, Graziano A, Lanza V, Carinci F, Naro F, et al. A new population of human adult dental pulp stem cells: a useful source of living autologous fibrous bone tissue (LAB). *Journal of Bone and Mineral Research* 2005;**20**:1394–402.
15. Laino G, Carinci F, Graziano A, d'Aquino R, Lanza V, De Rosa A, et al. In vitro bone production using stem cells derived from human dental pulp. *Journal of Craniofacial Surgery* 2006;**17**:511–5.
16. Huang G, Sonoyama W, Chen J, Park S. In vitro characterization of human dental pulp cells: various isolation methods and culturing environments. *Cell and Tissue Research* 2006;**324**:225–36.
17. Ivanovski S, Gronthos S, Shi S, Bartold PM. Stem cells in the periodontal ligament. *Oral Diseases* 2006;**12**:358–63.
18. Nakashima M, Akamine A. The application of tissue engineering to regeneration of pulp and dentin in endodontics. *Journal of Endodontics* 2005;**31**:711–8.
19. Chueh L-H, Huang GTJ. Immature teeth with periradicular periodontitis or abscess undergoing apexogenesis: a paradigm shift. *Journal of Endodontics* 2006;**32**:1205–13.
20. Rafter M. Apexification: a review. *Dental Traumatology* 2005;**21**:1–8.
21. Bishop BG, Woollard GW. Modern endodontic therapy for an incompletely developed tooth. *General Dentistry* 2002;**50**:252–6.
22. Goldstein S, Sedaghat-Zandi A, Greenberg M, Friedman S. Apexification & apexogenesis. *The New York State Dental Journal* 1999;**65**:23–5.
23. Webber RT. Apexogenesis versus apexification. *Dental Clinics of North America* 1984;**28**:669–97.
24. Iwaya SI, Ikawa M, Kubota M. Revascularization of an immature permanent tooth with apical periodontitis and sinus tract. *Dental Traumatology* 2001;**17**:185–7.
25. Banchs F, Trope M. Revascularization of immature permanent teeth with apical periodontitis: new treatment protocol? *Journal of Endodontics* 2004;**30**:196–200.
26. Thibodeau B, Trope M. Pulp revascularization of a necrotic infected immature permanent tooth: case report and review of the literature. *Pediatric Dentistry* 2007;**29**:47–50.
27. Rafter M. Vital pulp therapy—a review. *Journal of the Irish Dental Association* 2001;**47**:115–21.
28. Weisleder R, Benitez CR. Maturation: is it a new concept? *Journal of Endodontics* 2003;**29**:776–8.
29. Rule DC, Winter GB. Root growth and apical repair subsequent to pulpal necrosis in children. *British Dental Journal* 1966;**120**:586–90.
30. Matusow RJ. Acute pulpal-alveolar cellulitis syndrome V. Apical closure of immature teeth by infection control: case report and a possible microbial-immunologic etiology, Part 1. *Oral Surgery Oral Medicine & Oral Pathology* 1991;**71**:737–42.
31. Matusow RJ. Acute pulpal-alveolar cellulitis syndrome V. Apical closure of immature teeth by infection control: the importance of an endodontic seal with therapeutic factors, Part 2. *Oral Surgery Oral Medicine & Oral Pathology* 1991;**72**:96–100.
32. Saad AY. Calcium hydroxide and apexogenesis. *Oral Surgery Oral Medicine & Oral Pathology* 1988;**66**:499–501.
33. Whittle M. Apexification of an infected untreated immature tooth. *Journal of Endodontics* 2000;**26**:245–7.
34. Selden HS. Apexification: an interesting case. *Journal of Endodontics* 2002;**28**:44–5.
35. Sato I, Ando-Kurihara N, Kota K, Iwaku M, Hoshino E. Sterilization of infected root-canal dentine by topical application of a mixture of ciprofloxacin, metronidazole and minocycline in situ. *International Endodontic Journal* 1996;**29**:118–24.
36. Hoshino E, Kurihara-Ando N, Sato I, Uematsu H, Sato M, Kota K, et al. In-vitro antibacterial susceptibility of bacteria taken from infected root dentine to a mixture of

- ciprofloxacin, metronidazole and minocycline. *International Endodontic Journal* 1996;29:125–30.
37. Thibodeau B, Teixeira F, Yamauchi M, Caplan DJ, Trope M. Pulp revascularization of immature dog teeth with apical periodontitis. *Journal of Endodontics* 2007;33:680–9.
38. Cooke C, Rowbotham TC. The closure of open apices in non-vital immature incisor teeth. *British Dental Journal* 1988;165:420–1.
39. Windley 3rd W, Teixeira F, Levin L, Sigurdsson A, Trope M. Disinfection of immature teeth with a triple antibiotic paste. *Journal of Endodontics* 2005;31:439–43.
40. Kim ST, Abbott PV, McGinley P. The effects of Ledermix paste on discolouration of immature teeth. *International Endodontic Journal* 2000;33:233–7.
41. Kim ST, Abbott PV, McGinley P. The effects of Ledermix paste on discolouration of mature teeth. *International Endodontic Journal* 2000;33:227–32.
42. Ostby BN. The role of the blood clot in endodontic therapy. An experimental histologic study. *Acta Odontologica Scandinavica* 1961;19:324–53.
43. Myers WC, Fountain SB. Dental pulp regeneration aided by blood and blood substitutes after experimentally induced periapical infection. *Oral Surgery Oral Medicine & Oral Pathology* 1974;37:441–50.
44. Cox CF, Tarim B, Kopel H, Gurel G, Hafez A. Technique sensitivity: biological factors contributing to clinical success with various restorative materials. *Advances in Dental Research* 2001;15:85–90.
45. Farsi N, Alamoudi N, Balto K, Al Mushayt A. Clinical assessment of mineral trioxide aggregate (MTA) as direct pulp capping in young permanent teeth. *The Journal of Clinical Pediatric Dentistry* 2006;31:72–6.
46. Al-Hiyasat AS, Barrieshi-Nusair KM, Al-Omari MA. The radiographic outcomes of direct pulp-capping procedures performed by dental students: a retrospective study. *Journal of American Dental Association* 2006;137:1699–705.
47. Katebzadeh N, Dalton BC, Trope M. Strengthening immature teeth during and after apexification. *Journal of Endodontics* 1998;24:256–9.
48. Nevins A, Finkelstein F, Laporta R, Borden BG. Induction of hard tissue into pulpless open-apex teeth using collagen–calcium phosphate gel. *Journal of Endodontics* 1978;4:76–81.
49. Nevins A, Wrobel W, Valachovic R, Finkelstein F. Hard tissue induction into pulpless open-apex teeth using collagen–calcium phosphate gel. *Journal of Endodontics* 1977;3:431–3.