



CLINICAL ARTICLE

The use of cone beam computed tomography in the management of external cervical resorption lesions

S. Patel^{1,2} & A. Dawood²

¹Endodontic Postgraduate Unit, Guy's, King's & St Thomas' Dental Institute, King's College London; and ²45 Wimpole Street, London, UK

Abstract

Patel S, Dawood A. The use of cone beam computed tomography in the management of external cervical resorption lesions. *International Endodontic Journal*.

Aim To report the use of cone beam computed tomography in the assessment of external cervical resorption lesions.

Summary Asymptomatic external cervical resorption lesions were diagnosed radiographically in two patients. Clinical examination in both cases was unremarkable. Cone beam computed tomography scans revealed the true nature of the lesions in three dimensions. The resorption lesion in case 1 was confined predominantly to the buccal aspect of the root, the lesion had not perforated into the root canal. A mucoperiosteal flap was raised to gain access to the lesion, the resorptive lesion was excavated and the defect repaired with glass ionomer cement. In case 2 the cone beam computed tomography scan revealed that the resorptive lesion was more extensive than it appeared radiographically, making the prognosis of reparative treatment very poor. In this case, the patient was advised to have the tooth extracted.

Key learning points

- The true extent of external cervical resorption lesions cannot always be estimated from conventional radiographs.
- Cone beam computed tomography can be a useful diagnostic tool in the management of external cervical resorption lesions.

Keywords: cone beam computed tomography, external cervical resorption.

Received 7 October 2006; accepted 2 January 2007

Introduction

External cervical resorption is initiated by damage to the cementum immediately below the epithelial attachment allowing osteoclasts to colonize the damaged portion of the root. The pathogenesis of external cervical resorption is poorly understood. It has been reported that microorganisms either from the gingival sulcus (Tronstad 1988, Trope 2002), or the

Correspondence: Shanon Patel, 45 Wimpole Street, London W1G 8SB, UK (Tel.: +44 20 7935 0080; fax: +44 20 7935 1181; e-mail: shanonpatel@hotmail.com).

pulp space and dentinal tubules in nonvital teeth (Cvek & Lindvall 1985) may provide the stimulus for the lesion to continue. It has also been suggested that the presence of inflammatory cells is not due to microorganisms, and that external cervical resorption is an 'aseptic resorptive process, which may on occasions become secondarily invaded with microorganisms' (Heithersay 2004).

The cause of external cervical resorption is not fully known (Heithersay 2004), however, possible aetiological factors which may damage the cervical region of the root surface and therefore initiate external cervical resorption include; dental trauma (Heithersay 1999a), orthodontic treatment (Tronstad 2002), intracoronal bleaching (Harrington & Natkin 1979), periodontal treatment (Trope 2002) and idiopathic aetiology (Gunraj 1999, Liang *et al.* 2003). Heithersay (1999b) analysed the potential predisposing factors of 257 teeth in 222 patients with signs of external cervical resorption. A history of orthodontic treatment (24% of teeth), dental trauma (15% of teeth) and intracoronal bleaching (4% of teeth) were found to be the most common sole pre-disposing factors. Interestingly, there were no identifiable factors in 16% of the teeth assessed.

Diagnosis of these resorptive lesions may be challenging, especially when no clinical signs such as a 'pink spot' are seen. The only sign indicating the existence of an external cervical resorption lesion may be radiographic, revealing a radiolucency with poorly defined borders in the cervical-third of the root. The radiopaque outline of the root canal walls through the radiolucency may also suggest that the lesion is external cervical resorption. Angled radiographs using the parallax technique may be helpful to determine the location (palatal or labial) of the lesion, however, conventional radiographs do not provide an indication of the depth of such lesions (Kim *et al.* 2003), as will be seen with the two cases reported in this paper. Radiographs taken using the parallax technique may also be used to differentiate external from internal resorptive lesions. With internal resorption, the lesion will stay in the same position on two parallax radiographs. However, if the lesion is external cervical resorption, the radiographic position of the lesion alters when the angle of the X-ray beam is changed. Internal resorptive lesions commonly appear as a ballooning out or widening of the root canal. The radiographic appearance commonly reveals a radiolucent area which is generally spherical in shape and has smooth, well demarcated margins.

Cone beam computed tomography (CBCT) is a relatively new three dimensional imaging technique requiring a significantly lower radiation dose than conventional computed tomography. With traditional computed tomography, a narrow fan shaped X-ray beam makes a *series of rotations* around the patient's head as they are incrementally moved through the machine. The raw data from each rotation is then reconstructed to produce tomographic images. CBCT differs from conventional computed tomography imaging in that the whole volume of data is acquired in the course of a *single sweep* of the scanner. A cone shaped beam of X-rays passes through the area of interest and is detected by an opposing detector. The image is acquired by a detector which has an image intensifier and solid-state sensor or an amorphous silicon panel (Mah & Hatcher 2004). Sophisticated software compatible with personal computers is then used to reformat the huge volume of data allowing it to be processed into a format that closely resembles images produced by conventional computed tomography scanners.

The exposure time with CBCT scanners is typically less than 20 s and reconstruction of the image takes less than 2 min (<http://www.imagingsciences.com>). The efficient use of the radiation beam, and the elimination of the need for a conventional image intensification system used in conventional computed tomography scanners results in a huge reduction in radiation exposure. In a recent study the effective (radiation) dose of one particular CBCT scanner was only 8% of the effective dose of a conventional computed tomography scanner (Mah *et al.* 2003).

This clinical article demonstrates the use of CBCT as an effective diagnostic tool for the assessment and management of external cervical resorption in two clinical cases.

Case 1

A 32-year-old Caucasian male was referred by his general dental practitioner for the management of external cervical resorption. The general dental practitioner had noted a radiolucency on a dental panoramic tomograph which was taken as part of a new patient assessment. No other radiolucent lesions were detected in the patient's remaining teeth.

On presentation, the patient had no symptoms. He attended the dentist regularly and had a course of orthodontic treatment in his early teenage years. His medical history was unremarkable.

Clinical examination revealed a minimally restored dentition. Periodontal probing depths were no greater than 2 mm. The maxillary and mandibular right posterior teeth all responded positively to thermal and electrical sensitivity testing. The mandibular right second premolar tooth was unrestored (Fig. 1a).

A periapical radiograph of the mandibular right quadrant revealed a 4 mm diameter radiolucency in the cervical region of the root of the mandibular right second premolar. The lesion had well defined borders and the root canal was visible through the lesion suggesting that the lesion was external to the root canal (Fig. 1b).

With the patient's consent a 20 s, 120 Kv, 5 mA CBCT scan (i-CAT; Imaging Sciences International, Hatfield, PA, USA) was taken.

The cross sectional images through the area of interest confirmed the presence of a well defined uniformly radiolucent lesion lying on the cervical-third of the root of the mandibular right second premolar. Interestingly, the presence of a thin buccal cortical plate overlying the lesion was also noted. The lesion did not appear to be in communication with the root canal (Fig. 2a-c).

After discussing the various treatment options with the patient, it was decided to surgically repair the defect. The patient was given a preoperative chlorohexidine mouthwash. A triangular full mucoperiosteal flap was raised with a relieving incision mesial to the mandibular right canine. The cortical plate overlying the lesion was removed with a surgical bur under copious irrigation to reveal a resorption cavity. Granulomatous tissue was completely excavated from the cavity, and the defect was repaired with glass ionomer cement (Fuji LC glass ionomer cement; GC America Inc., Alsip, IL, USA). The margins of the restoration were polished with a fine diamond polishing bur. The flap was repositioned and held under gentle pressure for 10 min

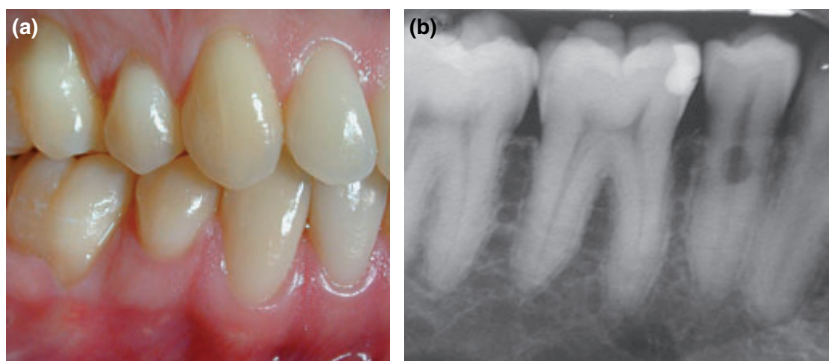


Figure 1 (a) Buccal view of the lower right quadrant; (b) radiograph of lower right quadrant revealing a cervical radiolucency on the lower right premolar.

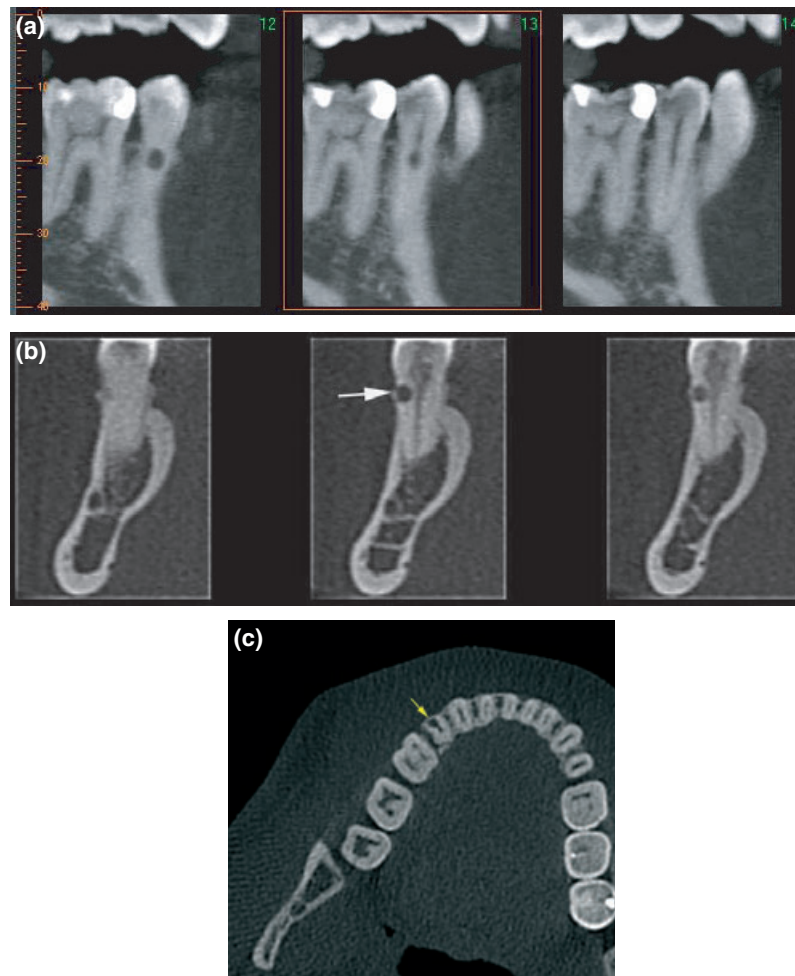


Figure 2 Cone beam computed tomography scans. (a) top left, sagittal slices; (b) top right, coronal slices – the resorptive lesion has not perforated into the root canal; (c) lower left, axial slice. Note the thin layer of cortical bone overlaying the resorptive lesion (yellow arrows).

with a damp gauze. Sutures were then used to close the surgical wound (5-0 Ethicon Proline; Johnson & Johnson, New Brunswick, NJ, USA) (Fig. 3a–d). The patient was given verbal and written postoperative instructions and discharged. The sutures were removed 4 days later, the patient reporting no significant post-treatment discomfort, and the surgical site appearing to be healing well. The patient was recalled 1 year later, and was asymptomatic. Clinical and radiographic examinations were unremarkable (Fig. 3e,f).

Case 2

A 37-year-old Caucasian female was referred by her orthodontist for advice regarding her tooth 11. The patient was about to undergo orthodontic treatment to align her maxillary anterior teeth, however routine pre-treatment radiographs revealed a radiolucency associated with tooth 11.

On presentation the patient had no symptoms, was medically fit and regularly attended the dentist. There was no history of dental trauma, however the patient did report a

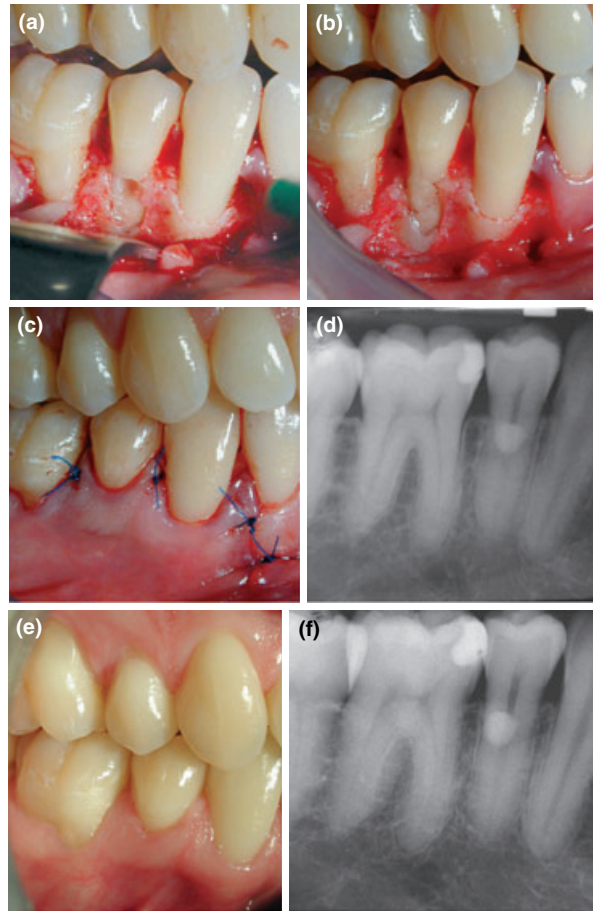


Figure 3 Operative management. (a) Resorptive lesion has been completely excavated; (b) resorption cavity has been restored with glass ionomer cement; (c) immediately post-treatment (d) radiograph of restored tooth; (e) clinical; (f) radiograph view at 1 year review.

course of orthodontic treatment when she was a teenager. Clinical examination was unremarkable, none of the maxillary anterior teeth were tender to percussion or palpation, and they all responded positively to thermal and electronic pulp testing. Periapical radiographs using a paralleling technique (Fig. 4a,b) revealed a cervical radiolucency indicative of external cervical resorption on the mesial aspect of tooth 11.

A CBCT scan (as described in case 1) revealed the resorptive lesion was significantly more extensive than originally diagnosed on the periapical radiographs (Fig. 5a,b). The lesion appeared to have two distinct areas. The outer portion of the lesion had the classical appearance of external cervical resorption, i.e. a radiolucent lesion with irregular borders. The inner portion of the lesion had a mottled appearance (which was not completely detectable on the periapical radiographs), suggesting that this portion of the lesion contained fibro-osseous like tissue. It was apparent from the sagittal and coronal slices that the lesion was not in communication with the root canal. The patient was advised that the lesion was not amenable to surgical repair. After a joint discussion with the orthodontist and a prosthodontist, it was decided that after orthodontic treatment was completed, tooth 11 would be assessed for progress of the resorptive lesion and replaced with an implant if required.

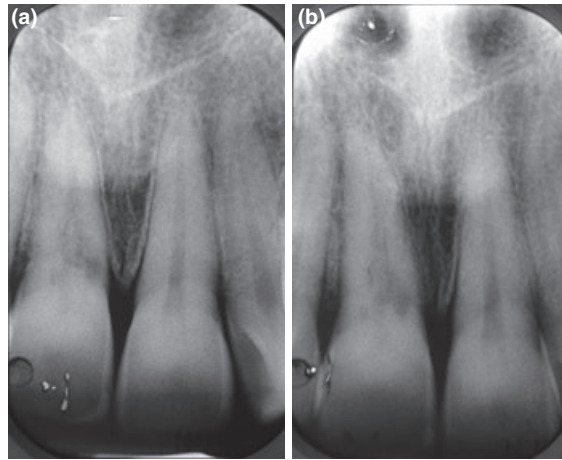


Figure 4 Two periapical radiographs taken at different horizontal angles confirm the resorptive lesion is palatally positioned using the parallax principle. The lesion appears to extend mesally, although this is difficult to confirm.

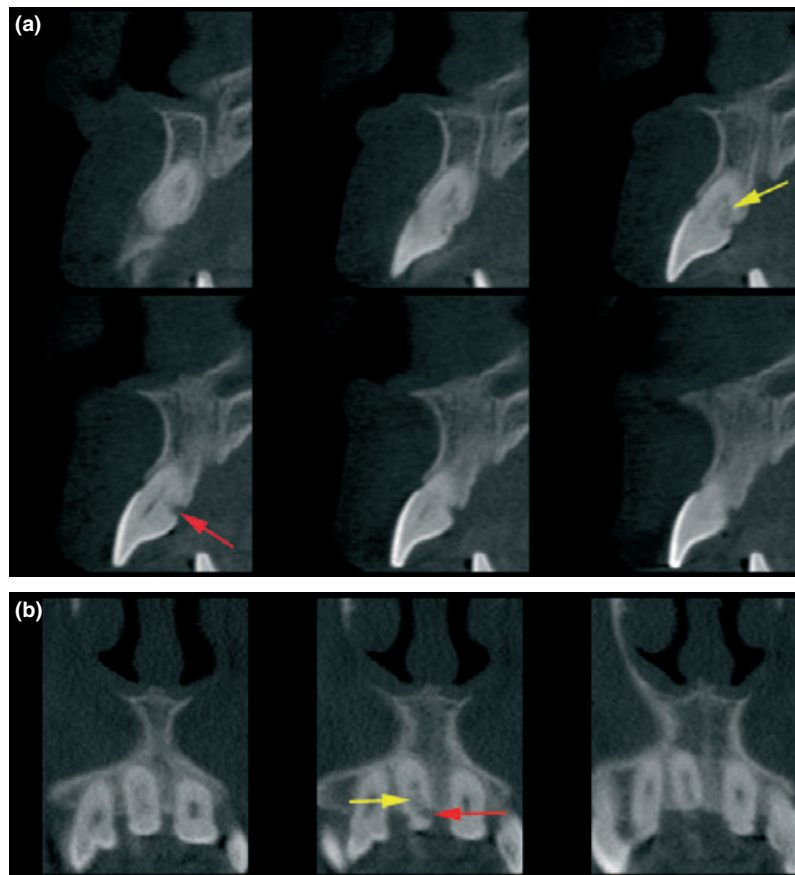


Figure 5 Cone beam computed tomograph scans. (a) Top, sagittal slices; (b) bottom, axial slices. The series of slices in both views clearly show two distinct areas within the resorptive lesion; outer inflammatory (red arrow), and an inner fibro-osseous (yellow arrow) resorption.

Discussion

Cone beam computed tomography was found to be particularly useful in the diagnosis of the external cervical resorption lesions reported here. In both cases, the position, depth in relation to the root canal and ultimately the restorability of the tooth was assessed objectively before any treatment was carried out. This allowed the operator to be confident of the best strategy for managing the defects and gave a better impression of prognosis. Although the exposure time of the CBCT scan was 20 s, its pulsed nature gives an actual equivalent exposure time of just 4.6 s. The effective dose of the i-CAT cone beam computed tomograph scanner used for these two cases is 69 μ Sv (Ludlow *et al.* 2006). This is in the same order of magnitude as conventional radiographs (Mah *et al.* 2003). Of particular relevance to endodontics is the 'limited' CBCT scanner (3D Accuitomo; J Morita Mfg. Corp, Kyoto, Japan) which is specifically designed to capture information from a small region of the maxilla or mandible. The image field is similar in size to a conventional periapical dental X-ray film. The effective dose of the 3D Accuitomo is equivalent to 2–3 standard periapical exposures (Arai *et al.* 2001).

Considerable information was gained from each volumetric scan, as the acquired data images could be easily generated in any plane (for example, coronal and axial planes) using the available software. Both patients found the CBCT images extremely helpful in understanding their endodontic problems.

Heithersay (1999c) described managing external cervical resorption defects using a flapless technique. He directly applied trichloroacetic acid to resorptive lesions, curetted out the resorption tissue and then restored the cavity with a plastic restoration. In case 1, a flapless technique could not be used as the CBCT scans clearly showed the presence of a thin layer of cortical bony plate overlying the resorption cavity. The prognosis of case 1 is excellent as the resorption defect was diagnosed at a relatively early stage and managed swiftly. Left untreated, the lesion may eventually have spread horizontally and vertically through the root and become untreatable. In case 2, it was interesting to note the true nature of the lesion was only visible in sagittal and axial sections of the reconstructed data from the CBCT. The scans clearly demonstrated that the resorption lesion had burrowed extensively towards the root canal in an apical and to a lesser extent in a coronal direction from the main (outer) lesion. This was not clearly detectable on the periapical radiographs. This previously undiagnosed inner portion of the resorptive lesion resulted in the lesion being untreatable.

Conclusion

Cone beam computed tomography is a useful addition to the endodontist's armamentarium for the management of complex endodontic problems. The lower radiation dosages compared with traditional CT scanners and geometric accuracy of scanned objects (Sonick *et al.* 1994, Mozzo *et al.* 1998) makes CBCT ideal for treatment planning periapical surgery, diagnosis of dento-alveolar trauma (Terakoda *et al.* 2000) and in certain circumstances the diagnosis of radiolucent apical lesions (Simon *et al.* 2006, Lofthag-Hansen *et al.* 2007).

Disclaimer

Whilst this article has been subjected to Editorial review, the opinions expressed, unless specifically indicated, are those of the author. The views expressed do not necessarily represent best practice, or the views of the IEJ Editorial Board, or of its affiliated Specialist Societies.

Acknowledgements

Cavendish Imaging for their help and advice in the preparation of this article.

References

- Arai Y, Honda K, Iwai K, Shinoda K (2001) Practical model '3DX' of limited cone-beam X-ray CT for dental use. *International Congress Series* **1230**, 713–8.
- Cvek M, Lindvall A-M (1985) External root resorption following bleaching of pulpless teeth with oxygen peroxide. *Endodontics and Dental Traumatology* **1**, 56–60.
- Gunraj MN (1999) Dental root resorption. *Oral Surgery, Oral Medicine, Oral Pathology, Oral Radiology, and Endodontics* **88**, 647–53.
- Harrington GW, Natkin E (1979) External resorption associated with the bleaching of pulpless teeth. *Journal of Endodontics* **5**, 344–8.
- Heithersay GS (1999a) Clinical, radiographic, and histopathologic features of invasive cervical resorption. *Quintessence* **30**, 27–37.
- Heithersay GS (1999b) Invasive cervical resorption: an analysis of potential predisposing factors. *Quintessence* **30**, 83–95.
- Heithersay GS (1999c) Treatment of Invasive cervical resorption: an analysis of the results using topical application of trichloroacetic acid, curettage, and restoration. *Quintessence* **30**, 96–110.
- Heithersay GS (2004) Invasive cervical resorption. *Endodontic Topics* **7**, 73–92.
- Kim E, Kim K-D, Roh B-D, Cho Y-S, Lee S-J (2003) Computed tomography as a diagnostic aid for extracanal invasive resorption. *Journal of Endodontics* **29**, 463–5.
- Liang H, Burkes EJ, Frederiksen NL (2003) Multiple idiopathic cervical root resorption: systematic review and report of four cases. *Dentomaxillofacial Radiology* **32**, 150–5.
- Lofthag-Hansen S, Huuonen S, Gröndahl K, Gröndahl H-G (2007) Limited cone-beam CT and intraoral radiography for the diagnosis of periapical pathology. *Oral Surgery, Oral Medicine, Oral Pathology, Oral Radiology, and Endodontology* **103**, 114–9.
- Ludlow JB, Davies-Ludlow LE, Brooks SL, Howerton WB (2006) Dosimetry of 3 CBCT devices for oral and maxillofacial radiology: CB Mercuray, NewTom 3G and i-CAT. *Dentomaxillofacial Radiology* **35**, 219–26.
- Mah J, Hatcher D (2004) Three-dimensional craniofacial imaging. *American Journal of Orthodontics and Dentofacial Orthopedics* **126**, 308–9.
- Mah J, Danforth RA, Bumann A, Hatcher D (2003) Radiation absorbed in maxillofacial imaging with a new dental computed tomography device. *Oral Surgery, Oral Medicine, Oral Pathology, Oral Radiology, and Endodontics* **96**, 508–13.
- Mozzo P, Procacci C, Tacconi A, Tinazzi Martini P, Bergamo Andreis IA (1998) A new volumetric CT machine for dental imaging based on the cone-beam technique: preliminary results. *European Radiology* **8**, 1558–64.
- Simon JHS, Enciso R, Malfaz J-M, Roges R, Bailey-Perry M, Patel A (2006) Differential diagnosis of large periapical lesions using cone-beam computed tomography measurements and biopsy. *Journal of Endodontics* **32**, 833–7.
- Sonick M, Abrahams J, Faiella RA (1994) A comparison of the accuracy of periapical, and computerized tomographic radiographs in locating the mandibular canal. *The International Journal of Oral and Maxillofacial Implants* **9**, 455–60.
- Terakoda M, Hashimoto K, Arai Y, Honda M, Sekiwa T, Sato H (2000) Diagnostic imaging with newly developed ortho cubic super-high resolution computed tomography (Ortho-CT). *Oral Surgery, Oral Medicine, Oral Pathology, Oral Radiology, and Endodontology* **89**, 509–18.
- Tronstad L (1988) Root resorption-etiology, terminology and clinical manifestations. *Endodontics and Dental Traumatology* **4**, 241–52.
- Tronstad L (2002) *Endodontic Aspects of Root Resorption*. *Clinical Endodontics*, 2nd edn. Stuttgart, Germany: Thieme.
- Trope M (2002) Root resorption due to dental trauma. *Endodontic Topics* **1**, 79–100.