

## CASE REPORT

# The use of white Portland cement as an apical plug in a tooth with a necrotic pulp and wide-open apex: a case report

**G. De-Deus & T. Coutinho-Filho**

Department of Endodontics, Rio de Janeiro State University, Rio de Janeiro, Brazil

---

### Abstract

**De-Deus G, Coutinho-Filho T.** The use of white Portland cement as an apical plug in a tooth with a necrotic pulp and wide-open apex: a case report. *International Endodontic Journal*, **40**, 653–660, 2007.

**Aim** To present a case in which substantial periapical healing occurred with the use of white Portland cement (WPC) to create an apical plug in the root of an immature tooth.

**Summary** Radiographic examination indicated an immature tooth (35) with a wide-open apex and a periapical radiolucency. The canal was mechanically cleaned using intracanal instruments and 5% NaOCl irrigation. Small pieces of resorbable collagen sponge were packed beyond the root apex with the aim of creating a periapical barrier for the compaction of filling material. WPC powder was then mixed with sterile water and delivered to the apical portion of the canal (approximately 3 mm). The patient was asked to return 1 week later for the continuation of treatment but he did not return as planned. Seven months after the intervention the patient returned and another radiograph was exposed to reveal complete radiographic healing of the periapical region. The remainder of the canal was filled with thermoplastic gutta-percha. Clinical follow-up 1 year later revealed adequate clinical function, absence of clinical symptoms and no signs of periapical rarefaction.

### Key learning point

- The positive clinical resolution of this case is encouraging for the use of WPC as an apical plug in immature teeth with necrotic pulps and wide-open apices.

**Keywords:** endodontic treatment, open apices, Portland cement.

Received 25 June 2005; accepted 15 February 2007

---

### Introduction

Traumatic injuries to permanent teeth occur in 30% of children (Andreasen *et al.* 2006). The majority of these incidents occur before root formation is complete and might result in

---

Correspondence: Prof. Gustavo André De-Deus Carneiro Vianna, R. Desembargador Renato Tavares, 11, ap.102, Ipanema, Rio de Janeiro, RJ 22411-060, Brazil (e-mail: endogus@gmail.com).

pulp inflammation or necrosis (Andreasen & Andreasen 1994). The main challenge in performing root-canal treatment in teeth with necrotic pulps and wide-open apices is to obtain an optimal apical seal. The wide foramen requires a large volume of filling material that may extrude from the root canal into the periapical tissues creating foreign-body responses and compromising the apical seal (Rafter 2005).

Several procedures utilizing different materials have been recommended to induce root-end barrier formation. Apexification with calcium hydroxide is the most commonly advocated therapy for immature teeth with nonvital pulp and the healing rate is high (Steiner *et al.* 1968, Van Hassel & Natkin 1970).

However, notwithstanding the clinical success of calcium hydroxide apexification techniques, a number of disadvantages are apparent. For example, the treatment requires compliance from the patient and many appointments over a period of time ranging from 3 to 24 months (Frank 1966). During this period, the root canal is susceptible to reinfection around the provisional restoration, which may promote apical periodontitis and arrest of repair. Other disadvantages in this lengthy treatment include financial concerns and aesthetic demands. In addition, Andreasen *et al.* (2002) reported that the fracture strength of immature teeth may be reduced by long-term calcium hydroxide treatment.

One alternative for calcium hydroxide apexification is a single-step technique using an artificial apical barrier. The one-visit apexification has been described as the nonsurgical compaction of a biocompatible material into the apical end of the root canal, thus, creating an apical stop and enabling immediate filling of the root canal (Steinig *et al.* 2003).

Mineral trioxide aggregate (MTA) has been suggested for one-visit apexification (Shabahang & Torabinejad 2000) and numerous authors have recommended this. It has been described as a good alternative to the  $\text{Ca(OH)}_2$  apexification procedure (Witherspoon & Ham 2001, Giuliani *et al.* 2002, Linsuwanont 2003, Maroto *et al.* 2003, Steinig *et al.* 2003, Hayashi *et al.* 2004). Adoption of this rapid MTA treatment would be of great benefit to patients (Hayashi *et al.* 2004). The *in vitro* sealing ability of MTA in teeth with open apices was demonstrated in a laboratory study by Hachmeister *et al.* (2002).

Mineral trioxide aggregate is widely used in procedures ranging from pulp capping to furcal perforation repair (Torabinejad *et al.* 1993, Torabinejad & Chivian 1999). These applications are possible due to the favourable properties of MTA including biocompatibility (De-Deus *et al.* 2005), good canal sealing ability (Torabinejad *et al.* 1993) and the ability to promote dental pulp and periradicular tissue regeneration (Torabinejad & Chivian 1999, Menezes *et al.* 2004). Felipe *et al.* (2006) reported that MTA, when applied as an apical plug, favoured apexification and periapical healing, regardless of the prior use of calcium hydroxide paste. The authors drew attention to other advantages, including predictable apical closure and reduced treatment time, number of appointments and radiographs, particularly in young patients.

In several investigations, the chemical, physical and biological properties of Portland cement (PC) have been analysed (Estrela *et al.* 2000, Menezes *et al.* 2004, De-Deus *et al.* 2006, Islam *et al.* 2006). Wucherpfenning & Green (1999) reported that MTA and PC were almost identical macroscopically, microscopically and when evaluated by X-ray diffraction analysis.

The first investigation of PC for dental use demonstrated that it had similar properties to grey MTA (Estrela *et al.* 2000, Camilleri & Pitt Ford 2006). The authors also verified that PC contained the same principal chemical elements as MTA, except for the radiopacifier bismuth oxide (Estrela *et al.* 2000). Ribeiro *et al.* (2006) demonstrated that MTA and PC had no cytotoxic effects on Chinese hamster ovary cells and reported that these results might be an additional argument to support the use of PC in dental practice. Histological evaluation of pulpotomies in dogs using MTA and PC reported that both were effective as pulp protection materials (Menezes *et al.* 2004). De-Deus *et al.* (2006), in a recent paper, showed that the

bacterial leakage of Pro-Root MTA and PC in furcation repairs were similar up to 50 days. In addition, Islam *et al.* (2006) reported that ProRoot MTA and PC had very similar physical properties. Due to these favourable results and its low cost, the authors suggested that it was reasonable to consider PC as a possible substitute for MTA in endodontics.

A major concern regarding the use of water-based cements is the amount of arsenic present in the material (Islam *et al.* 2006). Arsenic is an impurity of limestone that is used in the manufacture of PC. Nevertheless, the levels of arsenic released were similar for PC and MTA, and were below those considered to be dangerous (Duarte *et al.* 2005), demonstrating no contraindication for using these materials in clinical practice.

This report demonstrates the use of white Portland cement (WPC) combined with a resorbable sponge matrix to create an apical plug in a root canal with a wide-open apex.

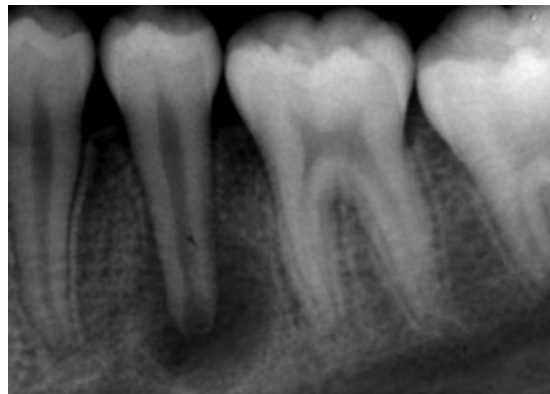
### Case report

A 17-year-old male presented to the Postgraduate Dental Course at the Rio de Janeiro State University with swelling of the mandible in the left premolar region. The patient reported no previous toothache. Clinical examination revealed a diffuse swelling between the apices of teeth 34 and 35. Radiographic examination (Fig. 1) indicated an immature tooth (35) with a wide-open apex and a radiolucent area.

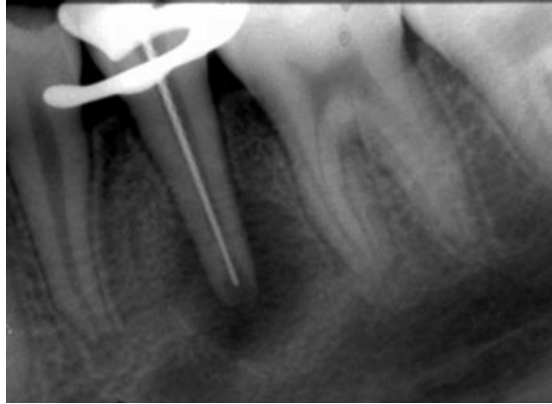After the application of a rubber dam and access cavity preparation, the working length was obtained (Fig. 2). The canal was cleaned with intracanal instruments and 5.25% sodium hypochlorite irrigation, and was then dried with sterile absorbent paper points.

With the intention to create a periapical barrier for the WPC, small pieces of resorbable collagen sponge (Kollagen-Resorb; Resorba, Nuremberg, Germany) were condensed beyond the canal apex until the periapical space was full. This procedure was adapted from the method described previously by Bargholz (2005).

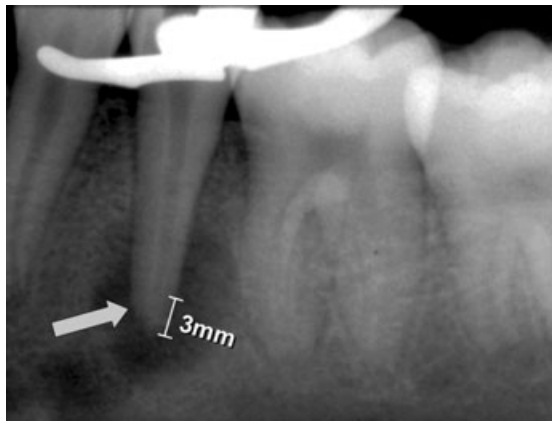
Following the application of collagen, WPC powder (Irajazinho® TYPO II, Votorantim Cimentos, Rio Branco, SP, Brazil) was mixed with sterile water, to a soft paste consistency. The WPC was delivered to the apical portion of the canal (approximately 3 mm) using an amalgam carrier and pluggers under an operating microscope (Dental F. Vasconcelos, M900 – X25, SP, Brazil), creating an apical plug of 3 mm thickness. A radiograph was exposed to determine that WPC was placed correctly (Fig. 3). A cotton pellet moistened with sterile water was placed in the pulp chamber and the access cavity was filled with IRM temporary filling material (Caulk Dentsply, Milford, DE, USA).



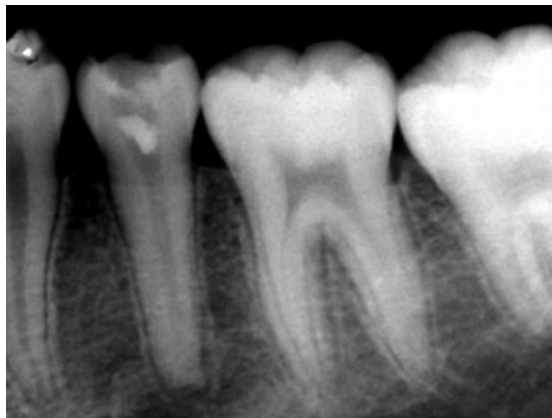**Figure 1** Preoperative radiograph of the mandibular left premolar (35). Note the wide-open apex and periapical radiolucent lesion.



**Figure 2** Working length radiograph.



**Figure 3** Preoperative radiograph with WCP placed at the apical portion of the canal (approximately 3 mm).



**Figure 4** Radiograph to verify the periapical situation and the WCP barrier condition 7 months after the initial intervention. Note the complete healing of the periapical region.

The patient was instructed to return 1 week later for the continuation of treatment but he did not return as planned. Seven months after the initial intervention the patient returned to the University to complete the treatment. A further periapical radiograph was

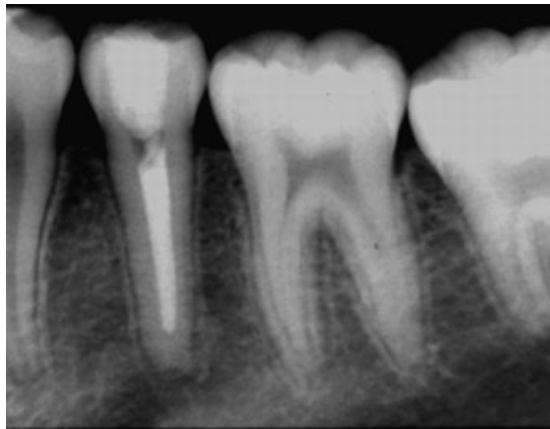
exposed to evaluate the periapical condition and revealed complete healing of the periapical region (Fig. 4).

The IRM and the cotton pellet were removed and the integrity of the WPC was verified with a size 20 file. The root canal was irrigated with 5.25% NaOCl for 15 min before backfilling with thermoplastic gutta-percha (Obtura II system, Obtura Corp., Fenton, MO, USA) combined with a root-canal sealer (Pulp Canal Sealer EWT, Kerr, Sybron Dental Specialties, Romulus, MI, USA). Composite resin was used for coronal restoration (Fig. 5).

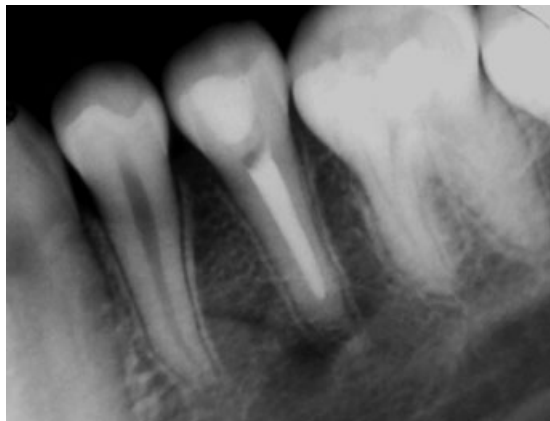
The 1-year follow-up revealed adequate function, absence of clinical symptoms and no periapical rarefaction (Fig. 6).

### Discussion

White Portland cement has been proposed as a potential material to create an apical plug in teeth with immature apices.



**Figure 5** Immediate postoperative radiograph with root-canal filling and the white Portland cement in the apical third.



**Figure 6** One-year postoperative radiograph confirming healing of the periapical region.

Previous reports have demonstrated the biocompatibility of PC (Holland *et al.* 2001a,b, Abdullah *et al.* 2002) and Abdullah *et al.* (2002) have shown fast setting PC to support the proliferation of SaOS-2 cells *in vitro*. Active stimulation of these cells through the production of cytokines and a bone-specific protein was noted. The results observed with MTA and PC were supported by Holland *et al.* (2001b). They reported that the mechanism of action of MTA and PC are similar. Saidon *et al.* (2003) also verified that MTA and PC had similar properties.

De-Deus *et al.* (2005) showed that two brands of MTA and PC created an elevated cytotoxic effect initially that decreased gradually allowing the cell culture to repair. Cell reaction patterns were similar for Pro-Root MTA<sup>®</sup>, MTA Angelus<sup>®</sup> and PC at all experimental periods. The authors concluded that the positive results achieved with PC were encouraging for its use as an endodontic restorative material with lower cost. Funteas *et al.* (2003) analysed samples of MTA and PC for 15 different elements using inductively coupled plasma emission spectrometry. Comparative analysis revealed that there was significant similarity, except for the nondetectable quantity of bismuth in PC.

From a practical point of view, MTA and PC can both be used in moist environments. This is an interesting property during the treatment of teeth with necrotic pulps and periapical lesions because one of the problems found in these cases is the presence of tissue fluid exudate.

A practical difference between MTA and PC is the lack of radiopacity of the latter. Figure 4 reveals that the radiopacity of white PC was similar to that of dentine. In the present case, the lack of radiopacity complicated but did not hinder the correct insertion of the material.

Despite an incomplete root-canal filling and a temporary coronal restoration, healing of the periapical tissues was observed 7 months after the WPC application. Similar findings have been reported by others (Shabahang & Torabinejad 2000, Witherspoon & Ham 2001, Giuliani *et al.* 2002, Linsuwanont 2003, Maroto *et al.* 2003, Steinig *et al.* 2003, Hayashi *et al.* 2004, De-Deus *et al.* 2005, 2006). In the present case, WPC acted as an efficient apical barrier in the wide-open apex of an infected root-canal system.

The concept of an internal matrix does not represent an innovation in endodontics. Lemon (1992) developed the internal matrix concept in which an intermediate layer of material is placed to form a barrier prior to placement of the repair material. Hydroxyapatite (Lemon 1992), decalcified freeze-dried bone (Hartwell & England 1993), calcium hydroxide (Petersson *et al.* 1985) and sterile bovine collagen have also been advocated as a matrix for perforation repairs. In the current case, a resorbable collagen sponge was chosen as the matrix. This matrix concept was described previously by Bargholz (2005) who reported that it could conform to the root-canal shape. In the present case, the resorbable collagen sponge was shown to be very effective.

### Conclusion

The positive clinical outcome in this case is encouraging for the use of WPC in immature teeth with necrotic pulps and wide-open apices. More laboratory and clinical studies are necessary before unlimited clinical use of this alternative material is necessary.

### Disclaimer

Whilst this article has been subjected to Editorial review, the opinions expressed, unless specifically indicated, are those of the author. The views expressed do not necessarily represent best practice, or the views of the IEJ Editorial Board, or of its affiliated Specialist Societies.

## References

- Abdullah D, Pitt Ford TR, Papaioannou S, Nicholson J, McDonald F (2002) An evaluation of accelerated Portland cement as a restorative material. *Biomaterials* **23**, 4001–10.
- Andreasen JO, Andreasen FM (1994) *Textbook and Color Atlas of Traumatic Injuries to the Teeth*, 3rd edn. Copenhagen: Munksgaard.
- Andreasen JO, Farik B, Munksgaard EC (2002) Long-term calcium hydroxide as a root canal dressing may increase risk of root fracture. *Dental Traumatology* **18**, 134–7.
- Andreasen JO, Bakland LK, Matras RC, Andreasen FM (2006) Traumatic intrusion of permanent teeth. Part 1. An epidemiological study of 216 intruded permanent teeth. *Dental Traumatology* **22**, 83–9.
- Bargholz C (2005) Perforation repair with mineral trioxide aggregate: a modified matrix concept. *International Endodontic Journal* **38**, 59–69.
- Camilleri J, Pitt Ford TR (2006) Mineral trioxide aggregate: a review of the constituents and biological properties of the material. *International Endodontic Journal* **39**, 747–54.
- De-Deus G, Ximenes R, Gurgel-Filho ED, Plotkowski MC, Coutinho-Filho T (2005) Cytotoxicity of mineral trioxide aggregate and Portland cement on human ECV 304 endothelial cells. *International Endodontic Journal* **38**, 604–9.
- De-Deus G, Petruccelli V, Gurgel-Filho E, Coutinho-Filho T (2006) MTA versus Portland cement as repair material for furcal perforations: a laboratory study using a polymicrobial leakage model. *International Endodontic Journal* **39**, 293–8.
- Duarte MA, De Oliveira Demarchi AC, Yamashita JC, Kuga MC, De Campos Fraga S (2005) Arsenic release provided by MTA and Portland cement. *Oral Surgery Oral Medicine Oral Pathology Oral Radiology and Endodontics* **99**, 648–50.
- Estrela C, Bammann LL, Estrela CR, Silva RS, Pécora JD (2000) Antimicrobial and chemical study of MTA, Portland cement, calcium hydroxide paste, sealapex and dycal. *Brazilian Dental Journal* **11**, 3–9.
- Felippe WT, Felipe MCS, Rocha MJC (2006) The effect of mineral trioxide aggregate on the apexification and periapical healing of teeth with incomplete root formation. *International Endodontic Journal* **39**, 2–9.
- Frank AL (1966) Therapy for the divergent pulpless tooth by continued apical formation. *Journal of American Dental Association* **72**, 87–93.
- Funteas UR, Wallace JA, Fochtman EW (2003) A comparative analysis of mineral trioxide aggregate and Portland cement. *Australian Endodontic Journal* **29**, 43–4.
- Giuliani V, Baccetti T, Pace R, Pagavino G (2002) The use of MTA in teeth with necrotic pulps and open apices. *Dental Traumatology* **18**, 217–21.
- Hachmeister DR, Schindler WG, Walker WA, Thomas DD (2002) The sealing ability and retention characteristics of mineral trioxide aggregate in a model of apexification. *Journal of Endodontics* **28**, 386–90.
- Hartwell GR, England MC (1993) Healing of furcation perforations in primate teeth after repair with decalcified freeze-dried bone: a longitudinal study. *Journal of Endodontics* **19**, 357–61.
- Hayashi M, Shimizu A, Ebisu S (2004) MTA for obturation of mandibular central incisors with open apices: case report. *Journal of Endodontics* **30**, 120–2.
- Holland R, de Souza V, Nery MJ et al. (2001a) Reaction of rat connective tissue to implanted dentin tube filled with mineral trioxide aggregate, Portland cement or calcium hydroxide. *Brazilian Dental Journal* **12**, 3–8.
- Holland R, de Souza V, Murata SS et al. (2001b) Healing process of dog dental pulp after pulpotomy and pulp covering with mineral trioxide aggregate or Portland cement. *Brazilian Dental Journal* **12**, 109–13.
- Islam I, Chng HK, Yap AU (2006) X-ray diffraction analysis of mineral trioxide aggregate and Portland cement. *International Endodontic Journal* **39**, 220–5.
- Lemon RR (1992) Nonsurgical repair of perforation defects. Internal matrix concept. *The Dental Clinics of North America* **36**, 439–57.
- Linsuwanont P (2003) MTA apexification combined with conventional root canal retreatment. *Australian Endodontic Journal* **29**, 45–9.

- Maroto M, Barberia E, Planells P, Vera V (2003) Treatment of a non-vital immature incisor with mineral trioxide aggregate (MTA). *Dental Traumatology* **19**, 165–9.
- Menezes R, Bramante CM, Letra A, Carvalho VG, Garcia RB (2004) Histologic evaluation of pulpotomies in dog using two types of mineral trioxide aggregate and regular and white Portland cements as wound dressings. *Oral Surgery Oral Medicine Oral Pathology Oral Radiology and Endodontics* **98**, 376–9.
- Petersson K, Hasselgren G, Tronstad L (1985) Endodontic treatment of experimental root perforations in dog teeth. *Endodontics & Dental Traumatology* **1**, 22–8.
- Rafter M (2005) Apexification: a review. *Dental Traumatology* **21**, 1–8.
- Ribeiro D, Marques M, Salvadori D (2006) Genotoxicity and cytotoxicity of glass ionomer cements on Chinese hamster ovary (CHO) cells. *Journal of Materials Science: Materials in Medicine* **17**, 405–500.
- Saidon J, He J, Zhu Q, Safavi K, Spångberg LS (2003) Cell and tissue reactions to mineral trioxide aggregate and Portland cement. *Oral Surgery Oral Medicine Oral Pathology Radiology and Endodontics* **95**, 483–9.
- Shabahang S, Torabinejad M (2000) Treatment of teeth with open apices using mineral trioxide aggregate. *Practical Periodontics & Aesthetic Dentistry* **12**, 315–20.
- Steiner JC, Dow PR, Cathey GM (1968) Inducing root end closure of non-vital permanent teeth. *Journal of Dentistry for Children* **35**, 47–54.
- Steinig TH, Regan JD, Gutmann JL (2003) The use and predictable placement of mineral trioxide aggregate in one-visit apexification cases. *Australian Endodontic Journal* **29**, 34–42.
- Torabinejad M, Chivian N (1999) Clinical applications of mineral trioxide aggregate. *Journal of Endodontics* **25**, 197–205.
- Torabinejad M, Watson TF, Pitt Ford TR (1993) Sealing ability of a mineral trioxide aggregate when used as a root end filling material. *Journal of Endodontics* **19**, 591–5.
- Van Hassel HJ, Natkin E (1970) Induction of root end closure. *Journal of Dentistry for Children* **37**, 57–9.
- Witherspoon DE, Ham K (2001) One-visit apexification: technique for inducing root-end barrier formation in apical closures. *Practical Procedures & Aesthetic Dentistry* **13**, 455–60.
- Wucherpfenning AL, Green DB (1999) Mineral trioxide vs. Portland cement: two biocompatible filling materials. *Journal of Endodontics* **25**, 308 (abstract).