

Root Resorption due to Dental Trauma

MARTIN TROPE

General principles

Protective mechanisms against resorption

Unlike deciduous teeth, permanent teeth rarely undergo root resorption (1). Even in the presence of peri-radicular inflammation, resorption will occur primarily on the bone side of the attachment apparatus and the root will be resistant to it (Fig. 1) (2). Although many theories have been put forward, the reason for the resistance of the root to resorption is not fully understood. One theory maintains that the remnants of the epithelial root sheath surround the root like a net, therefore imparting a resistance to resorp-

tion and subsequent ankylosis (3, 4). However, this theory has failed to gain support, and a second hypothesis that has been put forward is more likely (5).

This theory is based on the premise that the cementum and predentin covering on dentin are essential elements in the resistance of the dental root to resorption. It has long been noted that osteoclasts will not adhere to or resorb unmineralized matrix. Major mediators of osteoclast binding are RGD-peptides that are bound to calcium salt crystals on mineralized surfaces. Since the most external aspect of cementum is covered by a layer of cementoblasts over a zone of non-mineralized cementoid, a surface that provides satisfactory conditions for osteoclast binding

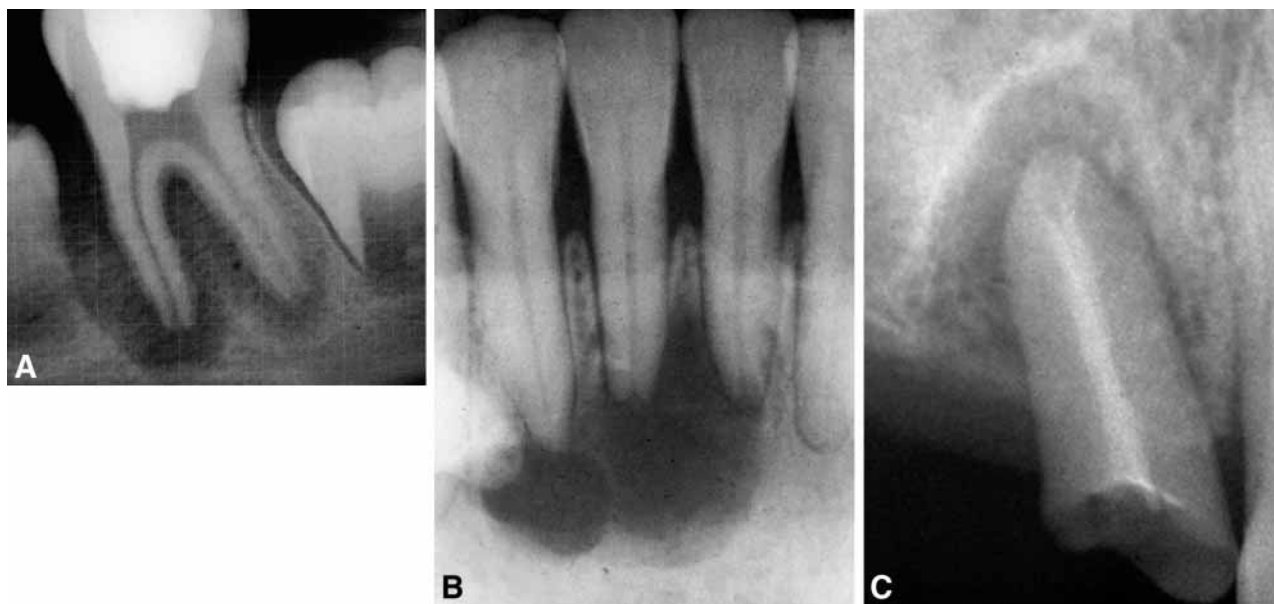


Fig 1. A, B, C. Teeth with extensive peri-radicular periodontitis due to pulpal infection. Note the resorption of bone; however, the roots remain intact.

is not present. Internally, the dentin is covered by pre-dentin matrix, which possesses a similar organic surface. Unlike the first theory, there are numerous studies which lend support to this idea (1, 5, 6, 7, 8, 9).

Another function of the cemental layer is related to its ability to inhibit the movement of toxins if present in the root canal space into the surrounding periodontal tissues (10). The consequence of an infected root canal space is, therefore, most likely to be apical periodontitis, as the toxins can only communicate with the periodontal tissues through the apical foramina or large accessory canals. However, if the cemental layer is lost or damaged, the inflammatory stimulators can pass from an infected pulp space through the dentinal tubules into the surrounding periodontal ligament, which, in turn, sets up an inflammatory response. Since the cementum is lost, this inflammatory response will result in both bone resorption and root resorption.

Requirements for the presence of root resorption

Due to the previously described inhibitory effects of organic pre-cementum and predentin, even in the presence of inflammation, an intact root is resistant to resorption. However, if an injury removes or alters the (protective) pre-dentin or pre-cementum, inflammation of the pulp or periodontium will induce root resorption with multinucleated clastic cells similar to those seen in bone resorption (11). (For a review of osteoclast function see Levin L and Trope M (12))

Thus, in order for root resorption to occur, two things must happen:

1. The loss or alteration of the protective layer (pre-cementum or pre-dentin)
2. Inflammation must occur to the unprotected root surface.

1. Loss or alteration of the protective layer

Damage to the protective layer can occur either directly, due to the trauma of a dental injury, or indirectly, when an inflammatory response occurs as a result of a dental injury. Most traumatic injuries, however, cause surprisingly little damage to the cemental layer. Even in an avulsion injury, the greatest damage that occurs is the tearing of the periodontal ligament

(Fig. 2), with only slight damage caused to the cemental layer. Physical damage to the cemental layer will only occur at the specific points where the force of the trauma pushed the tooth directly against the bony socket (13, 14). The only exception to this rule is an intrusive injury, where the forcing of the conical root apically into a similarly shaped socket will cause tremendous damage to the protective layer over the entire root surface.

Inflammation in reaction to the traumatic injury varies according to the stimulus it is exposed to after the injury, and has the potential to cause extensive damage to the protective layer. For example, the initial damage to the protective cementum after an avulsion injury, as described above, is limited (13, 14). However, if the periodontal ligament cells remaining on the root are allowed to dry out before re-plantation, they will provide the stimulus for an in-

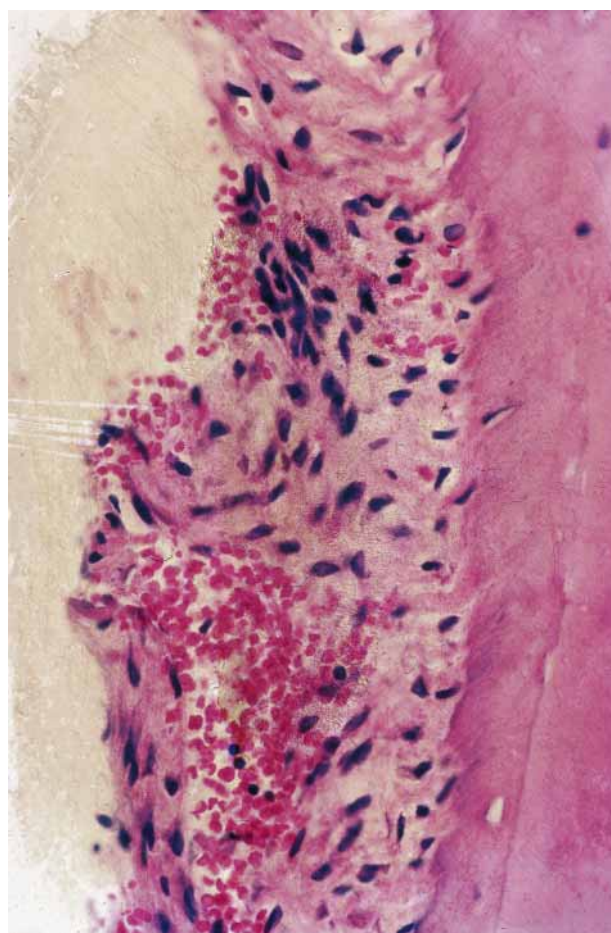


Fig. 2. Histologic appearances the attachment apparatus of a recently avulsed tooth. The periodontal ligament is torn but the root surface is intact.

flammatory response over the entire root surface, which, in turn, results in extensive damage to the protective layer (13, 14).

Little is known about the causes of pre-dentin protective damage. In most cases, the pulp will necrose very quickly, which removes the blood supply to the resorbing cells and, this, in turn, protects the root against extensive resorption (15). Therefore, as evidenced by the extremely low incidence of internal root resorption in permanent teeth, the conditions required to create an inflamed pulp adjacent to a damaged root surface are extremely rare (15).

2. The inflammatory response

A. The destructive phase. The inflammatory response caused by the dental injury can be divided into two critical phases. The first is the destructive phase where active resorption between the dried-out cells with multinucleated giant cells takes place (Fig. 3). This destruction will continue as long as there is stimulus present to allow the inflammation to develop. In most cases, the conditions necessary to the creation of the

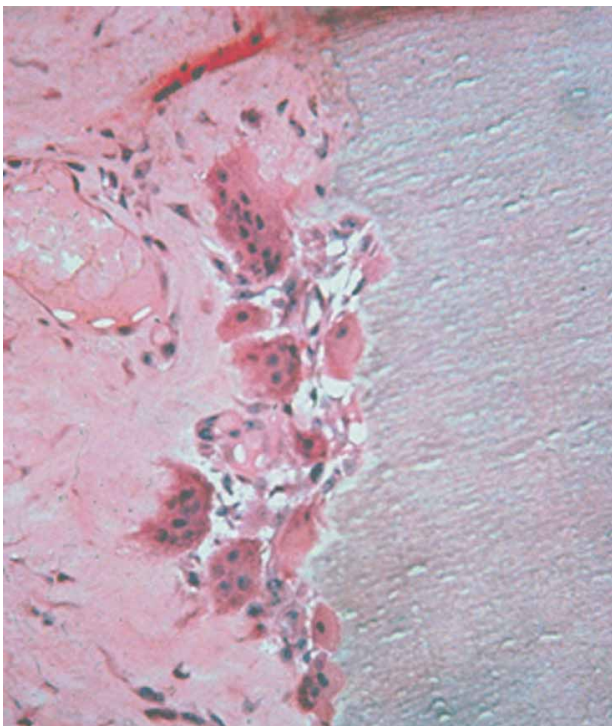


Fig. 3. Histologic appearance of multinucleated giant cells resorbing the root.

stimulus are due to either mechanical damage to the root surface, or foreign materials or bacteria picked up the accident site on the root surface; therefore, the stimulus can only exist for a short period of time. Healing will, therefore, take place without intervention by the dentist.

However, if the inflammatory stimulus is long-standing, the destructive root resorption will continue until either no root structure remains or the stimulus is removed by the intervention of the dentist. The destructive phase of root resorption is diagnosed primarily by the radiolucent appearance of the root and adjacent bone on X-rays (Fig. 4). Diagnosis is a major challenge as resorptive defects, facial or lingual/palatal, are most often missed during examination, although newer radiographic techniques, such as Tuned Aperture Computed Tomography (TACT) (16), display significant promise in improving our ability to identify these defects in the future. The diagnosis is also occasionally assisted by the presence of clinical symptoms which are similar to apical periodontitis. Once active root resorption has been diagnosed, the challenge to the practitioner is to determine whether it will spontaneously heal, i.e. the stimulus is of short duration, or whether intervention is necessary due to the presence of a long-standing stimulus.

Since most of the root destruction occurs due to the inflammatory response rather than direct physical damage, it seems logical that, if we could in some way limit this inflammation, we would also limit the root

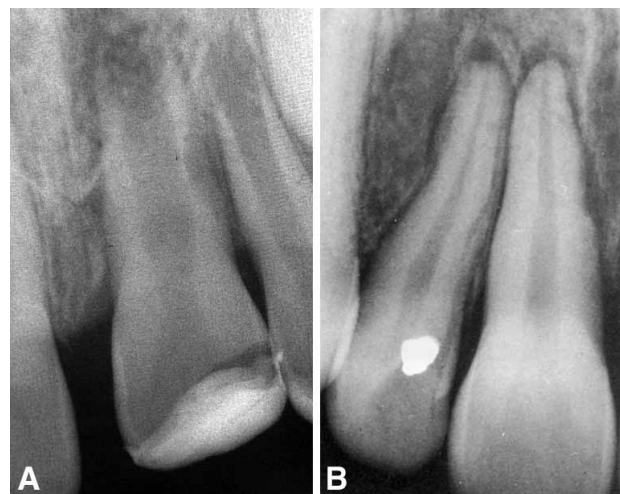


Fig. 4. A, B. Radiographic appearance of root resorption in the destructive phase. Note the radiolucencies in the root and bone. (B. Courtesy Drs. J. O. and F. Andreasen)

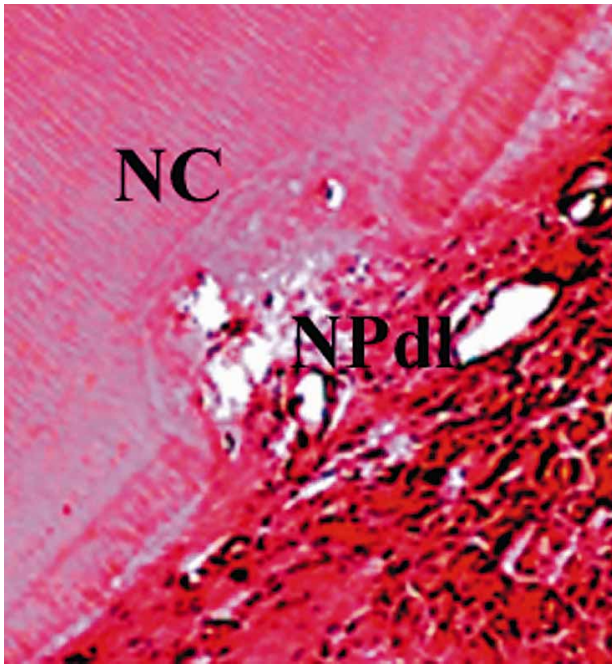


Fig. 5. Favorable healing with cementum (cemental healing, surface resorption). A previous resorptive defect is filled with new cementum (NC) and new periodontal ligament (NPdl).

destruction and expect a more favorable outcome in terms of healing (see below).

B. Healing phase The critical factor in determining the outcome after a dental traumatic injury has occurred is the type of cells that repopulate the root surface during the healing phase. If cementoblasts are able to cover the damaged root surface, a type of healing termed cemental healing or surface resorption (17, 18) (Fig. 5) will occur and the outcome will be favorable.

If, on the other hand, bone producing cells are able to cover the root surface, the conditions for healing will be unfavorable, as direct contact with bone and root will occur over some areas of the root surface; a phenomenon termed as ankylosis (19). Bone resorbs and forms physiologically throughout life. Thus, the root is resorbed by the osteoclasts but, in the reforming stage, bone is laid down instead of dentin. The root is, therefore, slowly replaced with bone. This process is termed as replacement resorption or osseous replacement (17, 18) (Fig. 6).

The type of tissue that will cover the root surface is dependent on the surface area of the root damage and the relative proximity of the cells to the root; i.e.

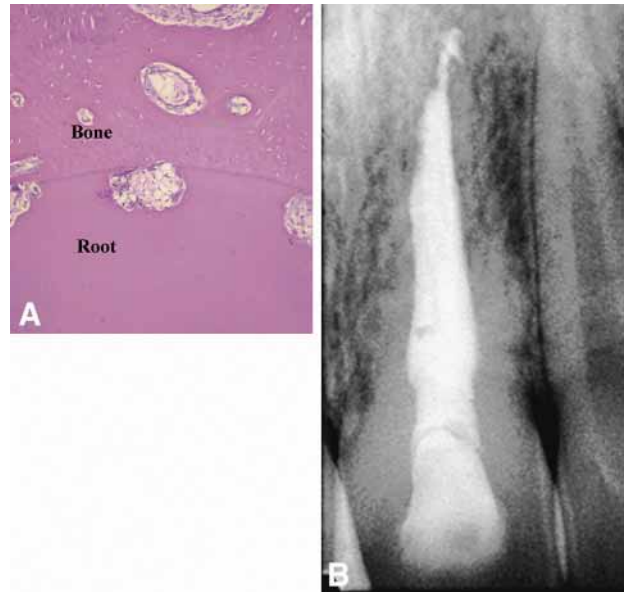

Fig. 6. Osseous replacement. A. Histologic slide showing bone directly attached to the root and areas of both bone and root undergoing active resorption. Both areas will later be replaced with new bone; in this way, the entire root will eventually be replaced by bone. B. Radiographic appearance. The root is being replaced by bone, and the lamina dura becomes lost around the root as it becomes incorporated in the bone.

how far and how fast the cells can travel in order to cover the damaged root surface. A localized injury over a small surface area favors cemental healing. Conversely, a diffuse injury over a large area will favor ankylosis with osseous replacement. It has been reported that destruction of over 20% of the root surface is required for osseous replacement to occur (20). As described above, the surface area of root damage is dependent on the scale of the initial injury which cannot be reversed. More importantly, it is dependent on the extent of the destructive inflammatory response. There is the opportunity here for the initial inflammation to be minimized by actions taken both immediately after the injury, where the way in which the tooth is handled is of crucial importance, and by the pharmacological manipulation of the inflammatory response.

External root resorption

As the name implies, the root resorption occurs on the outer surface of the root. Luxation injuries are the most likely injury where root resorption may result, and, as previously stated in this article, the long-

term outcome is dependent on whether the healing response is favorable or unfavorable. Figure 7 shows the order of likelihood of favorable to unfavorable healing following the different categories of luxation injuries occurring.

Resorption due to stimulus lasting a short duration (transient stimulus)

Short-acting stimulus is usually due to the mechanical damage of the traumatic injury alone without the presence of an additional stimulus. Very little can be done to reverse this initial attachment damage, therefore the main focus of treatment is to do everything possible to limit the destructive inflammatory process that occurs immediately after the injury. If the inflammation is minimized, the surface area of damaged root surface will also be kept to a minimum. It is, therefore, hypothesized that a smaller damaged root surface will result in a more favorable healing outcome.

Treatment strategies are therefore directed at avoiding or minimizing the severity of the initial inflammatory response. These can be listed more specifically as:

1. Prevention of the initial injury.
2. Minimizing additional damage after the initial injury.
3. Pharmacological manipulation (shut down) of the initial inflammatory response.
4. Possibly stimulating cemental, rather than bone, healing.

5. Slowing down the osseous replacement when it is inevitable.

1. Prevention

Nothing can be done about the initial damage caused by the primary traumatic injury. However, there is evidence that preventative measures successfully limit these injuries. In athletics, for instance, the mouth-guard is a proven protective device against traumatic damage to the teeth (21). Education at all levels should be aim to increase the usage of mouth-guards and other protective devices.

2. Minimizing Additional Damage after the Injury.

Steps must be taken to minimize additional avoidable damage to the periodontal ligament. As with the techniques for prevention outlined above, decisive and correct action taken at the site of injury is probably the most critical step in minimizing additional attachment damage after an injury. Reports indicate that the personnel typically present at the site of a traumatic dental injury are generally poorly educated in the appropriate handling of these injuries (22). It, therefore, remains a huge challenge to the dental community to educate these people in the correct emergency treatment of a traumatic injury.

Initially, the tooth should be gently repositioned back into its original position as soon as possible. The patient should then be sent to the emergency room or dentist immediately. If splinting is necessary it should be performed with a functional splint for 7–10 days (11, 17, 23) (Fig. 8). Most importantly, the splint should be constructed to allow adequate cleaning, thereby minimizing the wicking of bacteria from dental plaque into the blood clot between the tooth and the socket wall.

In the case of an avulsed tooth, replanting the tooth as soon as possible is the preferable treatment. If the tooth cannot be replanted for any reason, the extra-oral *dry time* must be minimized by placing the tooth in an appropriate storage medium. Milk, for instance, is a practical storage medium (24) as it is found near most accident sites, is relatively free of bacteria and has an osmolarity that is not excessively harmful to the periodontal ligament cells. Other practical alternatives include sterile saline or saliva (vestibule of the

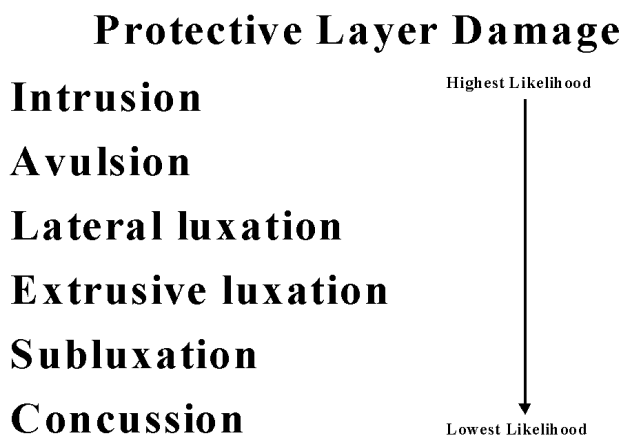


Fig. 7. Order of likelihood, from favorable to unfavorable healing outcomes, following the different categories of luxation injuries.

mouth). Water, on the other hand, is an unsuitable medium for the storage of avulsed teeth.

However, newer specialized media such as Hank's Balanced Salt Solution, which is a common culture medium, or ViaSpan, a liver transplant medium, may be able to sustain the viability of periodontal ligament cells for considerably longer periods than milk can (24). The use of these specialized storage media has been deemed impractical as they are seldom found near the accident site. However, if we consider that more than 60% of accidents occur close to the home or school, it should be possible to educate the public to have these media available at these sites. Media, such as ViaSpan, could also be placed in ambulances where they could be used for severe injuries in life-threatening situations that do not allow immediate replantation (22).

3. Pharmacological manipulation of the inflammatory response

An additional approach might be to pharmacologically manipulate the inflammatory response in order to minimize destruction and facilitate repair of the damaged root surface by new cementum and periodontal ligament. Tetracycline has been widely used in the treatment of periodontal disease because of its sustained antimicrobial effects. Recently, tetracycline has been shown to possess anti-resorptive, as well as anti-microbial, properties; specifically, it has a direct inhibitory effect on osteoclasts and collagenase (25, 26). Thus, if these drugs were found to be as effective as penicillin drugs in limiting bacterial contamination after a traumatic injury and, in addition to this, they possessed an anti-resorptive, they might replace penicillin as the systemic antibiotic of choice after this type of injury has occurred.

Our group has tested the effectiveness of systemic tetracycline in an 'infection' model in dogs and found the results to be similar to penicillin (26). In addition, when used in an osseous remodeling model, tetracycline was found to result in significantly more cemental healing than penicillin, which did not help healing at all (25). Provided the patient is not susceptible to tetracycline staining, we therefore recommend replacing systemic penicillin with tetracycline after a traumatic injury.

While tetracycline affects osteoclasts that are present at the site of resorption, drugs are also available

that affect the recruitment of osteoclasts to the injury site, meaning that the combination of the two types of drugs might have a synergistic effect on the inhibition of root resorption. Glucocorticoids have been widely used to reduce the deleterious effects of inflammatory responses; more specifically, they have been shown to reduce osteoclastic bone resorption by affecting cell recruitment using a plethora of mechanisms. Therefore, they could potentially also be useful in manipulating the initial inflammatory response after attachment damage, thereby encouraging repair by cementoblasts rather than bone-derived cells.

We tested the effect of local and systemic dexamethasone in a dog model that has been shown to produce a peak of inflammatory root resorption. Topical dexamethasone was found to be useful while systemic usage was not. Our group has recently tested Ledermix®, a drug combining tetracycline and corticosteroids (27), placed in the root canals of dogs *im-*

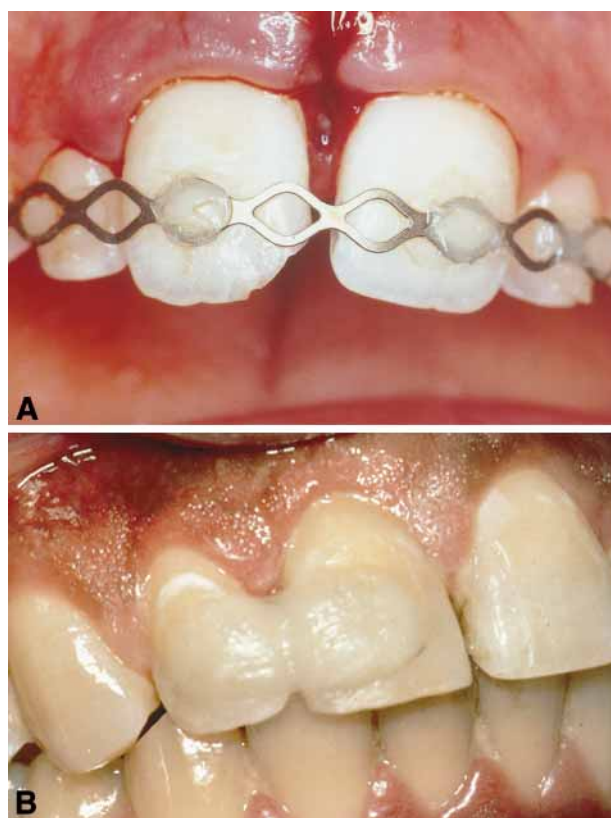


Fig.8. Examples of functional splints. A. TTS splint. This splint allows space for adequate cleaning, thereby minimizing infection due to plaque and food debris. It is flexible in a horizontal and vertical direction. B. Resin splint that, whilst allowing functional movement, is too thick, thus making it impossible for patients to keep it clean.

mediately after tooth replantation. Thus, a tetracycline/corticosteroid combination is deposited in a controlled released fashion to the periodontal ligament through the dentinal tubules. The results were extremely promising compared to standard controls (Fig. 9). We therefore feel confident that in severe traumatic injuries, where a large surface area of periodontal inflammation is expected, removing the pulp and placing Ledermix® into the canal at the emergency visit will become standard practice.

4. Stimulate Cemental Healing

If it were possible to stimulate periodontal cell growth, we may be able to limit the number of osseous cells able to attach to the denuded root surface, thus decreasing osseous replacement and slowing down the loss of the tooth. Fibroblast-like cells in culture secrete factors that have been shown to be significantly active in tissue repair processes. We hypothesized that the supernatant of cultured gingival fibroblasts, if used as a storage medium, might contain a number of biologically-active factors that might promote periodontal ligament regeneration and repair. We tested this ‘conditioned medium’ as a storage medium in dogs’ teeth for extended periods. The results were extremely promising, as the ‘conditioned medium’ appeared superior to Hanks’ Balanced Salt Solution and Viaspan after 96 h storage (28). However, when tested as a periodontal ligament-stimulating medium on roots with various extended dry times, the results for this medium were disappointing as ViaSpan was the only medium which had a beneficial result (29). Therefore, work needs to continue to promote periodontal stimulation after a traumatic injury.

In the meantime, recent studies have found that Emdogain® (enamel matrix protein; Biora, Malmo, Sweden) may be extremely beneficial in teeth with

	Favorable healing (%)	Unfavorable healing (%)
Ledermix	69	41
Control	14	86

P<0.001 Ledermix vs. control

Fig.9. Favorable vs. unfavorable healing when Ledermix® was used immediately after the replantation of dried dog teeth. In controls when Ledermix® was not used, favorable healing occurred at a much lower rate.

extended extra oral dry times, as it not only makes the root more resistant to resorption but also stimulates the formation of new periodontal ligament from the socket (30, 31) (Fig. 10). Up until this point, most studies with Emdogain® have tested the medication in the most extreme cases where no periodontal ligament is expected to be present on the root at the time of repositioning. Recent reports indicate, however, that it may be particularly beneficial in those less extreme cases where small areas of osseous replacement are expected or are present (30).

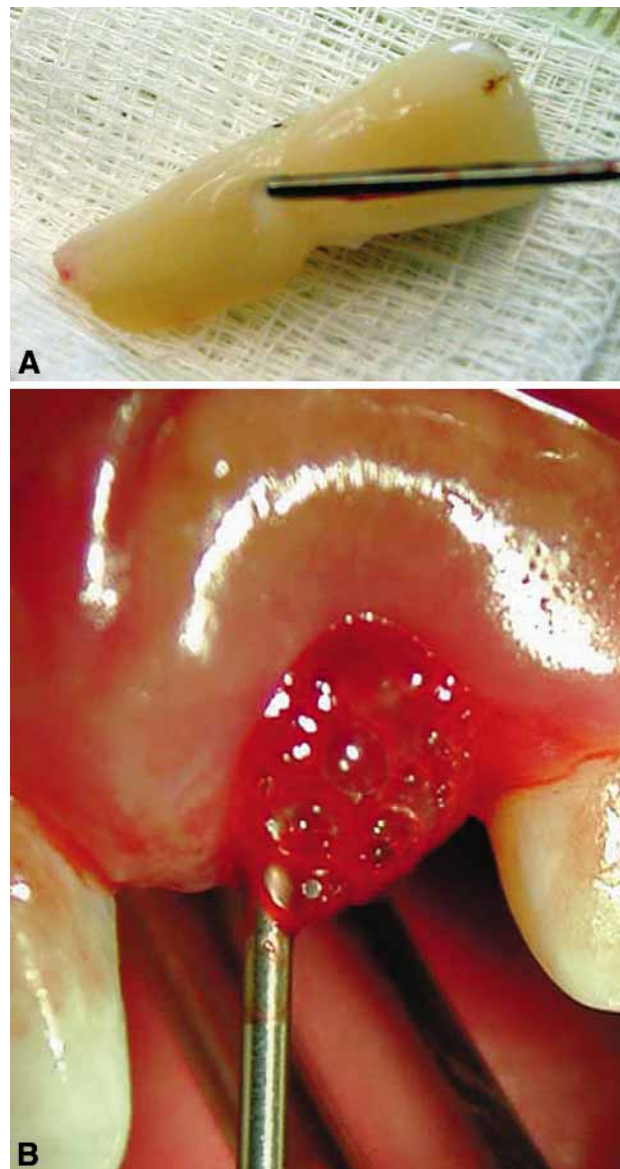


Fig.10. Emdogain® placed A. on the root surface and B. in the socket before the tooth is replanted.

5. Slow down 'inevitable' osseous replacement

When the periodontal ligament on the root surface is definitely destroyed and osseous replacement is inevitable, the focus of the treatment is to slow down the replacement of the root with bone. Injuries where such a situation might occur are intrusive injuries or avulsion injuries with extended extra-oral dry times. Presently, in intrusive injuries, the tooth is repositioned and the inevitable osseous replacement accepted, a philosophy which should be re-examined in light of improved treatment methods described in section 4 and below. For avulsion injuries with extended dry times, the methods described below are presently appropriate and accepted:

1. All remaining periodontal ligament debris is removed from the root by thorough curettage or with the use of acid.
2. Fluoride has been shown to effectively slow down remodeling of the root to bone and the root is soaked in fluoride for 5 min before replantation (32, 33).
3. Bisphosphonates are drugs that have been found to slow down osteoporosis in post-menopausal females. We tested the topical use of bisphosphonates in extracted dog's teeth which had been dried for an extended period (34). The use of the bisphosphonate slowed down the osseous replacement but, at this stage, we do not know if its effect is superior to the proven effect of topical fluoride, a much cheaper drug.
4. It appears from preliminary studies that both fluoride and bisphosphonate will be replaced by Emdogain® as the drug of choice for this application (30, 31).

Resorption due to a long-lasting (progressive) stimulus

As described previously, destructive inflammation and root resorption will continue as long as a stimulus for the inflammation is present. Pressure, pulpal infection and sulcular infection are common, long-lasting stimuli for progressive root resorption. The presence of a long-lasting stimulus does not imply that a short-acting stimulus was not initially present due to the initial injury. While it is comfortable to separate out these stimuli for the sake of explanation, it must be remem-

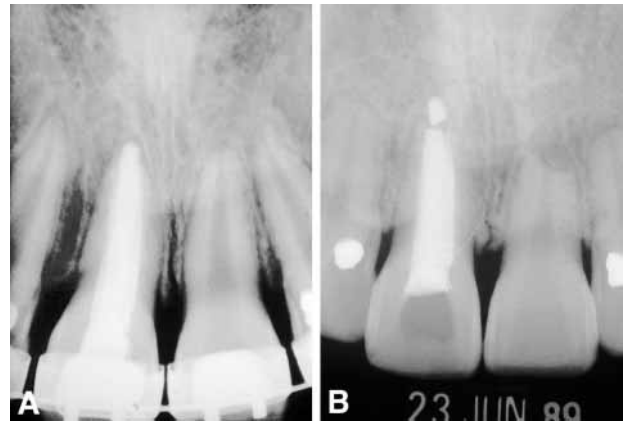


Fig. 11. Pressure resorption due to orthodontic treatment. A. Teeth at the start of orthodontic treatment. B. Severe root resorption on the left central incisor after orthodontic treatment. Note that, even though considerable resorption has taken place, favorable healing at the apex with cementum can be seen. (Courtesy Dr IB Bender)

bered that they, and the consequences that result from them, are often superimposed on each other.

Pressure

Pressure damage can be caused by many different sources, but the most common causes tend to be either orthodontic tooth movement or impacted teeth or tumors. Different theories of the mechanism of orthodontic tooth resorption have been put forward but presently it is considered to be a 'sterile' inflammation, with all the expected inflammatory cytokines present during active resorption. In most cases, orthodontic tooth movement can be considered a 'controlled' trauma where pressure is spread evenly over a root area, therefore minimizing the inflammatory response, which, in turn, favors resorption of the bone rather than the root. However, in rare cases where the pressure is localized to the apical region, it can be intense enough to cause cemental damage and apical root resorption. The resorption can result in considerable shortening of the root that, in some cases, will compromise the crown:root ratio of the tooth (Fig. 11).

Root resorption due to orthodontic pressure has always been considered to be external root resorption. However, this is not necessarily true. Damage takes place at the apex of the tooth near the cemental-dental junction due to the orthodontic pressure. Therefore, protective damage can be either cementum or predentin. Because the predentin can also be affected,

it is not unusual to see radiographic evidence of internal apical resorption during the active stage of the process. In 1997, Bender *et al.* suggested the term periapical replacement resorption (PARR) for describing this type of resorption (35).

For impacted teeth or tumors, the resorption will occur wherever the pressure from the impaction/tumor occurs. Treatment is relatively easy, in that removal of the source of the pressure will result in the cessation of resorption in the majority of cases. Repair and re-countouring of the root will occur after the pressure has been removed and this can result in some additional root loss for a limited time after the pressure has been removed. Interestingly, even though a considerable amount of root structure may be lost due to orthodontic pressure, favorable healing with cementum is always expected. The reason for this is explained by the fact that the resorption takes place over a cross-section of the root in an apical to coronal direction. Thus, even when a large amount of root structure has been lost from the root surface to be repaired, the area to be repaired stays relatively small, and cells with the potential to produce cementum can surround the area on the remaining healthy root. Therefore cemental healing is favored (Fig. 11).

Pulp space infection

Apical periodontitis with apical root resorption

The pulp of the tooth can become necrotic for many reasons but the predominant cause is a bacterial challenge through caries. When the pulp defenses are overcome and the pulp is necrotic and infected, the inflammatory stimulators will contact the surrounding periodontal attachment through openings from the pulp to the periodontium. In most routine cases, the root surface is protected by the intact cementum on the root surface and the communications will be conducted primarily through the apical foramina or, occasionally, through accessory canals.

Invariably, the periodontal inflammation is accompanied by slight resorption of the root at the cemento-dentinal junction. This resorption is usually not apparent radiographically but is routinely observed in a histologic evaluation. For a review of treatment strategies, please see the article in this issue by Trope M. and Bergenholtz G.: *The microbiological*

basis for endodontic treatment: can a maximal outcome be achieved in one visit?

Lateral periodontitis with root resorption

When the root loses its cemental protection, lateral periodontitis with root resorption can result (Figs 3, 4). In order for a pulp space infection to develop, the pulp must first become necrotic. This process will occur after all except the most minor luxation injuries because displacement of the tooth results in severing of the apical blood vessels. In mature teeth, pulp regeneration cannot occur and, usually by three weeks, the necrotic pulp will become infected (15, 36, 37). Because a serious injury is required for pulp necrosis, it is usual that areas of cemental covering of the root are also affected, resulting in its protective, insulating quality being lost. This means that bacterial toxins can now pass through the dentinal tubules and stimulate an inflammatory response in the corresponding periodontal ligament (38).

The result of this is the resorption of the root and bone. The periodontal infiltrate consists of granulation tissue with lymphocytes, plasma cells, and polymorphonuclear leukocytes. Multinucleated giant cells resorb the denuded root surface and this continues until the stimulus (pulp-space bacteria) is removed (36) (Fig. 3). Radiographically, the resorption is observed as progressively radiolucent areas of the root and adjacent bone (Fig. 4).

Treatment

The attachment damage due to the traumatic injury and minimizing the subsequent inflammation was the focus of the emergency visit. The practitioner's should ideally pay attention to pulp space infection 7–10 days after the injury (36, 37). Root canal disinfection removes the stimulus for the peri-radicular inflammation and the resorption will stop (36, 37). In most cases, favorable healing with cementum will occur but, if a large area of root is affected, osseous replacement may result by the mechanism described earlier. In cases where the peri-radicular inflammation is stimulated by pulpal infection, bone resorption is usually extensive. This may be considered to be a protective reaction since this extensive bone resorption will slow down the ability of

bone producing cells from attaching directly to the damaged root surface, allowing for healing with cementum.

Treatment principles include the prevention or elimination of the stimulus for the peri-radicular inflammation, i.e. prevention or elimination of the pulp space bacteria.

1. Prevention of pulp space infection

A. Maintain the vitality of the pulp. If the pulp is vital, the canal will be free of bacteria and, thus, this type of external inflammatory root resorption will not occur. In severe injuries where vitality has been lost it is possible, under some circumstances, to promote revascularization of the pulp space (39) (Fig. 12). The vital tissue that is present in the pulp space has been reported to be either new pulp or even periodontal ligament that has grown into the space. Revascularization is possible in young teeth with incompletely formed apices (> 1.1 mm wide radiographically) if they are replaced close to their original position soon after the injury (39, 40, 41). In the case of an avulsed tooth, revascularization is considered possible if replantation occurs before 60 min of dry time has elapsed. For avulsed teeth, soaking it in doxycycline for 5 min before replantation has been shown to double the revascularization rate (40, 41). It is hypothesized that this is because doxycycline will kill bacteria on the root surface and, importantly, at the pulp lumen, thus allowing for the new tissue to grow into

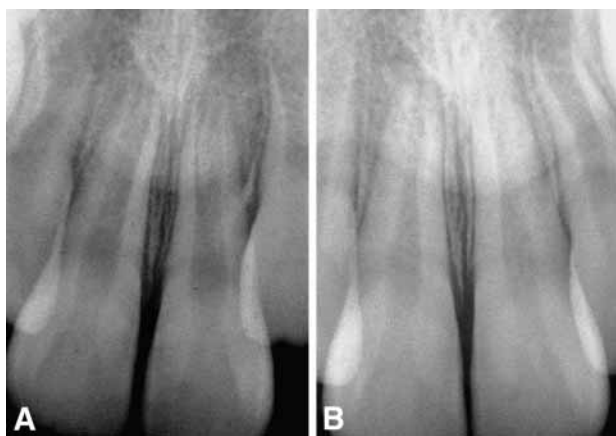

Figure 12. Revascularization of an immature tooth. A. The stage of root development soon after repositioning. B. One year later, it can be seen that the root has continued to develop and thicken.

the pulp space without challenge from bacteria. However, even under the best conditions revascularization will occur only about 50% of the time.

Revascularization after a traumatic dental injury is a race between the new tissue replacing the ischemically necrotic pulp and the bacteria moving into the unprotected pulp space. The new tissue will take about one month to revascularize a young pulp and, if bacteria do not populate the area before that time, revascularization will take place. Theoretically, if in an infected case with peri-radicular inflammation, the pulp could be effectively disinfected and reinfection prevented by an adequate coronal seal, it should be possible to revascularize a pulp space after it has become infected. This theory is confirmed by isolated cases that have started to appear within the last few years (42).

B. Prevent root canal infection by root canal treatment at 7–10 days. In teeth with closed apices, revascularization cannot occur. These teeth should be endodontically treated within 7–10 days of the injury before the ischemically necrosed pulp becomes infected (36, 37). From a theoretical point of view, the teeth treated during this time period can be considered as if this were equivalent to the treatment of a tooth with a vital pulp and, therefore, the endodontic treatment could be completed in one visit. However, efficient treatment is extremely difficult soon after a serious traumatic injury and, in the author's opinion, it is beneficial to start the endodontic treatment with chemomechanical preparation, after which an intracanal dressing with a creamy mix of calcium hydroxide is placed (43, 44). The practitioner can now obturate the canal at his/her convenience after the periodontal healing of the injury is complete approximately one month after the instrumentation visit (43, 44). There appears to be no necessity for long-term calcium hydroxide treatment in cases where the endodontic treatment is started within 10 days of the injury. Notwithstanding, in a compliant patient, the calcium hydroxide can be applied long-term (up to 6 months) to ensure periodontal health prior to filling the root canal with gutta-percha (37).

C. The elimination of pulp space infection. When root canal treatment is initiated later than 10 days after the accident or if active external inflammatory resorption is observed, the preferred antibacterial protocol con-

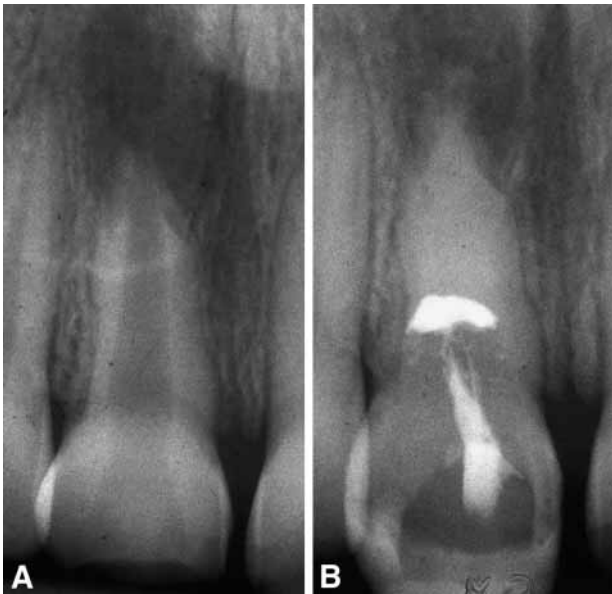


Fig. 13. Canal filled with thick mix of calcium hydroxide. A. Wide radiolucent canal. B. Canal appears to be calcified when filled with calcium hydroxide.

sists of a chemomechanical preparation, followed by long-term dressing with densely packed calcium hydroxide (37). Calcium hydroxide can affect an alkaline pH in the surrounding dentinal tubules, kill bacteria and neutralize endotoxin, a potent inflammatory stimulator.

The first visit consists of thorough chemo-mechanical instrumentation of the canal and the placement of a creamy mix of calcium hydroxide with a lentulo-spiral as an intracanal antibacterial agent. The patient is seen at approximately one month, at which time the canal is filled with a dense mix of calcium hydroxide. Once filled, the canal should appear radiographically to be calcified, since the radiodensity of calcium hydroxide in the canal is usually similar to the surrounding dentin (Fig. 13). A radiograph is then taken at three month intervals. At each visit, the tooth is tested for symptoms of periodontitis. In addition, healing of the resorptive process and the presence or absence of the calcium hydroxide i.e calcium hydroxide washout is also assessed.

Since the root surface is so radiodense as to make the assessment of healing difficult, the adjacent bone healing is assessed. If the adjacent bone has healed, it is assumed that the resorptive process has stopped in the root as well and the canal can be obturated with gutta-percha (Fig. 14). If it is felt that additional healing would be beneficial before obtu-

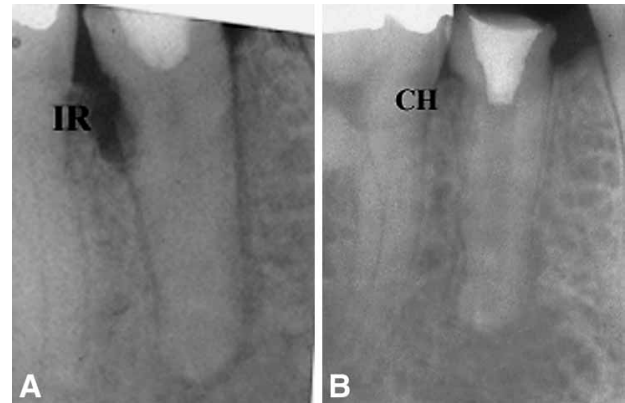


Fig. 14.. A. Destructive resorption is seen soon after the traumatic injury. B. After long-term $\text{Ca}(\text{OH})_2$ treatment, the resorptive defects have healed, and an intact lamina dura can be traced around the root. The tooth is ready for obturation.

ration, the need for replacing the calcium hydroxide in the canal is assessed. If the canal still radiographically appears calcified, there is no need to replace the calcium hydroxide. If, on the other hand, the canal has regained its lucent appearance, the calcium hydroxide should be re-packed and reassessed in another three months.

Sulcular infection

This progressive external root resorption, which is of inflammatory origin, occurs immediately below the epithelial attachment of the tooth, usually but not exclusively in the cervical area of the tooth. This type of resorption is most often referred to as cervical root resorption (17). However, the periodontal attachment of teeth is not always at the cervical margin, leading to the same process occurring more apically on the root surface. The anatomic connotation of its name has led to confusion and misdiagnosis of this condition. Because of this confusion, attempts have been made to rename this type of external resorption (18, 45, 46), and it is referred to as subepithelial external root resorption throughout this paper. Its exact pathogenesis is not fully understood (15) but, since its histological appearance and progressive nature is identical to other forms of progressive inflammatory root resorption, it appears logical that the pathogenesis would be the same (i.e. an unprotected or altered root surface attracting resorbing cells and an inflammatory response maintained by infection). Causes of the root damage immediately below the epithelial attachment of the root include or-

thodontic tooth movement, trauma, non-vital bleaching and other less definable cause (47). *The pulp plays no role in cervical root resorption and is mostly normal in these cases* (15).

Because the source of stimulation (infection) is not the pulp, it has been postulated that it is the bacteria in the sulcus of the tooth that stimulate and sustain an inflammatory response in the periodontium at the attachment level of the root (15). This theory is strengthened by the fact that bone resorption similar to marginal periodontitis will always accompany this type of root resorption and it is universally accepted that marginal periodontitis has a bacterial cause (Fig. 15).

Classification

Progression of the resorptive defect once the dentin has been penetrated is variable and unpredictable, and Heithersay has classified this type of resorption into four classes in order of severity (48) (Fig. 16). Resorptive defects in the root coronal or just below the attach-

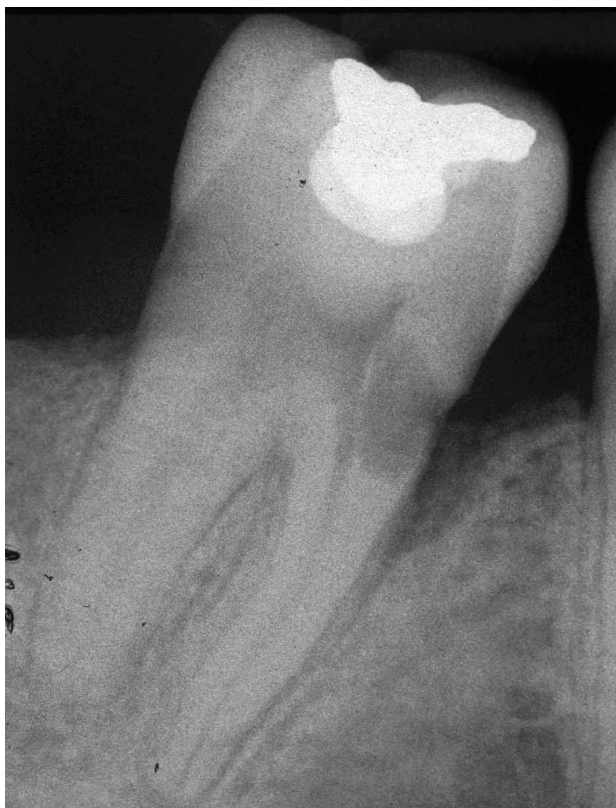

Fig. 15. Radiographic appearance of sub-epithelial external root resorption. Note the small opening and the ballooning of the defect inside the root. The pulp is not penetrated. Bone resorption similar to an angular bony defect is seen.

ment level are relatively easy to treat but, on the other hand, if the defect extends below the bone level, it is very complicated and sometimes impossible to treat.

Histological Appearance

Histologically, the defect appears similar to any external inflammatory root resorptive defect. There is usually a small opening into the root, with large amounts of granulomatous tissue inside the defect and multinucleated giant cells resorbing the dentinal structure. In extensive defects, osseous tissue may be seen inside the granulomatous tissue, indicating quiescent periods in the process where healing with reformation of an attachment may have been attempted. Even in the most extensive defects, the predentin/odontoblastic layer is unaffected, demonstrating the resistant nature of this tissue (Fig. 17).

Clinical Appearance

Resorption of this type is asymptomatic and usually only detected through routine radiographs. Occasionally, if the resorption is extensive, symptoms of pulpitis will develop. When the resorption is longstanding, the granulation tissue can be seen undermining the enamel of the crown of the tooth, resulting in a pinkish appearance. This 'pink spot' has traditionally been used to describe the pathognomonic clinical picture of internal root resorption, resulting in many cervical root resorption cases being misdiagnosed and treated as internal root resorption (Fig. 18). Probing may result in profuse bleeding, indicating the presence of inflamed tissue rather than normal attachment.

Radiographic Appearance

The radiographic appearance of subepithelial inflammatory root resorption can be vary quite consider-

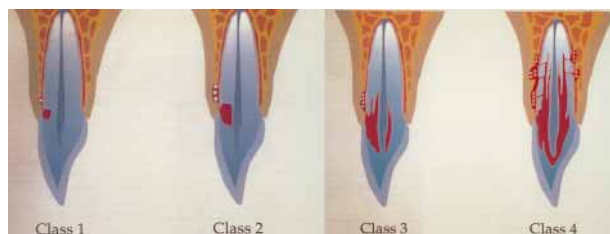


Fig. 16. Heithersay's classification of invasive cervical root resorption.

ably. If the resorptive process occurs mesially or distally on the root surface, it is common to see a small radiolucent opening into the root. The radiolucency expands coronally and apically in the dentin, and reaches, but usually does not perforate, the root canal (Fig. 18). If the resorptive process is buccal or palatal-lingual, the radiographic picture depends on the extent to which the resorptive process has spread in the dentin. It can be seen as a radiolucency at the attachment level or have spread a considerable way coronally or apically with a mottled appearance. Because the pulp is not involved, its outline can usually be distinguished through the resorptive defect (Fig. 15).

Treatment

Treatment of this type of resorption poses many problems. In principle, it would be preferable to re-

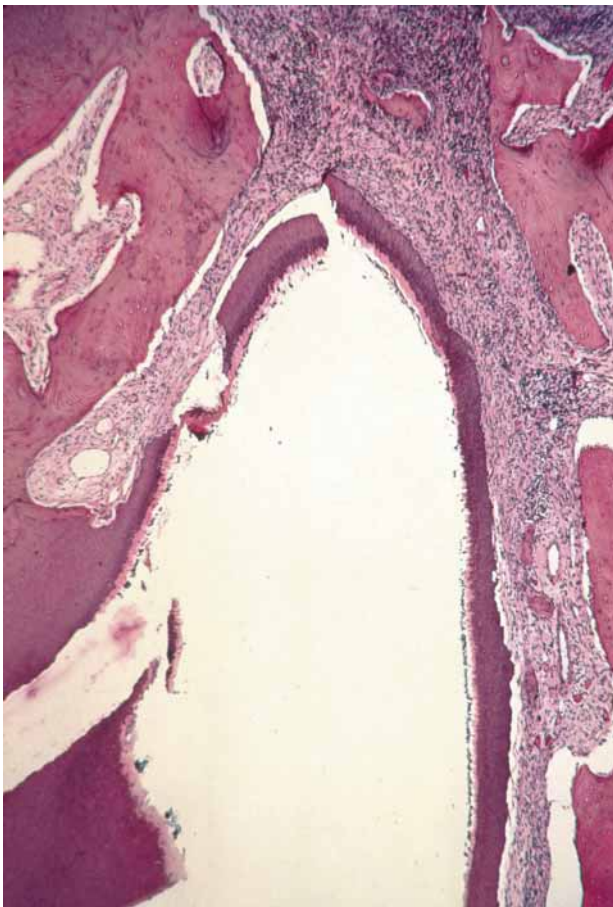


Fig.17. Histologic appearance of extensive resorption. Areas of bone are seen with the resorptive defect, indicating quiescent periods with an attempt to form an attachment apparatus. Note that, even with extensive resorption, the odontoblast predentin layer remains intact. (Courtesy Dr. R. Watson)

move the cause of the inflammation, i.e. the sulcular bacteria. However, unlike pulpal infection that is present in a closed environment, the sulcus is difficult to disinfect over a long period of time. Therefore, in these cases, with the hope that the damaged and susceptible root surface will be altered to be resistant to further resorption after treatment, the resorptive defect is the focus of treatment strategies.

Aims of Treatment

The aim of treatment is two-fold:

- *Stop continuation of resorption.* This may be achieved by removing all the granulomatous tissue from the root. In cases where removal of granulomatous tissue would cause unacceptable damage to supporting structures, an attempt is made to sever the blood supply to the granulomatous tissue, thus killing the resorptive cells and inhibiting progression of the resorptive process.
- *Replace the unprotected root surface with a foreign material that clastic cells cannot be attached to or penetrate.* Any well-sealing dental filling material can be used for this purpose. However, the problem exists that, while placing a filling material in the root inhibits attachment by clastic cells, it also does not allow attachment by those cells that provide for a normal periodontal ligament. Since most of these lesions are immediately below the attachment level, it is often not possible to leave attachable root structure above the defect while repairing it. The result is that root attachment will only occur apical to the filling material, leaving a periodontal pocket that is unacceptable.

As mentioned previously, in subattachment root resorption the pulp is mostly healthy and, therefore, root canal therapy is not required. However, in clinical terms, the resorptive defect usually impinges on the predentin (Fig. 16), making exposure of the pulp quite likely during removal of the granulomatous tissue. If the resorption is extensive the practitioner may choose to perform elective endodontic therapy before treatment proceeds.

Treatment aims can be met from an internal or external approach or by a combination of these two approaches, and possible treatment approaches that address the different clinical situations associated with this type of resorption are described below.

Localized defect entirely within the coronal third of the tooth or close to the cervical margin. Heithersay Class 1 or 2 (48).

External Approach Angled radiographs are taken to determine the exact location of the defect (buccal or lingual-palatal). Once the position has been determined, a full thickness flap is raised and the granulosomatous tissue is removed from the root and the bone defect (Fig. 19). It is also important to remove the granulosomatous tissue from sound, healthy bone so that revascularization of the resorbing tissues will not occur. The granulosomatous tissue can be removed with a curette or bur. The opening into the root should be as conservative as possible. The root defect is filled with a restorative material and the flap re-

placed in a way as to minimize the periodontal defect after healing. For the small coronal defect, this approach is preferable as, by raising the flap and curettage of the adjacent tissue, the blood supply to the resorbing cells is definitely severed. In addition, since the defect is small, a filling material can be placed in the susceptible root without creating a periodontal defect in the future.

Internal Approach It is also possible to remove the granulosomatous tissue and replace the space with a filling material from an internal approach. Heithersay has shown excellent results using trichloroacetic acid internally (49). The acid will chemically burn the granulosomatous tissue, thus necrosing it and providing space for the filling material internally. This chemical burning can also be achieved with the use of calcium

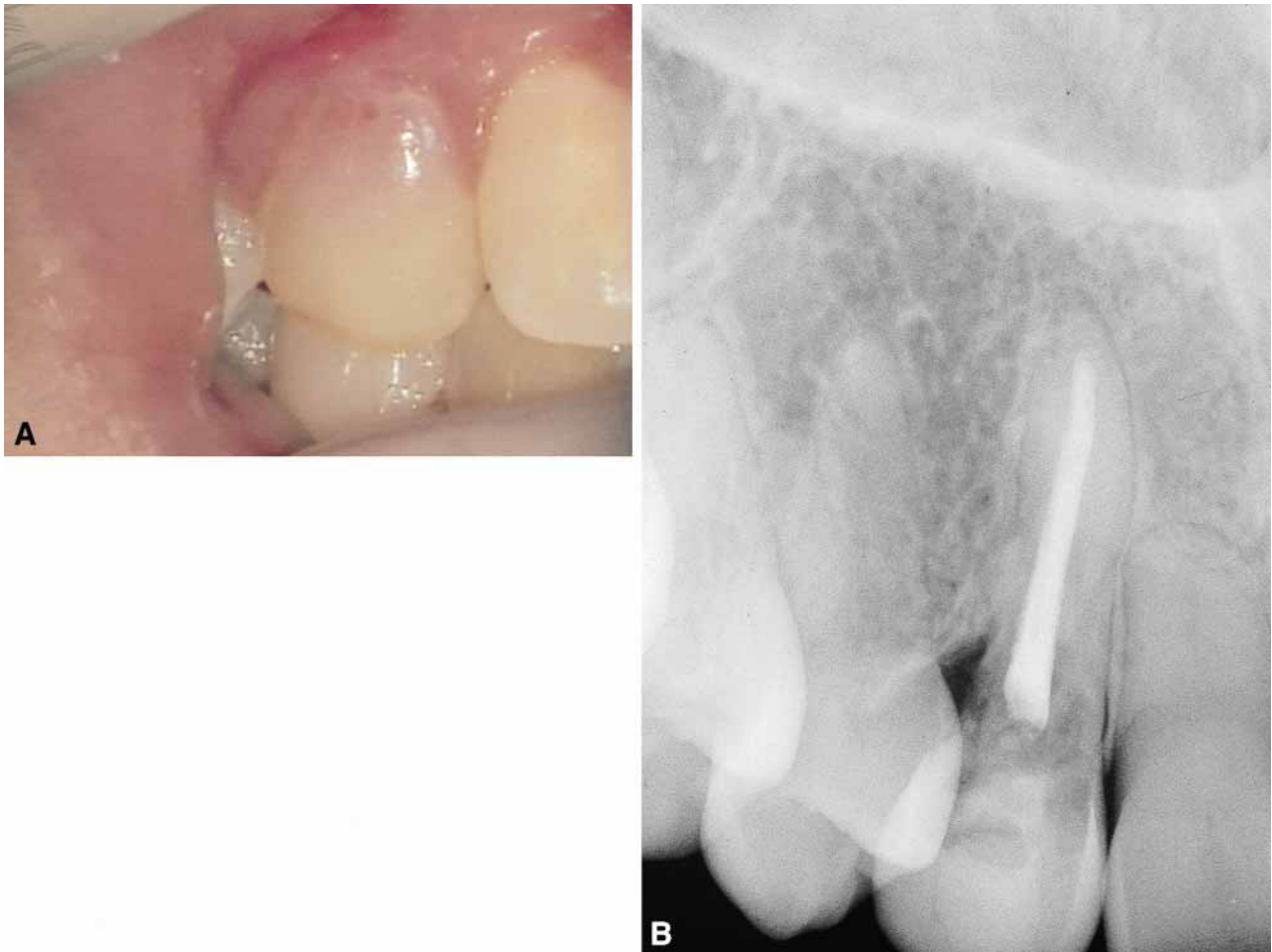

Fig. 18. A. "Pink spot" of external root resorption. The granulosomatous tissue has spread coronally and undermined the enamel, resulting in the pink colour seen in the crown. B. Radiographic appearance of tooth showing external root resorption with a root-treated tooth. The tooth had been root-treated 3 years previously before signs of resorption were present. Therefore, the lesion cannot be internal root resorption.

hydroxide but may take multiple applications to achieve the same results as trichloroacetic acid. Theoretically, a bur could be used but the chances of pulp exposure and/or extensive attachment damage are very high with this approach.

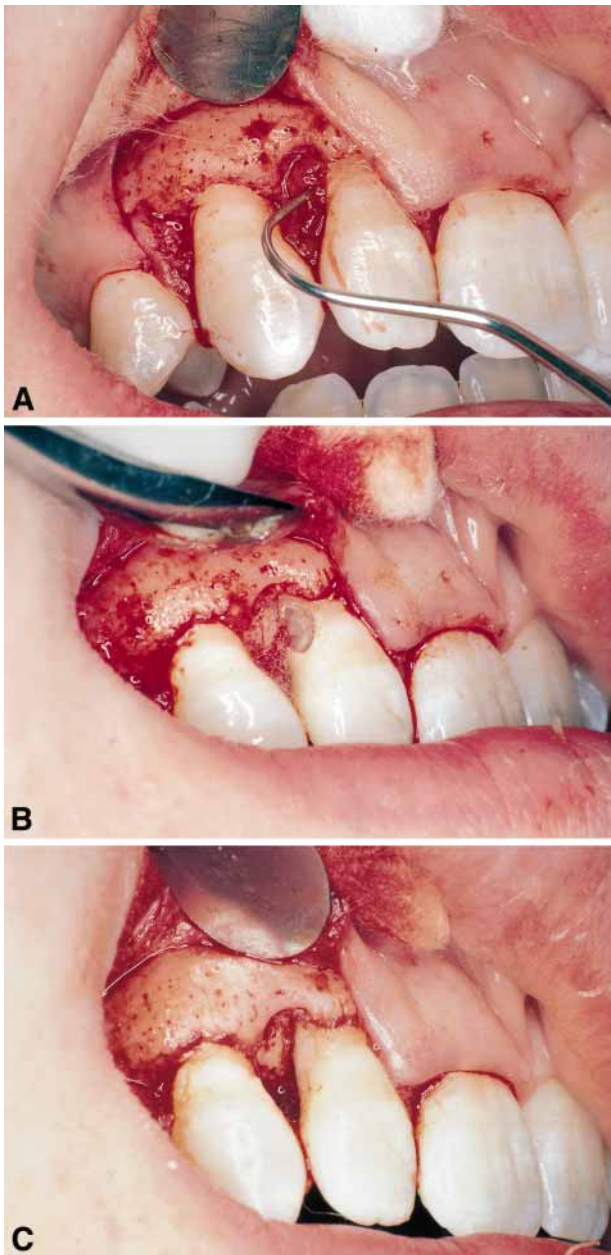


Fig. 19. Sub-epithelial root resorption treated by an external approach. A. The flap is raised, meaning the blood supply to the granulomatous tissue in the root has been cut. B. The tissue is removed from the root and bone and C. the root is filled with a composite resin filling.

Localized, medium-sized defect located in the coronal and mid-root dentin with a small subepithelial opening on the root (Class 3) (47).

Treatment of these defects pose a very difficult challenge. The practitioner should seriously consider whether treatment would offer the patient a better prognosis than leaving the tooth alone until symptoms appear or the attachment of adjacent teeth is affected. Extraction followed by an implant or fixed bridge should be seriously considered. Following are some treatment ideas:

External Approach When the resorptive defect extends apically, we have traditionally removed the entire root cementum surface adjacent to the granulomatous tissue in the dentin. Thus, root surface with the potential for periodontal ligament re-attachment has been removed. An alternative approach is to remove the resorptive tissue from a small opening at the most apical extent of the affected root, leaving coronal root surface onto which a new attachment might develop (Fig. 20). After the tissue is removed and the opening repaired with an acceptable restorative material, the defect and denuded root surface is covered with a spacer (freeze-dried bone), and the entire area covered with a Gore-Tex membrane (Gore Tex, W. L. Gore, Flagstaff, AZ). Other approaches include:

- *Forced eruption.* If the remaining root apical to the resorption defect is long enough to maintain the tooth forcefully erupting, the tooth is a very effective treatment method. The resorption defect is moved to a position coronal to the adjacent attachment. The entrance of the defect into the root can now easily be found and the defect cleaned and restored. Reshaping of the 'raised' bony contour now allows an ideal architecture to remain.
- *Forced eruption/re-intrusion.* If the procedure described above is complete, but it is felt that the crown root ratio is not ideal, after the repair is complete the tooth can be orthodontically moved into its original position (41). While biological width will always develop apical to the filling material, attachment would still be superior to that attained with forced eruption only.
- *Intentional replantation.* Intentional replantation should achieve the same result as forced eruption, with or without re-intrusion, and can be considered

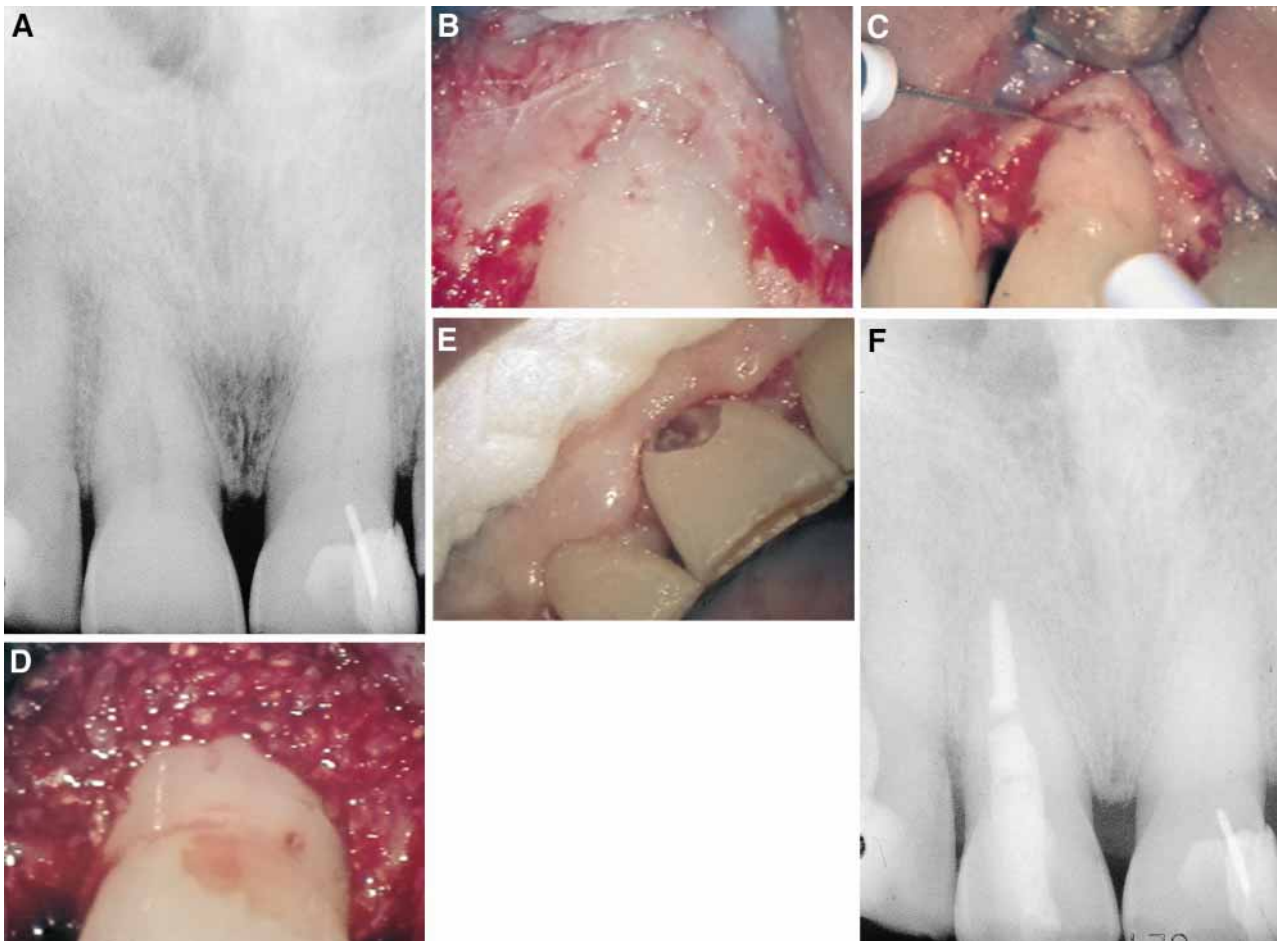


Fig. 20. A. Radiograph showing the external resorptive defect extending past the mid-root level. B. The flap has been raised, with care taken to leave as much of the root structure intact as possible. C. Granulomatous tissue is removed from the bone. D. A barrier is used to stop new tissue from growing into the root or revascularizing the necrotic tissue left inside the root. E. After approximately one month, an external opening is made above the attachment, and the necrotic granulomatous tissue is removed and F. as viewed radiographically, replaced with a filling material.

if the practitioner is confident that the resorbed root will not fracture on extraction.

External Approach/Internal Approach The need for root canal therapy is assessed and depends on the extent of the lesion. In these extensive lesions, elective endodontic therapy is often the best choice as a pulp exposure at any time during the procedure complicates an already difficult treatment. A flap is raised and the granulomatous tissue is aggressively removed from the bony defect only (Fig. 20). Care is taken to leave as much root-structure intact as possible. Since the source of the blood supply to the root defect is the periodontal structures that have been severed during surgery, necrosis of the resorbing tissues in the root results. To stop new tissue from growing into the root or revascularizing the necrotic tissue left in-

side the root, a barrier membrane is used. After approximately one month, an opening is made externally above the attachment and the necrotic granulomatous tissue is removed and replaced with a filling material (Fig. 20). If esthetics is not a major consideration, mineral trioxide aggregate (MTA) should be a useful filling material for this purpose.

With this approach, an attempt is made to preserve the ‘attachable’ root surface by not penetrating the root with a bur during the initial surgical procedure. Since the defects are often in locations that are difficult to access, excessive amount of root is sacrificed, thus jeopardizing attachment after surgery. The success of this approach is dependent on the size of the opening of the defect into the root after the flap is raised. If the flap is raised with care, so that it does not put pressure on the root surface and break through the undermined

root surface, in most cases the opening into the root is very small and the procedure can proceed as described above. If, on the other hand, the opening into the root is large, the treatment plan should be re-assessed with extraction an option if a large periodontal defect is to be expected after surgery.

Internal Approach In the author's opinion, this approach is not predictable enough in these extensive cases and should, therefore, not be considered.

Large defect extending apically. Heithersay Class 4.

In the author's opinion, these cases offer such a poor prognosis that extraction and replacement with an implant or fixed bridge is the preferred approach.

Prevention Since we know some of the indirect causes of this type of root resorption, it is possible to propose measures that may prevent it:

- *Nonvital bleaching.* Research suggests that 30% hydrogen peroxide activated with heat damages the cementum layer through the dentinal tubules (50, 51). To minimize these factors the following protective steps are suggested.
 1. Protection of the dentinal tubules. Remove the gutta-percha apical to the cervical line to remove discolored dentin, but do not extend the preparation into the root. Use the crestal bone as a guide. Place a layer of cement (IRM, Cavit, glass ionomer) to prevent ingress of the bleaching agent apically and into the cervical dentinal tubules.
 2. Do not use heat. Walking bleaches have been effective for over a quarter of a century. Repeated treatments produce results equal to a one-sitting thermocatalytic procedure (51).
 3. Avoid etching the dentin. Some techniques suggest etching of the dentin before bleaching; however, a recent study showed similar bleaching results with and without etching (52).
 4. Do not use Superoxol as it is caustic. Some advocate sodium perborate (USP) and water for the walking bleach and report excellent results with no history of external resorption (51). Others showed *in vitro* the effectiveness of sodium perborate and water as a bleaching agent, though it took longer to work (51, 52).

Orthodontic therapy All orthodontic forces, in particular tipping forces, should be as light as possible in order that they do not crush the attachment apparatus while the tooth is being uprighted.

Surgical procedures Surgical procedures, including excessive use of surgical elevators, theoretically damage the attachment apparatus and should be avoided. Surgical procedures that could damage the cervical margin, for example the canine wire lasso, before the orthodontic movement of an impacted canine should not be used; rather, surgical exposure and banding with acid etch and resin should be used to facilitate coronal movement.

Periodontal procedures Procedures that leave the root surface denuded (i.e. without periodontal ligament or epithelium) should be avoided.

Future Strategies

A. Long-term disinfection of the sulcus. Advances in periodontal therapeutic techniques include treatments that have the potential to disinfect the sulcus over a long period of time (53). If successful, the removal of the inflammatory stimulus would be a preferable way to treat these defects.

B. Manipulation of the inflammatory response. Local injections of high doses of corticosteroids have been effective in treating giant cell bone lesions in a conservative manner (15). Since the multinucleated resorbing cells are similar to the cells in root resorption, the use of similar steroid doses might stop the progression of root resorption. The root canal could be used as a reservoir for the corticosteroids. Outcomes from this type of approach are being presently being assessed.

Internal root resorption

Internal root resorption is rare in permanent teeth, and is characterized by an oval-shaped enlargement of the root canal space (15) (Fig. 21). External resorption, which is much more common, is often misdiagnosed as internal resorption.

Etiology

Internal root resorption is characterized by the resorption of the internal aspect of the root by multinucleated giant cells adjacent to granulation tissue in the pulp. Chronic inflammatory tissue is common in the pulp, but only rarely does it result in resorption. There are different theories on the origin of the pulpal granulation tissue involved in internal resorption. The most logical explanation is that pulp tissue becomes inflamed due to an infected coronal pulp space. Communication between the coronal necrotic tissue and the vital pulp is

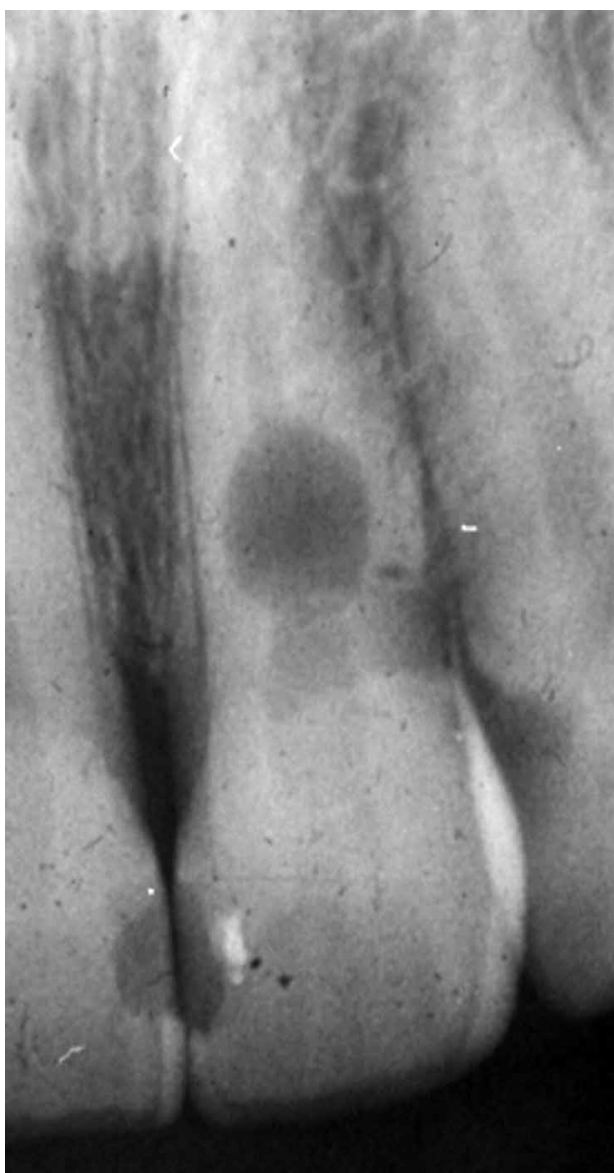


Fig. 21. Radiographic appearance of internal root resorption. A uniform oval radiolucency is seen in the root.

through appropriately oriented dentinal tubules (15). One investigator reports (9) that resorption of the dentin is frequently associated with deposition of hard tissue resembling bone or cementum and not dentin. He postulates that the resorbing tissue is not of pulpal origin but is 'metaplastic' tissue derived from the pulpal invasion of macrophage-like cells (11). Others (54) concluded that the pulp tissue was replaced by periodontium-like connective tissue when internal resorption was present. In addition to the requirement of the presence of granulation tissue, root resorption takes place only if the odontoblastic layer and predentin are lost or altered (45). Reasons for the loss of predentin adjacent to the granulation tissue are not obvious. Trauma frequently has been suggested as a cause (55). Some (9) report that trauma may be recognized as an initiating factor in internal resorption. They are divided into a transient type and a progressive type, with the latter requiring continuous stimulation by infection. Another reason for the loss of predentin might be the extreme heat produced when cutting on dentin without an adequate water spray. The heat presumably would destroy the predentin layer and, if the coronal aspect of the pulp later became infected, the bacterial products could initiate the typical inflammation in conjunction with resorbing giant cells in the vital pulp adjacent to the denuded root surface. Internal root resorption has been produced experimentally by the application of diathermy (56).

Clinical manifestations

Internal root resorption is usually asymptomatic and is first recognized clinically through routine radiographs. If perforation of the crown occurs and the metaplastic tissue is exposed to the oral fluids, pain may be a presenting symptom. For internal resorption to be active, at least part of the pulp must be vital, so that a positive response to pulp sensitivity testing is possible. It should be remembered that the coronal portion of the pulp is often necrotic whereas the apical pulp, which includes the internal resorptive defect, can remain vital. Therefore, a negative sensitivity test result does not rule out active internal resorption.

It is also possible that the pulp becomes non-vital after a period of active resorption, giving a negative sensitivity test, and giving radiographic signs of internal resorption and apical inflammation. Tra-

ditionally, the pink tooth has been thought to be pathognomonic of internal root resorption. The pink color is due to the granulation tissue in the coronal dentin, undermining the crown enamel. The pink tooth can also be a feature of subepithelial external inflammatory root resorption, which must be ruled out before a diagnosis of internal root resorption is made.

Radiographic appearance

The usual radiographic presentation of internal root resorption is a fairly uniform radiolucent enlargement of the pulp canal (Fig. 22). Because the resorption is initiated in the root canal, the resorptive defect includes some part of the root canal space. Therefore, the original outline of the root canal is distorted. Only on rare occasions, when the internal resorptive defect penetrates the root and impacts the periodontal ligament, does the adjacent bone show radiographic changes.

Histologic appearance

Like that of other inflammatory resorptive defects, the histologic picture of internal resorption is granulation tissue with multinucleated giant cells. An area of necrotic pulp is found coronal to the granulation tissue. Dentinal tubules, which contain microorganisms and communicate between the necrotic zone and the granulation tissue, can sometimes be seen. Unlike external root resorption, the adjacent bone is not affected with internal root resorption.

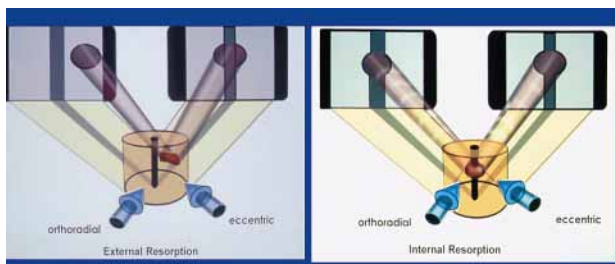


Fig. 22. Demonstration of the effect of angled X-rays on internal vs. external root resorption. A. Internal root resorption stays centered in the root while B. external resorption moves with the angled X-rays. (Courtesy Dr. Claudia Barthel).

Treatment

Treatment of internal root resorption is, conceptually, very easy. As the resorptive defect is the result of the inflamed pulp and the blood supply to the tissue is through the apical foramina, the correct approach to treatment is endodontic treatment that effectively removes the blood supply to the resorbing cells. After adequate anesthesia has been administered, the canal apical to the internal defect is explored and a working length short of the radiographic apex is used. The apical canal is thoroughly instrumented to ensure that the blood supply to the tissue resorbing the root is cut off. *By the completion of the root canal instrumentation it should be possible to obtain a blood free and dry canal with paper points.*

Calcium hydroxide is then spun into the canal to facilitate the removal of the tissue in the irregular defect at the next visit. At the second visit, the tooth and defect are filled using a soft gutta-percha technique. In rare cases where extremely large internal resorptive defects are found in the apical part of the canal, it is possible to surgically remove the defective root and place an endodontic implant in order to maintain stability of the tooth. With modern dental techniques, this treatment alternative should be weighed against the advantages of implant dentistry.

Diagnostic Features of External vs. Internal Root Resorption

It is often very difficult to distinguish external from internal root resorption, meaning that misdiagnosis and incorrect treatment result. What follows is a list of typical diagnostic features of each resorptive type.

Radiographic features

A change of angulation of X-rays should give a fairly good indication of whether a resorptive defect is internal or external. A lesion of internal origin appears close to the canal whatever the angle of the X-ray (Fig. 22). On the other hand, a defect on the external aspect of the root moves away from the canal as the angulation changes (Fig. 22). In addition, by using the buccal-object rule, it is usually possible to distinguish if the external root defect is buccal or lingual-palatal.

In internal resorption, the outline of the root canal is usually distorted and the root canal and the radiolucent resorptive defect appear to be contiguous (Fig. 21). When the defect is external, the root canal outline appears normal and can usually be seen ‘running through’ the radiolucent defect (Fig. 20A).

External inflammatory root resorption is always accompanied by the resorption of the bone in addition to that of the root (Fig. 15B, 18B). Therefore, radiolucencies are apparent in the root and the adjacent bone. Internal root resorption does not involve the bone and, as a rule, radiolucency is confined to the root (Fig. 21). On the rare occasions that the internal defect perforates the root, the bone adjacent to it is resorbed and appears radiolucent on the radiograph.

Vitality testing

External inflammatory resorption in the apical and lateral aspects of the root involves an infected pulp space, so that a negative response to sensitivity tests is required to support the diagnosis. On the other hand, since subepithelial external root resorption does not involve the pulp (the bacteria are thought to originate in the sulcus of the tooth), a normal response to sensitivity testing is usually associated with this type of resorption. Internal root resorption usually occurs in teeth with vital pulps and gives a positive response to sensitivity testing. However, in teeth that exhibit internal root resorption, it is not uncommon to register a negative response to sensitivity testing, as the coronal pulp has often been removed or is necrotic and the active resorbing cells are more apical in the canal. Also, the pulp might have become necrotic after active resorption has taken place.

Pink spot

With apical and lateral external root resorption, the pulp is non-vital and therefore the granulation tissue that produces the pink spot is not present in these cases. A possible sign of subepithelial external and internal root resorption is the pink spot, which is caused by the granulation tissue undermining the enamel.

Summary of possible diagnostic features

External inflammatory root resorption due to pulp infection

Apical. Negative pulp-sensitivity test, with or without a history of trauma.

Lateral. History of trauma, negative pulp-sensitivity test, lesion movement on angled X-rays, root canal visualized radiographically overlying the defect. Bony radiolucency is also apparent.

Sub-epithelial external inflammatory due to sulcular infection

History of trauma (often forgotten or not appreciated by the patient), positive pulp sensitivity test, lesion located at the attachment level of the tooth, lesion movement on angled X-rays, root canal outline is undistorted and can be visualized radiographically, crestal bony defect associated with the lesion, pink spot possible.

Internal Root Resorption

History of trauma, crown preparation or pulpotomy, positive pulp sensitivity test likely, may occur at any location along the root canal (not only attachment level); lesion stays associated with the root canal on angled X-rays, radiolucency contained in the root without an adjacent bony defect; pink spot possible.

The majority of misdiagnoses of resorptive defects are made between subepithelial external and internal root resorptions. The diagnosis should always be confirmed while treatment is proceeding. If root canal therapy is the treatment of choice for an apparent internal root resorption, the bleeding within the canal should cease quickly after pulp extirpation, as the blood supply of the granulation tissue is the apical blood vessels. If bleeding continues during treatment—and particularly if it is still present at the second visit—the source of the blood supply is external and treatment for external resorption should be carried out. It should also be possible to fill the entire canal from within internal resorption during obturation. Failure to achieve this should make the operator suspicious of an external lesion. Finally, if the blood supply of an internal resorption defect is re-

moved on pulp extirpation, any continuation of the resorptive process on recall radiographs should alert the dentist to the possibility that an external resorptive defect was misdiagnosed.

References

1. Hammarstrom L, Lindskog S. General morphologic aspects of resorption of teeth and alveolar bone. *Int Endod J* 1985; **18**: 293–298.
2. Seltzer S. *Endodontology*. Philadelphia: Lea & Febiger, 1988.
3. Loe H, Waerhaug J. Experimental replantation of teeth in dogs and monkeys. *Arch Oral Biol* 1961; **3**: 176–182.
4. Orban B. The epithelial network in the periodontal membrane. *J Am Dent Assoc* 1952; **44**: 632–637.
5. Andreasen JO. Review of root resorption systems and models. Etiology of root resorption and the homeostatic mechanisms of the periodontal ligament. In: Davidovitch ed. *The Biologic Mechanisms of Tooth Eruption and Resorption*. Birmingham, Alabama: EB-SCOP Media, 1989.
6. Karring T, Nyman S, Lindhe J. Healing following implantation of periodontitis affected roots into bone tissue. *J Clin Periodont* 1980; **7**: 96–103.
7. Polson AM, Caton JM. Factors influencing periodontal repair and regeneration. *J Periodont* 1982; **52**: 617–623.
8. Stenvik A, Mjor IA. Pulp and dentin reaction to experimental tooth intrusion. *Am J Orthodont* 1970; **57**: 370–376.
9. Wedenberg C, Lindskog S. Experimental internal resorption in monkey teeth. *Endod Dent Traumatol* 1985; **1**: 221–226.
10. Selvig KA, Zander HA. Chemical analysis and microradiography of cementum and dentin from periodontally diseased human teeth. *J Periodontol* 1962; **33**: 303–310.
11. Andersson L, Friskopp J, Blomlof L. Fiberglass splinting of traumatized teeth. *ASDC J Dent Child* 1983; **3**: 21.
12. Levin L, Trope M. Root Resorption. In: Seltzer S, Bender IB, Hargreaves K eds. *The Dental Pulp*. Carol Stream, IL: Quintessence Publishers, 2001.
13. Andreasen JO. The effect of extra-alveolar period and storage media upon periodontal and pulpal healing after replantation of mature permanent incisors in monkeys. *Int J Oral Surg* 1981; **10**: 43–51.
14. Soder PO, Otteskog P, Andreasen JO, Modeer T. Effect of drying on viability of periodontal membrane. *Scand J Dent Res* 1977; **85**: 167–172.
15. Tronstad L. Root resorption—etiology, terminology and clinical manifestations. *Endod Dent Traumatol* 1988; **4**: 241–249.
16. Nance RS, Tyndall D, Levin LG, Trope M. Diagnosis of external root resorption using TACT (tuned-aperture computed tomography). *Endod Dent Traumatol* 2000; **16**: 24–28.
17. Andreasen JO, Andreasen FM. *Textbook and Color Atlas of Traumatic Injuries to the Teeth*, 3rd edn. Copenhagen and St. Louis: Munksgaard and CV Mosby, 1994.
18. Trope M. Root resorption of dental and traumatic origin: Classification based on etiology. *J Pract Periodont Aesthet Dent*, 1998; **10**: 515–524.
19. Hammarstrom L, Pierce AM, Blomlof L, Feiglin B, Lindskog S. Tooth avulsion and replantation: a review. *Endod Dent Traumatol* 1986; **2**: 1–9.
20. Lindskog S, Pierce AM, Blomlof L, Hammarstrom L. The role of the necrotic periodontal membrane in cementum resorption and ankylosis. *Endod Dent Traumatol* 1985; **1**: 96–101.
21. Johnston T, Messer LB. An in vitro study of the efficacy of mouthguard protection for dentoalveolar injuries in deciduous and mixed dentitions. *Endodontics Dental Traumatol* 1996; **12**: 277–285.
22. Sae Lim V, Lim LP. Dental trauma management awareness of Singapore pre-school teachers. *Dent Traumatol* 2001; **17**: 71–60.
23. Trope M. Luxation injuries and external root resorption – etiology, treatment and prognosis. *CDA Journal* 2000; **11**: 860.
24. Trope M, Friedman S. Periodontal healing of replanted dog teeth stored in Viaspan, milk and Hanks Balanced Salt Solution. *Endod Dent Traumatol* 1992; **8**: 183–188.
25. Sae-Lim V, Wang C-Y, Choi G-W, Trope M. The effect of systemic tetracycline on resorption of dried replanted dogs' teeth. *Endod Dent Traumatol* 1998; **14**: 127–132.
26. Sae-Lim V, Wang C-Y, Trope M. Effect of systemic tetracycline and amoxicillin on inflammatory root resorption of replanted dogs' teeth. *Endod Dent Traumatol* 1998; **14**: 216–220.
27. Pierce A, Lindskog S. The effect of an antibiotic corticosteroid combination on inflammatory root resorption. *J Endod* 1988; **14**: 459–464.
28. Hupp JG, Trope M, Mesaros S, Aukhil I. Tritiated thymidine uptake in periodontal ligament cells of dogs' teeth stored in various media for extended time periods. *Endod Dent Traumatol* 1997; **13**: 223.
29. Pettiette M, Hupp J, Mesaros S, Trope M. Periodontal healing of extracted dog teeth air dried for extended periods and soaked in various media. *Endod Dent Traumatol* 1997; **13**: 113–118.
30. Filippi A, Pohl Y, von Arx T. Treatment of replacement resorption with Emdogain® – preliminary results after 10 months. *Dent Traumatol* 2001; **17**: 3–10.
31. Iqbal MK, Bamaas N. Effect of enamel matrix derivative (EMDOGAIN®) upon periodontal healing after replantation of permanent incisors in Beagle dogs. *Dent Traumatol* 2001; **17**: 36–34.
32. Bjorvatn K, Selvig KA, Klinge B. Effect of tetracycline and SnF₂ on root resorption in replanted incisors in dogs. *Scand J Dent Res* 1989; **97**: 477–482.
33. Selvig KA, Zander HA. Chemical analysis and microradiography of cementum and dentin from periodontally diseased human teeth. *J Periodont* 1962; **33**: 103–109.
34. Levin L, Bryson EC, Caplan D, Trope M. Effect of topical alendronate on root resorption of dried replanted dog teeth. *Dent Traumatol* 2001; **17**: 120–126.
35. Bender IB, Byers MR, Mori K. Periapical replacement resorption of permanent, vital, endodontically treated incisors after orthodontic movement: report of two cases. *J Endod* 1997; **23**: 768–776.
36. Trope M, Yesilsoy C, Koren L, Moshonov J, Friedman S. Effect of different endodontic treatment protocols on peri-

- odontal repair and root resorption of replanted dog teeth. *J Endod* 1992; **18**: 492–497.
37. Trope M, Moshonov J, Nissan R, Buxt P, Yesilsoy C. Short versus long term Ca(OH)₂ treatment of established inflammatory root resorption in replanted dog teeth. *Endodon Dent Traumatol* 1995; **11**: 124.
 38. Andreasen JO. Periodontal healing after replantation of traumatically avulsed human teeth. Assessment by mobility testing and radiography. *Acta Odontol Scand* 1975; **33**: 325–332.
 39. Kling M, Cvek M, Mejare I. Rate and predictability of pulp revascularization in therapeutically reimplanted permanent incisors. *Endodon Dent Traumatol* 1986; **2**: 83–89.
 40. Cvek M, Cleaton-Jones P, Austin J, Lownie J, Kling M, Fatti P. Effect of topical application of doxycycline on pulp revascularization and periodontal healing in reimplanted monkey incisors. *Endod Dent Traumatol* 1990; **6**: 170–177.
 41. Yanpiset K, Trope M. Pulp revascularization of replanted immature dog teeth after different treatment methods. *Endod Dent Traumatol* 2000; **16**: 211–217.
 42. Iwaya S, Ikawa M, Kubota M. Revascularization of an immature permanent tooth with apical periodontitis and sinus tract. *Dent Traumatol* 2001; **17**: 185–187.
 43. Bystrom A, Claesson R, Sundqvist G. The antibacterial effect of camphorated paramonochlorphenol, camphorated phenol and calcium hydroxide in the treatment of infected root canals. *Endod Dent Traumatol* 1985; **1**: 170–177.
 44. Sjogren U, Figdor D, Spangberg L, Sundqvist G. The antimicrobial effect of calcium hydroxide as a short term intracanal dressing. *Int Endod J* 1991; **24**: 119–125.
 45. Frank AL, Bakland LK. Nonendodontic therapy for supracrestal extracanal invasive resorption. *J Endod* 1987; **7**: 348–355.
 46. Gold SI, Hasselgren G. Peripheral inflammatory root resorption. *J Periodontol* 1992; **19**: 523–527.
 47. Heithersay GS. Invasive cervical resorption: an analysis of potential predisposing factors. *Quintessence Int* 1999; **30**: 83–95.
 48. Heithersay GS. Clinical, radiographic and histopathological features of invasive cervical resorption. *Quintessence Int* 1999; **30**: 27–37.
 49. Heithersay GS. Treatment of invasive cervical resorption: an analysis of results using topical application of trichloroacetic acid, curettage and restoration. *Quintessence Int* 1999; **30**: 98–110.
 50. Rotstein I, Lehr Z, Gedalia I. Effect of bleaching agents on inorganic components of human dentin and cementum. *J Endod* 1992; **18**: 290–296.
 51. Rotstein I, Mor C, Friedman S. Prognosis of intracoronal bleaching with sodium perborate penetration in vitro: 1 year study. *J Endodon* 1993; **1**: 10–12.
 52. Weiger R, Kuhn A, Lost C. Radicular penetration of hydrogen peroxide during intra-coronal bleaching with various forms of sodium perborate. *Int Endodon J* 1994; **6**: 313–317.
 53. Fiorellini JP, Paquette DW. The potential role of controlled release delivery systems for chemotherapeutic agents in periodontics. *Curr Opin Dent* 1992; **2**: 63–79.
 54. Stanley HR. Diseases of the Dental Pulp. In: Tieck RW, ed. *Oral Pathology*. New York: McGraw Hill Co, 1965.
 55. Wedenberg C, Zetterqvist L. Internal resorption in human teeth/a histological, scanning electron microscope and enzyme histo-chemical study. *J Endod* 1987; **13**: 255–261.
 56. Gottlieb B, Orban B. Veranderungen in Periodontium nach chirurgischer Diathermie. *ZJ Stomatol* 1930; **28**: 1208–1212.